

Pharmacological effect of T-NilPlus® and Synertox®, commercial anti-mycotoxins, on broiler chickens in Egypt

Magdy S. Amer¹

 0000-0001-7172-5656

Iman S. El-Tokhey¹

 0000-0003-2308-8036

Nani Nasreldin²

 0000-0001-5915-8601

Rasha A. Eltaysh¹

 0000-0002-7977-0117

Reham A.El-Shafei^{1*}

 0000-0003-2449-0609

¹ Mansoura University, Faculty of Veterinary Medicine, Department of Pharmacology, Mansoura, Egypt

² New Valley University, Faculty of Veterinary Medicine, Department of Pathology and Clinical Pathology, El-Kharga, P.O. Box 72511, Egypt.

*Corresponding author:

Email address:

dr_reham16@yahoo.com

Abstract

The present study was carried out to investigate the potential ameliorative effect of two commercial anti-mycotoxins, containing *Saccharomyces cerevisiae* cell wall as prebiotic (T-Nil Plus®) and *Bacillus subtilis* as probiotic (Synertox®) on performance and some biochemical parameters of broilers. One hundred and twenty chicks one day old chicks were divided into 3 equal groups. 1st group was served as control, 2nd group was given T-Nil Plus®. The 3rd group was given Synertox®. Chicken's performance was estimated. Serum samples obtained from each group for biochemical analysis. Tissues samples were collected for histopathological examination. The obtained results revealed that, T-Nil plus® induced a marked reduction in body weight gain and an elevation in Feed consumption, moreover, a marked elevation in, alanine aminotransferase (ALT), creatinine and malondialdehyde (MDA) and a marked reduction in aspartate aminotransferase (AST) was detected. While Synertox® caused a significant decrease in body weight, body weight gain and no change in feed conversion rate (FCR) and a marked elevation in ALT, creatinine and a marked reduction in AST and nitric oxide (NO) and it caused a significant reduction in serum glucose level of the birds. In conclusion, Synertox® induced a powerful effect comparing to T-Nil Plus®, as it induces a good FCR and increases the response of the birds against oxidative stress.

Keywords: Broiler; Synertox®; T-Nil Plus®, Performance, Oxidative stress.

Submitted: 2021-10-04

Accepted: 2022-02-11

Published: 2022-12-07

Additional information and declarations
can be found on page 18

© Copyright 2022
Magdy S. Amer et al.

open access 



Distributed under Creative Commons CC-BY 4.0

Cite this as:

Amer MS, El-Tokhey IS, Nasreldin N, Eltaysh RA, El-shafei RA. Pharmacological effect of T-Nil-Plus® and Synertox®, commercial anti-mycotoxins, on broiler chickens in Egypt. Veterinaria México OA. 2022;9. doi: 10.22201/fmvz.24486760e.2022.997.

Study contribution

The extensive uses of antimycotoxins in Egyptian poultry farms necessitate more investigations on their adverse effects; if any; on treated poultry. This work evaluates the impact of two commercial products of anti-mycotoxins; (T-Nil Plus®) and (Synertox®); which widely used in Egypt on performance, some biochemical parameters and histopathological changes in treated broilers. This study shows the benefits of using (Synertox®) to the bird performance, so it is recommended as anti-mycotoxin product for using as it induces a good feed conversion ratio and increases the response of the birds against oxidative stress.

Introduction

Poultry industry is one of the most important food suppliers in the world. Chicken meat is considered as a healthy animal food for human consumption because it represents an important source of animal proteins with high biological value and fats.⁽¹⁾ Many problems are facing poultry production such as mycotoxins, which are of great economic loss. Fungi are organisms which distributed widely on earth with high environmental and medical importance. Many fungi produce biologically active metabolites called mycotoxins including aflatoxins that induce hepatotoxic and carcinogenic effects to human and animals especially the poultry as they naturally contaminate several grains; the constituents of usual poultry nutrition.⁽²⁾

In Egypt, many biological products are used to control mycotoxins in poultry farms, as well as feed additives⁽³⁾ and immune stimulants.^(4,5) Among the biological control of mycotoxins are T-Nil Plus® (contains *S. cerevisiae* cell wall extract) and Synertox® (contains *Bacillus subtilis* extract). These products are containing other components as enzymes, organic acids, salts and some micronutrients.⁽⁶⁾ T-Nil plus® preparation composed of neutralizing fermentation yeast extract, *Saccharomyces cerevisiae*, selected organic acids (citric acid, phosphoric acid, lactic acid, formic acid), propylenglycol, beneficial bacterial count, amino acids, selected vitamins and minerals, all of these ingredient are physically adsorbs the polar mycotoxins.⁽⁷⁾ Synertox® is a commercial product, that considered a probiotic containing some valuable compounds (enzymes, organic acids, their salts, essential micronutrients and the extract of microorganisms), micronutrients giving the product superiority over other adsorbents because the chicks continue to drink water.⁽⁶⁾

Most of the studies used Synertox® as detoxifying agent in poultry feeds and reported the ability of it to compensate and supply the suffered chicks from aflatoxin with essential nutrients.⁽⁸⁾ Probiotics are live microbial feed additives that beneficially improve the intestinal microbial balance of animal.⁽⁹⁾ A wide range of microalgae, yeasts (*Debaryomyces*, *Phaffia*, and *Saccharomyces*), gram-positive bacteria (*Bacillus*, *Carnobacterium*, *Enterococcus*, *Lactobacillus*, *Lactococcus*, *Micrococcus*, *Streptococcus*, and *Weissella*) and gram-negative bacteria (*Aeromonas*, *Alteromonas*, *Photobacterium*, *Pseudomonas* and *Vibrio*) have been applied as probiotics.⁽¹⁰⁾ Some lactic acid bacteria (*Lactobacillus johnsonii* and *Lactobacillus reuteri*) and few non-lactic acid bacteria (*Bacillus subtilis* and *Bacillus licheniformis*) were considered as probiotics.⁽¹¹⁾

Probiotics as live microbes are used to improve the microbial population in the intestine of treated animals. They are live microbial feed supplement, which

improve immune response, feed utilization, growth rate and control intestinal infections.⁽¹²⁾ Some of the prebiotics that currently used in animal feed are *Saccharomyces cerevisiae* fermentation products. An extract from the cell wall of *Saccharomyces cerevisiae* (Mannan oligosaccharide) has shown broad-spectrum efficacy against most of the mycotoxins. Prebiotics have beneficial effect on poultry during mycotoxicosis.⁽¹³⁾

Materials and methods

Ethical statement

All animal experiments were performed with the recommendations of the 'Guide for the Care and Use of Laboratory Animals' approved by the Ethics Committee of the Faculty of Veterinary Medicine, Mansoura University (No.R/129).

Feed additives

T-Nil Plus®

It was purchased from Nutriad Company, Belgium. Ingredients (per 1000 mL): Yeast cell wall (*Sacchromyces cervisiae*) 100g, citric acid 100% 60g, phosphoric acid 100% 50g, lactic acid 100% 31g, monopropylene glycol 187g, water up to a liter.

Dose: From 0.25 mL per liter according to Mahmoud⁽¹⁴⁾ to a milliliter per liter according to Moursi et al.⁽⁷⁾ for 5 days.

Synertox®

It is a blend of biological substances produced by Agrarian Marketing Corporation, USA. Ingredients (per 1000 mL): citric acid 80 mL, phosphorus acid 60 mL, malic acid 5 mL, tartaric acid 5 mL, disodium EDTA 15 mL, propylene glycol 100 mL, lactic acid 80 mL, calcium lactate 25 mL, dried *bacillus subtilis* fermentation extract 260 mL, sodium citrate 40g, papain 40g, distilled water (180 mL) up to 1000 mL.

Dose: 0.5 mL per liter were administered according to Shareef and Omar⁽⁸⁾ for 5 days.

Experimental chicks and Management

A total of 120 chicks (Cobb of 1 day old) were purchased from a poultry farm. They have an average body weight of 43.3g. They were kept in cages which were well-ventilated through natural ventilation ensuring a balanced environment and optimal conditions for the birds. During the study period, all hygienic requirements and biosecurity measures (including sanitization, disinfection, temperature and lighting programs) were followed. They were fed with a balanced ration (free from any drugs). The ingredient composition of the basal diet is based on National Research Council⁽¹⁵⁾ presented in Table 1. The ration and water were supplied *ad-libitum* throughout the experimental period.

Table 1. Ingredients and nutrient composition of basal starter and grower diet of broilers

Ingredients	Starter % (0-3 weeks)	Grower % (3-5 weeks)
Maize	46.45	54.43
Soybean meal	36.19	30.16
Full-fat soybeans	9.00	9.00
Soybean oil	1.83	1.00
Protein concentrate	0.55	0.55
Salt (NaCl)	0.40	0.40
Mono-calcium phosphate	1.86	1.69
Sunflower oil	1.83	1.00
Calcium carbonate	1.89	1.77
Total	100	100
Calculated nutrient composition		
Crude protein (%)	23.11	21.14
Metabolizable energy (kCal/kg)	3071	3045
Lysine (%)	1.39	1.39
Methionine and cysteine (%)	1.06	0.88
Calcium (%)	1.03	0.93
Available phosphorus (%)	0.50	0.46

Grouping and experimental design

Birds were divided into three equal groups each of 40 chicks on the 1st day of age. The first group (G1) received ration free from any additives and left as control. The second group (G2) chickens were given T-Nil Plus® (0.5 mL per liter for 5 days) in the drinking water from 1st day of age. The third group (G3) Chickens were administered Synertox® (0.5 mL per liter for 5 days) in the drinking water from 1st day of age.

Evaluation of growth performance

Live body weight, body weight gain, feed consumption, and FCR were calculated at the end of 1st, 2nd, 3rd, 4th, 5th weeks post-treatment.⁽¹⁶⁾

Sampling

Blood samples

Blood samples were taken from wing vein of five chickens from each group on 1st, 7th and 14th days post treatment in non-heparinized clean sterile Eppendorf tubes. Samples were centrifuged (at 3000 rpm for 5 minutes) then sera were separated and were frozen at -20 °C until assayed. The serum samples were used to measure the levels of serum AST, ALT and ALP (aspartate aminotransferase, alanine aminotransferase and alkaline phosphatase), protein profile (total protein, albumin, globulin, and A/G ratio), kidney function parameters (creatinine and uric acid), glucose, the oxidative stress markers NO and MDA and antioxidative stress parameters (reduced glutathione, superoxide dismutase and catalase), and lipid profile

(Cholesterol, triglyceride, high density lipoprotein (HDL), low density lipoprotein (LDL) and very low density lipoprotein (VLDL) were also assayed.

Tissue samples

At the end of the experiment, the second week post treatment, five birds from each group were slaughtered by a method of neck dislocation, then specimens from liver, kidneys and duodenum were collected, washed with normal saline then fixed in 10 % neutral formalin for histopathological studies.⁽¹⁷⁾

Biochemical analysis

Liver function tests

Serum aminotransferases activity, ALT and AST, were determined calorimetrically using spectrophotometer.⁽¹⁸⁾ The serum level of ALP was measured according to Walter et al.⁽¹⁹⁾

Serum Total protein

Colorimetric determination of total protein level in the serum of chickens was carried out using spectrophotometer.⁽²⁰⁾

Serum albumin level

The serum albumin levels were calorimetrically determined by PCG-method using spectrophotometer.⁽²¹⁾

Serum globulin level

Serum globulin level was calculated by subtraction of the obtained albumin level from the level of total proteins.⁽²²⁾

Albumin/Globulin (A/G) ratio

A/G ratio was determined through dividing albumin to globulin concentration.⁽²³⁾

Kidney function test

The serum levels of creatinine and uric acids were estimated calorimetrically as mentioned by Bartels et al.,⁽²⁴⁾ and Fossati et al.,⁽²⁵⁾ respectively.

Glycemic status test

Glucose level in serum was determined by GOD-PAP method without deproteinization.⁽²⁶⁾

Oxidative stress tests

NO is determined by colorimetric determination of nitrite method.⁽²⁷⁾ Lipid peroxidase (malondialdehyde) was determined by colorimetric method.⁽²⁸⁾

Antioxidative stress tests

Colorimetric determination of serum glutathione reduced (GSH) was carried out using spectrophotometer.⁽²⁹⁾ Serum levels of superoxide dismutase and catalase were estimated spectrophotometrically according to Nishikimi et al.,⁽³⁰⁾ and Aebi,⁽³¹⁾ respectively.

Lipid profile

Cholesterol, triglycerides, HDL were measured as previously recorded by Young et al.⁽³²⁾ and LDL was calculated according to Friedewald et al.⁽³³⁾ Very low density lipoprotein (VLDL) was calculated according to Rifai et al.⁽³⁴⁾

Histopathological examination

Specimens from liver, kidneys and duodenum were embedded in paraffin then sectioned at five µm thickness and stained with hematoxylin and eosin for histopathological studies.⁽³⁵⁾

Statistical analysis

Statistical package for social science (SPSS) used for statistically analyzing of the obtained data for recording the mean SE. Variance was analyzed by one-way (ANOVA) for analyzing total variation. Duncan test was used for determining significance.⁽³⁶⁾ Probability levels of less than 0.05 were considered statistical significance. Different letters were significantly different and the highest value was represented with the letter a.

Results

Effect of the tested Products on the chicken performance

The effect of administration of T-Nil Plus® and Synertox® on performance of medicated chickens was illustrated in Table 2. Chickens treated with T-Nil Plus® showed non-significant changes in body weight, meanwhile, a marked decrease ($P < 0.05$) in body weight gain, feed consumption was recorded at the end of 1st week of experiment comparing the control group with no alterations in feed conversion ratio. While Synertox® treated birds revealed a significant reduction ($P < 0.05$) in body weight and body weight gain at the end of 1st week of experiment and no alterations in feed conversion ratio.

Effect of the tested products on blood biochemical variables

The effect of T-Nil Plus® and Synertox® on liver function (ALT, AST and ALP), protein profile (TP, albumin, globulin, A/G ratio), kidney function (creatinine, uric acid), glucose, NO, MDA, GSH, superoxide dismutase, catalase, and lipid profile (cholesterol, triglycerides, HDL, LDL and VLDL) of treated chicks were recorded in Tables 3 through 8. Serum of birds treated with T-Nil Plus® evoked non-marked alterations in serum levels of ALT, AST, ALP, TP, albumin, globulin, A/G ratio, uric acid, glucose, NO, MDA, GSH, serum superoxide dismutase (SOD), catalase (CAT), cholesterol, triglycerides, HDL, LDL and VLDL of treated group at 1st day post treatment, while an increase ($P < 0.05$) in ALT, A/G ratio at 7th and 14th day after dosing and a marked reduction ($P < 0.05$) in AST, globulin levels at 7th and 14th after dosing.

Table 2. The effect of the orally administered T-Nil Plus® and Synertox® for 5 successive days on production performance variables¹ of broiler chickens (n = 10)

Items	Groups ²		
	G1	G2	G3
Initial body weight (g)	43.5 ± 0.5	43 ± 0.56	43.4 ± 0.62
1st week			
Body weight (g)	198.8 ± 2.09 ^a	191.6 ± 3.15 ^{ab}	189.1 ± 2.78 ^b
Body weight gain (g)	155.3 ± 1.6 ^a	148.6 ± 2.6 ^b	145.7 ± 2.28 ^b
Feed consumption (g)	156.45	147.83	152.16
Feed conversion ratio	1.01 ± 0.01 ^{bc}	1 ± 0.02 ^c	1.05 ± 0.02 ^{ab}
2nd week			
Body weight (g)	511 ± 8.42	494.7 ± 12.58	509.2 ± 8.18
Body weight gain (g)	312.4 ± 6.39	303.1 ± 10.1	320.1 ± 5.73
Feed consumption (g)	405.52	398.04	411.63
Feed conversion ratio	1.3 ± 0.03	1.33 ± 0.05	1.29 ± 0.02
3rd week			
Body weight (g)	1 047 ± 23.63 ^{ab}	1 041 ± 28.69 ^{ab}	1 060.5 ± 30.59 ^a
Body weight gain (g)	535.8 ± 16.34	546.3 ± 18.2	551.3 ± 22.86
Feed consumption (g)	735.35	740.31	736.1
Feed conversion ratio	1.39 ± 0.05	1.37 ± 0.04	1.36 ± 0.06
4th week			
Body weight (g)	1683 ± 53.59	1 701 ± 60.58	1 759 ± 69.84
Body weight gain (g)	636 ± 30.27	660 ± 32.72	698.5 ± 41.61
Feed consumption (g)	952.42	1 005.51	1 034.7
Feed conversion ratio	1.53 ± 0.08	1.56 ± 0.08	1.53 ± 0.09
5th week			
Body weight (g)	2 156 ± 83.49	2 227.5 ± 88.25	2 230.0 ± 89.72
Body weight gain (g)	473 ± 33.69	526.5 ± 30.91	477 ± 29.29
Feed consumption (g)	1 006.04	1 020.14	1 040.23
Feed conversion ratio	2.23 ± 0.16	2 ± 0.12	2.25 ± 0.12

¹ Mean ± standard error.

²G1: control group; G2: one-day old chickens were given T-Nil Plus® (0.5 mL/L for five days) in the drinking water; G3: one-day old chickens were administered Synertox® (0.5 mL/L for five days) in the drinking water.

^{a, b, c} Values with different superscripts in the same row are significantly different (P < 0.05).

Table 3. The effect of the orally administered T-Nil Plus® and Synertox® on serum enzyme levels¹ of one-day old broiler chickens (n = 5) across 14 days post-treatment

Groups ²	Alanine aminotransferase (U/L)			Aspartate aminotransferase (U/L)			Alkaline phosphatase (U/L)		
	Days post-treatment			Days post-treatment			Days post-treatment		
	1	7	14	1	7	14	1	7	14
G1	19.83 ± 0.87 ^b	21.00 ± 1.41 ^b	21.50 ± 1.78 ^{bc}	284.83 ± 20.99 ^a	285.83 ± 20.99 ^a	286.33 ± 21.19 ^{ab}	1 418.81 ± 3.89	1 420.51 ± 4.72	1 422.40 ± 4.80
G2	26.33 ± 3.35 ^{ab}	32.83 ± 1.51 ^a	30.50 ± 1.45 ^a	221.67 ± 23.88 ^{ab}	176.17 ± 3.19 ^c	191.33 ± 4.10 ^c	1 416.12 ± 2.94	1 423.27 ± 4.21	1 424.18 ± 4.67
G3	24.17 ± 2.60 ^{ab}	29.33 ± 1.12 ^a	21.83 ± 1.62 ^b	195.83 ± 7.46 ^b	166.83 ± 3.20	237.33 ± 27.42 ^{bc}	1 415.12 ± 2.44	1 424.64 ± 4.84	1 425.63 ± 4.50

¹ Mean ± standard error.

² G1: control group; G2: one-day old chickens were given T-Nil Plus® (0.5 mL/L for five days) in the drinking water; G3: one-day old chickens were administered Synertox® (0.5 mL/L for five days) in the drinking water.

a, b, c Values with different superscripts in the same column are significantly different (P < 0.05).

Table 4. The effect of the orally administered T-Nil Plus and Synertox® on serum protein levels¹ of one-day old broiler chickens (n = 5) across 14 days post treatment

Groups ²	Total protein (g/dL)			Albumin (g/dL)			Globulin (g/dL)			Albumin/Globulin ratio		
	Days post-treatment			Days post-treatment			Days post-treatment			Days post-treatment		
	1	7	14	1	7	14	1	7	14	1	7	14
G1	3.07 ± 0.08	3.19 ± 0.08	3.31 ± 0.14 ^a	1.59 ± 0.08 ^a	1.60 ± 0.08	1.61 ± 0.08 ^{ab}	1.47 ± 0.1	1.59 ± 0.08 ^{ab}	1.7 ± 0.07 ^a	1.15 ± 0.17	1.03 ± 0.1 ^b	0.95 ± 0.04 ^b
G2	2.82 ± 0.15	3.08 ± 0.12	2.95 ± 0.1 ^b	1.48 ± 0.08 ^a	1.73 ± 0.11	1.60 ± 0.09 ^{ab}	1.34 ± 0.17	1.35 ± 0.12 ^c	1.35 ± 0.02 ^{bc}	1.21 ± 0.18	1.37 ± 0.2 ^a	1.18 ± 0.05 ^a
G3	2.94 ± 0.14	3.07 ± 0.07	2.8 ± 0.1 ^b	1.60 ± 0.09 ^a	1.67 ± 0.03	1.53 ± 0.05 ^b	1.34 ± 0.12	1.40 ± 0.06 ^{bc}	1.26 ± 0.07 ^c	1.24 ± 0.14	1.2 ± 0.05 ^{ab}	1.23 ± 0.07 ^a

¹ Mean ± standard error.

² G1: control group; G2: one-day old chickens were given T-Nil Plus® (0.5 mL/L for five days) in the drinking water; G3: one-day old chickens were administered Synertox® (0.5 mL/L for five days) in the drinking water.

a, b, c Values with different superscripts in the same column are significantly different (P < 0.05).

Table 5. The effect of the orally administered T-Nil Plus® and Synertox® on serum creatinine and uric acid levels¹ of one-day old broiler chickens (n = 5) across 14 days post treatment

Groups ²	Creatinine (mg/dL)			Uric acid (mg/dL)		
	Days post-treatment			Days post-treatment		
	1	7	14	1	7	14
G1	0.33 ± 0.01 ^{bc}	0.34 ± 0.01 ^b	0.34 ± 0.01	6.42 ± 0.31	6.43 ± 0.28	6.45 ± 0.27
G2	0.49 ± 0.01 ^a	0.34 ± 0.00 ^b	0.33 ± 0.01	6.68 ± 0.16	6.72 ± 0.15	6.86 ± 0.24
G3	0.34 ± 0.02 ^{bc}	0.37 ± 0.01 ^a	0.33 ± 0.02	6.70 ± 0.13	6.58 ± 0.16	6.76 ± 0.17

¹ Mean ± standard error.

² G1: control group; G2: one-day old chickens were given T-Nil Plus® (0.5 mL/L for five days) in the drinking water; G3: one-day old chickens were administered Synertox® (0.5 mL/L for five days) in the drinking water.

a, b, c Values with different superscripts in the same column are significantly different (P < 0.05).

Table 6. The effect of the orally administered T-Nil Plus® and Synertox® on serum glucose levels¹ of one-day old broiler chickens (n = 5) across 14 days post treatment

Groups ²	Glucose (mg/dL)		
	Days post-treatment		
	1	7	14
G1	220.23 ± 5.47	221.17 ± 5.51 ^a	222.11 ± 5.51 ^a
G2	208.15 ± 2.75	232.06 ± 1.37 ^a	232.73 ± 1.92 ^a
G3	208.13 ± 5.60	200.39 ± 5.85 ^b	193.80 ± 7.67 ^b

¹ Mean ± standard error.

²G1: control group; G2: one-day old chickens were given T-Nil Plus® (0.5 mL/L for five days) in the drinking water; G3: one-day old chickens were administered Synertox® (0.5 mL/L for five days) in the drinking water.

^{a, b, c} Values with different superscripts in the same column are significantly different (P < 0.05).

Table 7. The effect of the orally administered T-Nil Plus® and Synertox® on serum oxidant-antioxidant variables¹ of one-day old broiler chickens (n = 5) across 14 days post treatment

Groups ²	Nitric Oxide (μmol/L)			Malondialdehyde (nmol/mL)			Reduced Glutathione (mg/dL)			Superoxide Dismutase (U/mL)			Catalase (U/mL)		
	Days post-treatment			Days post-treatment			Days post-treatment			Days post-treatment			Days post-treatment		
	1	7	14	1	7	14	1	7	14	1	7	14	1	7	14
G1	0.011 ± 0.001	0.00 ± 0.001	0.00 ± 0.001 ^a	6.29 ± 0.62 ^b	8.22 ± 0.54 ^{ab}	9.68 ± 0.86 ^{ab}	1.57 ± 0.12	2.14 ± 0.14 ^b	2.1 ± 0.26 ^{ab}	10.27 ± 0.29	10.62 ± 0.27	10.54 ± 0.26	3.51 ± 0.37	3.36 ± 0.34 ^b	3.32 ± 0.18 ^b
G2	0.01 ± 0.001	0.01 ± 0.001	0.01 ± 0.001 ^a	6.3 ± 0.69 ^b	7.54 ± 0.25 ^b	7.27 ± 0.77 ^b	1.71 ± 0.1	1.97 ± 0.04 ^{bc}	2.24 ± 0.03 ^a	10.04 ± 0.32	11.23 ± 0.34	10.43 ± 0.35	3.85 ± 0.24	3.43 ± 0.19 ^b	3.26 ± 0.20 ^b
G3	0.009 ± 0.001	0.008 ± 0.001	0.008 ± 0.001 ^{ab}	9.2 ± 0.87 ^{ab}	8.97 ± 0.47 ^a	9.6 ± 0.43 ^{ab}	1.85 ± 0.18	2.63 ± 0.19 ^a	2.11 ± 0.16 ^{ab}	10.47 ± 0.35	10.87 ± 0.38	10.94 ± 0.49	3.94 ± 0.23	4.46 ± 0.30 ^a	4.29 ± 0.19 ^a

¹ Mean ± standard error.

²G1: control group; G2: one-day old chickens were given T-Nil Plus® (0.5 mL/L for five days) in the drinking water; G3: one-day old chickens were administered Synertox® (0.5 mL/L for five days) in the drinking water.

^{a, b, c} Values with different superscripts in the same column are significantly different (P < 0.05).

Table 8. The effect of the orally administered T-Nil Plus® and Synertox® on serum lipids profile¹ of one-day old broiler chickens (n = 5) across 14 days post-treatment

Groups ²	Cholesterol (mg/dL)			Triglycerides (mg/dL)			High density lipoprotein (mg/dL)			Low density lipoprotein (mg/dL)			Very low density lipoprotein (mg/dL)		
	Days post-treatment			Days post-treatment			Days post-treatment			Days post-treatment			Days post-treatment		
	1	7	14	1	7	14	1	7	14	1	7	14	1	7	14
G1	217.3 ± 2	216.8 ± 2.2	214.7 ± 1.8	260.5 ± 1.6 ^a	258.2 ± 1.8	246.5 ± 1.7	45.3 ± 0.8	44.9 ± 0.9	41.8 ± 1.2	29.9 ± 1.3	28.6 ± 1.1	27.5 ± 1.2	12.8 ± 0.5 ^a	11.9 ± 0.5 ^a	10.9 ± 0.5 ^a
G2	214.9 ± 5.5	213.3 ± 5.3	211 ± 5.3	257.6 ± 1.7 ^a	256.9 ± 1.8	244 ± 2.3	46.08 ± 1.15	45 ± 0.8	42.5 ± 0.8	27.8 ± 1.0	26.9 ± 1.2	24.9 ± 1.6	12.4 ± 0.3 ^a	11.8 ± 0.5 ^a	11.1 ± 0.3 ^a
G3	213.4 ± 6.1	211.2 ± 5.3	210.1 ± 5.3 ^a	258.4 ± 1.6	256.9 ± 1.6	245.6 ± 1.4	46.1 ± 1.2	45.9 ± 0.7	43.3 ± 0.8	26.45 ± 1.39	25.85 ± 1.79	24.22 ± 1.88	9.39 ± 0.40 ^b	8.38 ± 0.39 ^b	6.63 ± 0.36 ^b

¹ Mean ± standard error.

²G1: control group; G2: one-day old chickens were given T-Nil Plus® (0.5 mL/L for five days) in the drinking water; G3: one-day old chickens were administered Synertox® (0.5 mL/L for five days) in the drinking water.

^{a, b, c} Values with different superscripts in the same column are significantly different (P < 0.05).

The recorded results revealed that Synertox® evoked non-marked alterations in ALT, ALP, TP, globulin and A/G ratio, creatinine, uric acid, glucose, NO, GSH, SOD, CAT, cholesterol, triglycerides, HDL and LDL at 1st day post-treatment. On the other hand, it induced a marked elevation in serum levels of and TP, globulin, A/G ratio at 7th day post-treatment, and a significant increase ($P < 0.05$) in ALT, creatinine, GSH at 7th day post-treatment, A/G ratio, SOD and CAT levels at 14th day after dosing, also it revealed a marked reduction ($P < 0.05$) in AST at 1st and 7th day post-treatment, glucose and VLDL at 7th and 14th day post-treatment, TP and globulin at 14th day post-treatment.

Histopathological findings

Liver

Microscopic pictures of hematoxylin and eosin stained hepatic sections showed normal arrangement of hepatic cords, central vein (CV), and sinusoids in control broiler group (Figure 1: A1-A2). Likewise, liver of chickens treated with T-Nil Plus® showed marked congestion (red arrow), lymphocytic follicular aggregation (yellow arrow) and small focal periportal areas of coagulative necrosis (black arrow) (Figure 1: B1-B2). Moreover, liver cobb broiler chickens treated with Synertox® showed expansion of portal areas with congested portal veins (red arrow), biliary hyperplasia (green arrow) accompanied with multifocal periportal areas of coagulative necrosis (black arrows) and fibrous tissue proliferation infiltrated with mixed leukocytes (yellow arrows) (Figure 1: C1-C2).

Kidney

Microscopic pictures of hematoxylin and eosin stained renal sections showed normal arrangement of glomeruli (G), tubules (T) and interstitial tissue in control broiler group (Figure 2: A1-A2). Likewise, kidneys of cobb broiler chickens treated with T-Nil Plus® showed lymphocytic follicular aggregation (yellow arrow), mild interstitial edema (black arrow), small shrunken glomeruli (black arrowheads), red blood cells casts (green arrows) and desquamated and separated renal epithelium (blue arrows) (Figure 2: B1-B2). Moreover, kidneys of cobb broiler chickens treated with Synertox® showed small shrunken glomeruli (black arrowheads), mild interstitial edema (black arrow), congested interstitial blood vessels (red arrows) (Figure 2: C1-C2).

Duodenum

Histopathological examination of hematoxylin and eosin stained duodenal sections obtained from control group showed normal villi and crypts (Figure 3A). Meanwhile, broiler given T-Nil plus® showed desquamated villous epithelium (blue arrows) (Figure 3B), while group on Synertox® showed fused villi (black arrow) with desquamated epithelial covering (blue arrow) (Figure 3C).

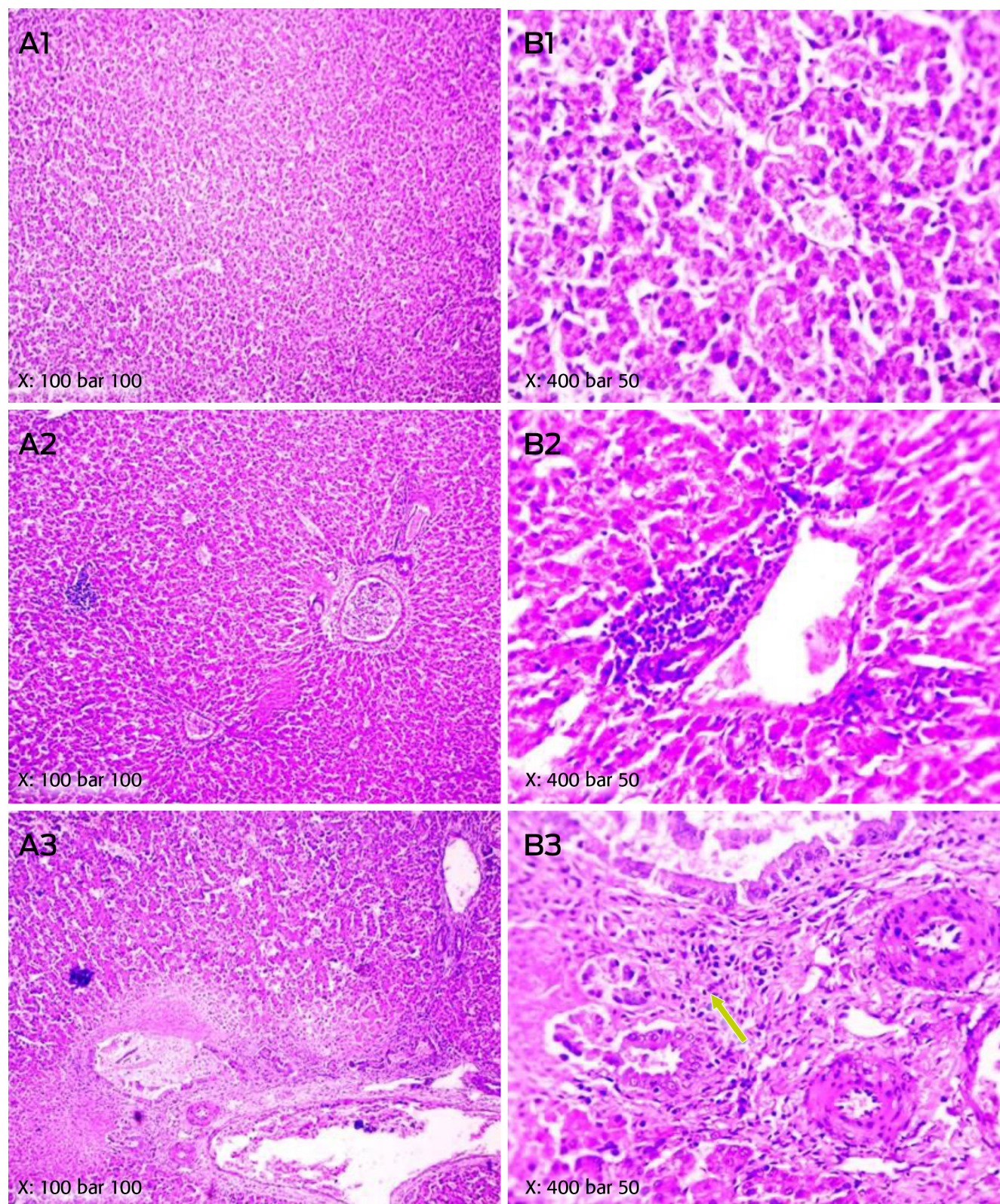


Figure 1. Microscopic pictures of hematoxylin and eosin stained hepatic sections of animals from control (A1-A2), T-Nil Plus® (B1-B2), and Synertox® groups (C1-C2).

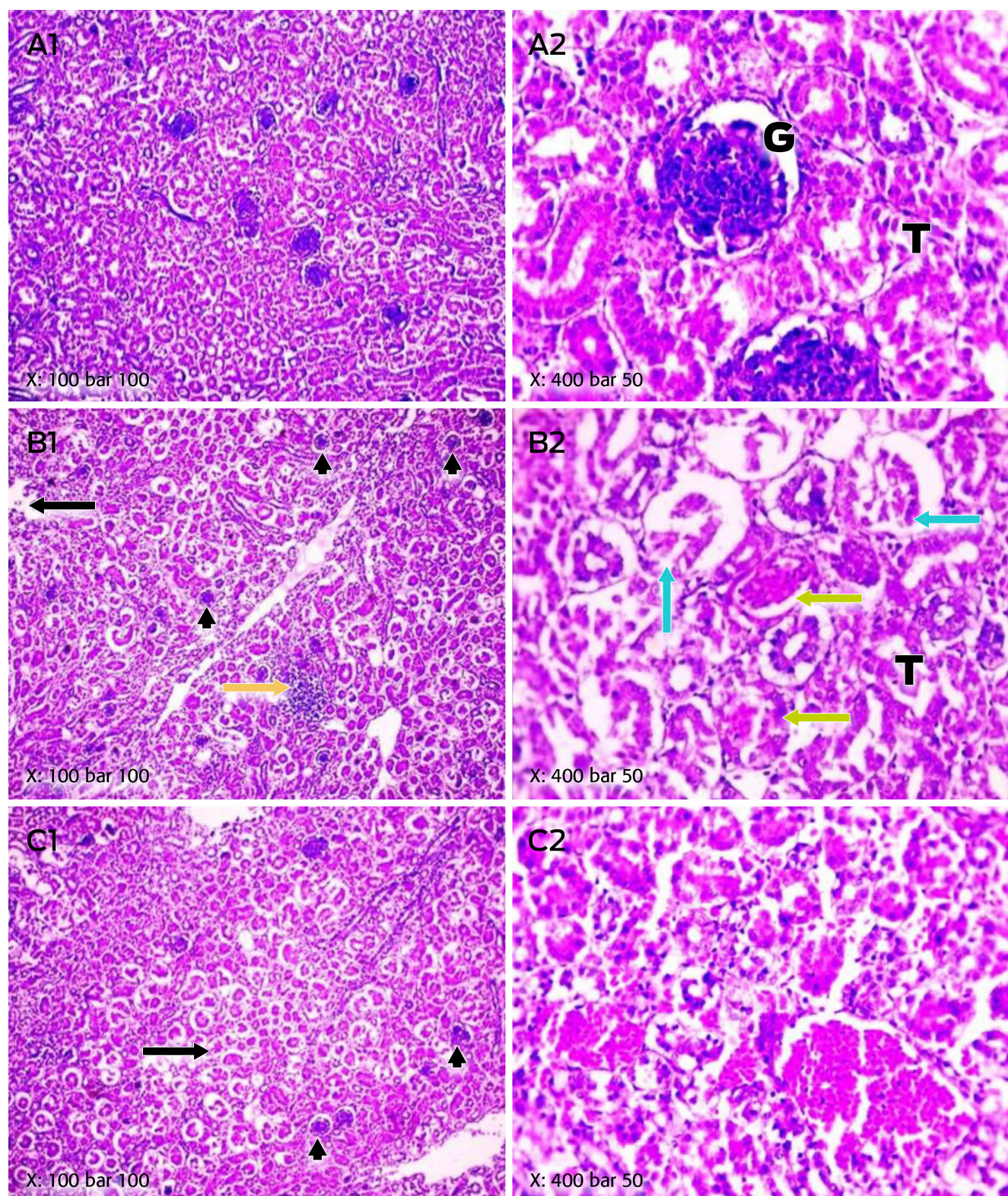


Figure 2. Microscopic pictures of hematoxylin and eosin stained renal sections of animals from the control (A1-A2), T-Nil Plus® (B1-B2), and Synertox® (C1-C2) groups. (G) glomeruli, (T) tubules.

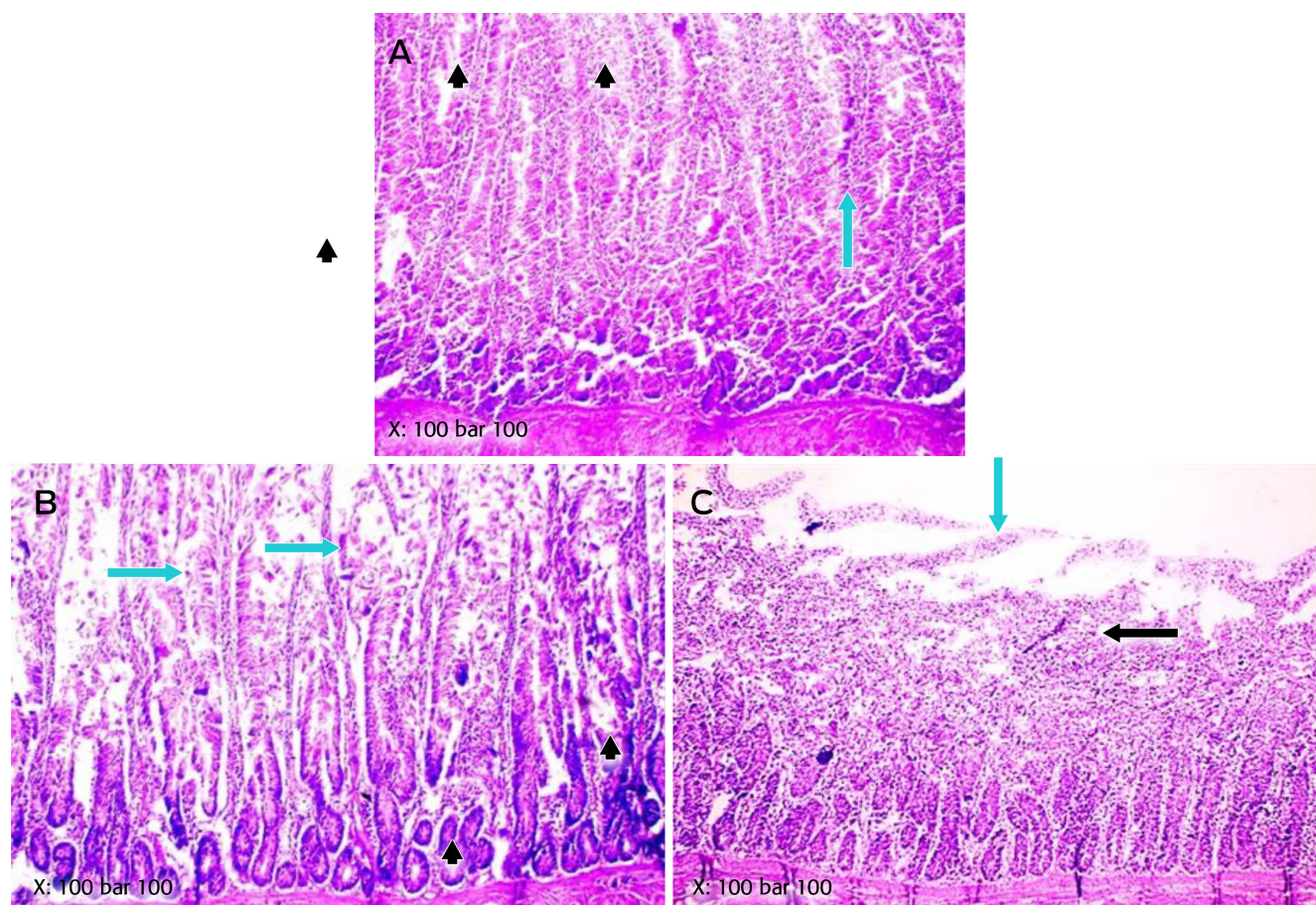


Figure 3. Microscopic pictures of hematoxylin and eosin stained duodenal sections of animals from the control (A), T-Nil Plus® (B), and Synertox® (C) groups.

Discussion

The present study was carried out to investigate the possible potentiating effect of two commercial anti-mycotoxin products, T-Nil plus® and Synertox® on chicken through evaluation of body performance, some biochemical parameters and histopathological examinations. The obtained results showed that birds treated with T-Nil Plus® revealed no marked alterations in weight of the body, body weight gain as well as FCR from 2nd week to the end of the experiment. These data are in agreement with Moursi et al.⁽⁷⁾ who reported that birds received Toxynil-plus® preparation revealed non-significant changes in chicken's performance including feed intake and body weight gain and general health condition. Similarly, Mahmoud⁽¹⁴⁾ stated that administration of T-Nil plus® (0.25 mL/L from 1–28 days old) markedly improved the body performance like body weight, and body weight gain compared with fusarium toxin received birds.

The obtained results showed that birds treated with Synertox® revealed no marked alterations in body weight and body weight gain also there were non-significant changes in feed conversion ratio FCR and higher feed consumption from 2nd week to the end of the experiment. These results are in accordance with Shareef and Omar,⁽⁸⁾ who reported that addition of Synertox® in the drinking water showed a marked elevation in feed consumption with non-significant changes in FCR com-

pared with non-treated group. Moreover, Abdelnaser et al.⁽³⁷⁾ found that the use of anti-mycotoxin product in drinking water showed non-significant difference in FCR of treated birds compared with the non-treated birds. Similarly, K mentioned that there were no marked alterations of body weight, body weight gain and FCR while there was a marked elevation in feed intake of the chickens treated with product similar to Synertox® compared with the non-treated birds. These findings might be due to the high active protease, amylase and lipase enzymes which are secreted by *Bacillus subtilis* as they induce feed decomposition and facilitate the absorption of more nutrients.⁽³⁹⁾

In addition, the obtained results showed that birds received T-Nil Plus® revealed non-significant changes in ALT and AST levels at 1st day post-treatment. These data are in the line with Moursi et al.,⁽⁷⁾ who mentioned that there was non-significant effect of T-Nil plus® on the activities of serum ALT and AST in treated chickens. While at 7th and 14th day after dosing *Saccharomyces cerevisiae* wall induced an increase in serum levels of ALT and a significant decrease in serum AST. These results are agree with these of El-Olemy⁽⁴⁰⁾ and Elkatcha et al.,⁽⁴¹⁾ who found that *Saccharomyces cerevisiae* wall caused a marked elevation in serum level of ALT and a significant decrease in serum level of AST at 7th and 14th day post-treatment. In the current study, the addition of dietary T-Nil Plus® has no side effect on ALP. These findings are in agreement with Abdalhakim et al.,⁽⁴²⁾ and SeyiDoğlu et al.⁽⁴³⁾ who found that the serum ALP activity was insignificantly changed in rabbit fed diet supplied with *Saccharomyces cerevisiae*.

The recorded results showed that birds treated with Synertox® showed non-significant alterations in serum ALT and AST activities at 1st day post-treatment. These findings are relatively similar with Sherif et al.,⁽⁴⁴⁾ who reported that fish treated with Synertox® revealed no marked alterations in ALT and AST levels compared with the control group. On the other hand, Synertox® revealed a marked elevation in the levels of serum AST and ALT at 7th day post-treatment. These data are similar to the result obtained by Ashour et al.,⁽⁴⁵⁾ who noticed that addition of Synertox® also markedly increase serum AST and ALT compared with control group. This finding was recorded by Li et al.,⁽⁴⁶⁾ and Abdel-Moneim et al.,⁽⁴⁷⁾ who reported that serum AST level were markedly increased in Japanese quails after administration of *Bacillus subtilis* spores in the diet when compared with non-treated group. The addition of Synertox® evoked non-significant changes in the serum levels of ALP in broiler chickens. These findings are in agreement with Abdel-Moneim et al.,⁽⁴⁷⁾ who reported that serum levels of ALP were not affected by dietary levels of *Bacillus subtilis*.

Moreover, chickens treated with T-Nil Plus® revealed non-significant changes in total protein, globulin and A/G ratio at 1st day post-treatment. These data are in harmony with those obtained by Moursi et al.,⁽⁷⁾ who reported that there was non-significant effect observed by T-Nil-plus® in levels of total protein, albumin, globulin and A/G ratio. The obtained results showed that birds treated with Synertox® showed non-significant alterations in serum total protein, globulin and A/G ratio at 1st and 7th day post-treatment. These findings are in the line with Sherif et al.,⁽⁴⁴⁾ who mentioned that fish treated with Synertox® showed no marked alterations in total protein, albumin and globulin compared with group was fed with low level of AFB1.

In addition, the obtained results showed that chickens treated with T-Nil Plus® induced a marked elevation in serum creatinine level. These results are relatively similar to Czech et al.,⁽⁴⁸⁾ who clarified that addition of *Saccharomyces cerevisiae*, the main active principle of T-Nil Plus®, increased levels of creatinine. Administration of T-Nil Plus® not alters the level of serum uric acid in broiler chicken. These results are in accordance with Mahmoud⁽¹⁴⁾; Al-Afifi et al.,⁽⁴⁹⁾ and Hasan et al.⁽⁵⁰⁾ who said that administration of *Saccharomyces cerevisiae* will not change the serum level of uric acid in chickens. Our results showed that birds treated with Synertox® revealed non-significant changes of serum creatinine level at 1st day post-treatment. These data are in harmony with Sherif et al.,⁽⁴⁴⁾ who reported that fish treated with Synertox® showed non-significant changes in serum creatinine compared with group fed with low level of AFB1. On the other hand, Synertox® showed a marked elevation of serum creatinine at 7th and 14th day post-treatment. This finding was recorded by Ashour et al.,⁽⁴⁵⁾ who found that administration of Synertox® to rabbit was markedly increase serum creatinine level comparing with control group. While administration of Synertox® not alters the serum level of uric acid of treated group. This finding is supported by Abdel-Moneim et al.,⁽⁴⁷⁾ who reported that no significant changes in serum level of uric acid treated with *Bacillus subtilis* to the diet of quails.

The recorded results showed that chickens treated with T-Nil Plus® revealed non-significant changes in serum glucose level. These data are similar to the result obtained by Czech et al.,⁽⁴⁸⁾ who mentioned that a non-significant change in the plasma content of glucose in turkeys received *Saccharomyces cerevisiae*. The recorded data showed that birds treated with Synertox® revealed non-significant alterations in serum glucose level at 1st day post-treatment. This result was in harmony with Mahmoudzadeh et al.,⁽⁵¹⁾ who reported that high dose of *Bacillus subtilis* in fish diet was not significantly altered the serum glucose level. On the other hand, our results showed that birds treated with Synertox® revealed a marked reduction in serum glucose level at 7th and 14th day post treatment. These results are in the line with Abdel-Moneim et al.⁽⁴⁷⁾ who stated that serum glucose level were markedly decreased in Japanese quail birds after addition of *Bacillus subtilis* spores in the diet.

The recorded data showed that chickens treated with T-Nil-Plus® revealed non-significant change in serum nitric oxide level at 1st, 7th and 14th day after dosing. These findings are relatively similar to Awaad et al.,⁽⁵²⁾ who found that the use of mannan-oligosaccharides with β -glucans (extracted from the cell wall of a specific strain of *Saccharomyces cerevisiae*) induced non-significant change in serum nitric oxide in broiler. Our results revealed that birds treated with Synertox® showed non-significant changes in serum nitric oxide level at 1st, 7th day after treatment. Meanwhile, there was a marked reduction in serum nitric oxide level at 14th day post-treatment. This finding was recorded by Lee et al.⁽⁵³⁾ who reported that using some *Bacillus subtilis* strains revealed a marked reduction in serum nitric oxide level. The obtained data showed that chickens treated with T-Nil Plus® from revealed non-significant changes in serum MDA level at 1st, 7th and 14th day post dosing. These results are in the line with Deters et al.⁽⁵⁴⁾ who mentioned that plasma MDA concentrations remained relatively constant in newly weaned beef steers after receiving diet containing *Saccharomyces cerevisiae* fermentation product.

The recorded data showed that birds treated with Synertox® showed non-significant changes in serum MDA level at 1st, 7th and 14th day post-treatment. These findings are in harmony with Fan et al.,⁽⁵⁵⁾ who reported that supplementation of *Bacillus subtilis* to broilers showed non-significant changes on serum MDA when compared with control group. Our results showed that chickens treated with T-Nil Plus® revealed non-significant changes in serum GSH level at 1st, 7th and 14th day post-treatment. These data are in accordance with the result obtained by Rageb et al.,⁽⁵⁶⁾ who reported that non-significant alterations of GSH level in Ross broiler chickens administered mannan-oligosaccharide and β -glucan prebiotic. Our results showed that chickens treated with Synertox® showed a marked elevation in serum GSH level at 1st day and 7th day post-treatment. These findings are in harmony with Zhang et al.,⁽⁵⁷⁾ who reported that the effects of *Bacillus subtilis* in the diet of broilers showed a significant increase of serum GSH when compared with control group. Similarly, Bai et al.⁽⁵⁸⁾ stated that the serum glutathione (GSH) were increased significantly by adding *Bacillus subtilis* into the broiler diets comparing with control group.

Also Abdel-Moneim et al.,⁽⁴⁷⁾ reported that serum GSH level were significantly increased in Japanese quail birds after administration of *Bacillus subtilis* spores in the diet when compared with control group. T-Nil Plus® not alters the SOD and CAT levels of treated chicks at 1 and 14 days post-treatment. These results are in harmony with those recorded by Abdalhakim et al.⁽⁴²⁾ who reported that SOD and CAT activities were insignificantly changed post treatment with *Saccharomyces cerevisiae* in rabbits. In the same line Abdalla et al.⁽⁵⁹⁾ stated that the serum levels of SOD and CAT was not altered post treatment with *Saccharomyces cerevisiae* in calves. The obtained result showed that chickens treated with Synertox® showed a significant increase in serum SOD and CAT at 7 and 14 days after dosing. These results was in accordance with Zhang et al.,⁽⁵⁷⁾ who reported that there are a significant increase in the levels of serum SOD and CAT of broiler chicken after dietary supplementation of *Bacillus subtilis* comparing with control group. Similarly, Chen et al.⁽⁶⁰⁾ found that *Bacillus subtilis* increased the activities of SOD and CAT which had a positive response on antioxidant activity in serum of chickens. These findings revealed that probiotic bacteria enhance anti-oxidant defense mechanism of poultry. This effect might be due to the potency of probiotic bacteria to induce chelate free radicals, capturing reactive oxygen species and inhibiting their cytotoxic activity Lin and Yen,⁽⁶¹⁾ or due to the components that Synertox® contains, that help in protein digestion.⁽⁸⁾

The recorded data showed that chickens given T-Nil Plus® evoked non-marked alterations in serum levels of cholesterol, triglycerides, HDL and LDL. These results are in accordance with Zamanizadeh et al.⁽⁶²⁾; Jazi et al.,⁽⁶³⁾ and Sohail et al.,⁽⁶⁴⁾ who reported that serum levels of cholesterol, triglycerides, HDL and LDL were not affected by *Saccharomyces cerevisiae* supplementation. Similar results were recorded by He et al.,⁽⁶⁵⁾ who reported that there are no-marked alterations in serum levels of cholesterol, triglycerides and LDL at day 21 in broiler chickens supplemented with *Saccharomyces cerevisiae* also, administration of *Saccharomyces cerevisiae* wall not alter serum levels of VLDL of broilers. This finding was supported by Elkatcha et al.,⁽⁴¹⁾ who reported that there is no significant changes were observed in serum VLDL of broiler chickens supplemented with *Saccharomyces cerevisiae*. Also, similar results were observed by El-Mahmoudy et al.⁽⁶⁶⁾

administration of *Saccharomyces cerevisiae* wall not alter serum cholesterol, triglycerides, HDL, LDL and VLDL in rats.

The current study showed that chickens given Synertox® exerted non-marked alterations in serum levels of cholesterol, triglycerides. These findings were noted by Devyatkin et al.⁽⁶⁷⁾; Mohebbifar et al.⁽⁶⁸⁾ and Santoso et al.⁽⁶⁹⁾ who observed that no significant impact of a probiotic supplement on the level of cholesterol, triglycerides in chicken blood also chickens given *Bacillus subtilis* extract exerted non-marked alterations in serum levels of HDL and LDL. This result is reported by Al-Baadani et al.⁽⁷⁰⁾ who observed that no significant impact of *Bacillus subtilis* supplement on the level of HDL, LDL and triglycerides of treated broilers. On the other hand, administration of *Bacillus subtilis* extract evoked a significant decrease in serum level of VLDL of treated broilers. Similar results were observed by Abdel-Moneim et al.⁽⁴⁷⁾ and Aliakbarpour et al.⁽⁷¹⁾ who reported that there is a significant decrease in in serum level of VLDL of broilers supplemented with *Bacillus subtilis* to the diet.

Microscopic examination of hepatic sections from broiler group after receiving T-Nil plus® showed lymphocytic follicular aggregation, leukocytic cell infiltration comparing with control group. These results are in accordance with Abd El Tawab et al.⁽⁷²⁾ who reported that liver treated with probiotic and prebiotic showed leukocytic cell infiltration in the fibrous connective tissue of the portal area and in hepatic parenchyma. Hepatic sections from broiler group after receiving Synertox® showed fibrous tissue proliferation infiltrated with mixed leukocytes and few leukocytic cells infiltration around central vein. These findings were in the line with kilany et al.⁽³⁸⁾ who reported that liver treated with product similar to Synertox® showed portal and interstitial leukocytic aggregation in hepatic cells.

Renal sections from broiler group after receiving Synertox® showed congested interstitial blood vessels and mild interstitial edema. These results were relatively similar to those of kilany et al.⁽³⁸⁾ who reported that kidney treated with product similar to Synertox® showed acute cell swelling of renal tubules and congestion. Duodenal sections from broiler treated groups (G2, G3) showed desquamated villous epithelium due to the increase in lymphocyte populations due to the anti-inflammatory role of the tested agents in the duodenum, these results were in accordance with those of Awadin et al.⁽⁷³⁾

Conclusions

Synertox® induced a powerful effect comparing to T-Nil Plus®, as it induces a good feed conversion ratio and increases the response of the birds against oxidative stress.

Data availability

All relevant data are within the manuscript and its supporting information files.

Acknowledgments

The researchers are very grateful for the faculty of veterinary medicine, Mansoura University, Egypt to provide the suit place to achieve this study.

Funding statement

All authors were paid for this publication, there was not any external funding.

Conflicts of interest

The authors have no conflict of interest to declare in regard to this publication

Author contributions

Conceptualization: Magdy S. Amer & Reham A. El-Shafei

Data curation: Iman S. El-Tokhey

Formal analysis: Iman S. El-Tokhey

Funding acquisition: All Authors

Methodology: Iman S. El-Tokhey, Nani Nasreldin

Software: Iman S. El-Tokhey , Reham A. El-Shafei

Supervision: Magdy S. Amer & Reham A. El-Shafei& Rasha A. Eltaysh

Validation: Magdy S. Amer & Reham A. El-Shafei& Rasha A. Eltaysh

Visualization: Magdy S. Amer & Reham A. El-Shafei& Rasha A. Eltaysh

Writing-original draft: Iman S. El-Tokhey& Reham A. El-Shafei

Writing-review and editing: Iman S. El-Tokhey & Magdy S. Amer & Reham A. El-Shafei

References

1. Umay R. Application of *Moringa oleifera* in poultry: a review. World Journal of Pharmaceutical Research. 2014;3(2):1955-60.
2. van Egmond H, Schothorst R, Jonker M. Regulations relating to mycotoxins in food: perspectives in a global and European context. Analytical and Bioanalytical Chemistry. 2007;389(1):147-57. doi: 10.1007/s00216-007-1317-9.
3. El-Shafei RA, Saleh RM. Pharmacological effects of vitamin C & E on diclofenac sodium intoxicated rats. Biomedicine & Pharmacotherapy. 2016;84:314-22. doi: 10.1016/j.biopha.2016.09.005.
4. EladL AH, Mosad SM, El-Shafei RA, Saleh RM, Ali HS, Badawy BM, et al. Immunostimulant effect of a mixed herbal extract on infectious bursal disease virus (IBDV) vaccinated chickens in the context of a co-infection model of avian influenza virus H9N2 and IBDV. Comparative Immunology, Microbiology and Infectious Diseases. 2020;72:101505. doi: 10.1016/j.cimid.2020.101505.
5. Farag VM, El-Shafei RA, Elkenany RM, Ali HS, EladL AH. Antimicrobial, immunological and biochemical effects of florfenicol and garlic (*Allium sativum*) on rabbits infected with *Escherichia coli* serotype O55: H7. Veterinary Research Communications. 2021:1-14. doi: 10.1007/s11259-021-09859-3
6. Amer M, El-Bayomi K, Zeinab M. Field studies on effect of probiotic on reproductivity of 51 weeks old broiler breeder chickens fed on mycotoxins contaminated ration. The Journal of American Science. 2011;7(4):840-4.

7. Moursi MK, Gharieb EG, el-Genaidy HM. Pathological and immunological studies on dietary T-2 toxin with concurrent *E. coli* infection in chickens and some relevant control trial. Suez Canal Veterinary Medicine Journal. 2008;13(2):565-600.
8. Shareef A, Omar E. Effect of synertox® on broiler health and performance during aflatoxicosis. Iraqi Journal of Veterinary Sciences. 2012;26:27-34. doi: 10.33899/ijvs.2020.167132.
9. Elshagabee FMF, Rokana N, Gulhane RD, Sharma C, Panwar H. *Bacillus* as potential probiotics: status, concerns, and future perspectives. Frontiers in Microbiology. 2017;8:1490. doi: 10.3389/fmicb.2017.01490.
10. Chiu C-H, Cheng C-H, Gua W-R, Guu Y-K, Cheng W. Dietary administration of the probiotic, *Saccharomyces cerevisiae* P13, enhanced the growth, innate immune responses, and disease resistance of the grouper, *Epinephelus coioides*. Fish & Shellfish Immunology. 2010;29(6):1053-9. doi: 10.1016/j.fsi.2010.08.019.
11. Holzapfel WH, Haberer P, Geisen R, Björkroth J, Schillinger U. Taxonomy and important features of probiotic microorganisms in food and nutrition. The American Journal of Clinical Nutrition. 2001;73(2):365s-73s. doi: 10.1093/ajcn/73.2.365s.
12. Abu El-Ela, W., Abou.Elazm, K., Awad, S. Efficacy of Ginger and Nutritox® in counteracting aflatoxin effects on white Pekin ducklings. Mansoura Veterinary Medical Journal. 2019;20(4):21-8. doi: 10.21608/mvmj.2019.20.404.
13. Raju M, Reddy M. Prevention and control of mycotoxins in poultry diets. Poultry Seminar. Hyderabad: 9th March, 2000:61-81.
14. Mahmoud EA. Clinicopathological studies on the effect of fusarium mycotoxin on hematological and biochemical parameters in broiler chickens. Global Veterinaria. 2014;12:885-90. doi: 10.5829/idosi.gv.2014.12.06.96193.
15. National Research Council. Nutrient Requirement of Poultry. 9th edition. Washington DC, USA: National Academy Press; 1994.
16. Wagner DD, Furrow RD, Bradley BD. Subchronic toxicity of monensin in broiler chickens. Veterinary Pathology. 1983;20(3):353-9. doi: 10.1177/030098588302000311.
17. Arafat N, Abd El Rahman S, Naguib D, El-Shafei RA, Abdo W, EladL AH. Co-infection of *Salmonella enteritidis* with H9N2 avian influenza virus in chickens. Avian Pathology. 2020;49(5):496-506. doi: 10.1080/03079457.2020.1778162.
18. Schumann G, Klauke R. New IFCC reference procedures for the determination of catalytic activity concentrations of five enzymes in serum: preliminary upper reference limits obtained in hospitalized subjects. Clinica Chimica Acta. 2003;327(1-2):69-79. doi: 10.1016/s0009-8981(02)00341-8.
19. Walter K, Schütt C. Alkaline phosphatase in serum. Methods of Enzymatic Analysis. 1974:860-4. doi: 10.1016/b978-0-12-091302-2.50068-2.
20. Tietz NW. Tietz Clinical guide to laboratory tests. 4th edition. Philadelphia, USA: Saunders; 2006.
21. Doumas BT, Ard Watson W, Biggs HG. Albumin standards and the measurement of serum albumin with bromocresol green. Clinica Chimica Acta. 1971;31(1):87-96. doi: 10.1016/0009-8981(71)90365-2.
22. Doumas B, Biggs H. Determination of serum albumin in standard method of clinical chemistry. In: Standard Methods of Clinical Chemistry Cooper GR, editor. New York: Academic Press; 1972.

23. Kaneko JJ, Harvey JW, Bruss ML, Bruss M. Clinical biochemistry of domestic animals: Academic Press. 5th edition. California, USA: 1997.
24. Bartels H, Bohmer M. Microestimation of creatinine. *Clinica Chimica Acta*. 1971;32:81-5. doi: 10.1016/0009-8981(71)90467-0.
25. Fossati P, Prencipe L, Berti G. Use of 3,5-dichloro-2-hydroxybenzenesulfonic acid/4-aminophenazone chromogenic system in direct enzymic assay of uric acid in serum and urine. *Clinical Chemistry*. 1980;26(2):227-31. doi: 10.1093/clinchem/26.2.0227.
26. Teuscher A, Richterich P. New Swiss guidelines for the diagnosis of diabetes mellitus. *Schweiz Med Wochenschr*. 1971;101(11):390-8 concl. German. PMID: 5558552.
27. Montgomery H, Dymock J. The determination of nitrite in water. *The Analyst*. 1961;86:414-6.
28. Kei S. Serum lipid peroxide in cerebrovascular disorders determined by a new colorimetric method. *Clinica Chimica Acta*. 1978;90(1):37-43. doi: 10.1016/0009-8981(78)90081-5.
29. Beutler E. Improved method for the determination of blood glutathione. *Journal of Laboratory and Clinical Medicine*. 1963;61:882-8.
30. Nishikimi M, Appaji Rao N, Yagi K. The occurrence of superoxide anion in the reaction of reduced phenazine methosulfate and molecular oxygen. *Biochemical and Biophysical Research Communications*. 1972;46(2):849-54. doi: 10.1016/s0006-291x(72)80218-3.
31. Aebi H. *Methods in enzymatic analysis*. New York: Academic Press; 1984.
32. Young DS, Friedman RB. *Effects of disease on clinical laboratory tests*. Washington DC, USA: American Association for Clinical Chemistry; 2001.
33. Friedewald WT, Levy RI, Fredrickson DS. Estimation of the concentration of low-density lipoprotein cholesterol in plasma, without use of the preparative ultracentrifuge. *Clinical Chemistry*. 1972;18(6):499-502. doi: 10.1093/clinchem/18.6.499.
34. Rifai N, Warnick GR, McNamara JR, Belcher JD, Grinstead GF, Frantz ID. Measurement of low-density-lipoprotein cholesterol in serum: a status report. *Clinical Chemistry*. 1992;38(1):150-60. doi: 10.1093/clinchem/38.1.150.
35. Bancroft JD, Stevens A. *Theory and Practice of Histological Techniques*. 3rd edition. Edinburgh, UK: Churchill Livingstone; 1990. 740 p.
36. Duncan DB. Multiple range and multiple F tests. *Biometrics*. 1955;11(1):1. doi: 10.2307/3001478.
37. Abdelnaser A, Zyan K, El Basuni S, El Nabarawy A. Efficacy of different antimycotoxicosis compounds on the main immune organs and humoral immune response of broiler chickens fed on aflatoxin and/or ochratoxin contaminated diet. *Benha Veterinary Medical Journal*. 2017;33(2):430-46. doi: 10.21608/bvmj.2017.30591.
38. Kilany O, Helmi R, Fares I, Mahmoud M. Effects of chemical and biological anti-mycotoxins on performance, haematological, biochemical and immunological parameters of broiler chickens during aflatoxicosis. *Egyptian Academic Journal of Biological Sciences, F. Toxicology and Pest Control*. 2020;12(1):141-62. doi: 10.21608/eajbsf.2020.84488.

39. Li W, Bai J, Li Y, Qin Y, Yu D. Effects of *Bacillus subtilis* on meat quality, nutrient digestibility and serum biochemical parameters of broilers. Chinese Journal of Veterinary Science. 2014;34(10):1682-5.
40. El-Olemy KA. The Potential effect of feeding naturally mycotoxins-contaminated and antimycotoxin-treated rations in broiler chicks; clinicopathological and immunological assessment. Egyptain Journal of Comparative Pathology and Clinical Pathology. 2016;29(1):199-209.
41. Elkatcha M, Soltan M, ElShobokshy S, Shokry A. Protective effect of chemical and biological mycotoxin binder on growth performance, serum biochemistry and carcass traits in broiler chicks fed on aflatoxin contaminated diet. Alexandria Journal of Veterinary Sciences. 2017;55(1):180. doi: 10.5455/ajvs.269041.
42. Abdalhakim S, Abdelhamid F, Hamed M, Abdalla O. The effect of dietary supplementation with *Saccharomyces cerevisiae* on growth performance, some selective hematological, biochemical and antioxidant parameters in new zealand white rabbits. Mansoura Veterinary Medical Journal. 2018;19(1):383-99. doi: 10.21608/mvmj.2018.187684.
43. SeyiDoğlu N, Galip N. Effects of *Saccharomyces cerevisiae* and *Spirulina platensis* on growth performances and biochemical parameters in rabbits. Kafkas Universitesi Veteriner Fakultesi Dergisi. 2014;20:331-6. doi: 10.9775/kvfd.2013.9988.
44. Sherif AH, Abdel-Maksoud SA, Shukry MM. Study on toxicity of *Oreochromis niloticus* with aflatoxinb1. Egyptian Journal of Aquatic Biology and Fisheries. 2013;17(3):107-19. doi: 10.12816/0011065.
45. Ashour G, Sedki A, Abdel-Rahman S, El kholy K. Physiological responses of rabbit does to Synertox® supplementation under different housing conditions during summer in Egypt. Egyptian Journal of Rabbit Science. 2017;27(2):377-97. doi: 10.21608/ejrs.2017.46661.
46. Li A, Wang Y, Li Z, Qamar H, Mehmood K, Zhang L, et al. Probiotics isolated from yaks improves the growth performance, antioxidant activity, and cytokines related to immunity and inflammation in mice. Microbial Cell Factories. 2019;18(1):112-. doi: 10.1186/s12934-019-1161-6.
47. Abdel-Moneim A-ME, Selim DA, Basuony HA, Sabic EM, Saleh AA, Ebeid TA. Effect of dietary supplementation of *Bacillus subtilis* spores on growth performance, oxidative status, and digestive enzyme activities in Japanese quail birds. Tropical animal health and production. 2020;52(2):671-80. doi: 10.1007/s11250-019-02055-1.
48. Czech A, Merska-Kazanowska M, Całyniuk Z. Redox Status, Biochemical parameters and mineral elements content in blood of turkey hens fed a diet supplemented with *Yarrowia lipolytica* yeast and two *Bacillus* species. Animals (Basel). 2020;10(3):459. doi: 10.3390/ani10030459.
49. Al-Afifi SH, Manal I, Bayomi ASA. Biochemical effects of *Saccharomyces cerevisiae* (biological product) and Hydrated Sodium Calcium Alimono-Silicate" HSCAS"(chemical compound) as anti-aflatoxin in chicken rations. Animal Health Research Journal. 2018;6(1):19-38.
50. Hasan M, Youssef F, Elakhras R. Evaluation of some treatments for coliform infection in chicken. Egyptian Academic Journal of Biological Sciences, B Zoology. 2020;12(1):127-38. doi: 10.21608/eajbsz.2020.105147.

51. Mahmoudzadeh L, Meshkini S, Tukmehchi A, Motalebi Moghanjoghi A, Mahmoudzadeh M. Effects of dietary *Bacillus subtilis* on growth performance and immune responses, in rainbow trout, *Oncorhynchus mykiss* (Walbaum, 1792). Iranian Journal of Fisheries Sciences. 2016;15(1):347-59.
52. Awaad M, Atta A, Abd El-Ghany WA, Elmenawey M, Ahmed K, Hassan A, et al. Effect of a specific combination of mannan-oligosaccharides and β -glucans extracted from yeast cell wall on the health status and growth performance of ochratoxicated broiler chickens. Journal of American Science. 2011;7(3):82-96.
53. Lee K-W, Lillehoj HS, Jang SI, Li G, Lee S-H, Lillehoj EP, et al. Effect of *Bacillus*-based direct-fed microbials on *Eimeria maxima* infection in broiler chickens. Comparative Immunology, Microbiology and Infectious Diseases. 2010;33(6):e105-e110. doi: 10.1016/j.cimid.2010.06.001.
54. Deters EL, Stokes RS, Genther-Schroeder ON, Hansen SL. Effects of a *Saccharomyces cerevisiae* fermentation product in receiving diets of newly weaned beef steers. I. Growth performance and antioxidant defense. Journal of Animal Science. 2018;96(9):3897-905. doi: 10.1093/jas/sky246.
55. Fan Y, Zhao L, Ji C, Li X, Jia R, Xi L, et al. Protective effects of *Bacillus subtilis* ANSB060 on serum biochemistry, histopathological changes and antioxidant enzyme activities of broilers fed moldy peanut meal naturally contaminated with aflatoxins. Toxins (Basel). 2015;7(8):3330-43. doi: 10.3390/toxins7083330.
56. Rageb S, Abd-Allah E, Abou Khalil N, Abdel-Maksoud F, Mahmoud U. Effects of mannan-oligosaccharide and β -glucan prebiotic on the brain oxidant/antioxidant balance in broilers under natural Egyptian summer conditions. Egyptian Academic Journal of Biological Sciences, B Zoology. 2018;10(1):35-46. doi: 10.21608/eajbsz.2018.13428.
57. Zhang L, Bai K, Zhang J, Xu W, Huang Q, Wang T. Dietary effects of *Bacillus subtilis* fmbj on the antioxidant capacity of broilers at an early age. Poultry Science. 2017;96(10):3564-73. doi: 10.3382/ps/pex172.
58. Bai K, Huang Q, Zhang J, He J, Zhang L, Wang T. Supplemental effects of probiotic *Bacillus subtilis* fmbj on growth performance, antioxidant capacity, and meat quality of broiler chickens. Poultry Science. 2017;96(1):74-82. doi: 10.3382/ps/pew246.
59. Abdalla OA, El-Boshy ME, Hamid FMA, Ali NM. Clinicopathological studies of dietary supplementation of *Saccharomyces cerevisiae* in calves. Journal of American Science. 2013;9(9):298-306.
60. Chen JF, Kuang YH, Qu XY, Guo SC, Kang KL, He CQ. The effects and combinational effects of *Bacillus subtilis* and montmorillonite supplementation on performance, egg quality, oxidation status, and immune response in laying hens. Livestock Science. 2019;227:114-9. doi: 10.1016/j.livsci.2019.07.005.
61. Lin M-Y, Yen C-L. Antioxidative ability of lactic acid bacteria. Journal of Agricultural and Food Chemistry. 1999;47(4):1460-6. doi: 10.1021/jf981149l.
62. Zamanizadeh A, Mirakzei MT, Agah MJ, Saleh H, Baranzehi T. A comparison of two probiotics *Aspergillus oryzae* and *Saccharomyces cerevisiae* on productive performance, egg quality, small intestinal morphology, and gene expression in laying Japanese quail. Italian Journal of Animal Science. 2021;20(1):232-42. doi: 10.1080/1828051x.2021.1878944.
63. Jazi V, Ashayerizadeh A, Toghyani M, Shabani A, Tellez G, Toghyani M. Fermented soybean meal exhibits probiotic properties when included in Japanese quail

- diet in replacement of soybean meal. Poultry Science. 2018;97(6):2113-22. doi: 10.3382/ps/pey071.
64. Sohail MU, Rahman ZU, Ijaz A, Yousaf MS, Ashraf K, Yaqub T, et al. Single or combined effects of mannan-oligosaccharides and probiotic supplements on the total oxidants, total antioxidants, enzymatic antioxidants, liver enzymes, and serum trace minerals in cyclic heat-stressed broilers. Poultry Science. 2011;90(11):2573-7. doi: 10.3382/ps.2011-01502.
 65. He T, Mahfuz S, Piao X, Wu D, Wang W, Yan H, et al. Effects of live yeast (*Saccharomyces cerevisiae*) as a substitute to antibiotic on growth performance, immune function, serum biochemical parameters and intestinal morphology of broilers. Journal of Applied Animal Research. 2021;49(1):15-22. doi: 10.1080/09712119.2021.1876705.
 66. El-Mahmoudy A, Elgerwi A. Safety profile after long-term administration of sildenafil to hyperlipidemic albino rats. Journal of Pharmacological and Toxicological Methods. 2014;70(3):321. doi: 10.1016/j.vascn.2014.03.044.
 67. Devyatkin V, Mishurov A, Kolodina E. Probiotic effect of *Bacillus subtilis* B-2998D, B-3057D, and *Bacillus licheniformis* B-2999D complex on sheep and lambs. Journal of Advanced Veterinary Animal Research. 2021;8(1):146-57. doi: 10.5455/javar.2021.h497.
 68. Mohebbifar A, Kashani S, Afsari M, Torki M. Effects of commercial prebiotic and probiotics of diet on performance of laying hens, egg traits and some blood parameters. Annual Research & Review in Biology. 2013;3:921-34.
 69. Santoso U, Tanaka K, Ohtani S, Sakaida M. Effect of fermented product from *Bacillus subtilis* on feed conversion efficiency, lipid accumulation and ammonia production in broiler chicks. Asian-Australasian Journal of Animal Sciences. 2001;14(3):333-7. doi: 10.5713/ajas.2001.333.
 70. Al-Baadani HH, Abudabos AM, Al-Mufarrej SI, Al-Baadani AA, Alhidary IA. Dietary supplementation of *Bacillus subtilis*, *Saccharomyces cerevisiae* and their symbiotic effect on serum biochemical parameters in broilers challenged with *Clostridium perfringens*. Journal of Applied Animal Research. 2018;46(1):1064-72. doi: 10.1080/09712119.2018.1454325.
 71. Aliakbarpour HR, Chamani M, Rahimi G, Sadeghi AA, Qujeq D. Intermittent feeding programme and addition of *Bacillus subtilis* based probiotics to the diet of growing broiler chickens: Influence on growth, hepatic enzymes and serum lipid metabolites profile. Archives Animal Breeding. 2013;56(1):410-22. doi: 10.7482/0003-9438-56-040.
 72. Abd El Tawab A, Amar A, Elshorbagy M, Mostafa E. Impact of probiotic and prebiotic on the lysozyme response of broilers against clostridial infection. Benha Veterinary Medical Journal. 2015;28(2):208-13. doi: 10.21608/bvmj.2015.32504.
 73. Awadin WF, Eladl AH, El-Shafei RA, Mohamed A, Aziza AE, Ali HS, et al. Effect of omega-3 rich diet on the response of Japanese quails (*Coturnix coturnix japonica*) infected with Newcastle disease virus or avian influenza virus H9N2. Comparative Biochemistry and Physiology Part C: Toxicology & Pharmacology. 2020;228:108668. doi: 10.1016/j.cbpc.2019.108668.