

## Evaluation of the presence of avian influenza receptors in oviducts of forced moulting birds using immunofluorescence

**Elizabeth Castillo-Villanueva**<sup>1</sup>

0000-0001-8161-5565

**Félix Sánchez-Godoy**<sup>2</sup>

0000-0002-8764-5762

**Magdalena Escorcía**<sup>2\*</sup>

0000-0002-3936-4907

<sup>1</sup> Departamento de Microbiología y Parasitología,  
 Laboratorio de Virología, Facultad de Medicina,  
 Universidad Nacional Autónoma de México,  
 Av. Ciudad Universitaria, No. 3000,  
 Col. Ciudad Universitaria, Delegación Coyoacán,  
 Cd. de México, 04510.

<sup>2</sup> Departamento de Medicina y Zootecnia de Aves,  
 Facultad de Medicina Veterinaria y Zootecnia,  
 Universidad Nacional Autónoma de México,  
 Av. Ciudad Universitaria, No. 3000,  
 Col. Ciudad Universitaria, Delegación Coyoacán,  
 Cd. de México, 04510.

**\*Corresponding author:**

Tel: + 52-55-56-22-58-68

Email address:

[magdaesc@unam.mx](mailto:magdaesc@unam.mx)

### Abstract

During the 2012 highly pathogenic avian influenza outbreak in Mexico caused by the H7N3 subtype, infection led to the death of approximately 22 million laying hens. Thus, poultry farmers were faced with a challenge to ensure the continued commercial flow of eggs. In addition to implementing established sanitary protocols and vaccination programs, forced moulting management was utilized in the affected areas. This strategy guaranteed the maintenance of egg production in the quarantined areas by decreasing the mortality of the infected flock while re-stimulating egg production. To understand how forced moulting reduced mortality of the infected birds, we examined the distribution of the avian influenza receptor in the oviduct of hens subjected to forced moulting. We tested if changes in the reproductive tract caused by forced moulting generated a decrease in the expression of the specific virus receptor in the cell membranes. Host susceptibility to the influenza virus was determined by the presence of these specific receptors. We utilized immunofluorescence of the *Maackia amurensis* lectin to identify the presence of the virus receptor in histological sections of the oviducts of birds in egg production and birds undergoing forced moulting. The results showed the presence and distribution of the receptors for avian influenza. A strong signal of the receptor was observed in the histological sections of the oviducts of birds in egg production. Conversely, the signal was low in the oviducts of birds undergoing forced moulting. These results demonstrate a decrease in the number of receptors of birds subjected to forced moulting. A lack of receptors would affect virus infection and replication as well as virus-induced damage in the oviduct, which may help explain the observation in the field that birds infected with avian influenza and subjected to forced moulting have decreased mortality.

**Keywords:** avian influenza, immunofluorescence, forced moulting, oviduct, egg production.

Received: 2016-10-25

Accepted: 2016-12-02

Published: 2017-02-17

Additional information and declarations  
 can be found on page 7

© Copyright 2017  
 Elizabeth Castillo-Villanueva et al.

open access 



Distributed under Creative Commons CC-BY 4.0

### Introduction

On June 21, 2012, Mexico officially reported the presence of the highly pathogenic avian influenza (HPAI) virus subtype H7N3 in three commercial egg laying farms in the state of Jalisco. The affected birds showed clinical signs of ruffled feathers,

lethargy, anorexia, prostration, depression, and acute death.<sup>1</sup> The ages of the infected birds were 32, 72, 75, 84, and 94 weeks. To prevent the dissemination of the disease, health authorities implemented a quarantine, restricting the movement of both products and by-products to and from the areas where the outbreaks were identified. They also initiated epidemiological surveillance to determine viral dissemination, humane slaughter of the surviving birds from the affected farms, and disinfection of infected areas or establishments.<sup>2</sup> Despite these implemented measures, the virus continued to disseminate to different poultry farms in the area and two additional states of Mexico.<sup>3</sup> The infection significantly affected laying and breeding hens but had limited effects on farms producing broilers. Following the implementation of vaccination, the infected flocks of vaccinated laying hens exhibited decreased mortality. However, the virus's most significant impact was on the hen-day-egg production rates, which did not recover after their initial descent. Additionally, eggs exhibited poor internal and external qualities and deformities.<sup>4</sup> A first step for influenza virus to successfully infect and propagate within a host is the binding of hemagglutinin (HA) to surface receptors in the host cell, which occur with significant affinity and specificity.<sup>5,6</sup> Thus, the presence of influenza virus receptors in the organs of birds is vital to the success of influenza virus infection.<sup>5-7</sup>

In addition to the sanitary measures implemented in Jalisco, the forced moulting of birds was performed in the quarantined areas to further ensure the flow of eggs in the market, as eggs are considered a staple food in Mexico.<sup>8</sup> Forced moulting involves decreasing the caloric intake and amount of daylight animals are exposed to in order to first stop egg production; afterwards, the reproductive track is rejuvenated and again begins to produce eggs.<sup>9</sup> Commercial egg producers use moulting to optimize and synchronize their layer flocks. Historically, laying birds have been produced for one laying cycle and then subsequently culled<sup>10</sup>; with forced moulting, laying birds are used for a second production cycle that produces a larger egg with a more resistant shell compared to the eggs produced on the first cycle.

Groups of vaccinated birds that were beginning to experience increased mortality were immediately subjected to forced moulting; egg production was stimulated and the rate of hen-day-egg production increased up to 90 percent. In contrast, the high mortality rate continued in the vaccinated flocks that became infected and were not subjected to forced moulting, showing a hen-day-egg production rate of 50 percent or less (personal communication of Dr. Ramón López). Forced moulting also prevented egg deformities and preserved egg quality.

Despite the controversy behind forced moulting secondary to public perceptions of the production methods, this practice can be performed with proper animal care parameters that are minimally stressful to the birds while successfully promoting egg production, as observed during emergency situations, such as the last HPAI outbreak in Mexico, and ensure the commercial egg supply. We aimed to explain why HPAI infected birds undergoing forced moulting had lower mortality rates than birds not subjected to forced moulting. We hypothesized that forced moulting provoked physiological atrophy of the reproductive system, causing changes (i.e., receptor density for the avian influenza (AI) virus) in the lining of the reproductive tract of the birds that protected them from HPAI virus infection. To test this hypothesis, we determined if changes in the reproductive tracts of laying hens caused by forced moulting provoked a decrease in the expression of the specific receptor for

the AI virus. Such effects would prevent infection and replication with HPAI, allowing birds to reach their optimal production rates without affecting internal and external egg qualities.

## Materials and methods

### Sample collection

To ensure the absence of AI infection in the flocks from which samples for this study were obtained, all birds in either production or induced into forced moulting were obtained from the State of Nuevo Leon, Mexico, which was officially identified as free of both the low pathogenic and high pathogenic H5N2 and H7N3 subtypes of AI.<sup>11</sup> A group of 20 healthy laying hens aged 30 weeks from the Bovans White line was obtained (henceforth referred to as the production group). The hens were euthanized with the permission of the farm manager,<sup>12</sup> and necropsies were performed. The oviduct was isolated from each hen. Sections of the magnum region and the uterus were obtained and placed in a 10 % buffered formalin solution for processing. Samples were collected from these two regions because we observed that vaccinated and HPAI H7N3 infected laying hens produced eggs with poor albumin content (performed in the magnum) and mineralization (performed in the uterus).<sup>13</sup> In a second group (henceforth referred to as the forced moulting group), a flock of healthy birds from the Bovans White line (75 weeks old) that had completed their first production cycle were induced into forced moulting. Twenty birds were randomly selected and euthanized with the permission of the farm manager.<sup>12</sup> Necropsies were performed, and the oviducts were recovered. The regions that comprised the organs could not be differentiated because they were atrophic. Therefore, sections were obtained at different distances and placed in a 10 % buffered formalin solution for processing.

### Haematoxylin and Eosin (HE) Staining

To visualize the structures forming the different regions of the oviduct and the structural differences between birds in production and birds in forced moulting, HE staining was performed on the oviducts of both groups of birds according to standard protocols.<sup>13</sup>

### Immunofluorescence (IF) Assays

To demonstrate the presence of the AI receptor, *Maackia amurensis* lectin (MAA), which specifically recognizes sialic acid in an  $\alpha$ 2-3 conformation, was coupled to the FITC fluorophore (M1062-50F); US Biological Life Science, Mexico.<sup>14</sup> The samples of the oviduct tissue were fixed in formalin and embedded in paraffin. Sections with 3 mm thickness were obtained and placed on positively charged slides (Klingon HIER Slides, Biocare Medical, Mexico). The slides were maintained at 57 °C for 2 hours. The sections were deparaffinized, incubated in xylol for 15 minutes at room temperature, and then rehydrated in a graduated series of ethanol and water. Following hydration, antigen retrieval was performed with 1X DIVA Decloaker (Biocare Medical, Mexico) in a pressure cooker for 10 minutes. The slides were incubated overnight at 4 °C with FITC-MAA, which specifically recognizes sialic acid  $\alpha$ 2-3, diluted 1:1000 in Da Vinci Green Diluent buffer (Biocare Medical, Mexico).

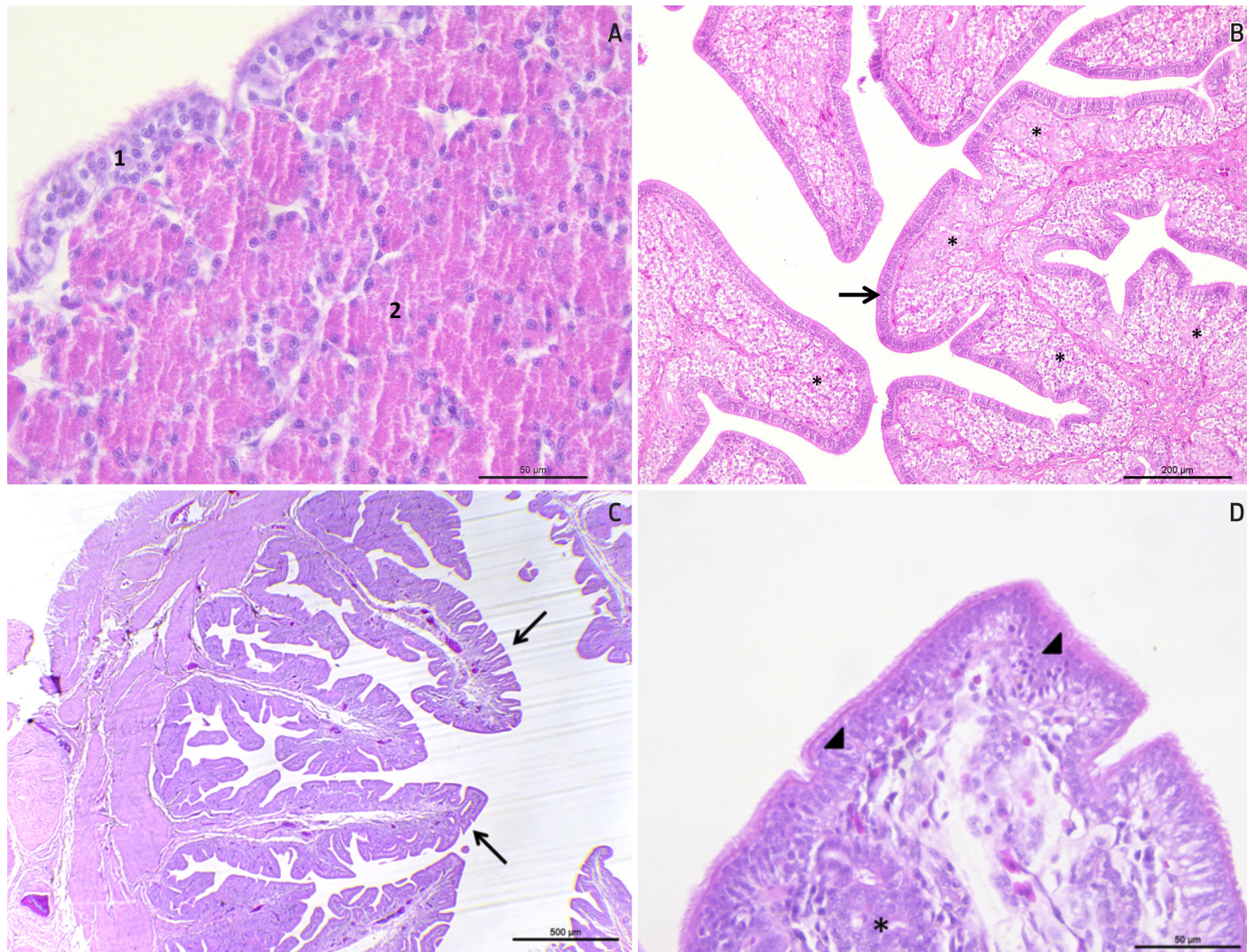
Three washes were performed with 1X PBS. The slides were then incubated for 20 min with 4'-6-diamidino-2-phenylindole dihydrochloride (DAPI; Sigma-Chemical, Mexico) to stain cell nuclei. The slides were prepared with VECTASHIELD® mounting medium (Vector Laboratories, Mexico) and then examined with a Leica TCS SP5 confocal laser microscope (Leica Microsystems, Wetzlar, Germany). For the negative controls, MAA lecithin was replaced with 1X PBS and a secondary antibody coupled to the FITC fluorophore (Alexa 488, Invitrogen, Mexico).

## Results and discussion

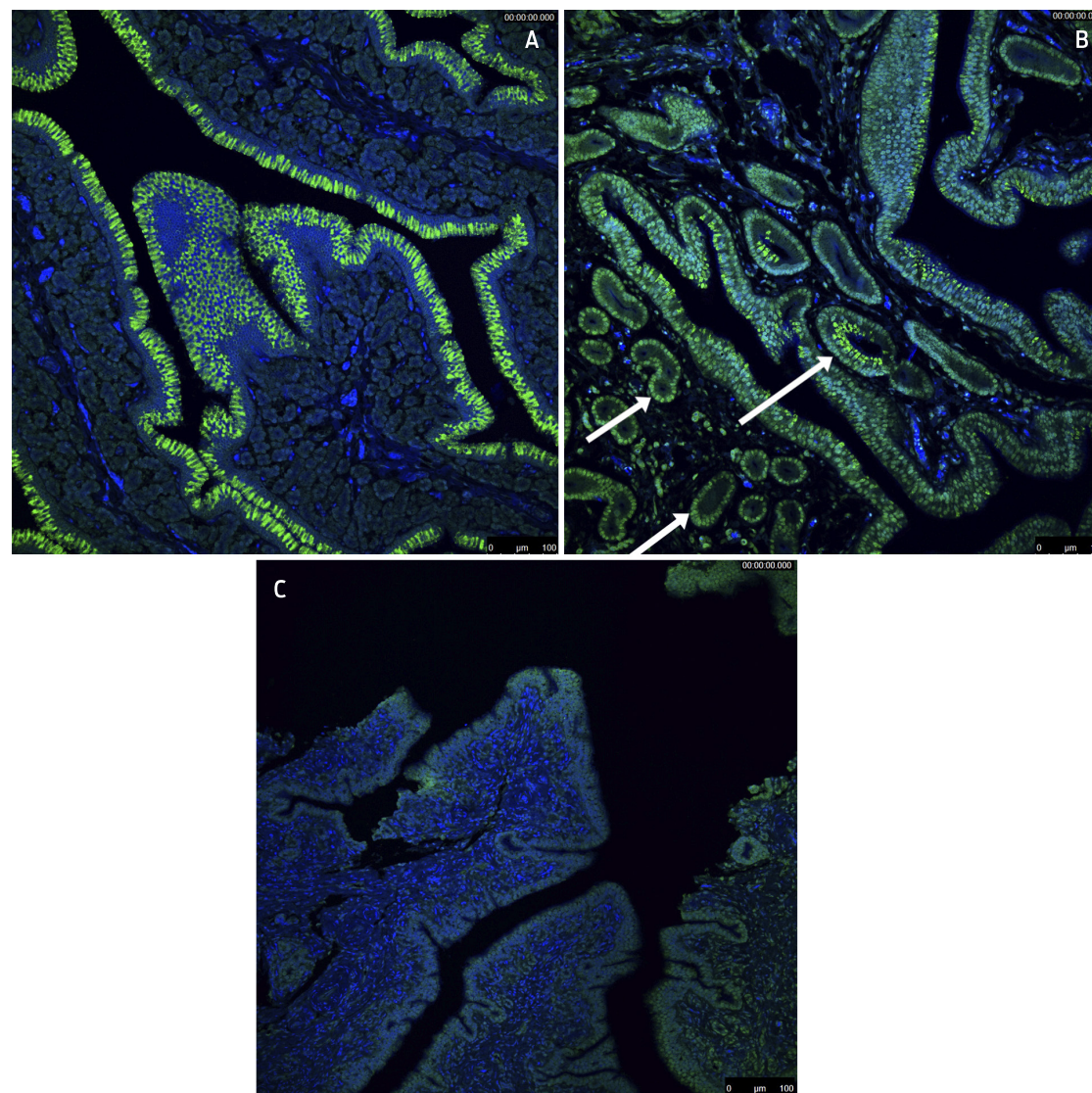
The data reported below was found in the oviducts of birds in this study. In the histological sections from the production group, the magnum mucosa was lined with a ciliated pseudostratified cylindrical epithelium. Underneath the epithelium, we observed tubular secretory glands with basal pyknotic nuclei and a cytoplasm occupied by acidophilic granules (Figure 1A). In the uterus, the mucosa was lined with a ciliated pseudostratified cylindrical epithelium that overlaid an abundant amount of eggshell glands (Figure 1B).

Moderate atrophy characterized by folds of the small and narrow mucosa was observed in the oviducts of the forced moulting group. The epithelial lining was decreased in size, the secretory material in the cytoplasm was minimal, and only a few caliciform cells were observed. In the glandular portion, scarce and poorly developed glands characterized by round, euchromatic nuclei with small amounts of cytoplasm were detected; a moderate amount of connective tissue was also observed (Figures 1C and 1D). The results described above are consistent with the results reported by Eroschenko and Wilson.<sup>15</sup>

In the immunofluorescence assay, we detected abundant expression of the AI virus receptor in the apical areas of the cells of the mucosal epithelium, in the epithelial cells of the glandular ducts of the magnum regions and in the uterus of the oviduct of the birds in production (Figures 2A and 2B). These results agreed with the results obtained by Wang *et al.*<sup>16</sup> In the oviducts of birds subjected to forced moulting, a decreased signal intensity of the AI virus receptor was observed compared to the signal in the oviducts of birds in production. This phenomenon may be explained by the atrophy of this organ as a consequence of forced moulting (Figure 2C). The presence of AI virus receptors causes host cells to be susceptible to infection and thus plays an important role in viral pathogenesis. The presence of receptors in the epithelial cells of the glandular ducts is key for the infection of the reproductive tract and contributes to AI viremia. Wang *et al.*<sup>16</sup> performed a linear regression analysis and showed that the correlation coefficient between the presence of AI virus receptors and the viral load was 0.9 with a slope of 3.5, indicating that these variables are strongly associated. Together, the evidence presented by Wang *et al.*<sup>16</sup> and our results suggest that in birds subjected to forced moulting, the AI virus is not able to replicate in the reproductive tract. Therefore, the viral load was low in birds subjected to forced moulting, secondary to the low presence of receptors in their reproductive tract, allowing that the antibodies stimulated by the previous vaccination prevented damage in the oviduct and in the quality of the egg.



**Figure 1.** A. Photograph of a histological section of the magnum region of healthy hens in production. The mucosa was lined with a ciliated pseudostratified cylindrical epithelium (1) on top of tubular secretory glands (2) with basal, pyknotic nuclei and a cytoplasm occupied by acidophilic granules. HE staining. Bar: 50  $\mu$ m. B. Photograph of a histological section of the uterus region of healthy hens in production. Mucosa (arrow) was formed by a ciliated pseudostratified cylindrical epithelium and a glandular epithelium containing a significant quantity of cells with active nuclei. HE staining. Bar: 200  $\mu$ m. C. Photograph of a histological section of the oviduct from a hen in forced moulting. Severe mucosal atrophy is observed, which is characterized by small and narrow folds (arrows). HE staining. Bar: 500  $\mu$ m. D. Photograph of a histological section of the oviduct of a hen in forced moulting. Hyposecretion of the epithelial lining (arrowhead) and scarce glands in the regenerative phase (asterisk) are observed. HE staining. Bar: 50  $\mu$ m.



**Figure 2.** **A.** Abundant amount of influenza-like receptors, labelled with apple-green fluorescence, on the apical region of the ciliated cylindrical pseudostratified epithelium of the uterine region of healthy hens in production. Bar: 100  $\mu$ m. **B.** Influenza-like receptors (arrows), marked by apple-green fluorescence, located on the epithelial cells of the glandular ducts of the magnum region of healthy hens in production. Bar: 100  $\mu$ m **C.** Histological section of birds in forced moulting. The influenza virus receptor, labelled with apple-green fluorescence, is localized in the apical area of the mucosal epithelium; the fluorescence intensity is lower than the intensities shown in Figures 2A and 2B. Bar: 100  $\mu$ m.

This result is in contrast to data obtained for birds that were vaccinated but were not subjected to forced moulting. García *et al.*<sup>17</sup> evaluated the antigenic concentration of emulsified vaccines and showed the importance of the antigenic load for inducing adequate immunity in field challenges. One question that remains is how much HPAI antigen is necessary to cause damage to the reproductive tract of vaccinated birds subject to forced moulting.

Currently, we cannot conclude definitively that our hypothesis is correct, and further research is needed. Specifically, a next obvious step in testing our hypothesis would be controlled AI infection in birds undergoing forced moulting. Furthermore, another important variable to test is the number of doses of vaccination that are needed to reduce the level of viral shedding from vaccinated birds subjected to forced moulting and infected with AI under controlled conditions.

## Conclusion

Our results showed that forced moulting decreased the presence and distribution of the receptor for avian influenza in the oviducts of laying hens. These results suggest that one method to counteract the risk of infection of laying hens exposed to avian influenza virus, is to implement forced moulting as was performed in the quarantine zone of Mexico, during the HPAI outbreak in the summer of 2012.

---

## Funding

This study was supported by CONACYT: SALUD 2009-C02-126619, Facultad de Medicina Veterinaria y Zootecnia. Universidad Nacional Autónoma de México.

## Acknowledgements

The authors thank Ramón López, MVZ for his valuable assistance in allowing us access to production records from infected flocks and Carlos Cubillas, MVZ, and Daniel Juárez Pérez, MVZ, for providing organs that allowed us to obtain the results published in this study. We also thank the technicians Maria J. Gomora, V. Rodríguez-Mata, and M. Peña Rico for technical assistance in the histological process. Additionally, we thank Dr. Patti Miller for comments on the manuscript.

## Conflicts of interest

The authors declare that they have no conflicts of interest.

## Author contributions

Magdalena Escorcía led the research and experimental design, analysed the data and wrote part of the manuscript. Elizabeth Castillo-Villanueva interpreted the results and wrote part of the manuscript, and Félix Sánchez-Godoy interpreted the results and wrote part of the manuscript.

## References

1. Organización Mundial de la Salud Animal [OIE]. Update on avian influenza Paris, France: OIE; 2012 [Available from: [www.oie.int/en/animal-health-in-the-world/update-on-avian-influenza/2012/](http://www.oie.int/en/animal-health-in-the-world/update-on-avian-influenza/2012/)].
2. Diario Oficial de la Federación. Acuerdo Sanitario para la Erradicación de Influenza Aviar de Alta Patogenicidad H7N3. In: SAGARPA, editor. México D F: Secretaría de Gobernación; 2013.
3. Organización Mundial de la Salud Animal [OIE]. Update on avian influenza Paris, France: OIE; 2013 [Available from: <http://www.oie.int/es/sanidad-animal-en-el-mundo/actualizacion-sobre-la-influenza-aviar/2013/>].
4. Kapczynski DR, Patin-Jackwood M, Guzman SG, Ricardez Y, Spackmen E, Bertran K, et al. Characterization of the 2012 highly pathogenic avian influenza H7N3 virus isolated from poultry in an outbreak in Mexico: Pathobiology and vaccine protection. *J Virol*. 2013;87(16):9086-96. doi: 10.1128/JVI.00666-13.
5. Fouchier RA, Kawaoka Y, Cardona C, Compans RW, García-Sastre A, Govorkova EA, et al. Gain-of-function experiments on H7N9. *Science*. 2013;341(6146):612-3. doi: 10.1126/science.341.6146.612.
6. Skehel JJ, Wiley DC. Receptor binding and membrane fusion in virus entry: The influenza hemagglutinin. *Annu Rev Biochem*. 2000;69:531-69. doi: 10.1146/annurev.biochem.69.1.531.
7. Sasaki GL, Elli S, Rudd TR, Macchi E, Yates EA, Naggi A, et al. Human ( $\alpha$ 2,6) and avian ( $\alpha$ 2,3) sialylated receptors of Influenza A virus show distinct conformations and dynamics in solution. *Biochemistry*. 2013;52:7217-30. doi: 10.1021/bi400677n.
8. INEGI. Índice Nacional de Precios al Consumidor. In: Geografía INdEy, editor. México D. F. 2016.
9. Sariözkan S, Güclü BK, Kara K, Gürçan S. Comparison of different molting methods and evaluation of the effects of postmolt diets supplemented with humate and carnitine on performance, egg quality, and profitability of laying hens. *J App Poult Res*. 2013;22(4):689-99. doi: 10.3382/japr.2012-00612.
10. Bell DD. Historical and current molting practices in the U.S. table egg industry. *Poult Sci*. 2003;82:965-70.
11. Organización Mundial de la Salud Animal [OIE]. Update on avian influenza Paris, France: OIE; 2016 [Available from: [www.oie.int/en/animal-health-in-the-world/update-on-avian-influenza/2016/](http://www.oie.int/en/animal-health-in-the-world/update-on-avian-influenza/2016/)].
12. Facultad de Medicina Veterinaria y Zootecnia. Norma Oficial Mexicana. Especificaciones técnicas para la producción, cuidado y uso de los animales de laboratorio. México D F: Universidad Nacional Autónoma de México; 2014.
13. Prophet EB, Mills B, Arrington JB, Sobin LH. *Laboratory Methods in Histotechnology* (Armed Forces Institute of Pathology). Washington D C, USA: American Registry of Pathology; 1992. 279 p.
14. França M, Stallknecht DE, Howerth EW. Expression and distribution of sialic acid influenza virus receptors in wild birds. *Avian Pathol*. 2013;42(1):60-71. doi: 10.1080/03079457.2012.759176.
15. Eroschenko VP, Wilson WO. Histological changes in the regressing reproductive organs of sexually mature male and female Japanese quail. *Biol Reprod*. 1974;11:168-79.

16. Wang JY, Chen ZL, Li CS, Cao X, Wang R, Tang C, et al. The distribution of sialic acid receptors of avian influenza virus in the reproductive tract of laying hens. *Molecular and Cellular Probes*. 2015;29:129-34. doi: 10.1016/j.mcp.2015.01.002.
17. García A, Johnson H, Srivastava DK, Jayawardene DA, Wehr DR, Webster RG. Efficacy of inactivated H5N2 influenza vaccines against lethal A/Chicken/Queretaro/19/95 infection. *Avian Dis*. 1998;42(2):248-56.