Revista Odontológica Mexicana
Órgano Oficial de la Facultad de Odontología UNAM

Clinical case

Complete Oral Rehabilitation with Total Dentures in a Patient with Intellectual Disability

Ernesto Sandino Falcón-Contreras[1], Blanca Nieves-Rodríguez[2], Jacqueline Adelina Rodríguez-Chávez[3], Alvaro García-Pérez[4], Karina Magaña-Curiel[5], Ricardo Curiel-González[6]

1. Residente de la especialidad en Prostodoncia. Departamento de Clínicas Odontológicas Integrales. Centro Universitario de Ciencias de la Salud. Universidad de Guadalajara. Guadalajara, Jalisco. México. https://orcid.org/0009-0002-0574-794X
2. Profesora de la especialidad en Prostodoncia. Departamento de Clínicas Odontológicas Integrales. Centro Universitario de Ciencias de la Salud. Universidad de Guadalajara. Guadalajara, Jalisco. México. https://orcid.org/0009-0007-7588-2473
3. Profesora investigadora de la especialidad en Prostodoncia. Departamento de Clínicas Odontológicas Integrales. Centro Universitario de Ciencias de la Salud. Universidad de Guadalajara. Guadalajara, Jalisco. México. https://orcid.org/0000-0003-1010-5044
4. Laboratorio de Investigación en Salud Pública. Facultad de Estudios Superiores Iztacala. Universidad Nacional Autónoma de México. México. https://orcid.org/0000-0002-0725-4658
5. Profesora de la especialidad en Prostodoncia. Departamento de Clínicas Odontológicas Integrales. Centro Universitario de Ciencias de la Salud. Universidad de Guadalajara. Guadalajara, Jalisco. México. https://orcid.org/0000-0003-1207-3170
6. Coordinador y profesor de la especialidad en Prostodoncia. Departamento de Clínicas Odontológicas Integrales. Centro Universitario de Ciencias de la Salud. Universidad de Guadalajara. Guadalajara, Jalisco. México. https://orcid.org/0009-0000-5825-2751

Correspondence author:
Jacqueline Adelina Rodríguez-Chávez
E-mail: jacqueline.rchavez@academicos.udg.mx

Received: 4 September 2025
Accepted: 8 January 2026

Universidad Nacional Autónoma de México. Revista Odontológica Mexicana Órgano Oficial de la Facultad de Odontología UNAM. ISSN 1870-199X. Se distribuye bajo una Licencia Creative Commons Atribución-NoComercial-SinDerivar 4.0 Internacional.

Cite as:
Falcón-Contreras ES, Nieves-Rodríguez B, Rodríguez-Chávez JA, García-Pérez A, Magaña-Curiel K, Curiel-González R. Rehabilitación oral completa con prótesis totales en paciente con discapacidad intelectual [Complete Oral Rehabilitation with Total Dentures in a Patient with Intellectual Disability]. *Rev Odontol Mex*. 2026; 30(1): 43-51. DOI: https://doi.org/10.22201/fo.1870199xp.2026.30.1.92892

ABSTRACT

Introduction: Total edentulism is defined as the absence of all teeth in both the maxilla and the mandible, and represents a condition that significantly affects the quality of life, by compromising essential functions such as mastication, phonation and facial aesthetics. It is also considered a global public health problem, especially among adults over 60 years of age. In the case of people with intellectual disabilities (ID), the situation can be even more complex, as they have a greater risk of developing edentulism due to difficulties in self-care, barriers to accessing dental services, and a higher prevalence of untreated oral diseases. **Objective:** To rehabilitate a patient with ID using mucosa-supported total dentures, restoring health, function, and aesthetics, thus improving her quality of life. **Case presentation:** A 55-year-old female patient diagnosed with mild ID and high blood pressure came to the Prosthodontics Specialty Clinic for an evaluation. During the clinical inspection, total edentulism was observed in the maxilla and partial edentulism in the mandible, with only tooth 46 present. Due to the ID, alveolar bone resorption, economic limitations and the patient's poor oral care, it was decided to perform conventional total dentures. **Conclusions:** Although implant-supported prostheses are an advanced option for edentulous patients, their cost and maintenance limit their access for many patients with ID. In these cases, rehabilitation with mucosa-supported total dentures remains a fundamental alternative, as it allows for the restoration of function, aesthetics, and oral health. Furthermore, when they are adapted to the needs and abilities not only of the patient, but of their caregivers, it contributes to improving their communication, socialisation and quality of life.

Keywords: Complete dentition, Edentulous arch, Intellectual disability

INTRODUCTION

Edentulism is defined as the complete loss of natural teeth and is an irreversible process[1-5]. Several authors report that edentulism is a public health problem affecting a large part of the world's population, which, although it has decreased in the last decade, remains a significant health problem, especially among adults over 60 years of age[1,5]. The relative prevalence is decreasing in developed countries, but it remains very prevalent in older adults and vulnerable populations. It has been shown that its frequency varies depending on the country or region due to various factors such as: age, education, socioeconomic level, lifestyle, knowledge about oral health and attitudes towards dental care[1,4]. It can occur due to multifactorial causes such as biological (dental caries, periodontal disease, trauma, cancer, among others), social (poor access to dental care and insurance systems) and behavioural (patient habits) that have led to that status of disease[3].

Felton[6] reported that edentulous patients are associated with poor eating habits, inadequate nutritional intake, osteoporosis, and an increased risk of hypertension and coronary artery disease. Other authors point out that edentulism can negatively affect the well-being of patients, who often express dissatisfaction with their dental aesthetics and a decrease in self-esteem. In addition, there may be significant social repercussions, such as avoiding social events or situations, difficulties in communication due to speech impairments, and the association of edentulism with old age or poor general health, which can lead to experiences of discrimination or self-exclusion[3,7].

On the other hand, people with intellectual disabilities (ID) are patients who frequently present with poor oral hygiene, so it is common to observe periodontal problems and dental caries[8-10]. This group of patients faces various difficulties when undergoing dental treatments, due to their physical and/or mental limitations that can lead to a decline in self-care, and oral health is often given low priority. Oliveira *et al.*[9] highlight problems such as the lack of knowledge about oral diseases, awareness of oral needs, the side effects of medications, and the organisation of dental services. These cases require a great commitment from the patient, dentist, and healthcare staff for the proper follow-up and maintenance of the dental prostheses[8].

The objective of this clinical case is to rehabilitate a patient with intellectual disability using mucosa-supported total dentures, restoring health, function, aesthetics, and thus improving her quality of life.

CLINICAL CASE PRESENTATION

A 55-year-old female patient diagnosed with mild intellectual disability (ID) and hypertension came to the Prosthodontics Specialty Clinic for consultation: *"I want to get my teeth put in"*. Extraoral photographs showed a lack of lip support, loss of vertical dimension, and very marked nasolabial folds as a result of missing teeth (Figure 1. A-B). She presented total edentulism in the maxilla with alveolar ridge resorption Seibert's Class I in the anterior part and Class III in the posterior part; in the mandible she presented partial edentulism, with only tooth 46 with amalgam metal restoration and with Seibert's Class III resorption (Figure 1. C-D). In the orthopantomography (Figure 1. E), we highlighted a superior alveolar process with bone resorption at the level of premolars, and the mandible showed the periodontal ligament widening in tooth 46.

Due to ID, alveolar bone resorption, economic issues, and the patient's poor oral hygiene, it was decided to create complete mucosa-supported dentures, which were fabricated through the following phases:

Phase I: Diagnostic anatomical impressions were taken with alginate (Neocolloid, Zhermack SpA, Italy) using metal trays (Rim-Lock Tray, Dentsply Sirona Inc, USA) and filled with type III plaster (Elite Model, Zhermack SpA, Italy) for the fabrication of individual trays with acrylic for trays (Nic Tone®, MDC® Dental, Mexico).

Phase II: Definitive impressions were taken using the closed-mouth technique with regular consistency polyvinyl siloxane (3MTM ImprintTM, 3M, USA) since the patient had firm gum tissue. Myofunctional cuts were made with red modelling clay (Impression Compound, Kerr Corporation, USA), on the contour of the tray, heating it with a lamp (HanauTM Alcohol Torch, Whip Mix, USA) and tempering it with warm water, so to achieve an optimal peripheral seal, which is essential in the stability and retention of the total prostheses (Figure 2. A).

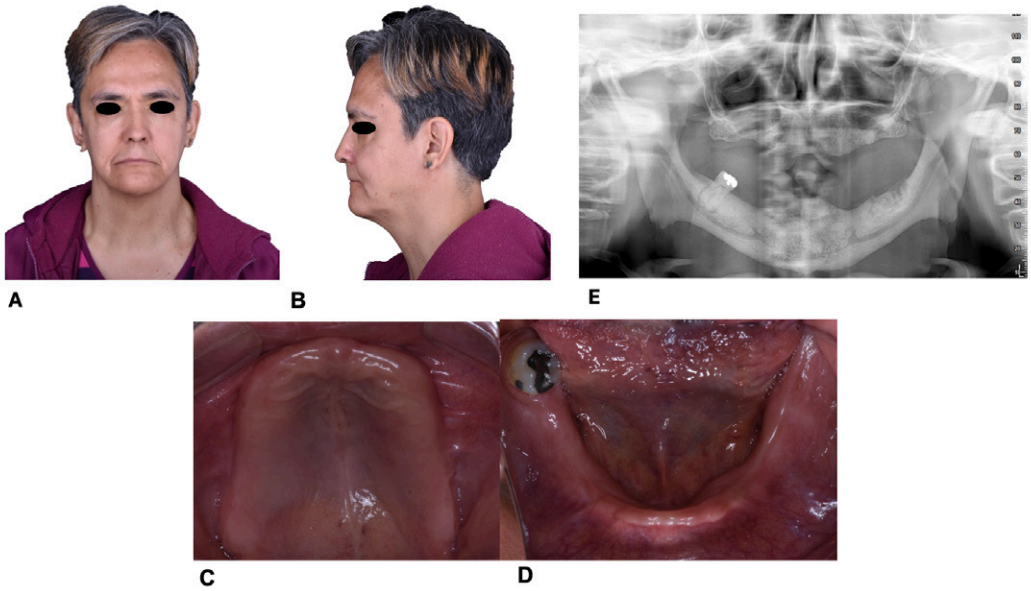

Figure 1. Initial patient status. A. Frontal extraoral photography. B. Left lateral extraoral photography. C. Maxillary occlusal intraoral photography. D. Mandibular occlusal intraoral photography. E. Initial orthopantomographic radiograph.

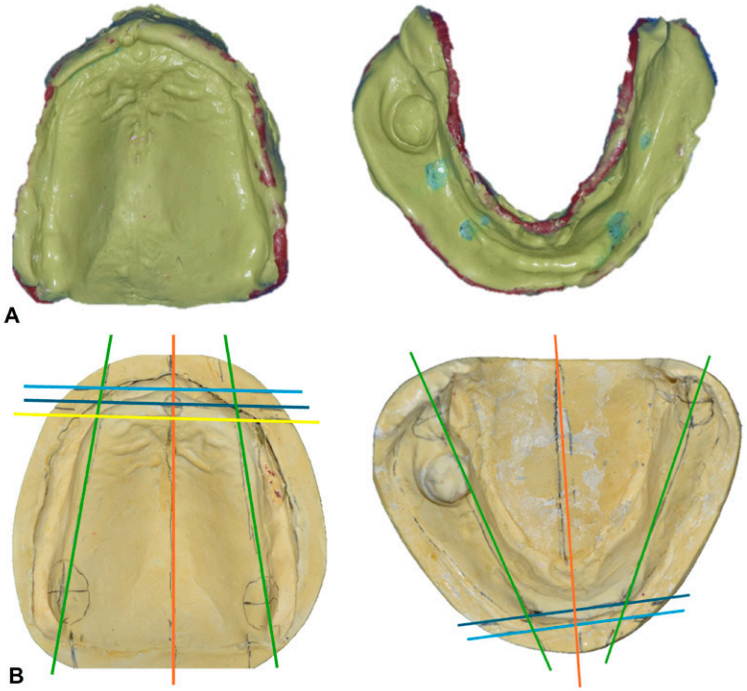

Figure 2. Final impressions and models. A. Final impressions with regular polyvinylsiloxane and modeling compound. B. Working plaster models with anatomical features: anterior border of the gingival margin (light blue), center of the incisive papilla (navy blue), posterior line of the incisive papilla (yellow), median raphe (orange), and center of the residual process and maxillary tuberosity (green).

Phase III: In the type III plaster models obtained, the lines were drawn with the help of anatomical references such as median raphe, maxillary tuberosity, retromolar pad (Figure 2. B) to delimit the extension of the bases, made with Nic Tone® transparent acrylic to improve their stability, and the rollers were made with extra-hard pink wax (Rogson Wax, MDC® Dental, Zapopan, Mexico), to record the maxillo-mandibular relationships. Subsequently, various anatomical references were recorded, such as the position of the dental midline and canines, in addition to verifying the parallelism with the interpupillary line (Figure 3. A) and Camper's plane (Figure 3. B), which are aesthetic parameters for the fabrication of total prostheses. The second lower right molar was also extracted due to the patient's poor hygiene.

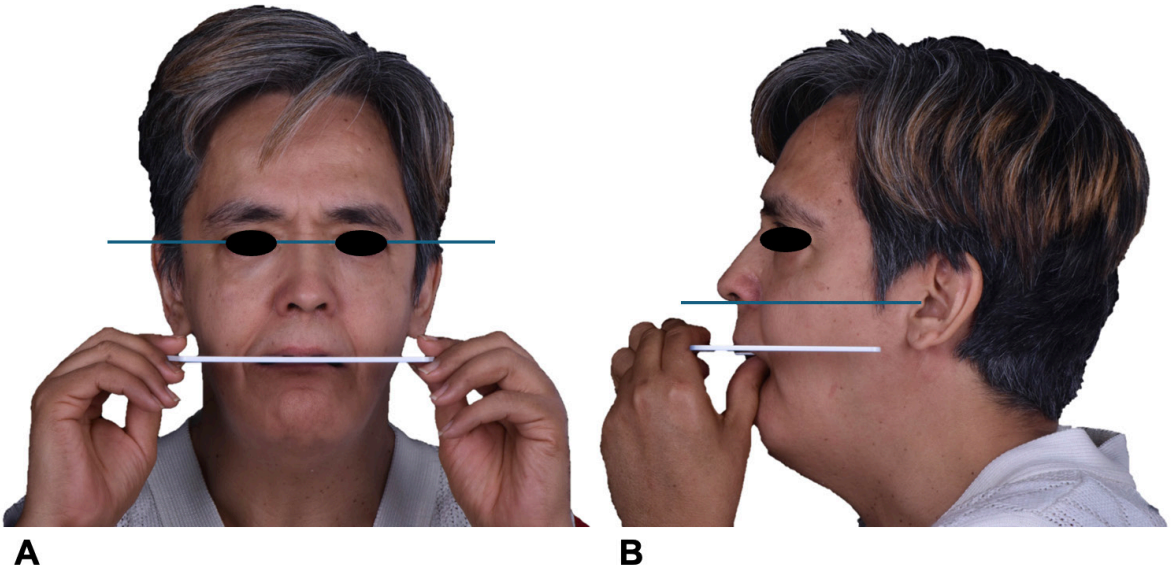

Figure 3. Parallelism with reference facial planes. A. Parallelism with the interpupillary line. B. Parallelism with Camper's plane.

Phase IV: On the bases and rollers, the acrylic teeth were mounted (VITA MFT®, VITA Zahnfabrik, Germany) and a wax trial was performed (Figure 4. A), with an occlusal scheme with balanced bilateral occlusion, this scheme presents good functional results in mucosa-supported total prostheses11. Afterwards, the complete dentures were processed using heat-curing acrylic shades RV1 and RV2 (Opti-Cryl®, New Stetic S.A., Colombia), and the dentures were polished and finished (Figure 4. B). Finally, the prostheses were delivered (Figure 5) and instructions for use and care of the prostheses were given to the patient verbally, in writing and audiovisually, with simple, understandable and didactic language, and likewise to the family members who are taking care of her. Throughout the treatment, techniques generally used in paediatric dentistry were employed, including appropriate communication, tell-show-do method, positive reinforcement, and picture communication systems, to help the patient gain more confidence and cooperation during consultations[12].

Figure 4. Laboratory process. A. Complete dentures in wax try-in. B. Complete dentures processed, adjusted, and polished.

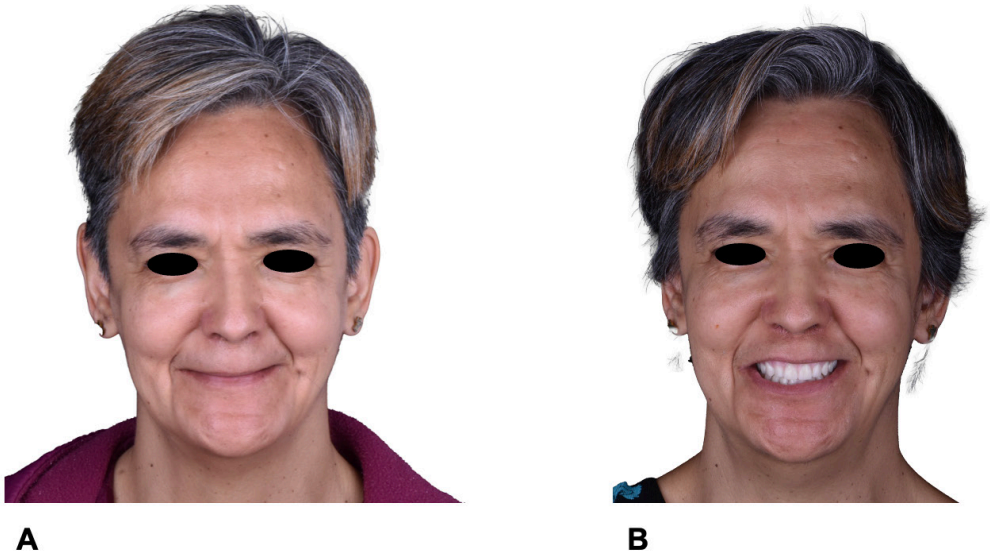

Figure 5. Initial and final comparisons. A. Initial frontal photography. B. Final frontal photography.

Phase V: After four weeks of using the prostheses, the patient experienced discomfort, so internal adjustments were made to the prosthesis in some areas with greater pressure, which were verified with pressure indicating paste (Mizzy PIP, Keystone Industries, USA), worn down with a round-tipped tungsten bur with a red line (Horico Dental, Hopf, Ringleb & Co. GmbH & Cie., Germany) and subsequently a direct self-curing acrylic reline (FlexacrylTM Soft, Lang Dental MFG. CO., Inc., USA) was made in the area of tooth 46, where there was a slight misalignment due to the previous extraction.

The treatment objectives of improving the dental health, function, and aesthetics of the patient with ID were successfully met, improving her quality of life through complete rehabilitation with total dentures.

DISCUSSION

Edentulism represents a significant public health problem due to its repercussions on masticatory function, aesthetics, and quality of life. According to Emami *et al.*[1], total tooth loss not only compromises oral health but also fundamental aspects such as nutrition, communication, and general health. These consequences are even more relevant in people with ID, who have a higher prevalence of oral diseases. These individuals face significant barriers to accessing dental care, such as a lack of knowledge about oral health, limited awareness due to ID, lack of oral health promotion, and conditional access to dental services, as highlighted by Ward *et al.*[8]. In the clinical case presented, the patient reported that she could not eat comfortably or communicate adequately due to the complete loss of her teeth, a situation aggravated by her ID. This difficulty was also reflected in the medical history, where she stated that she avoided participating in family events due to the inability to eat or speak normally.

Lee & Saponaro[3] mention that complete dentures remain a valid rehabilitation option for completely edentulous patients. However, they point out that implant-supported alternatives offer advantages in terms of retention, stability, and comfort. Nonetheless, in people with ID, the prosthetic approach must be carefully individualised, taking their cognitive, functional, and social conditions into account. In the present case, the patient presented with mild ID, which according to the American Psychiatric Association[13] has an intelligence quotient of 50 to 70, which corresponds to a preschool child, approximately 5 years old, so the patient cannot perform basic activities independently, including eating, brushing her teeth, personal hygiene, etc., which may explain why she lost her teeth.

In this case, different therapeutic options were considered, including total implant rehabilitation. However, this was ruled out due to three determining factors: mild ID, the complexity of hygiene for this type of prosthesis, and the patient's economic limitations. Therefore, the decision was made to manufacture conventional total prostheses.

The available evidence strongly supports the positive impact of prosthetic rehabilitation on oral health-related quality of life. Studies such as those by Martins *et al.*[10] and Linn *et al.*[4] confirm that the use of complete dentures improves self-perceived oral well-being and promotes social integration. These benefits are especially relevant for people with ID, who frequently face situations of social exclusion and communication limitations, as noted by Oliveira *et al.*[9]. In this sense, the clinical findings and the experience reported by the patient fully coincide with what is described in the literature; for example, she reported that she did not usually go out to family events because of her difficulty in communicating and eating.

However, dental care for people with ID involves several clinical challenges. The assessment of supporting tissues and oral habits, as indicated by Patel *et al.*[5], is fundamental before designing a prosthesis, and in these patients, this assessment should be complemented with behavioural management strategies, active participation of caregivers and, in certain cases, the use of conscious sedation or general anaesthesia. Solanki *et al.*[7] emphasise that caregiver education is an essential component, since maintaining oral hygiene and caring for the prostheses depend largely on the family or institutional environment. It is not only crucial that the prostheses are well made, but also that their proper cleaning, maintenance and follow-up

are guaranteed, aspects that are particularly relevant in patients with ID who require more intensive support, attention and care from their family members and/or guardians. In our case, the patient's close relatives and caregiver were given information verbally, in writing, and audiovisually about cleaning the mouth and the prostheses, maintenance appointments in case of any misalignment, the use of adhesives to improve the retention of the prostheses, the use of the prostheses only during the day, and to schedule a check-up appointment in case of any discomfort.

Both Oliveira *et al.*[9] and Ward *et al.*[8] agree that people with intellectual disabilities have a higher prevalence of caries, periodontal disease, and edentulism, reflecting a significant vulnerability in their oral health. In this context, the total prosthesis should not be understood solely as a rehabilitative resource, but also as a fundamental tool to prevent nutritional complications, promote social communication and foster the patient's overall well-being. In the clinical case presented, it was found that conventional prosthetic rehabilitation was an effective and accessible alternative, contributing to improving the quality of life of the edentulous patient with ID. However, its success depends on the treatment being approached from a multidisciplinary perspective, with patient-centred strategies and the active support of their family or institutional environment.

CONCLUSIONS

Edentulism still represents a significant challenge within public health, especially in vulnerable populations such as older adults and people with intellectual disabilities, who face greater barriers to accessing and maintaining dental treatment. This clinical case demonstrates that, despite the patient's cognitive, motor, and economic limitations, it is possible to achieve oral rehabilitation with conventional total dentures. The intervention not only restored health, function, and aesthetics, but also contributed to improving the patient's quality of life and overall well-being, highlighting the importance of adapting treatments to individual conditions and providing personalised follow-up, especially in patients with special needs.

BIBLIOGRAPHIC REFERENCES

1. Emami E, de Souza RF, Kabawat M, Feine JS. The impact of edentulism on oral and general health. *Int J Dent*. 2013; 2013(1): 498305. DOI: 10.1155/2013/498305
2. Layton DM, Morgano SM, Muller F, Kelly JA, Nguyen CT, Scherrer SS *et al*. The glossary of prosthodontic terms 2023: Tenth edition. *J Prosthet Dent*. 2023; 130(4 Suppl 1): e1-e126. DOI: 10.1016/j.prosdent.2023.03.003
3. Lee DJ, Saponaro PC. Management of edentulous patients. *Dent Clin North Am*. 2019; 63(2): 249-261. DOI: 10.1016/j.cden.2018.11.006
4. Linn TT, Khaohoen A, Thu KM, Rungsiyakull P. Oral-health-related quality of life in elderly edentulous patients with full-arch rehabilitation treatments: A systematic review. *J Clin Med*. 2024; 13(12): 3391. DOI: 10.3390/jcm13123391
5. Patel J, Jablonski RY, Morrow LA. Complete dentures: an update on clinical assessment and management: part 1. *Br Dent J*. 2018; 225(8): 707-714. DOI: 10.1038/sj.bdj.2018.866
6. Felton DA. Edentulism and comorbid factors. *J Prosthodont*. 2009; 18(2):88-96. DOI: 10.1111/j.1532-849X.2009.00437.x

7. Solanki J, Khetan J, Gupta S, Tomar D, Singh M. Oral rehabilitation and management of mentally retarded. *J Clin Diagn Res*. 2015; 9(1): ZE01-ZE06. DOI: 10.7860/JCDR/2015/11077.5415
8. Ward LM, Cooper SA, Hughes-McCormack L, Macpherson L, Kinnear D. Oral health of adults with intellectual disabilities: a systematic review. *J Intellect Disabil Res*. 2019; 63(11): 1359-1378. DOI: 10.1111/jir.12632
9. Oliveira JS, Prado Júnior RR, de Sousa Lima KR, de Oliveira Amaral H, Moita Neto JM, Mendes RF. Intellectual disability and impact on oral health: a paired study. *Spec Care Dentist*. 2013; 33(6): 262-268. DOI: 10.1111/scd.12015
10. Martins AMC, Guimarães LS, Campos CH, Küchler EC, Pereira DMS, Maia LC, *et al*. The effect of complete dentures on edentulous patients' oral health-related quality of life in long-term: a systematic review and meta-analysis. *Dent Res J* (Isfahan). 2021; 18(1): 65. DOI: 10.4103/1735-3327.324024
11. Goldstein G, Kapadia Y, Campbell S. Complete denture occlusion: best evidence consensus statement. *J Prosthodont*. 2021; 30(S1): 72-77. DOI: 10.1111/jopr.13309
12. American Academy of Pediatric Dentistry. Behavior guidance for the pediatric dental patient. In: *The reference manual of pediatric dentistry, 2025-2026* (p. 379-399). Chicago, IL: American Academy of Pediatric Dentistry, 2024. Disponible en https://www.aapd.org/globalassets/media/policies_guidelines/bp_behavguide25.pdf
13. American Psychiatric Association. *Diagnostic and statistical manual of mental disorders*. 5th ed, Washington, DC: American Psychiatric Association, 2022.