Revista Odontológica Mexicana
Órgano Oficial de la Facultad de Odontología UNAM

Clinical case

Management of a Dental Malocclusion with Mini Implants in Mandibular Shelf and Fixed Appliances. Case Report

Franklin Paul Ortiz-Garay[1], Nelinho Enrique Jiménez-Sánchez[2], Antonio Gómez-Arenas[3]

1. Docente. Universidad Católica de Cuenca. Práctica privada en ortodoncia. Ecuador. https://orcid.org/0009-0005-7282-2286
2. Docente. Departamento de Ortodoncia. División de Estudios de Posgrado e Investigación. Facultad de Odontología. Universidad Nacional Autónoma de México. México. https://orcid.org/0009-0007-2942-4092
3. Docente. Departamento de Ortodoncia. División de Estudios de Posgrado e Investigación. Facultad de Odontología. Universidad Nacional Autónoma de México. México. https://orcid.org/0009-0004-0875-9318

Correspondence author:
Franklin Paul Ortiz-Garay
E-mail: odfrankgaray@gmail.com

Received: 22 January 2025
Accepted: 28 November 2025

Cite as:
Ortiz-Garay FP, Jiménez-Sánchez NE, Gómez-Arenas A. Tratamiento de maloclusión dental con mini implantes en la repisa mandibular y aparatología fija. Reporte de caso [Management of a Dental Malocclusion with Mini Implants in Mandibular Shelf and Fixed Appliances. Case Report]. *Rev Odontol Mex*. 2026; 30(1): 32-42. DOI: https://doi.org/10.22201/fo.1870199xp.2026.30.1.94937

ABSTRACT

Introduction: Skeletal class III due to prognathism is defined as the anteroposterior disproportion of the mandible in relation to the maxilla. Its origin is multifactorial, and among its most frequent causes are genetic factors, oral habits, and premature loss of primary teeth, among others. The solution to this malocclusion in people who have completed their development is usually surgical or through a compensation treatment as a viable option to correct or mitigate the effects of

Universidad Nacional Autónoma de México. Revista Odontológica Mexicana Órgano Oficial de la Facultad de Odontología UNAM. ISSN 1870-199X. Se distribuye bajo una Licencia Creative Commons Atribución-NoComercial-SinDerivar 4.0 Internacional. Vol. 30, Núm. 1, Enero-Marzo 2026: 32-42

this condition, offering less invasive and accessible solutions for patients. **Objective:** To present non-surgical treatment techniques for patients with a class III maxillomandibular relationship due to mandibular prognathism. **Case presentation:** A 13-year-old female patient who sought orthodontic treatment whose reason for consultation was «*I don't like my teeth*." The diagnosis showed a straight facial profile, class I skeletal relationship with a tendency to class III due to an ANB of 1°, Ricketts convexity of 0.9°, and Wits -3.9°, Angle class III molar relationship, canine class III, proclination of upper incisors, upper and lower anterior crowding, and anterior and posterior crossbite on the left side. The treatment plan consisted of distalization of the lower arch with the use of mini-implants placed bilaterally on the mandibular shelf. At the end of the treatment, an Angle class I molar relationship, canine class I, posterior crossbite correction, and adequate overjet, overbite, and intercuspation were obtained. **Conclusions:** The use of mandibular shelf mini-implants is efficient for distalization of the lower dental arch in skeletal Class I patients with tendency towards Class III who present bilateral Angle molar Class III and canine Class III.

Keywords: Class III, mini screws, mandibular shelf.

INTRODUCTION

Treatment options for Class III malocclusion in adult patients will depend on the degree of dental and skeletal discrepancy. Cases can be treated by camouflage (performing extractions or distalization) or surgically. However, when the discrepancy is significant, the surgical option is more effective. It is essential to perform a complete clinical evaluation to determine the appropriate treatment for each patient[1-3]. Mini implants are minimally invasive skeletal anchorage that, although effective in orthodontics, must be used with justification and considering anatomical and biomechanical limitations and possible side effects[3,4]. The development of skeletal anchorage represents the emergence of a new way of performing orthodontics. Its use is increasingly common, offering many advantages if placed properly, functioning as a stable anchorage, with low cost, easy placement, and immediate loading[5,6]. Some skeletal malocclusions that in the past were only treatable with surgery can now be treated orthodontically with the use of mini implants. These are useful in comparison with other distalization mechanisms as they allow the entire mandibular arch to be distalized without loss of anchorage[7].

There are several options for distalizing upper molars; however, there are far fewer descriptions for the lower arch, considering that distal movements of the lower molars are more difficult to perform. Alternatives such as spring-loaded Gurin stops and Class III elastics can cause undesirable effects such as loss of anchorage, molar extrusion, and incisor proclination. The use of mini implants offers new possibilities for treating Class III malocclusions, but their placement in interradicular areas requires careful evaluation of space, as root proximity increases the risk of anchorage failure[6]. Studies using three-dimensional computed tomography to determine the most suitable interradicular areas for mini implant placement in the mandible have found that the interradicular distance is greater between the second premolar and first molar and between the first and second molar[6,8]. The retromolar area is considered one of the main areas for mini-implant placement in cases of Class III malocclusion because the bone mass is very large in this site. Adjacent roots, major blood vessels, and nerves do not interfere with the placement of mini implants[9]. However, their placement in the retromolar area is sometimes contraindicated due to the lack of attached gingiva. When a mini implant is placed through

mobile tissue, it generally has a lower success rate compared to when it is placed in attached gingiva[3].

In cases where there is insufficient space between the roots or in patients with repeated failure of mini-implant placement in the mandible, they can be placed in the upper arch. The biomechanics consist of using elastics with a Class III vector from the mini-implant placed in a posterior area of the maxilla to a crimpable hook located in the anterior area of the mandibular arch, typically the canines. By using skeletal anchorage in the maxilla, some of the side effects of using Class III elastics, such as proclination of the incisors and extrusion of the posterior teeth in the maxilla, can be avoided[10].

In lower arch retraction mechanics, the preferred site for mini implant placement is the mandibular shelf, which is located bilaterally in the most posterior part of the mandibular body, buccal to the roots of the first and second molars, and anterior to the oblique line of the mandibular ramus[11]. The mandibular shelf extends buccally with a considerable amount of bone, and this extension allows the orthodontist to insert the mini implant in an orientation parallel to the long axes of the molar roots[10]. Knowing the thickness of the cortical bone is beneficial for selecting the insertion site. Studies performed on cone beam computed tomography scans determined that the most favorable width is obtained from the buccal bone to the distal half of the second molar[12,13].

Baumgaertel[14] confirmed that cortical bone thickness is an important factor for mini-implant placement. It is also important to understand the anatomical characteristics of the bone at this insertion site. The results obtained in the studies by Elshebiny *et al.*[12] using cone beam computed tomography showed that the mandibular ramus offers sufficient bone quantity and quality. They can also be placed in the external oblique line if the mandibular shelf area is very thin[15]. The manner of the mini implant placement avoids the possibility of contact with the root during the distalization process as well as during its insertion. The overall failure rate for mini implant placement is relatively low[15]. In a study of 1,680 mini implants placed in the mandibular shelf, a success rate of 93% was achieved[12]. These data are consistent with the findings published by Chang *et al.*[11], where the success rate was 90%, and the failure rate was lower compared to those associated with the placement of mandibular interradicular mini implants[7,16].

The most common complications associated with mini implants are gingival enlargement and initial loosening. To avoid problems related to gingival enlargement, strict cleaning of the area is essential. The incidence of gingival enlargement is considerably lower in mini implants with larger heads. If the implant is not properly fitted, it is recommended that the mini implant be repositioned in a different area to ensure better stability and clinical prognosis[4,17]. Trauma to the ligament or tooth root may also occur. Possible complications of root injury include loss of vitality, root resorption, and dentoalveolar ankylosis[8]. Dental roots damaged by the placement of a mini implant can be completely repaired in terms of the tooth and periodontium within 12 to 18 weeks after immediate removal of the mini implant[10].

The stability of mini implants is achieved through primary mechanical retention between the surface of the mini implant and the cortical bone, with the healing process of the surrounding tissue providing secondary stability[17]. Primary stability is important to minimize the potential for failure due to micro-movement, and secondary stability is related to the microstructure of the mini-implant surface[18]. After leveling and aligning the mandibular arch to begin the distalization process, nickel-titanium closed springs or elastomeric chains with a force of 200–350 g can be placed between the mini implant and a crimpable hook attached to the lower arch[5]. It is recommended that traction be applied with forces as parallel as possible. To do this, the height of *the hook* and the force vector that will determine the control of forces in

the occlusal plane must be considered[4]. The objective of this case is to present a non-surgical treatment technique for patients with a Class I maxillomandibular relationship with a Class III tendency.

CLINICAL CASE PRESENTATION

A 13-year-old female patient with a Class I maxillomandibular relationship and a Class III tendency presented to the clinic. While obtaining her medical history, she did not report any apparent pathological data. The extraoral examination revealed a straight profile, enlarged lower third, neutral smile, and non-coincident facial and dental midlines (Figure 1). Dentally, she presented with Angle Class III molar relationship, Class III canine relationship, left posterior crossbite, tooth #22 in crossbite, moderate upper and lower crowding, and dental midline deviation (Figure 2).

Figure 1. Initial extraoral photographs.

Figure 2. Initial intraoral photographs.

Analysis of the initial panoramic radiograph revealed the formation process of teeth 18, 28, 38, and 48. The cephalometry confirmed a skeletal Class I relationship with a Class III tendency

due to ANB values of 1°, Ricketts convexity of 0.9°, Witts of -3.9°, long mandibular body, upper dental proclination, and dental biprotrusion. A vertical growth pattern was present (Figure 3. A-B, Table 1). The treatment objectives were to achieve bilateral molar and canine Angle Class I, eliminate the left posterior crossbite, correct the crossbite of tooth #22, achieve adequate overjet and overbite, center the midlines, correct the inclination of the upper and lower incisors, eliminate crowding, and obtain a functional and stable occlusion.

Table 1. Initial and final cephalometric values

Parameter	Standard	Initial values	Final values
SNA	80° ± 5°	80	82
SNB	78 ± 5°	79	80
ANB	2	1	2
Wits	-3 to +3	-3.9 mm	-3.2 mm
Ricketts' convexity	2° ± 2°	0.9	1.4
SN-GoGn	32	36°	39
IMPA	90° ± 5°	91	95
Upper incisor with SN	102° ± 2°	114°	112th

Figure 3. Imaging studies. A. Lateral head film.
B. Panoramic radiograph. C. Posteroanterior radiograph.

Treatment began with the bonding of interactive self-ligating CCO fixed upper and lower appliances with a 0.022" x 0.028" slot, starting the alignment and leveling phase with a 0.014" Sentalloy® (Dentsply Sirona) archwire; resin occlusal stops were placed on the upper first molars to open the bite, and early triangular elastics were used between the upper second premolars and lower premolars with 2 oz of pressure. At 8 weeks, a 0.018" Sentalloy® archwire (Dentsply Sirona) was placed in the upper and lower arches, and the occlusal stops were progressively removed between appointments.

At week 12, a 0.017" x 0.025" NiTi archwire was placed in the upper and lower arches, and at week 17, a 0.017" x 0.025" SS archwire was placed in the upper and lower arches. At 32 weeks of treatment, the placement of 2 mm in diameter x 12 mm in length (TD - Implants) mini implants in the mandibular shelf was planned. The process began with the placement of mini implants under anesthesia. For correct placement, the interdental area of the first and second molars, 2 mm below the mucogingival junction was used as a reference. The self-drilling mini implant

was placed at a 90° angle to the occlusal plane. After the initial drilling, a notch was created in the bone, and the implant was inserted approximately 2 mm. The direction of the mini implant was then changed to 70° in relation to the molars, which helped to avoid contact with the dental roots. The patient was asked to undergo a postero-anterior X-ray to assess the correct placement of the mini implants (Figure 3. C).

In week 36, the implants were loaded with elastic chains directed from the head of the mini implant to a crimpable hook located mesial to the lower canines with a force of 7 oz on each side (Figure 4). Eight weeks after activation of the mini implants, a left Class I molar and canine relationship was achieved, so distalization of the right side was maintained. On the left side, a 0.10" metal ligature twisted tie was placed from the head of the mini implant to the crimpable hook to maintain the results obtained and control distalization on the opposite side. Once bilateral Class I molar and canine were achieved, treatment was held static for 4 weeks to consolidate the occlusion. Subsequently, a 0.019" x 0.025" SS (Dentsply Sirona) upper and lower archwire was placed for 4 weeks. Upon reaching the final detailing and finishing phase, brackets of teeth #22 and #42 were repositioned, lowering the archwire caliber to 0.017" x 0.025" NiTi. One month later, a 0.019" x 0.025 NiTi upper and lower archwire was used. Once root parallelism was achieved, a 0.019" x 0.025" braided archwire (Dentsply Sirona) was placed on the upper arch. Short triangular settling elastics were used bilaterally for three weeks. The first ones were placed with their apex on the upper canine and their base on the lower canine and first premolar; the second ones were placed with their apex on the upper first premolar and their base on the lower first premolar and second premolar; and the third ones were placed with their apex on the upper second premolar and their base on the lower second premolar and first molar, with a force of 1/8" 6 ½ Oz (American Orthodontics) (Figure 5. A-B).

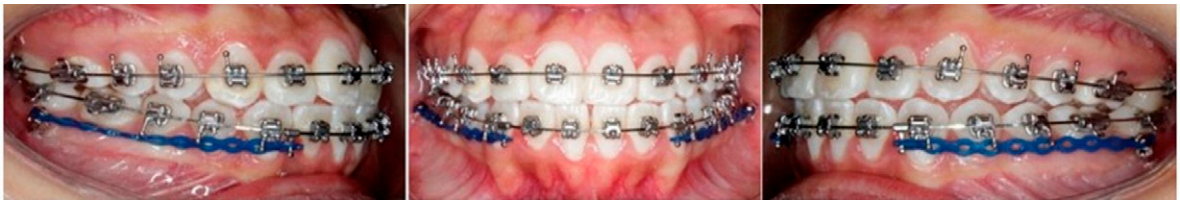

Figure 4. Start of full lower arch traction with mini implants.

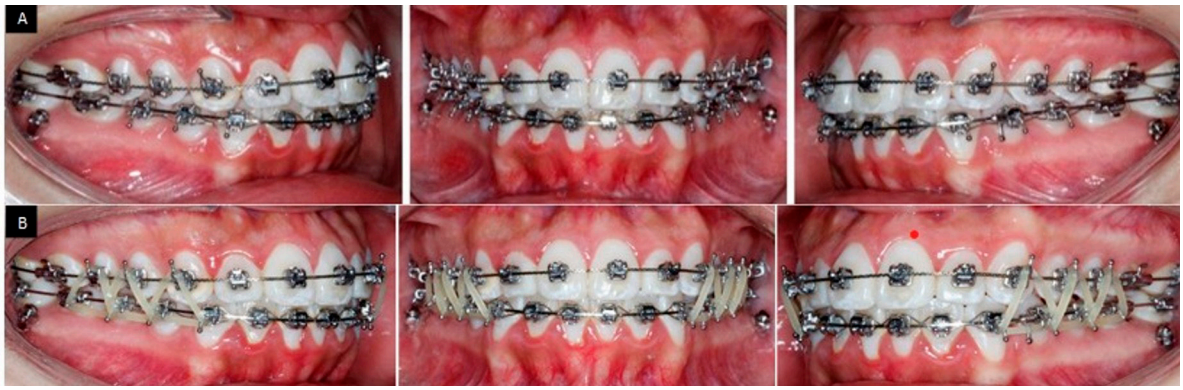

Figure 5. Treatment progress. A. Final settling phase. B. Placement of intermaxillary elastics.

After 58 weeks of active treatment, the two mini implants located in the mandibular shelf were removed, as were the upper and lower fixed appliances. For fixed lower canine-to-canine retention, a TRI-FLEXX (Bioray) Type 2 lingual titanium braided wire was placed and cemented with fluid resin (Figure 6). For removable retention, upper and lower *Hawley* retainers were placed, with the recommendation that they be worn throughout the day for the first six months.

Figure 6. Final intraoral photographs.

The final result was a balanced profile, soft tissue harmony (Figure 7), Angle molar Class I, bilateral canine Class I, adequate overjet and overbite, correction of left posterior crossbite and of tooth #22, and excellent intercuspation and functionality. The posterior crossbite was corrected by expanding the upper arch, given the archwire shape. The panoramic radiograph showed good root parallelism and apical flattening of teeth 15, 14, 24, and 25. The final lateral head film showed a skeletal Class I consolidation with a 2° SNA, Ricketts convexity of 1.4°, Wits of -3.2 mm, and a vertical growth pattern (Figure 8. A-C) (Table 1).

The superimposition cephalometry showed a slight clockwise rotation of the mandible, as well as an increase in lower height. There was a distalization of the first lower molar of approximately 3 mm, retroinclination of the upper incisors, proinclination of the lower incisors, and improved projection of soft tissues such as the chin and lower lip (Figure 8. C, Table 1).

DISCUSSION

The amount of movement that can be achieved with distalization of the lower molars, according to the study conducted by Saito *et al.*[18] in dogs, was 1.8 mm to 10.7 mm. These results reflect the range of displacement achievable in posterior teeth during the distalization process, helping to understand the limitations and possibilities of this procedure. In other reports, the average amount of distalization with plates and mini implants of the first mandibular molars was 3.5 mm at the crown level and 1.8 mm at the root level. The average amount of relapse was 0.3 mm at both the apex and the crown.[19] In one case report, the mandibular posterior teeth were distalized 6 mm and 4 mm on the right and left sides, respectively. Jing *et al.*[19] reported 4

mm of distalization without any relapse. These values are similar to those found in this clinical case, where a bilateral distalization of 3 mm of the lower arch was obtained[20].

Figure 7. Final extraoral photographs.

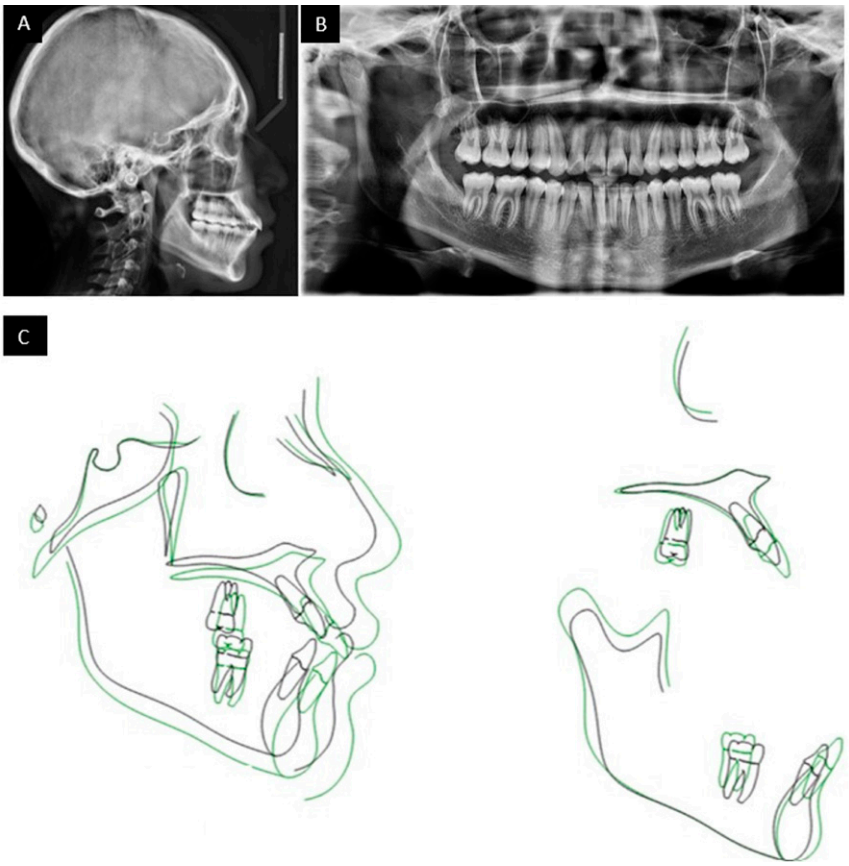

Figure 8. Final imaging studies. A. Lateral head film. B. Panoramic radiograph. C. Cephalometric superimposition before treatment (black line) and after treatment (green line).

Sugawara *et al.*[21] used a technique to distalize lower molars using titanium plates and monocortical mini implants that were temporarily placed in the bone for distalization[19]. The placement of mini implants in the retromolar area and segmented distalization of molars and premolars to avoid a *round-trip* effect of the incisors has also been reported[22]. This technique is similar to that used by de Lima *et al.*[2] in a case report where first premolars were extracted, and mini

implants were used in the retromolar area to correct a Class III malocclusion[2]. Jing *et al.*[19] reported the correction of Class III using implants in the mandibular shelf and full arch distalization using elastic chains directed from the mini implant to a crimpable hook[22]. In this clinical case report, a similar technique was used in which two mini implants were inserted into the external mandibular ridge, and distalization was performed with elastic chains directed from the implant head to a crimpable hook located mesial to the lower canine.

In a clinical case report by *Gosh et al.*[4] in which full lower arch distalization was performed with 12 mm mini implants in the external mandibular ridge, a Wits angle of -6.5 mm to -5 mm was obtained, as well as an increase in the ANB angle from -2° to 0°, and an increase in the SN plane – mandibular plane from 28° to 30°[3]. These data are similar to those obtained in this study, where a Wits angle of -3.9 mm to -3.2 mm was obtained, an increase in the ANB angle from 1° to 2°, and an increase in the SN plane – mandibular plane from 36° to 39°. In this case report, the anteroposterior maxillomandibular discrepancy was mild; therefore, mini implants were considered a good anchorage unit to resolve the malocclusion quickly, effectively, and without a high need for patient cooperation. Based on a review of the literature, it was decided to place mini implants for distalization of the lower arch, located bilaterally on the mandibular shelf. The process was observed to be rapid and very controlled.

In this clinical case, three treatment options were considered. The first consisted of extracting the upper and lower first premolars to achieve a bilateral Class I molar and canine relationship, improving the inclination of the upper and lower incisors. The second was to distalize the molars using Gurin stops with springs or a *York* appliance to achieve a Class I molar relationship and then distalize the lower anterior segment until a Class I canine relationship was achieved. The third was to use mini implants in the mandibular ridge to provide absolute anchorage and distalize the entire lower arch. This option was chosen for its biomechanical benefits, final results, and shorter treatment time.

CONCLUSIONS

In this clinical case report, the use of mini implants in the mandibular shelf for distalization of the complete lower arch in a patient with a Class I relationship with a tendency toward Angle Class III proved to be efficient. Good facial harmony of soft tissues and a functional, aesthetic, and stable occlusion were achieved. The aesthetic and functional changes were positively accepted by the patient. She stated that her expectations were satisfactorily met. When performing complete arch distalization, we recommend using both a removable wrap-around retainer and a fixed retainer, with simultaneous bilateral occlusion. Class III intermaxillary elastics applied to a splint-type retainer with hooks for nighttime use may be a good alternative to conventional retention methods.

BIBLIOGRAPHIC REFERENCES

1. de Angelo BL, Nogueira WA. Tratamento de Classe III com mini-implantes extra alveolares: buccal shelf. *J Multidiscip Dent*. 2022; 12(2): 93-99. DOI: https://doi.org/10.46875/jmd.v12i2.1102
2. de Lima E, Brum F, Mezomo M, Pasquali CE, Farret M. Orthodontic treatment of Class III malocclusion with lower extraction and anchorage with mini implants: Case report. *J World Fed Orthod*. 2017; 6(1): 28-34. DOI: https://doi.org/10.1016/j.ejwf.2017.02.003

3. Farret MM, Benitez Farret MM. Skeletal class III malocclusion treated using a non-surgical approach supplemented with mini-implants: a case report. *J Orthod.* 2013; 40(3): 256-263. DOI: https://doi.org/10.1179/1465313313y.0000000046
4. Ghosh A. Infra-zygomatic crest and buccal shelf-orthodontic bone screws: a leap ahead of micro-implants – clinical perspectives. *J Indian Orthod Soc*. 2018; 52(4 suppl 2): 127-141. DOI: https://doi.org/10.4103/jios.jios_229_18
5. Abhijith A, Sahu A, Ranjan R, Roy S, Priya P, Goswami M. Evaluation of mandibular buccal shelf area for mini screw placement in different sagittal and vertical skeletal pattern: a CBCT study. *J Pharm Bioallied Sci.* 2024; 16(Suppl 4): S3986-S3991. DOI: https://doi.org/10.4103/jpbs.jpbs_669_24
6. Monnerat C, Restle L, Mucha JN. Tomographic mapping of mandibular interradicular spaces for placement of orthodontic mini-implants. *Am J Orthod Dentofacial Orthop.* 2009; 135(4): 428-429. DOI: https://doi.org/10.1016/j.ajodo.2008.12.003
7. Liu Y, Yang ZJ, Zhou J, Xiong P, Wang Q, Yang Y, *et al*. Comparison of anchorage efficiency of orthodontic mini-implant and conventional anchorage reinforcement in patients requiring maximum orthodontic anchorage: a systematic review and meta-analysis. *J Evid Based Dent Pract.* 2020; 20(2): 101401. DOI: https://doi.org/10.1016/j.jebdp.2020.101401
8. Liu H, Wu X, Tan J, Li X. Safe regions of miniscrew implantation for distalization of mandibular dentition with CBCT. *Prog Orthod*. 2019; 20(1): 45. DOI: https://doi.org/10.1186/s40510-019-0297-6
9. Chung K, Kim SH, Kook Y. C-orthodontic microimplant for distalization of mandibular dentition in Class III correction. *Angle Orthod*. 2005; 75(1): 119-128. DOI: https://doi.org/10.1043/0003-3219(2005)075%3C0119:CMFDOM%3E2.0.CO;2
10. Asscherickx K, Vannet BV, Wehrbein H, Sabzevar MM. Root repair after injury from mini-screw. *Clin Oral Implants Res.* 2005; 16(5): 575-578. DOI: https://doi.org/10.1111/j.1600-0501.2005.01146.x
11. Chang C, Liu SSY, Roberts WE. Primary failure rate for 1680 extra-alveolar mandibular buccal shelf mini-screws placed in movable mucosa or attached gingiva. *Angle Orthod.* 2015; 85(6): 905-910. DOI: https://doi.org/10.2319/092714.695.1
12. Elshebiny T, Palomo JM, Baumgaertel S. Anatomic assessment of the mandibular buccal shelf for miniscrew insertion in white patients. *Am J Orthod Dentofacial Orthop*. 2018; 153(4): 505-511. DOI: https://doi.org/10.1016/j.ajodo.2017.08.014
13. Eto VM, Figueiredo NC, Eto LF, Azevedo GM, Silva AIV, Andrade I Jr. Bone thickness and height of the buccal shelf area and the mandibular canal position for miniscrew insertion in patients with different vertical facial patterns, age, and sex. *Angle Orthod.* 2023; 93(2): 185-194. DOI: https://doi.org/10.2319/060822-412.1
14. Baumgaertel S. Predrilling of the implant site: Is it necessary for orthodontic mini-implants? *Am J Orthod Dentofacial Orthop.* 2010; 137(6): 825-829. DOI: https://doi.org/10.1016/j.ajodo.2008.06.038
15. Papadopoulos MA, Papageorgiou SN, Zogakis IP. Clinical effectiveness of orthodontic miniscrew implants: A meta-analysis. *J Dent Res.* 2011; 90(8): 969–76. DOI: https://doi.org/10.1177/0022034511409236
16. Chung KR, Kim SH, Choo HR, Kook YA, Cope JB. Distalization of the mandibular dentition with mini-implants to correct a Class III malocclusion with a midline deviation. *Am J Orthod Dentofacial Orthop.* 2010; 137(1): 135-146. DOI: https://doi.org/10.1016/j.ajodo.2007.06.023
17. Kravitz ND, Kusnoto B. Risks and complications of orthodontic miniscrews. *Am J Orthod Dentofacial Orthop.* 2007; 131(4): S43-S51. DOI: https://doi.org/10.1016/j.ajodo.2006.04.027
18. Saito S, Sugimoto N, Morohashi T, Ozeki M, Kurabayashi H, Shimizu H, *et al*. Endosseous titanium implants as anchors for mesiodistal tooth movement in the beagle dog. *Am J Orthod Dentofacial Orthop.* 2000; 118(6): 601-607. DOI: https://doi.org/10.1067/mod.2000.110636

19. Jing Y, Han X, Guo Y, Li J, Bai D. Nonsurgical correction of a Class III malocclusion in an adult by miniscrew-assisted mandibular dentition distalization. *Am J Orthod Dentofacial Orthop*. 2013; 143(6): 877-887. DOI: https://doi.org/10.1016/j.ajodo.2012.05.021
20. Park HS, Jeong SH, Kwon OW. Factors affecting the clinical success of screw implants used as orthodontic anchorage. *Am J Orthod Dentofacial Orthop*. 2006; 130(1): 18-25. DOI: https://doi.org/10.1016/j.ajodo.2004.11.032
21. Sugawara J, Daimaruya T, Umemori M, Nagasaka H, Takahashi I, Kawamura H, *et al*. Distal movement of mandibular molars in adult patients with the skeletal anchorage system. *Am J Orthod Dentofacial Orthop*. 2004; 125(2): 130-138 DOI: https://doi.org/10.1016/j.ajodo.2003.02.003
22. Poletti L, Silvera AA, Huanca Ghislanzoni LT. Dentoalveolar class III treatment using retromolar miniscrew anchorage. *Prog Orthod*. 2013; 14(1): 7. DOI: https://doi.org/10.1186/2196-1042-14-7