Revista Odontológica Mexicana
Órgano Oficial de la Facultad de Odontología UNAM

Clinical case

Correction of Class II Edge-to-Edge Maloclussion with Micro-implants. Case Report

Stefany Annabel Cevallos-Luna[1], Francisco Javier Marichi-Rodríguez[2]

1. Egresada de la especialidad de Ortodoncia. División de Estudios de Posgrado e Investigación, Facultad de Odontología, Universidad Nacional Autónoma de México.
2. Director de la Facultad de Odontología, Universidad Nacional Autónoma de México. https://orcid.org/0009-0007-2541-4399

Correspondence author:
Stefany Annabel Cevallos-Luna
E-mail: tefy_121@hotmail.com

Received: 4 July 2024
Accepted: 29 September 2025

Cite as:
Cevallos-Luna SA, Marichi-Rodríguez FJ. Corrección de maloclusión Clase II borde a borde con utilización de microimplantes. Reporte de un caso [Correction of Class II Edge-to-Edge Maloclussion with Micro-implants. Case Report]. *Rev Odontol Mex*. 2025; 29(4): 34-43. DOI: 10.22201/fo.1870199xp.2025.29.4.94457

ABSTRACT

Introduction: In orthodontic practice, the use of micro-implants as skeletal anchorage has increased in recent years. Orthodontists have noncompliant patients, slow treatments, and the undesirable effects that occur in tooth movement with conventional treatments. Therefore, simplifying orthodontic mechanics, reducing treatment time, and not depending completely on the patient are strategies for success with the use of these appliances. **Objective:** To achieve the correction of the Class II malocclusion in the shortest possible time with micro-implants. **Case presentation:** A 12-year-old female patient attended the Clinic of Postgraduate Orthodontics-UNAM for orthodontic treatment. Her initial treatment plan consisted of a conventional

Universidad Nacional Autónoma de México. Revista Odontológica Mexicana Órgano Oficial de la Facultad de Odontología UNAM. ISSN 1870-199X. Se distribuye bajo una Licencia Creative Commons Atribución-NoComercial-SinDerivar 4.0 Internacional. Vol. 29, Núm. 4, Octubre-Diciembre 2025: 34-43.

mechanic of passive self-ligating braces without extractions. However, due to the prolonged treatment time, it was decided to include infrazygomatic micro-implants for anterior retraction, and the objectives were achieved in a relatively short time. **Conclusions:** An orthodontic treatment with micro-implants considerably reduces the treatment time, and reduces the adverse effects on the mechanics of distalization and anterior retraction.

Keywords: infrazygomatic micro-implants, anterior retraction, CII correction.

INTRODUCTION

Skeletal Class II (CII) patients have alterations in their facial function and aesthetics. In general, the facial profile is convex, with poor jaw development and narrow airways. Most of them show Class II molar and canine characteristics, increased overjet, and negative bone-tooth discrepancy, among others. Therefore, anchorage control in orthodontic mechanics for this type of patient is a challenge for the orthodontist, as the undesirable effects of anchorage loss must be minimized.

There are different types of anchorage control treatments for CII patients. These include intraoral (transpalatal arch), extraoral (headgear), dental (intermaxillary ligatures), and skeletal (microimplants). All have advantages and disadvantages. The disadvantages include increased overjet and overbite, molar mesialization, and increased treatment time, among others. Orthodontic microimplants, being a type of skeletal anchorage and located in the bone, greatly reduce the aforementioned disadvantages. The area of choice for placing microimplants depends on the mechanics to be performed. For example, in the distalization of the anterior segment, the infrazygomatic area is preferred, since the roots of the molars do not interfere with the sliding movement of the teeth[1].

A systematic review by Antoszewska-Smith *et al.*[2] compared the effectiveness of conventional anchorage and microimplants, demonstrating that *en-masse* retraction of the anterior segment with microimplants is more effective, with an 87% success rate, compared to conventional methods. Similarly, Deguchi *et al.*[3], compared patients treated with and without microimplants, finding that those treated with microimplants had a significant difference in the reduction of profile convexity and inferior labial sulcus angle. On the other hand, certain cases require maxillofacial surgery; for example, there are cases of anterior open bite treated without microimplants that have been surgical, due to skeletal or soft tissue discrepancy; however, the use of microimplants for posterior intrusion has provided a compensatory alternative, thus avoiding orthognathic surgery. Sherwood *et al.*[4] point out that, in patients who are candidates for surgery, this can be avoided by using techniques that employ microimplants.

Therefore, the objective of this clinical case was to achieve correction of a Class II malocclusion in the shortest time possible with orthodontic microimplants. To this end, it should be noted that some orthodontic treatments for Class II malocclusion lead to the extraction of premolars, while in cases where no extractions are performed, maxillary distalization and mandibular mesialization are used.

CLINICAL CASE PRESENTATION

A 12-year-old female patient presented to the Department of Orthodontics of the Division of Post-Graduate Studies and Research (DEPeI) of the Faculty of Dentistry at UNAM (Universidad Nacional Autónoma de México). The main reason for consultation was "*I want to fix my teeth so they don't look* bad," for orthodontic treatment for dental crowding and supraocclusion of the upper canines.

Clinical analysis revealed that the patient had a symmetrical oval face, competent lips, a convex profile, and lip biprotrusion. The facial pattern was dolichofacial, with a neutral, short smile, and the dental midline coincided with the facial midline (Figure 1. A). The intraoral analysis identified a bilateral canine class that could not be assessed because teeth 13 and 23 were in supraocclusion, with a bilateral molar crossbite; severe upper and mild lower crowding, non-coincident dental midlines, as well as dental biprotrusion and tongue thrusting (Figure 1. B). The lateral headfilm showed a skeletal Class II due to maxillary protrusion with a vertical growth tendency (Figure 1. C). The panoramic radiograph identified a 1:2 crown-root ratio in all teeth, condyles, and mandibular ramus with apparent symmetry in morphology and position, as well as the presence of tooth buds of 18, 28, 38, and 48 (Figure 1. D). The initial treatment plan consisted of a passive self-ligating system without extractions.

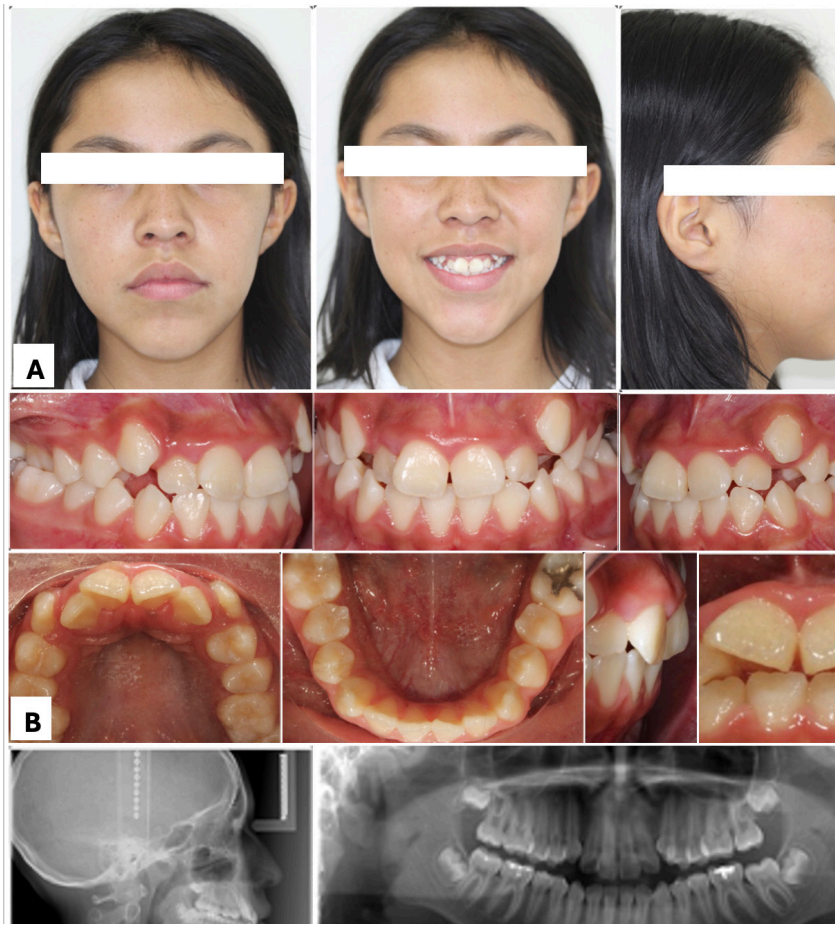

Figure 1. Initial findings. A. Extraoral photographs, front, smiling, and right side. B. Intraoral photographs. C. Lateral headfilm. D. Panoramic radiograph.

In phase 1, treatment began with alignment and leveling; fixed appliances and 0.014" broad TA archwires were placed, and short, light elastics were prescribed from the upper canine to the lower canine on both sides (Figure 2. A), followed by 0.018" broad TA upper archwires and 0.014"x0.025" broad TA lower archwires. The patient had poor hygiene and several brackets came loose between appointments. Because of this, it was decided to use bands with bonded tubes on teeth 16 and 26, while at the same time prescribing the use of cross elastics on brackets 24, 25, 26, and 27, along with 0.018" x 0.025" broad TA upper and lower archwires. Phase 1 lasted 32 months, extending longer than planned. With conventional mechanics, treatment progress was limited. Added to this was the patient's lack of cooperation, which resulted in a delay in treatment. Therefore, intraoral photographs were taken to reassess the case (Figure 2. B).

Figure 2. Intraoral photographs of phase 1. A. Start. B. 32 months of treatment.

In the re-evaluation of the case, it was observed that the patient maintained both the tongue habit and the convex and protrusive profile (Figure 3. A). Likewise, the overbite became edge-to-edge with non-coinciding midlines, and the canine relationships remained in CII (Figure 3. B). Due to the poor results obtained, a new treatment alternative was chosen, which consisted of placing 2 x 12 mm surgical grade stainless steel TD® microimplants in the infrazygomatic area

to facilitate the necessary anchorage in the new phase of treatment, in addition to achieving retraction of the upper arch, correcting the deviation of the midlines, and reducing the patient's profile. The placement technique was simple and quick, following asepsis and antisepsis of the area with a gauze impregnated with 0.12% chlorhexidine. Subsequently, local anesthesia was administered using ¼ tube of 2% lidocaine. Once the area was anesthetized, a puncture was made at the site where the microimplant would be placed using cotton forceps. The microimplant was inserted at a 90° perpendicular angle and screwed in manually using the universal *handle* (microimplant holder). During insertion, a slight upward movement of 45° was made, maintaining constant force and controlled threading to ensure stable insertion (Figure 4. A). Each microimplant was successfully placed. Since the infrazygomatic area is far from the tooth roots, there was no risk of perforating any roots. To verify the correct placement of the microimplants, a posteroanterior radiograph was taken, which confirmed that there was no contact with or damage to the roots. The radiographic image showed accurate and secure placement of both microimplants in the infrazygomatic region (Figure 4. B). In addition, lingual spurs were used to correct the persistent tongue thrusting, and the leveling phase was resumed using 0.018" broad TA upper and lower archwires.

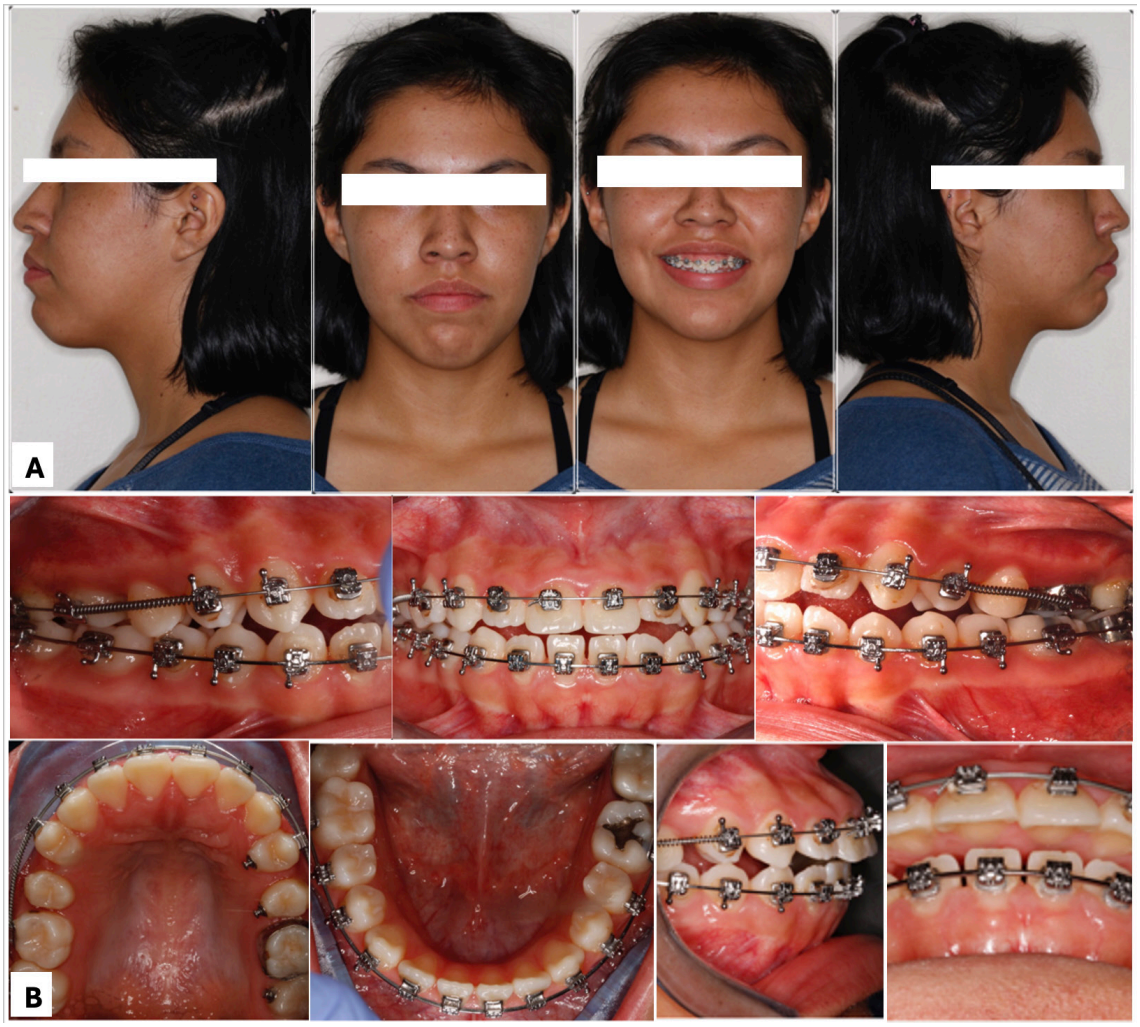

Figure 3. Reassessment of the case. A. Extraoral photographs, left side, front, smiling, and right side. B. Intraoral photographs.

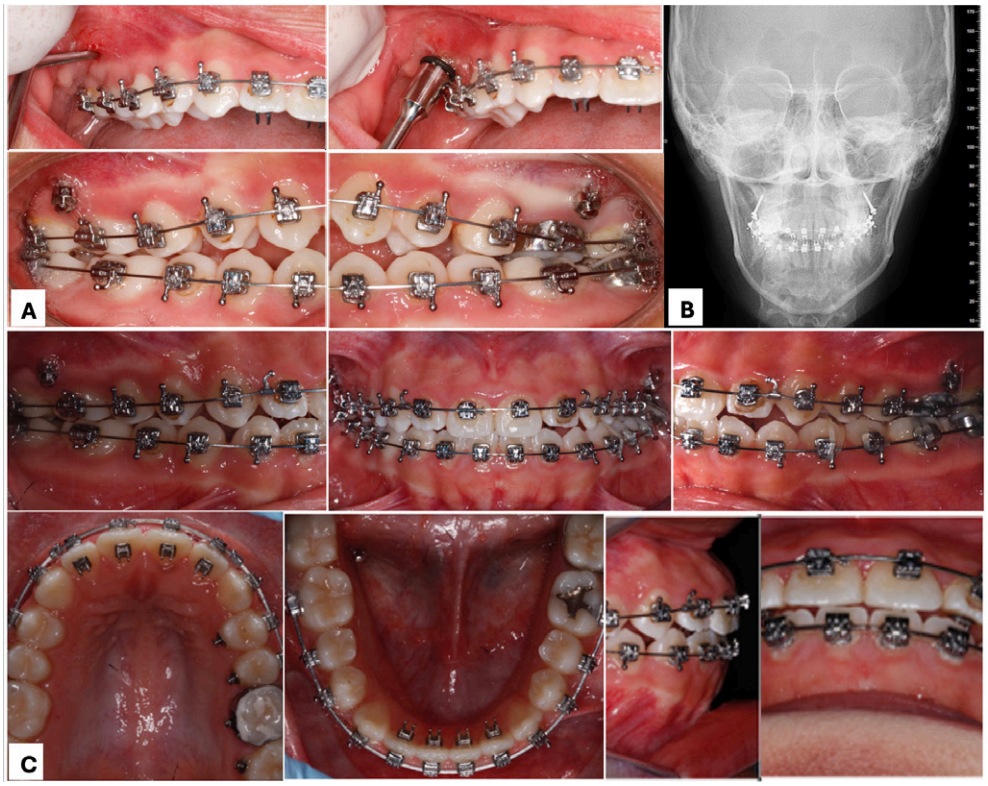

Figure 4. Placement of infrazygomatic microimplants – Case evolution. A. Sequence of microimplant placement. B. Posteroanterior control radiograph. C. Intraoral photographs of phase 2 of treatment.

During the working phase, arch coordination and space closure were performed using 0.014" x 0.025" TA archwires in both arches. At this stage, the use of microimplants was optimized, initiating retraction of the anterior segment. To do this, passive elastic chains were used, connecting the microimplants to the crimpable *hooks*, applying an initial force of 8 oz per side. The force was gradually increased by 2 oz each month until reaching 14 oz in the fourth month of treatment, at which point the change to 0.018" x 0.025" TA upper and lower archwires was made to continue controlling tooth movement (Figure 4.C). The total duration of this phase was four months.

In the final phase, detailing, settling, and orthodontic retention procedures were performed. It was also decided to refer the patient to the periodontics department for evaluation of gingivectomy in the upper and lower anterior sectors (Figure 5. A-B). During this stage, 0.017" x 0.025" BT archwires with positive individual torque on brackets 26 and 27 and negative torque on bracket 37 were used to stabilize the roots within the bone. Upper and lower 7-7 closed chains were placed, complemented by the use of 5/16 3oz Z-shaped anterior and posterior settlement elastics to improve occlusal engagement. Final extraoral photographs were taken (Figure 6. A). After achieving all the objectives set with the microimplants, the appliances were removed and the respective orthodontic retainers were placed: a removable circumferential retainer in the upper arch and a fixed retainer in the lower arch (Figure 6. B). The final occlusal adjustment was performed, verifying the correct function of the bilateral canine guides (Figure 6. C). Finally, postoperative control radiographs were taken: lateral headfilm (Figure 7. A) and panoramic radiograph (Figure 7. B), for cephalometric superimposition. This comparison clearly

showed the retraction of the anterior segment, attributed to the effective use of microimplants in the infrazygomatic region (Figure 7. C).

Figure 5. Gingivectomy. A. Upper. B. Lower.

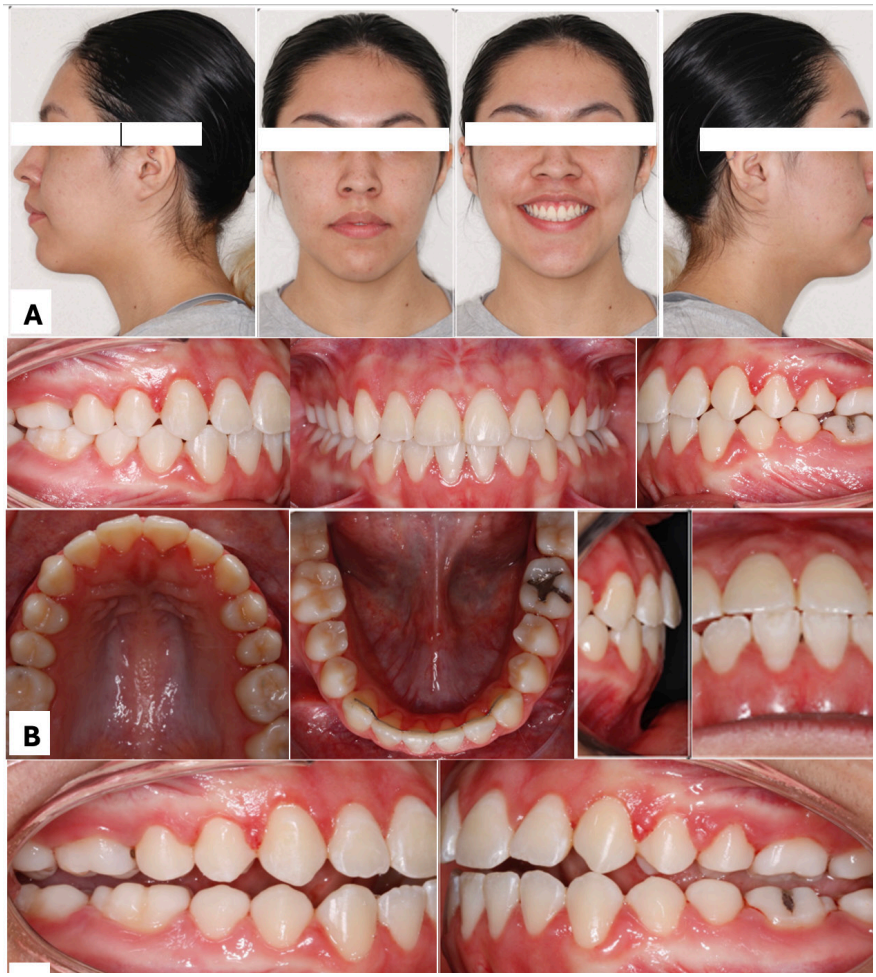

Figure 6. Final photographs. A. Extraoral, left lateral, front, smiling, and right lateral. B. Intraoral photographs. C. Posterior disocclusion and right-left laterality.

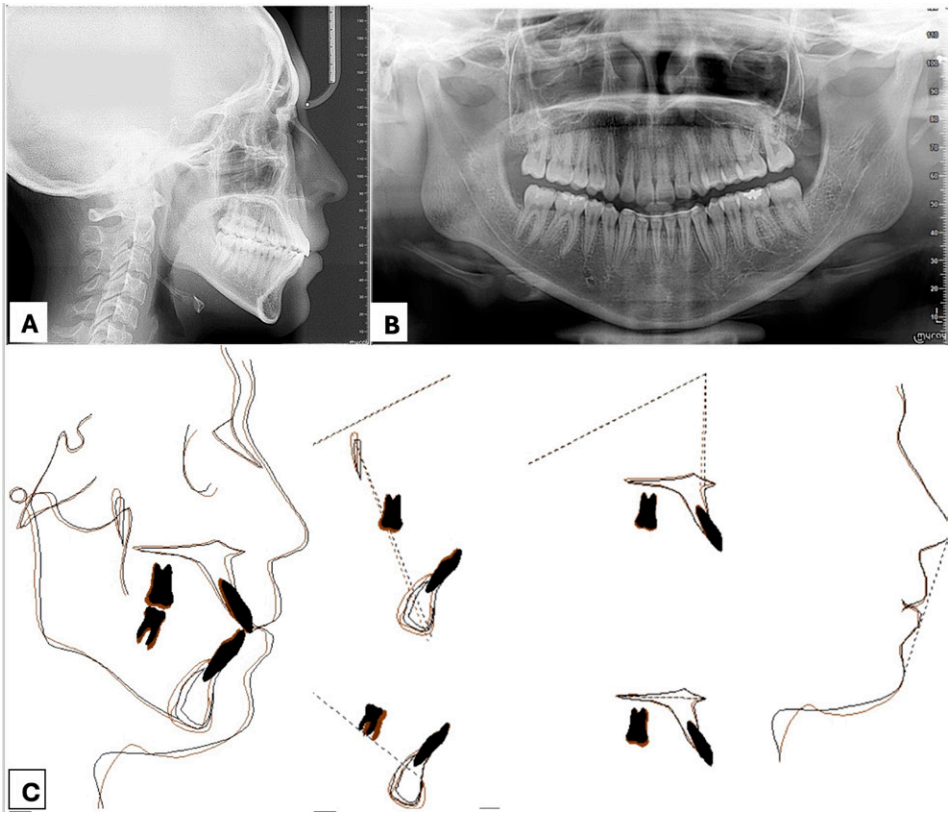

Figure 7. Final radiographs. A. Lateral headfilm. B. Panoramic radiograph. C. Cephalometric superimposition, pretreatment (black line), post-treatment (orange line).

DISCUSSION

Aly *et al.*[5] indicated that microimplants have an 82% success rate, making them a viable option in orthodontic treatments. Similarly, Moon *et al.*[6] reported an overall average success rate of 83% with microimplants. According to Arnett and Bergman[7], *"the diagnosis is the definition of the problem, the treatment plan* is *the program to change that problem, and the treatment* is *the execution of the plan."* In this case, retraction of the anterior segment using conventional mechanics took 32 months, while with skeletal anchorage and microimplants, it was achieved in four months.

The failure of microimplants remains a challenge for orthodontists. Among the most common complications are damage to the roots of adjacent teeth or periodontal ligaments, microimplant fracture, lack of professional skill, etc. However, the literature shows that solutions have been adapted for each of these challenges, such as the use of guides for microimplant placement and the choice of areas away from the teeth, such as the infrazygomatic area and the mandibular shelf, among others[8.] In this patient, there was no failure of the microimplants, since the chosen area, the infrazygomatic crest, did not pose a placement problem, and the microimplants remained stable throughout the retraction mechanism.

In conventional mechanics, *tipping* and *roller coaster* effects are generated by the application of force away from the center of resistance[9]. In this regard, Benson *et al.*[10] mention that the average loss of anchorage is twice as high with headgear as with microimplants, at approximately 1.3-2 mm. Other treatment alternatives such as transpalatal arches, Nance buttons, or various orthodontic systems can replace it; however, microimplants continue to be more successful. As with distalization in Class II malocclusions, the headgear has a higher relapse rate than microimplants, with the latter providing 71% molar distalization and 29% reciprocal anchorage loss. Although retention is certainly not required to prevent skeletal relapse, it is required for dental recurrence[11]. The use of extraoral appliances for anchorage must consider four parameters: anchorage loss due to mesial movement of the first premolars, incisor inclination, the distalization effect of the first molars when the second molars have not erupted, and patient cooperation[12]. In this case, the patient was non-compliant, so the use of microimplants as skeletal anchorage facilitated the achievement of the anterior segment retraction.

Orthodontics without microimplants remains a valid option. Chhibber *et al.*[13] presented a case treated with conventional orthodontics without microimplants in a 19-year-old female patient with skeletal and dental Class II malocclusion, loss of teeth 36 and 46, moderate crowding, incisor proinclination, and a convex profile. The objective of the case was to verticalize and mesialize teeth 37 and 47 toward the site of the first molars (36 and 46). A cantilever was used for verticalization, and retroligatures were used for mesialization, including a Forsus to reinforce the anchorage. Microimplants were not used due to the risk of damaging adjacent roots and patient rejection. The treatment lasted 28 months, and verticalization and protraction of teeth 37 and 47 into the space of the first molars was achieved.

Mariani *et al.*[14] conducted a retrospective study of 57 patients with skeletal and dental Class II to investigate the dentoalveolar and skeletal effects of using microimplants (30 patients) versus pendulum (27 patients). No extractions were performed, and all patients were in the growth phase. The result was that in patients treated with microimplants, molar distalization was 4.9 mm in 7 months, while in patients treated with pendulum appliances it was 2.9 mm in 9 months. In addition, the amount of molar relationship correction in patients with microimplants was 5.9 mm, while in patients with pendulum appliances it was 4.9 mm. Anterior anchorage loss occurred in both groups; therefore, both appliances work.

CONCLUSIONS

The use of skeletal anchorage in orthodontics is an effective tool, both in the precise control of tooth movement and in reducing treatment time. The effectiveness of anterior segment retraction with microimplants was reflected in the patient's soft profile, satisfactorily reducing profile convexity and lip biprotrusion in a relatively short clinical period. The importance of correct diagnosis, together with an appropriate treatment plan and the selection of the right orthodontic mechanics, is vital to avoid delays in treatment and complications in orthodontic cases. It is important to note that in treatment with microimplants, patient cooperation is essential, as is adherence to treatment objectives. While conventional orthodontic treatments remain viable and effective, current clinical and scientific evidence indicates that the use of microimplants improves biomechanical control and significantly shortens treatment times.

BIBLIOGRAPHIC REFERENCES

1. Uslu-Akcam MO, Efendiyeva R, Akcam MO. Treatment of anterior open-bite using zygomatic anchorage: a 10-year follow-up case report. *Aust. Orthod. J*. 2020; 36(2): 211-219. DOI: 10.21307/aoj-2020-024
2. Antoszewska-Smith J, Sarul M, Łyczek J, Konopka T, Kawalaa B. Effectiveness of orthodontic miniscrew implants in anchorage reinforcement during en-masse retraction: a systematic review and meta-analysis. *Am J Orthod Dentofacial Orthop*. 2017: 151(3): 440-445. DOI: 10.1016/j.ajodo.2016.08.029
3. Deguchi T, Kurosaka H, Oikawa H, Kuroda S, Takahashi I, Yamashiro T, *et al*. Comparison of orthodontic treatment outcomes in adults with skeletal open bite between conventional edgewise treatment and implant-anchored orthodontics. *Am J Orthod Dentofacial Orthop*. 2011; 139(4,Suppl): S60-S68. DOI: 10.1016/j.ajodo.2009.04.029
4. Sherwood KH, Burch JG, Thompson WJ. Closing anterior open bites by intruding molars with titanium miniplate anchorage. *Am J Orthod Dentofacial Orthop*. 2002; 122(6): 593-600. DOI: 10.1067/mod.2002.128641
5. Aly SA, Alyan D, Fayed MS, Alhammadi MS, Mostafa YA. Success rates and factors associated with failure of temporary anchorage devices: A prospective clinical trial. *J Invest Clin Dent*. 2018; 9(3): e12331. DOI: 10.1111/jicd.12331
6. Moon CH, Lee DG, Lee HS, Im JS, Baek SH. Factors associated with the success rate of orthodontic miniscrews placed in the upper and lower posterior buccal region. *Angle Orthod*. 2008; 78(1): 101-106. DOI: 10.2319/121706-515.1
7. Arnett GW, Bergman RT. Facial keys to orthodontic diagnosis and treatment planning. Part I. *Am J Orthod Dentofacial Orthop*. 1993; 103(4): 299-312. DOI: 10.1016/0889-5406(93)70010-L
8. Chen Y, Kyung HM, Zhao WT, Yu WJ. Critical factors for the success of orthodontic mini-implants: A systematic review. *Am J Orthod Dentofacial Orthop*. 2009; 135(3): 284-291. DOI: 10.1016/j.ajodo.2007.08.017
9. Dermaut LR, Kleutghen JPJ, De Clerck HJJ. Experimental determination of the center of resistance of the upper first molar in a macerated, dry human skull submitted to horizontal headgear traction. *Am J Orthod Dentofacial Orthop*. 1986; 90(1): 29-36. DOI: 10.1016/0889-5406(86)90024-7
10. Benson PE, Tinsley D, O'Dwyer JJ, Majumdar A, Doyle P, Sandler PJ. Midpalatal implants vs headgear for orthodontic anchorage—a randomized clinical trial: cephalometric results. *Am J Orthod Dentofacial Orthop*. 2007; 132(5): 606-615. DOI: 10.1016/j.ajodo.2006.01.040
11. Sa'aed NL, Park CO, Bayome M, Park JH, Kim Y, Kook YA. Skeletal and dental effects of molar distalization using a modified palatal anchorage plate in adolescents. *Angle Orthod*. 2015; 85(4): 657-664. DOI: 10.2319/060114-392.1
12. Cozza P, Baccetti T, Franchi L, De Toffol L, and McNamara JA. Mandibular changes produced by functional appliances in Class II malocclusion: a systematic review. *Am J Orthod Dentofacial Orthop*. 2006; 129(5): 599.e1-599e12. DOI: 10.1016/j.ajodo.2005.11.010
13. Chhibber A, Upadhyay M. Anchorage reinforcement with a fixed functional appliance during protraction of the mandibular second molars into the first molar extraction sites. *Am J Orthod Dentofacial Orthop*. 2015; 148(1): 165-173. DOI: 10.1016/j.ajodo.2015.02.029
14. Mariani L, Maino G, Caprioglio A. Skeletal versus conventional intraoral anchorage for the treatment of class II malocclusion: dentoalveolar and skeletal effects. *Prog Orthod*. 2014; 15(1): 43. DOI: 10.1186/s40510-014-0043-z