Revista Odontológica Mexicana
Órgano Oficial de la Facultad de Odontología UNAM

Clinical case

Management of Anterior Open Bite in a Biprotusive Patient with Mini-Implants: Clinical Case Report

Esperanza Lizbeth Huautla-Ortiz[1], Nancy Jeovanna Valadez-Alcántara[2], Francisco Javier Marichi-Rodríguez[3]

1. Egresada de la especialidad de Ortodoncia. División de Estudios de Posgrado e Investigación, Facultad de Odontología, Universidad Nacional Autónoma de México.
2. Egresada del diplomado Actualización en Ortodoncia Biológica Individualizada, Facultad de Odontología, Universidad Nacional Autónoma de México.
3. Director de la Facultad de Odontología, Universidad Nacional Autónoma de México. https://orcid.org/0009-0007-2541-4399

Correspondence author:
Esperanza Lizbeth Huautla Ortiz
E-mail: lizbeth.huautla@gmail.com

Received: 5 November 2024
Accepted: 24 September 2025

Cite as:
Huautla-Ortiz EL, Valadez-Alcántara J, Marichi-Rodríguez FJ. Manejo de mordida abierta anterior en paciente biprotusivo con mini-implantes: reporte de caso clínico [Management of Anterior Open Bite in a Biprotusive Patient with Mini-Implants: Clinical Case Report]. *Rev Odontol Mex*. 2025; 29(4): 23-33. DOI: 10.22201/fo.1870199xp.2025.29.4.94459

ABSTRACT

Introduction: Anterior skeletal open bite is one of the most complex malocclusions to treat with conventional orthodontics. Thanks to the use of mini-implants, it has been possible to obtain results very similar to those of orthodontic-surgical treatment. **Objective:** to present the clinical case of a class II patient with anterior open bite treated with orthodontics and mini-implants.

Universidad Nacional Autónoma de México. Revista Odontológica Mexicana Órgano Oficial de la Facultad de Odontología UNAM. ISSN 1870-199X. Se distribuye bajo una Licencia Creative Commons Atribución-NoComercial-SinDerivar 4.0 Internacional. Vol. 29, Núm. 4, Octubre-Diciembre 2025: 23-33.

Case presentation: 32-year-old female patient, with a cephalometric diagnosis of skeletal class II biprotrusive, hyperdivergent; dental diagnosis of left molar class I, canine class II, anterior open bite of -3 mm, non-coincident midlines; facially, she presents biprotrusive convex profile and lip incompetence. With lingual habit etiology and increased lower facial height. The orthodontic-surgical treatment, initially proposed, was rejected due to refusal of surgery, and a compensatory treatment with mini-implants in the infrazygomatic area and in the retromolar area, bite turbos were placed for adequate vertical control. The distalization of the upper arch was performed using elastic chains, achieving mandibular anterotation, a vertical overbite of +1 mm, and upper distalization of +1 mm. **Conclusions:** The use of mini-implants as skeletal anchorage allowed distalization as well as controlled intrusion of the upper molars, favoring clockwise mandibular rotation and significantly contributing to anterior bite closure.

Keywords: Open bite, mini-screws, distalization.

INTRODUCTION

Skeletal and dental anterior open bite are among the most difficult malocclusions to treat in orthodontic practice, as achieving adequate stability is extremely complex[1-3]. It is a malocclusion characterized by a lack of contact between the upper and lower incisors and a lack of vertical overlap when the posterior teeth are in occlusion[2,4].

Proffit *et al*.[5] define overbite as the vertical overlap of the incisors. Normally, the incisal edges of the lower teeth are in contact with the lingual surface of the upper incisors, at or below the cingulum, *i.e*., there is usually an overbite of 1-2 mm. In an open bite, there is no vertical overlap, and the vertical separation is measured. The etiology of this type of malocclusion is multifactorial, as it involves the interaction of environmental factors such as prolonged sucking habits, tongue thrusting, mouth breathing, allergies, tonsillar and adenoid hypertrophy, as well as eruption disturbances with a vertical facial growth pattern[2,3,6,7]. According to Ramírez-Mendoza *et al*.[8] the prevalence of open bite in Mexico is 38% in children aged 3 to 6 years. In early childhood, open bite is related to habits in 96.6% of cases[9].

Currently, open bites are classified as dental or skeletal[10]. If bone imbalance is the cause of the lack of dental contact, the bite is skeletal in origin. On the other hand, if the teeth or an environmental factor are responsible and do not affect the bones, the open bite is dental in origin. Cephalometric analyses are very helpful in differentiating between skeletal and dental origins.

The cephalometric characteristics of an anterior open bite are increased anterior facial height and gonial angle, short mandibular ramus, increased posterior dentoalveolar height, mandibular retrusion, decreased posterior facial height, tendency toward Class II, and divergent cephalometric planes. Transverse discrepancies may also be present and, in some cases, a downward inclination of the posterior palatal plane. Additional characteristics are lip incompetence, convex profile, dentoalveolar proclination, and dental crowding[4,6,11,12].

There are several methods for correcting an open bite, such as: orthodontic mechanics, orthopedic appliances, myofunctional appliances, and a combination of the above or surgical procedures. Some of the treatment options may include: myofunctional therapy, extraction of first premolars, second premolars, or first molars, *bite blocks* or posterior bite blocks, Frankel IV,

vertical traction chin cup, high pull head gear, multi-arch straight wire technique (MEAW)[10,12], temporary anchorage devices such as mini titanium plates, mini-implants, or orthognathic surgery[10,12-14]. The choice of treatment mechanics will depend on the etiology of the malocclusion and the age of the patient. It is extremely important to diagnose the origin and classification of anterior open bite in order to choose the best treatment.

Nogueira *et al*.[15] established that lingual ramps and spurs are two effective methods for treating anterior open bites in patients with atypical swallowing or tongue habits. However, lingual ramps require a greater number of appointments for the device to be fitted. The spur, on the other hand, is inexpensive and promotes greater freedom of the tongue due to its small size.

Extrusion of the anterior teeth is another alternative for managing an open bite, with prior assessment of smile analysis. However, extrusion is a less stable treatment than intrusion. Intrusion of the posterior teeth with temporary anchorage devices leads to a decrease in lower facial height through counterclockwise mandibular rotation, and gives results similar to those of orthognathic surgery to any patient with an open bite[12].

In recent years, mini-implants have been used for the correction of anterior open bites with orthodontics[2], as patient cooperation is almost null and they provide absolute anchorage for performing different dental movements[11,12,16]. Erverdi *et al*.[13] proposed the infrazygomatic crest area as an absolute and stable anchorage site for intrusion and distalization of upper molars. Maxillary molar distalization is the most common treatment for managing Class II malocclusion and obtaining Class I molar and canine relationships. Mohamed et *al*.[17] concluded that mini-implant-supported appliances are effective in distalizing molars with minimal distal inclination. Along with molar distalization, mini-implant-supported appliances lead to premolar distalization without loss of anchorage.

This clinical case will present the diagnosis, treatment plan, and management of an anterior open bite in a biprotrusive patient using mini-implants located in the retromolar ridge and infrazygomatic area as temporary anchorage.

CLINICAL CASE PRESENTATION

A 32-year-old female patient attended the Orthodontic Clinic of the DEPeI at the Faculty of Dentistry of the Universidad Nacional Autónoma de México (UNAM) for a consultation: *"I want to close the gap between my teeth"*. The patient was undergoing psychiatric treatment for depression. Physical examination revealed atypical swallowing combined with tongue thrusting. Facially, photographic analysis showed a biprotrusive convex profile, dolichofacial, lip incompetence, non-coincident facial and dental midlines, and an unassessable smile arc. Intraorally, she presented an overjet of 2.5 mm and an overbite of -3 mm, an anterior open bite, severe dental crowding, bilateral canine class II, left molar class I, and absence of the lower right first molar (Figures 1 and 2).

Cephalometric analysis showed a skeletal Class II (SNA 80°; SNB 75°; ANB 5°, and Ricketts convexity 5.8°) with mandibular hyperdivergence (SN-PM 32.4° and facial axis 76°) and dental biproclination (SU-FH 122.6°, IMPA: 101°; interincisal 103°). The upper and lower lips were off 1 mm and 5.6 mm, respectively, from the aesthetic line (Table 1). The panoramic radiograph showed 31 permanent teeth, absence of tooth 48, upper third molars present; left lower third molar in a horizontal position to the second molar, and good crown-root relationship (Figure 3).

Figure 1. Initial photographs. A. Extraoral, from left to right: neutral, smiling, and lateral. B. Intraoral, from left to right: right lateral, central, and left lateral. C. Occlusal, from left to right: upper and lower.

Figure 2. Initial study models. A. From right to left: right lateral, central, and left lateral. B. Occlusal, from left to right: upper and lower.

Table 1. Results of pre- and post-treatment cephalometric measurements, performed using Webceph orthodontic diagnostic analysis software.

	Standard	Pre-Tx	Post-Tx
FH-1U	110	122	121
IMPA	90	101°	97
1U-1L	135	103	108
A/Pg-1U	+ 3mm	14 mm	13 mm
A/Pg 1L	+1mm	10 mm	8 mm
ANB	2	5	4
SNA	82	81	81
SNB	78	76	75
Maxillary convexity	0-2 mm	7 mm	5 mm
Maxillary depth	90	87	87
FH-MP	26	32.4	31
SN-MP	32	45	43
Facial depth	87	87	87
Facial axis	90	76	80
AFA	112 mm	147 mm	145 mm
Upper lip	1-4 mm	1 mm	1 mm
Lower lip	0-2 mm	5. 6 mm	3 mm

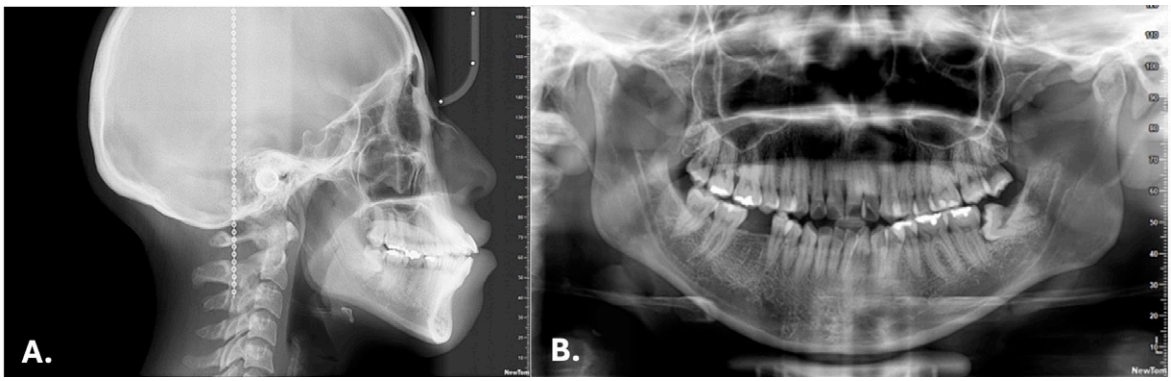

Figure 3. Initial radiographs. A. Lateral headfilm. B. Panoramic radiograph.

The facial objectives of the treatment were to improve the profile and achieve both lip competence and smile arc. The skeletal objectives focused on correcting the anterior open bite through mandibular anterior rotation, vertical control in upper second molars, and bimaxillary distalization. Dentally, treatment focused on coordinating arches, achieving bilateral canine class I, loss of anchorage of the lower right second molar, correcting dentoalveolar inclinations, centering midlines, and increasing occlusal contacts.

The patient was informed that an orthodontic-surgical approach was ideal for correcting the anterior open bite and mandibular hyperdivergence. However, this treatment option was ruled out because the patient refused surgery. The alternative was a compensatory treatment plan; first, the patient was referred to the Department of Maxillofacial Surgery for the extraction of the upper third molars and the lower left third molar, after which total distalization of both

arches was performed with the help of mini-implants and a loss of anchorage of the lower right hemiarch. The patient was informed of the advantages (less invasive procedure, lower cost, acceptable results without orthognathic surgery) and disadvantages (high relapse tendency, possible failure of the mini-implant, limited results) of this procedure. The patient accepted the compensatory treatment plan and understood its limitations compared to orthodontic-surgical treatment.

Treatment began with the bonding of passive self-ligating appliances with a 0.022" x 0.028" slot using the Roth technique on the upper and lower teeth with heights by Pitts[18]. During the alignment and leveling phase, 0.014" and 0.018" copper, nickel, and titanium (CuNiTi) alloy arches were used. Subsequently, the sequence of 0.016 x 0.016", 0.014 x 0.025", and 0.018 x 0.025" CuNiTi arches was followed. Bite turbos were placed on the upper second and first molars, and light bilateral class III 3/16" two-ounce force elastics and 5/16" rainbow elastics with two ounces of force were indicated (Figure 4). After four months of treatment, surgical-grade stainless steel mini-implants were placed in the mandibular shelf (2 x 8 mm) and infracigomatic (2 x 14 mm) with immediate loading using a closed chain with a force of 6 ounces in both the upper and lower arches (Figure 5). *Spikes* were used *on* the palatal surfaces of the upper and lower lateral incisors to control and stabilize the tongue habit. Also, during this phase, micro-osteoperforations were performed in the edentulous area at tooth 46, along with anchorage loss with elastic chain, two ounces of force on the vestibular and lingual sides of teeth 47 to 43. A panoramic radiograph was taken for repositioning; 0.021x0.025" *braided* steel archwires and settling elastics were placed (Figure 6).

Figure 4. Placement of bite turbos on upper first and second molars, bilateral Class III light elastics 3/16" 2 ounces of force, and rainbow elastics 5/16" with 2 ounces of force were indicated. A. From right to left: right lateral, central, and left lateral. B. From right to left: upper occlusal and lower occlusal.

Figure 5. Placement of infrazygomatic and mandibular shelf mini-implants with immediate loading, using a 6-ounce elastic chain. A. From right to left: right lateral, central, and left lateral. B. From right to left: upper occlusal and lower occlusal.

Figure 6. Finishing phase with 0.021x0.025" *braided* archwires and settling elastics. From right to left: right lateral, central, and left lateral.

The treatment was completed, and rigid 0.040" acetates were used as retention in both arches. The final panoramic radiograph showed good root parallelism, and the lateral head film evaluated cephalometric changes by superimposition, showing distalization and intrusion of +1 mm of the upper molar, clockwise mandibular rotation, and distalization of the lower right second molar of +4 mm (Figure 7). Post-treatment facial photographs and cephalometry showed greater anterior tooth exposure when smiling and an improvement in the profile. Post-treatment intraoral photographs show bilateral canine class I; left molar class I, closure of the edentulous space with good occlusal interdigitation, coinciding midlines, and acceptable horizontal and vertical overbite (Figure 8).

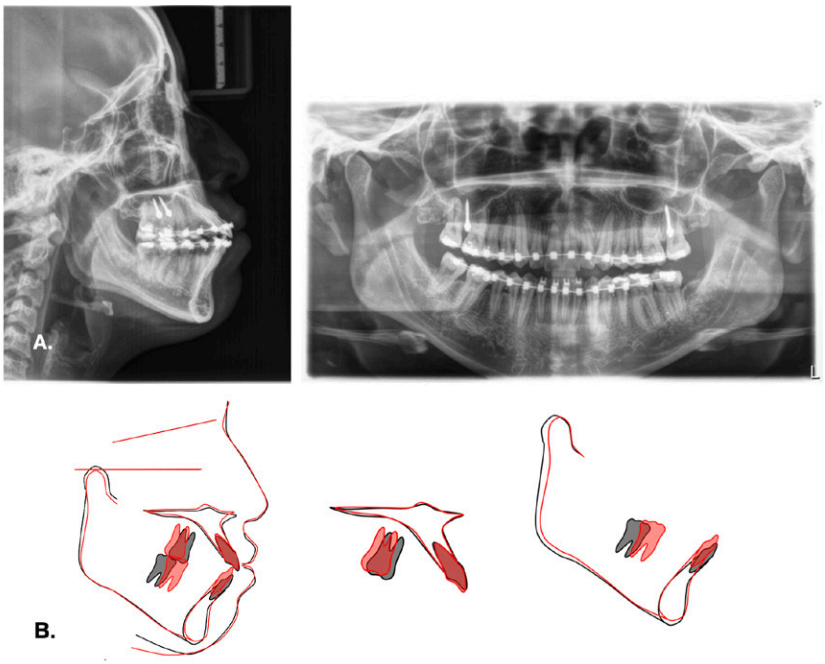

Figure 7. Final radiographs and cephalometric superimposition. A. From right to left: lateral head film and panoramic radiograph. B. From right to left: bimaxillary cephalometric superimposition, maxillary superimposition (palatal plane over ENA), and mandibular superimposition (mandibular plane over Me), black indicates the initial cephalometry, and red indicates the final cephalometry.

Figure 8. Final photographs. A. Extraoral, from left to right: neutral, smiling, and lateral. B. Intraoral, from left to right: right lateral, central, and left lateral. C. Occlusal, from left to right: upper and lower.

DISCUSSION

In the clinical case hereby presented, successful closure of the anterior open bite was achieved without orthognathic surgery, through a compensatory approach based on the use of mini-implants as skeletal anchorage. Currently, the use of mini-implants to obtain absolute skeletal anchorage is a practice that has been on the rise and has been accepted by the orthodontic community because of the advantages offered by this aid, such as ease of placement and removal, effectiveness, resistance, stability, and low cost, thus providing excellent anchorage control in movements that in the past could not be performed without orthognathic surgery.

Orthodontic-surgical treatment in patients with anterior open bite would provide long-term stability, but would also cause facial changes with the possibility of complications such as excessive bleeding, nerve damage, healing problems, anesthetic complications, or undesired results. The patient's refusal to undergo surgery determined the approach to the case using advanced orthodontic mechanics, including the use of mini-implants as temporary absolute anchorage, which coincides with what has been proposed in recent literature as an effective alternative in cases where surgical intervention is not possible or is not accepted by the patient [12,13,19].

Chen *et al.*[20] presented a clinical case of a biprotrusive patient where distalization was bimaxillary, using absolute anchorage with vestibular intraradicular mini-implants between the second premolars and first molars, where they obtained very favorable results. This type of mini-implant placement is usually divided into two stages due to the limitations imposed by the intraradicular space, which can cause discomfort in patients. In the present case, we used four mini-implants, two of which were placed in the infrazygomatic crest and the other two in the mandibular shelf. The placement of absolute anchorage in these areas prevented relocation and allowed for bimaxillary distalization with precise vertical control, which is essential for promoting clockwise mandibular self-rotation and reducing lower facial height.

Several authors have documented that molar distalization supported by mini-implants can generate significant advances without loss of anchorage, with predictable and stable dentoalveolar movements over time[17,20]. In their systematic review, Mohamed *et al.*[17] stated that molars were distalized with a mean value ranging from 1.87 mm to 6.4 mm, with the highest distalization (6.4 mm). Molar distalization allows us to obtain extra space for anterior retraction or when the space from extractions is not wide enough to correct crowding or dental proclination. In the case presented, the obtained distalization of the upper first molar was +1 mm, with no distalization of the incisors and total closure of the anterior open bite.

Another key element in achieving successful results was the etiological approach to the tongue habit. A clear relationship was documented between tongue thrusting and the presence of anterior open bite, which is consistent with the findings of Lowe[21] who identified a significant correlation between the postural activity of the genioglossus muscle and *overbite,* suggesting that the postural activity of the tongue could have a definitive influence on the position of both the upper and lower incisors.

Shetty and Shaikh[22] mentioned that spikes, also known as lingual spurs or reminders, are safe and effective in myofunctional reeducation in adults. Meanwhile, McRae[23] assessed the use of bonded lingual spurs for the correction of tongue malposition, which would eliminate the non-nutritive sucking habit by closing the anterior open bite. He evaluated 12 patients with non-nutritive sucking habits and/or atypical tongue thrusting who were treated for 6 months with bonded lingual spurs. An improvement in overbite was observed in 11 of the 12 patients in the sample, and the anterior open bite was reduced by an average of 1.38 mm over a period of 6

months. The results obtained in this clinical case were entirely favorable; the spikes allowed the resting position of the tongue to be modified and prevented it from pressing on the anterior incisors.

Cephalometrically, the observed changes reflect a significant improvement in the antero-posterior and vertical relationship. The decrease in the ANB angle, the increase in the facial axis, and the reduction in facial convexity demonstrate a positive orthopedic effect derived from the mechanics of intrusion and distalization. These changes have been described in previous studies as comparable to those obtained through orthognathic surgery, especially when using a skeletal anchorage system that controls molar verticality [19,20].

CONCLUSIONS

The objectives achieved in this case, through comprehensive diagnosis, individualized planning, and the use of mini-implants placed in the infrazygomatic area and on the mandibular shelf, were complete closure of the anterior open bite with slight mandibular autorotation as well as bimaxillary distalization that improved biprotrusion without the need for extraction of healthy premolars or loss of anchorage for space closure due to the absence of tooth 46.

BIBLIOGRAPHIC REFERENCES

1. Solano-Hernández B, Antonarakis GS, Scolozzi P, Kiliaridis S. Combined orthodontic and orthognathic surgical treatment for the correction of skeletal anterior open-bite malocclusion: a systematic review on vertical stability. *J Oral Maxillofac Surg*. 2013; *71*(1): 98-109. DOI: 10.1016/j.joms.2012.03.016
2. Pisani L, Bonaccorso L, Fastuca R, Spena R, Lombardo L, Caprioglio A. Systematic review for orthodontic and orthopedic treatments for anterior open bite in the mixed dentition. *Prog Orthod*. 2016; *17*(1): 28. DOI: 10.1186/s40510-016-0142-0
3. García CA. Mordida abierta anterior. Revisión de la literatura. *Revista Estomatología*. 2004; 12(2): 4-19 DOI: 10.25100/re.v12i2.5563
4. Lentini-Oliveira DA, Carvalho FR, Rodrigues CG, Ye, QS, Hu RD, Minami-Sugaya H et al.Orthodontic and orthopaedic treatment for anterior open bite in children. *Cochrane Database Syst Rev. 2014(9)*: CD005515. DOI: 10.1002/14651858.CD005515.pub3
5. Proffit WR, Fields HW, Sarver DM. *Ortodoncia contemporánea*. 5 ed. Barcelona: Elsevier Health Sciences; 2013.
6. Kim YH, Han UK, Lim DD, Serraon MLP. Stability of anterior openbite correction with multiloop edgewise archwire therapy: A cephalometric follow-up study. *Am J Orthod Dentofacial Orthop*. 2000; *118*(1): 43–54. DOI: 10.1067/mod.2000.104830
7. Artese A, Drummond S, Nascimento JM, Artese F. Criteria for diagnosing and treating anterior open bite with stability. *Dental Press J Orthod*. 2011; *16*(3): 136-161. Disponible en: https://www.scielo.br/j/dpjo/a/BY6KGbZchWbSLL8S4QgBpHt/?lang=en&format=pdf
8. Ramírez-Mendoza J, Bulnes-López RM, Guzmán-León R, Torres-López JE, Priego-Álvarez HR. Características y alteraciones de la oclusión en la dentición primaria de preescolares de 3 a 6 años en Tabasco, México. *Odontol Pediatr*. 2011; *10*(1): 6-12. Disponible en: https://repebis.upch.edu.pe/articulos/op/v10n1/a1.pdf

9. Miranda-Salguero ÁE, Sánchez-Valverde A. Corrección de una mordida abierta anterior esquelética mediante miniimplantes y un bite block modificado. *Rev Mex Ortod*. 2017; *5*(2): 107-115. DOI: 10.1016/j.rmo.2017.06.007
10. Fonseca-Fernández Y, Fernández-Pérez E, Cruañas AM. Mordida abierta anterior. Revisión bibliográfica. *Rev Haban Cienc Méd*. 2014; *13*(4): 509-515. Disponible en: http://scielo.sld.cu/scielo.php?script=sci_arttext&pid=S1729-519X2014000400003&lng=es
11. Akbaydogan LC, Akin M. Cephalometric evaluation of intrusion of maxillary posterior teeth by miniscrews in the treatment of open bite. *Am J Orthod Dentofacial Orthop*. 2022; *161*(5): 621-627. DOI: 10.1016/j.ajodo.2020.11.033
12. Reichert I, Figel P, Winchester L. Orthodontic treatment of anterior open bite: a review article – is surgery always necessary? *Oral Maxillofac Surg*. 2014; 18(3): 271-277. DOI: 10.1007/s10006-013-0430-5
13. Erverdi N, Usumez S, Solak A. New generation open-bite treatment with zygomatic anchorage. *Angle Orthod*. 2006; 76(3): 519-526. DOI: 10.1043/0003-3219(2006)076[0519:NGOTWZ]2.0.CO;2
14. Kaku M, Kawai A, Koseki H, Abedini S, Kawazoe A, Sasamoto T, *et al*. Correction of severe open bite using miniscrew anchorage. *Aust Dent J*. 2009; 54(4): 374-380. DOI: 10.1111/j.1834-7819.2009.01166.x
15. Nogueira FF, Mota LM, Nouer PRA, Nouer DF. Esporão lingual colado Nogueira®: tratamento coadjuvante da deglutição atípica por pressionamento lingual. *Rev Dent Press Ortod Ortop Facial*. 2005; *10*(2): 129-156. DOI: 10.1590/S1415-54192005000200016.
16. Leite JS, Matiussi LB, Salem AC, Provenzano MGA, Ramos AL. Effects of palatal crib and bonded spurs in early treatment of anterior open bite: A prospective randomized clinical study. *Angle Orthod*. 2016; *86*(5): 734-739. DOI: 10.2319/031815-170.1
17. Mohamed RN, Basha S, Al-Thomali Y. Maxillary molar distalization with miniscrew-supported appliances in Class II malocclusion: a systematic review. *Angle Orthod*. 2018; *88*(4): 494-502. DOI: 10.2319/091717-624.1
18. Pitts TR. Comience con el final en mente. Protocolos de cementación de brackets y elásticos tempranos para la protección del arco de la sonrisa. *Clinical impressions*. 2009; *17*(1): 2-11. Disponible en: https://digitalsmiledesign.com/files/Old-Website-Assets/Static/Pitts_T_espanol.pdf
19. Kuroda S, Sakai Y, Tamamura N, Deguchi T, Takano-Yamamoto T. Treatment of severe anterior open bite with skeletal anchorage in adults: comparison with orthognatic surgery outcomes. *Am J Orthod Dentofacial Orthop*. 2007; *132*(5): 599-605. DOI: 10.1016/j.ajodo.2005.11.046
20. Chen G, Teng F, Xu TM. Distalization of the maxillary and mandibular dentitions with miniscrew anchorage in a patient with moderate Class I bimaxillary dentoalveolar protrusion. *Am J Orthod Dentofacial Orthop*. 2016; *149*(3): 401-410. DOI: 10.1016/j.ajodo.2015.04.041
21. Lowe AA. Correlations between orofacial muscle activity and craniofacial morphology in a sample of control and anterior open-bite subjects. *Am. J. Orthod*. 1980; *78*(1): 89-98. DOI: 10.1016/0002-9416(80)90042-1
22. Shetty S, Shaikh N. An effective and simple method for treatment of tongue thrusting in adult patient. A case report. *IP J Surg Allied Sci*. 2021; *3*(4):116-119. DOI: 10.18231/j.jsas.2021.026
23. McRae EJ. Bondable lingual spur therapy to treat anterior open bite [Master of Science Theses]. Milwaukee, Wisconsin: Marquette University; 2009. Disponible en: https://epublications.marquette.edu/theses_open/25/