



Clinical case

Assessment of Secondary Implant Stability by its Response to Percussion. Case Report

Eduardo Melgarejo-González-Aragón¹, Juan Antonio Espinoza-Navarro²,
Oswaldo Villa-Campos³, Yoshamín Abnoba Moreno-Vargas⁴

- ¹. Estudiante de la Maestría en Implantología Oral Integral, Universidad Westhill.
- ². Profesor de asignatura, Facultad de Odontología, Universidad Westhill.
- ³. División de Periodoncia, Departamento de Estomatología, Facultad de Odontología, Universidad de São Paulo, São Paulo, Brasil.
- ⁴. Profesor de asignatura, Facultad de Odontología, Universidad Nacional Autónoma de México.

Correspondence author:

Eduardo Melgarejo González-Aragón
Email: oiemga@yahoo.com.mx

Received: 19 October 2023

Accepted: 2 September 2024

Cite as:

González-Aragón EM, Espinoza-Navarro JA, Villa-Campos O, Moreno-Vargas YA. Valoración de la estabilidad implantaria secundaria mediante su respuesta a la percusión. Reporte de caso [Assessment of Secondary Implant Stability by its Response to Percussion. Case Report]. *Rev Odont Mex.* 2024; 28(4): 44-50. DOI: 10.22201/fo.1870199xp.2024.28.4.86977

ABSTRACT

Introduction: Determining the ideal time for functional loading of dental implants represents a complex clinical challenge, as multiple factors are involved and each option presents its own risks, advantages and disadvantages. Therefore, it is important to consider implant stability, because it is necessary for osseointegration and it is an essential requirement for implant rehabilitation, as well as for its long-term success. For this purpose, the Anycheck[®] device measures implant stability non-invasively, reducing the risk of failure in implants that replace lost teeth. **Objective:** To determine the stability of a dental implant using the Neobiotech AnyCheck[®] implant stability

meter. **Case presentation:** 39-year-old male patient with tooth 16 missing. Surgical and prosthetic planning was performed. An Ø 5.00, 10 mm long mis[®] implant was placed and left submerged for 12 weeks; subsequently, stability was measured with the AnyCheck[®] dental implant stability meter. **Conclusions:** Stability is affected by numerous factors, however, devices such as the AnyCheck[®] stability meter allow the stability of dental implants to be measured non-invasively, and their evolution can be monitored over time. Furthermore, it can be done without removing the healing abutment and therefore without the risk of causing bone resorption.

Keywords: AnyCheck[®], Stability, Dental implant, Percussion, Implant stability test.

INTRODUCTION

Oral health has a significant impact on our overall health, as it is the portal to what nourishes and feeds us, as well as a reflection of what happens in our body. The design of the stomatognathic system could allow us to keep our teeth for decades, however, there are various factors that lead to the premature loss of one or more teeth and with it, to the loss of quality of life and the compromise of our well-being^{1,2}. One of the main objectives of contemporary dentistry is for the patient to recover the characteristics of the teeth they have lost, including their function, shape and aesthetics. Dental implantology has experienced significant advances in recent decades, transforming the lives of millions of people by offering effective solutions to replace their missing teeth²⁻⁴.

Dental implants are defined, according to the Glossary of Prosthodontic Terms 9th Edition (GPT-9) as: *"a prosthetic device made of alloplastic material(s) implanted in the oral tissues beneath the mucosal and/or periosteal layer and on or within the bone to provide retention and support for a fixed or removable dental prosthesis"*³. Long-term success depends largely on its stability and ability to optimally integrate into the surrounding bone⁴⁻⁵.

Stability is divided into two types: primary stability, which is obtained with the initial insertion torque at the time of placement through mechanical stabilisation factors of the implant within the bone. Secondary stability, which is achieved when the implant has achieved osseointegration with the bone that biologically surrounds it. The sum of both will give value to the final stability, which will be the biological basis for success in long-term treatment⁴⁻⁶. Therefore, it is very convenient to quantify implant stability at various times, either to determine the moment of functional loading, or to detect changes in implant stability over time.

In this context, various devices have been developed such as the Osstell[®] from Osstell[®], which measures implant stability using resonance, with the disadvantage that it requires the single-use Osstell[®] SmartPeg abutments. Likewise, the AnyCheck[®] dental implant stability meter from Neobiotech[®], which allows the stability of dental implants to be evaluated objectively and quantitatively and whose operation is based on percussion, a physical examination technique that consists of gently tapping a surface to evaluate its sonority and mobility. In the case of implants, percussion is used to assess the integration of the implant into the bone. When the implant is percussed, vibrations are generated which are transmitted through the bone and the implant. The AnyCheck[®] device captures and analyses these vibrations, providing information on the stiffness of the implant-bone junction without the need to place or remove the healing abutment. Therefore, it emerges as an indispensable tool in the practice of implantology,

allowing professionals to evaluate, quantify and make informed decisions about the stability of dental implants within implant therapy⁷⁻⁹.

This scientifically-based device features excellent repeatability and reproducibility, and also provides an objective assessment of implant stability, providing crucial information at all stages of the treatment process, from placement to long-term follow-up. It is worth mentioning that there is no robust scientific evidence or clinical studies on the matter, because the device has been recently launched and there are no reports of clear evidence about it. While exact figures for implant failure at 12 weeks are scarce, it is generally accepted that the overall success rate for implants exceeds 95% of cases. For this reason, the objective of this study was to determine the stability of a dental implant 12 weeks after its placement using the AnyCheck® dental implant stability meter¹⁰⁻¹².

CLINICAL CASE PRESENTATION

A 39-year-old male patient attended the Implantology Clinic at Westhill University presenting with the absence of the right first maxillary molar (16). In the anamnesis, he reported that he lost the tooth approximately 12 years ago due to a carious process and said that he wanted to recover his tooth by using a single implant-supported fixed prosthesis, thus avoiding damage to the adjacent teeth. The patient did not report any pathological history and considered his health to be good. He did not report taking any medications, nor any drug or food allergies and stated that he smoked four cigarettes a day.

In the clinical, photographic and radiographic assessment (Figure 1. A-B), the appropriate conditions were found for the placement of a dental implant in the area of tooth 16, such as: sufficient bone height and width, more than 7 mm of interocclusal space for the implant-supported fixed prosthesis, and sufficient keratinised gingiva without mucogingival defects in the area to be treated. Tomographic planning was then carried out using CBCT equipment (Orthopantomograph® OP300, Instrumentarium Dental, Tuusula, Finland) and Blue Sky Plan® software version 4.0 (Blue Sky Bio, LLC, Libertyville, USA), performing a three-dimensional mapping of the area. Type 3 bone was observed in the edentulous area and a regular and defined process, without alterations and with the appropriate dimensions for the placing of the dental implant.

The implant of Ø 5.00, 10 mm long (Seven XD, MIS® Implants Technologies Ltd., Northern District, Israel) was placed. After asepsis and antisepsis with 0.12% Chlorhexidine intraorally for 1 minute, the patient was locally anaesthetised with two cartridges of lidocaine HCl-epinephrine (2%-1:100,000) (FD®, Laboratorios Zeyco®, S.A. de C.V., Zapopan, Mexico). The anaesthetic technique consisted of a posterior maxillary alveolar nerve block, infiltration of the mucosa of the vestibular surface of the area of the right maxillary first molar, and a block of the greater palatine nerve. Subsequently, a full-thickness flap was made with a supracrestal incision, from the mesial surface of the right second maxillary molar to the distal surface of the right second maxillary premolar, freeing the gingival sulcus in both teeth (Figure 1. C).

The implant site was made according to the manufacturer's guidelines, and the implant was screwed to 25 Ncm initial torque. Next, the cover screw provided in the implant kit was placed and sutured with three simple stitches interrupted with 3-0 gauge Nylon suture (Atramat® Nylon Monofilament, Internacional Farmacéutica, S.A. de C.V., Mexico City, Mexico). A digital dentoalveolar radiograph was taken, which showed an adequate position of the implant with sufficient bone around it and a safe distance to the floor of the maxillary sinus and the roots of the adjacent teeth (Figure 1. D).

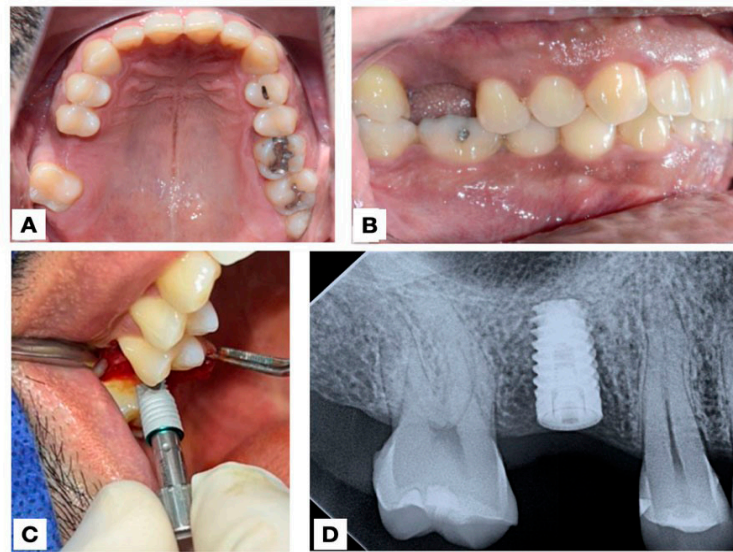


Figure 1. Initial photographs. A. Preoperative maxillary occlusal view. B. Left lateral view (preoperative). C. Implant placement in area of tooth 16. D. Postoperative digital dentoalveolar radiograph.

Twelve weeks after implant placement, local anaesthesia was applied and a 1.0 cm crestal incision was made, palatinized to protect the keratinised tissue in the implant area. The cover screw was located and removed, and a 5 mm gingival height wide platform healing abutment (Standard Healing Cap, MIS® Implants Technologies Ltd., Northern District, Israel) was installed, with which implant stability was measured with the AnyCheck® device (Neobiotech Co., Ltd., Wonju, Korea), using a colour/numeric scale, red: 30-59, orange: 60-64 and green: 65-85 expressed in *Implant Stability Test* (IST) units. According to the manufacturer's recommendations, the patient was positioned in an upright position during the measurement. The contact angle between both surfaces was set between 0° and 30°. The device struck the abutment for about 2 seconds and immediately displayed the measurement on the monitor's LED screen (Figure 2. A-B). The stability measurement was located on the green colour scale with 73 IST (Figure 2. C-D), however, the Anycheck® device uses a 4 mm high standard abutment and the patient was fitted with a 5 mm one. This required a reading correction as recommended by the manufacturer, increasing the initial reading by 2 IST, resulting in 75 IST (Figure 3). Which indicates that the implant achieved high stability (in the range of 65 to 85 IST), and a low risk of failure for the same according to the manufacturer's parameters.

Three weeks after profiling the soft tissue, the impression was taken with a prosthetic kit (Complete Prosthetic Kit (CPK), MIS® Implants Technologies Ltd., Northern District, Israel), which requires working with a cemented prosthesis. The clinical advantages of this decision were: working comfortably with a slightly limited mouth opening, significantly reduced costs for the patient, as well as a smaller number of appointments at the clinic, and also, avoiding a chimney in the crown, giving it greater aesthetics and eliminating the need to seal it with resin. This impression was taken using a closed spoon technique and polyvinyl siloxane to be sent to the laboratory, and a monolithic zirconia crown was manufactured (Classic zirconia, CAD-CAM software, Whitepeaks Dental Solutions GmbH, Hamminkeln, Germany; milling machine, VHF Camufacture AG, Ammerbuch, Germany) (Figure 4. A-B). Occlusal and aesthetic tests were performed, and after checking its correct fit and colour, it was cemented with temporary cement

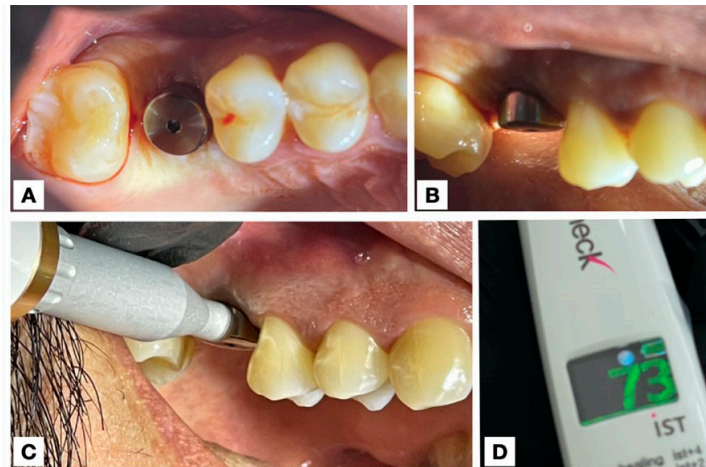


Figure 2. Placement of the healing abutment on the implant in the area of tooth 16. A. Occlusal view. B. Lateral view. C. Stability measurement in IST units with the AnyCheck® measuring device on the healing abutment. D. Measurement result (73 IST) on the LCD screen of the AnyCheck® device.

(Temp-Bond™ NE, Kerr Corporation, Orange, USA) for possible recovery if necessary. The occlusion was confirmed with 40 micron articulating paper (Bausch Arti-Check®, Dr. Jean Bausch GmbH & Co. KG, Cologne, Germany). A final digital dentoalveolar radiograph was also taken (Figure 4. C), to confirm the fit of the prosthesis, where a correct seating of both the prosthetic abutment and the crown was observed. The patient was provided with hygiene instructions and the respective post-operative and maintenance indications.

DISCUSSION

According to studies by Luengas *et al.*¹, edentulism in Mexico is a complex problem that affects oral health, masticatory and digestive functions, as well as the aesthetics of people who have lost teeth. This is why it is essential that, as professionals, we address the problem with the best tools available, always keeping in mind that the fundamental objective of rehabilitation is to improve the quality of life of patients².

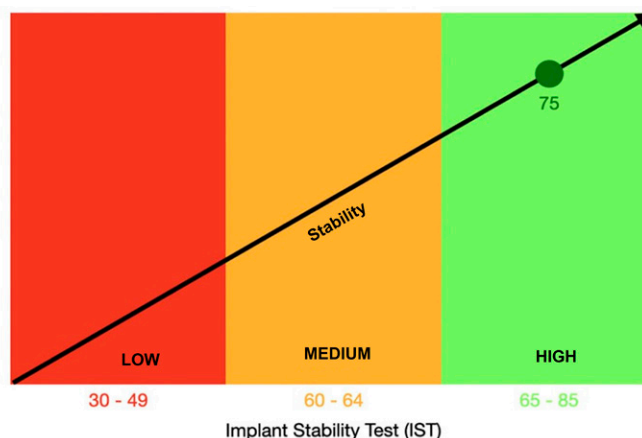


Figure 3. Implant stability value using AnyCheck®, obtained 12 weeks after implant placement. The 75 IST obtained correspond to high stability with a low risk of failure.

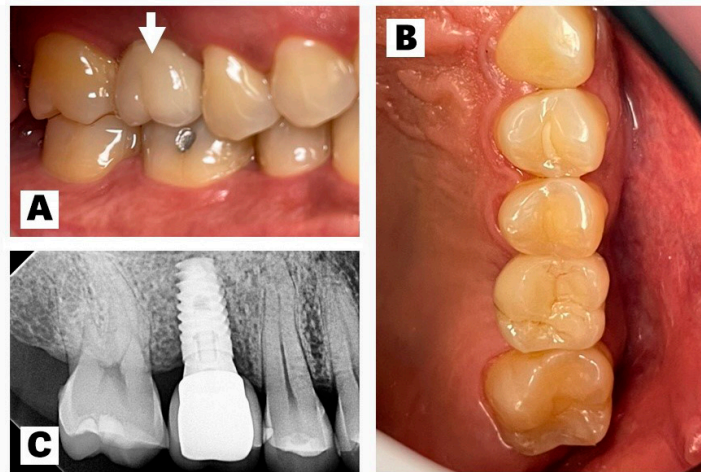


Figure 4. Final photographs. A. Lateral view, white arrow pointing to the monolithic zirconium crown cemented on the implant in the area of the right maxillary first molar (16). B. Occlusal view. C. Final digital dentoalveolar radiograph.

In this sense, the studies by Huang *et al.*⁴ have shown that we depend on the stability of the implant to carry out its rehabilitation. This stability is affected by numerous factors and, therefore, it is very challenging for the professional to determine the risks and times for the different phases of treatment. Being able to quantify it by means of percussion is precise, objective and convenient for the professional and the patient⁵.

Various studies⁷⁻¹¹ show that devices such as AnyCheck[®] have proven to be a useful clinical tool in the prevention, diagnosis and prediction of implant failures, with excellent repeatability and reproducibility, making it possible to follow up implant stability over time. After having used it in our case, we found that its viability, and the advantage of not manipulating the implant, make it an excellent tool in the arsenal of any rehabilitation with implants. In this case, the 75 IST obtained allowed us to feed the clinical decision-making process, by verifying the good stability of the implant, anticipating a favourable prognosis and a low risk of failure for the treatment.

It is worth mentioning that the device has been recently introduced and, consequently, there is little documentation about it. Therefore, we consider that more studies are needed, with a larger sample size, to quantify its impact and to be able to conduct a more complete analysis of its application in the field of oral implantology.

CONCLUSION

The multiple factors that affect the stability of an implant, such as: the quality, density and type of bone, the anatomical region, the position and angulation, the characteristics of the implant (shape, dimensions, surface, material and design) as well as the surgical technique and the expertise of the professional, must be combined to achieve secondary stability through osseointegration and thus reach a good relationship between the implant and the bone and, consequently, a favourable result for prosthetic rehabilitation.

The use of the AnyCheck[®] device in our work proved to be useful in attaining quantitative stability measurements, and was found to be easy to use and to incorporate into the treatment

plan. Additionally, it allowed us to obtain quick and necessary information, optimising the procedure of fulfilling the implant loading and its subsequent prosthetic rehabilitation.

ACKNOWLEDGEMENTS

The authors consider it appropriate to extend their gratitude to the Faculty of Dentistry at Westhill University, and to all the professors in the specialty of Comprehensive Oral Implantology, especially Dr. Miguel Ángel Pérez Pérez and Dr. Arisdé Sánchez Anaya.

BIBLIOGRAPHIC REFERENCES

1. Luengas-Aguirre MI, Sáenz-Martínez LP, Tenorio-Torres G, Garcilazo-Gómez A, Díaz-Franco MA. Aspectos sociales y biológicos del edentulismo en México: un problema visible de las inequidades en salud. *Ciencias Clínicas*. 2015; 16(2): 29-36. DOI: 10.1016/j.cc.2015.12.002
2. Alghamdi HS, Jansen JA. The development and future of dental implants. *Dent Mater J*. 2020; 39(2): 167-172. DOI: 10.4012/dmj.2019-140
3. The Academy of Prosthodontics. The glossary of prosthodontic terms: Ninth edition. *J Prosthet Dent*. 2017; 117(5S): e1-e105. DOI: 10.1016/j.prosdent.2016.12.001
4. Huang H, Wu G, Hunziker E. The clinical significance of implant stability quotient (ISQ) measurements: A literature review. *J Oral Biol Craniofac Res*. 2020; 10(4): 629-638. DOI: 10.1016/j.jobcr.2020.07.004
5. Monje A, Ravidà A, Wang HL, Helms JA, Brunski JB. Relationship between primary/mechanical and secondary/biological implant stability. *Int J Oral Maxillofac Implants*. 2019; 34(Suppl): s7-s23B. DOI: 10.11607/jomi.19suppl.g1
6. Pandey C, Rokaya D, Bhattarai BP. Contemporary concepts in osseointegration of dental implants: A review. *Biomed Res Int*. 2022; 6170452. DOI: 10.1155/2022/6170452
7. Bafijari D, Benedetti A, Stamatovski A, Baftijari F, Susak Z, Veljanovski D. Influence of resonance frequency analysis (RFA) measurements for successful osseointegration of dental implants during the healing period and its impact on implant assessed by Osstell Mentor Device. *Open Access Maced J Med Sci*. 2019; 7(23): 4110-4115. DOI: 10.3889/oamjms.2019.716
8. Ahmad OK, Kelly JR. Assessment of the primary stability of dental implants in artificial bone using resonance frequency and percussion analyses. *Int J Oral Maxillofac Implants*. 2013; 28(1): 89-95. PMID: 23377052
9. Díaz-Castro MC, Falcao A, López-Jarana P, Falcao C, Ríos-Santos JV, Fernández-Palacín A, et al. Repeatability of the resonance frequency analysis values in implants with a new technology. *Med Oral Patol Oral Cir Bucal*. 2019; 24(5): e636-e642. DOI: 10.4317/medoral.22761
10. Lim HK, Lee SJ, Jeong Y, Lee JS, Ryu JJ, Shim JS, et al. Clinical validation of dental implant stability by newly designed damping capacity assessment device during the healing period. *Medicina (Kaunas)*. 2022; 58(11):1570. DOI: 10.3390/medicina58111570
11. Okuhama Y, Nagata K, Kim H, Tsuruoka H, Atsumi M, Kawana H. Validation of an implant stability measurement device using the percussion response: A clinical research study. *BMC Oral Health*. 2022; 22(1): 286. DOI: 10.1186/s12903-022-02320-0
12. Lee DH, Shin YH, Park JH, Shim JS, Shin SW, Lee JY. The reliability of Anycheck device related to healing abutment diameter. *J Adv Prosthodont*. 2020; 12(2): 83-88. DOI: 10.4047/jap.2020.12.2.83