Revista Odontológica Mexicana
Facultad de Odontología
Vol. 18, No. 1 ● January-March 2014
pp 43-49
CASE REPORT

Segmented trans-maxillary approach for clivus tumor resection. Case report

Abordaje transmaxilar segmentado para resección de tumores del clivus. Reporte de un caso

Doroteo Vargas López,* Ronald H Rojas Villegas,§ Víctor A García Alcaráz,|| Gloria Leticia Lara Fong,|| Heriberto Herrera Gómez¶

ABSTRACT

The complex anatomy exhibited by the vital structures of the skull base hinders surgical resection of tumors present in that area. The main problem when facing tumors lodged in the skull base resides in choosing the most suitable approach. The initial development of skull base surgery was a product of the collaboration between otorhinolaryngology and neurosurgery techniques. The participation of maxillofacial surgeons in these events has been a relatively recent endeavor. In the present instance a case of trans-maxillary approach to access clivus and remove a tumor was presented.

RESUMEN

La compleja anatomía de las estructuras vitales de la base de cráneo dificulta mucho la resección quirúrgica de los tumores que afectan esta zona. El problema fundamental de los tumores que afectan a la base del cráneo es elegir el abordaje ideal. El desarrollo inicial de la cirugía de la base del cráneo fue producto de la colaboración entre la otorrinolaringología y la neurocirugía. La participación del cirujano maxilofacial ha sido un fenómeno relativamente reciente. En este caso se presenta abordaje transmaxilar para acceso a clivus y eliminar el tumor.

Key words: Clivus tumor, trans-maxillary approach, skull base.
Palabras clave: Tumor de clivus, abordaje transmaxilar, base del cráneo.

INTRODUCTION

The introduction of trans-facial approach is frequently attributed to Walter Dandy who in 1941 published a book in which he elaborated on resection of orbital tumors through the anterior portion of the skull base. Techniques described in the Dandy text were the first to combine facial and cranial surgery. In 1954 Smith & al reported the first intra-cranial and trans-facial combined approach for frontal sinus tumor treatment. The initial experience with these techniques was plagued with significant infection and cerebrospinal fluids filtration rates. To some extent, reduction of complications rate can be attributed to the creation of new local flaps which use scalp (galea), frontal muscle or pericranium. With the advent of craniofacial surgery development, many techniques formerly used to correct congenital defects of the facial skeleton and cranial vault are being presently adapted to skull base surgery procedures. In our days, the reconstructive aspects of skull base surgery procedures are in the limelight, this compels surgeons to offer neurosurgeons an enhanced exposition so as to facilitate the tumor resection (extirpation) eliciting lesser functional and esthetic losses.

When an exclusively facial approach is undertaken, with lack of suitable exposition or intracranial component control, the result will be incomplete tumor resection, cerebrospinal liquid fistula, hemorrhage and infection, with all the consequent serious sequels. Craniofacial surgery requires observation of the following principles:

* Maxillofacial surgeon attached to Maxillofacial Surgery Service «Lic. Adolfo Lopez Mateos» Hospital (ISSSTE), Mexico City, Mexico.
§ Maxillofacial surgeon, private practice
|| Maxillofacial surgeon, attached to the Maxillofacial Surgery Service of the Regional Hospital «Merida» (ISSSTE).
¶ Neurosurgeon, attached to the Neuro-surgery Service, Regional Hospital «Lic Adolfo Lopez Mateos», (ISSSTE) Mexico City, Mexico

ISSSTE (Institute for Social Security for State Workers) Mexico.

This article can be read in its full version in the following page:
http://**www.medigraphic.com/facultadodontologiaunam**

1. Suitable exposition of surgical resection area must be obtained.
2. Encephalic retraction should be nil.

A division scheme of the different regions of the cranial base is advised in order to be able to classify surgical interventions in that area. The base of the skull is divided into three regions in anterior-posterior direction:

1. Anterior fossa.
2. Middle fossa.
3. Posterior fossa.

Skull base surgery has undergone significant advances in the last 30 years. The skull base, formerly considered prohibited territory, is now systematically approached in various instances such as vascular malformations, benign or malign neoplasia and trauma. With the development of new approaches as well as improved techniques, such as image-guided surgery, performance and safety of skull base surgery have dramatically increased. Surgical approach for skull base surgery depends upon the anatomical location of the condition as well as the extent of its invasion. Therefore, surgical approaches are different for the cranial fossa, be it anterior, middle or inferior as well as for the clivus region.

There might be contraindications in the approach for surgical treatment of malignancies such as

1. Macroscopic invasion of encephalon.
2. High grade massive tumors.
3. Invasion of both orbits (eye sockets).
4. Elderly patients whose physical or psychological circumstances are not suitable for such major surgical interventions.
5. Recurrent disease entailing skull base invasion after previous radiotherapy (relative contraindication).[1]

A great number of direct and indirect approaches have been proposed to gain access to the central component of the anterior skull base, from the sphenoid sinus up to the high cervical spine. Procedures most frequently mentioned in scientific literature are:

- Trans-cervical- trans-temporal approach.
- Soft palate retraction.
- Soft palate dissection.
- Stepped osteotomy of the lower jaw.
- Medial glossotmy.
- Upper jaw low osteotomy with approach through the nasopharynx.
- Upper jaw low osteotomy with soft and hard palate dissection.

Combinations of these procedures:

- Trans-maxillary: when tumor growth was mainly directed towards the maxillary, sphenoid and ethmoid sinuses.
- Trans-oral: In cases when there was invasion of cranio-vertebral union
- Trans-mandibular cygomatic: For lesions located in the middle fossa presenting invasion towards the infra-temporal fossa and para-pharyngeal space.

The most frequent anterior skull base conditions are:

- Clivus chondroma.
- Meningioma of the foramen magnum.
- Vascular lesions of the anterior brain.
- Hypophysis tumors with extension to sphenoid bone.
- Odontoid apophysis abnormalities which create brain compression.
- Nasopharyngeal tumors.
- Basilar invagination.

Chordoma are rare neoplasia which represent 0.1 to 0.2% of all primary intra-cranial tumors. They originate from primitive notochord epithelial remains and appear all along the cranio-spinal axis.[2]

Notochord ends at the sphenoid bone just underneath the *sella turcica* and *sella dorsum*, consequently, chordoma of the skull base appear in the clivus region. 35% of all chordoma affect the skull base, 50% appear at the sacrococcygeal region and 15% in the spine[3,4]

Approximately 60% of all chordoma affect vertebrae in this location. Intra-cranial tumors constitute 40%, and appear mainly at two locations: the most common location is the clivus region, or spheno-occipital union, and the second would be the sellar region. This is rare tumor, constituting 4% of all bone primary malign tumors. Frequency of location is as follows: sacrococcygeal region 50%, spheno-occipital region 37%, cervical region 6%, lumbar region 4%, thoracic region 3%.

Based upon histological findings, a chordoma variant has been described. This is due to the fact that within certain regions they resemble the hyaline type of chondrosarcoma. In 1973 Heffelfin-ger & al named it chondroid chondroma.

Chondroma can appear at any age, nevertheless, in the cranio-vertebral area they appear mostly in subjects aged 30 to 50 years. Males are more heavily affected than females. Scientific literature reports chondroma with apparent family lineage.[3,5,6]

The neurosurgeon frequently encounters difficulties when treating clivus, upper vertebrae and cervico-medullary junction lesions.

Available approaches for the clivus through anterior clivus venue offer excellent visualization but afford little ease for cranial nerve and cerebral stem manipulation. Early attempts to expose lesions by way of a clivectomy involved high cervical incisions which deliberately avoided the oral cavity in order to decrease infection and contamination risks. This process nevertheless entailed wide neck dissections, which sacrificed cranial nerves and were frequently accompanied by complications such as dysphonia and dysphagia.

Surgical treatment of mid-line lesions is frequently fraught with varied technical difficulties: normally, a sub-occipital approach is undertaken, contingent upon the neck position and the lesion projection; this technique can be combined with a *trans-tectum* approach.

Its main disadvantages are excessive time for retraction of cerebral stem and vagal nerves, as well as the great risks of large lesions such as large aneurisms or tumors. Due to this reason, trans-oral approaches have been described, employing Le Fort I osteotomy, which markedly improve exposition, with lumbar drain of cerebrospinal fluid while the operation is ongoing, and then human fibrin application for dura closure.

CLINICAL CASE

The present study presents the case of a 35 year old female, who first complains of generalized clonic-tonic convulsive seizures (crises), as well as, in one instance, lipothymy, which evolved with bi-parietal headaches as well as dysesthesia in both hands. A tomographic study was requested which revealed clivus tumor *(Figures 1 to 3)*.

Surgical resection of the lesion required a multi-disciplinary approach, the Maxillofacial Surgery Service undertook to achieve exposition and the neurosurgical team performed the resection.

Endotracheal intubation was performed so as to later undertake a sub-mental derivation *(Figure 7)*.

Under balanced general anesthesia and with the patient in prone position *(dorsi decubitus)* with secured skull, lidocaine with epinephire was applied to the affected area. After this, a circum-vestibular approach was undertaken and a Le Fort I osteotomy *(Figure*

Figure 1.

Front view.

Figure 2. Occlusion.

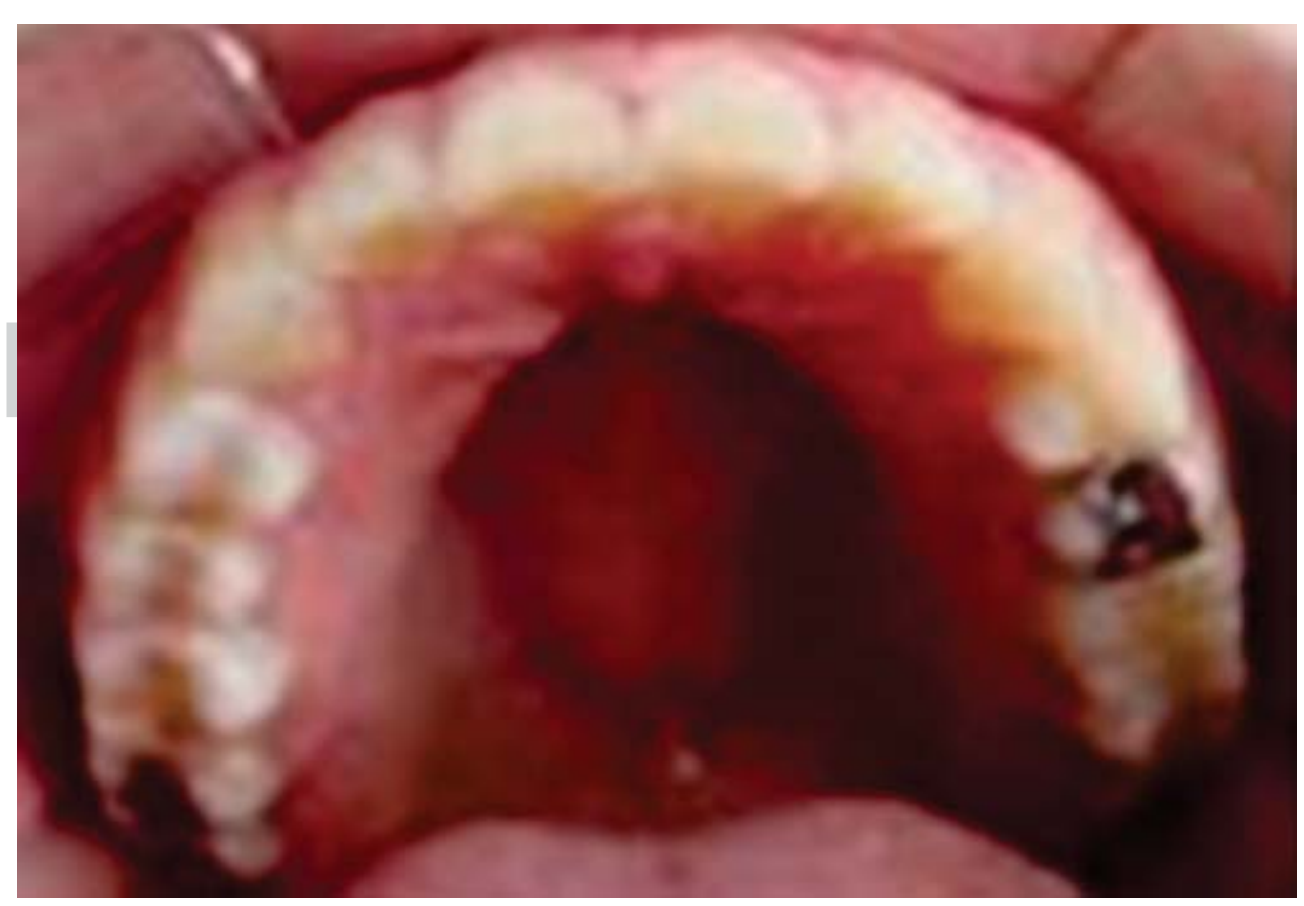

Figure 3. Palatal view.

Figure 4.

Chordoma are lesions frequently found in the clivus midline, entailing bone destruction and masses with soft parts.

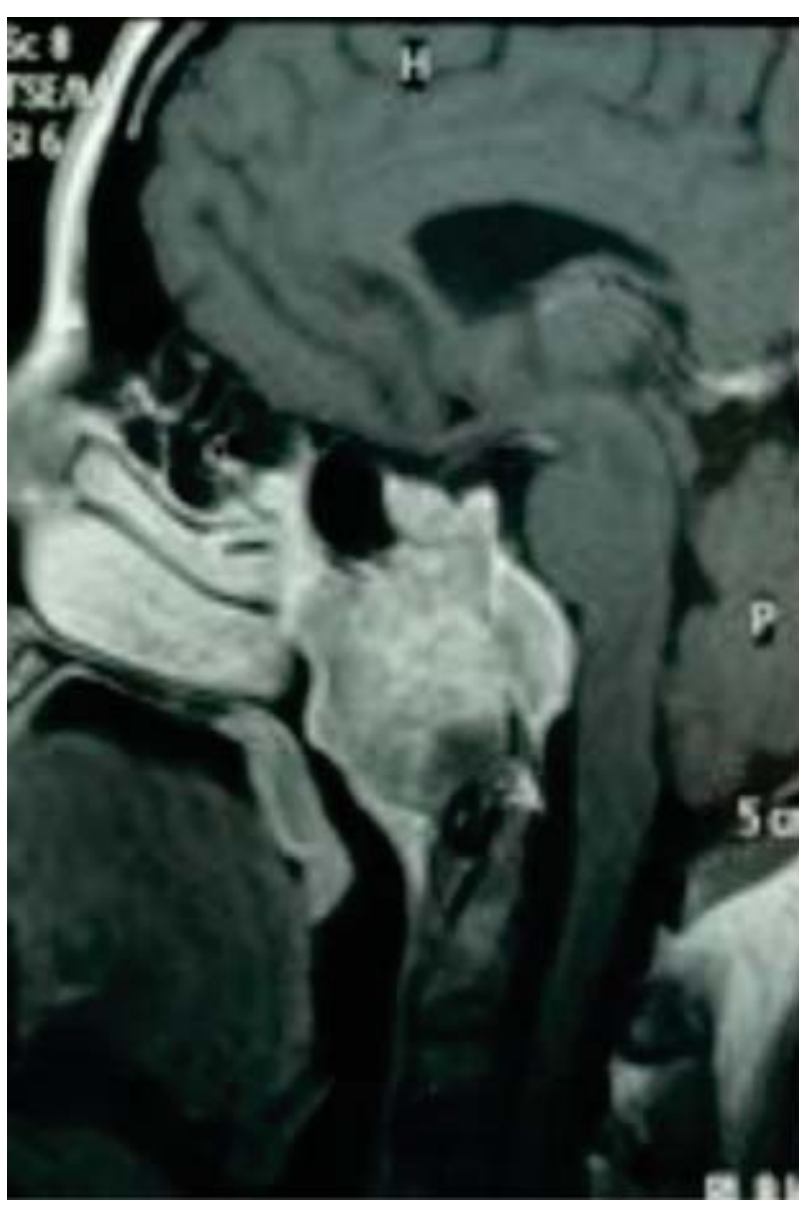

Figure 5.

Magnetic resonance is an excellent tool to detect lesion borders and their relation to other anatomical structures.

Figure 6.

Normal vessels of skull base and neighboring areas are frequently displaced by the tumor.

Figure 7. Sub-mentonian derivation.

Figure 8. Le Fort I osteotomy.

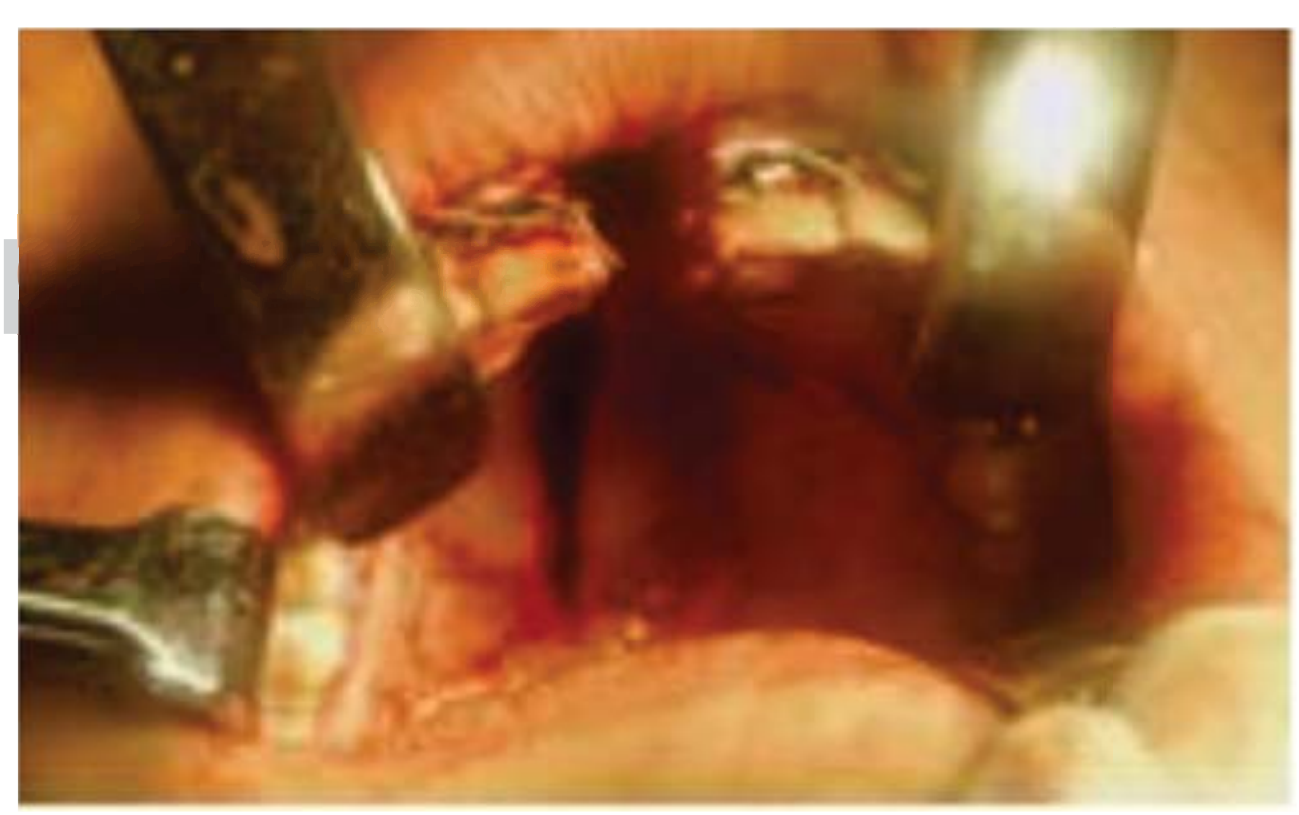

Figure 9. Le Fort I osteotomy.

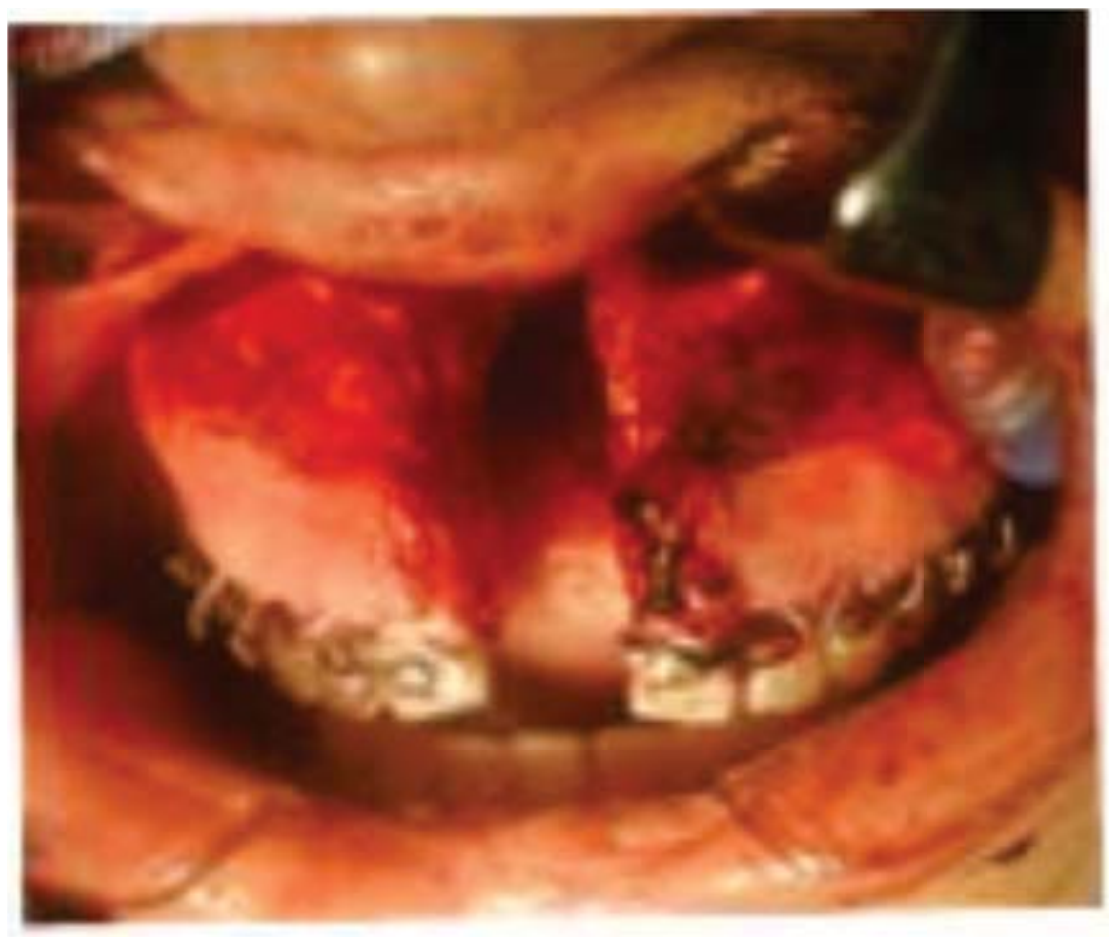

Figure 10. Maxillary segmentation.

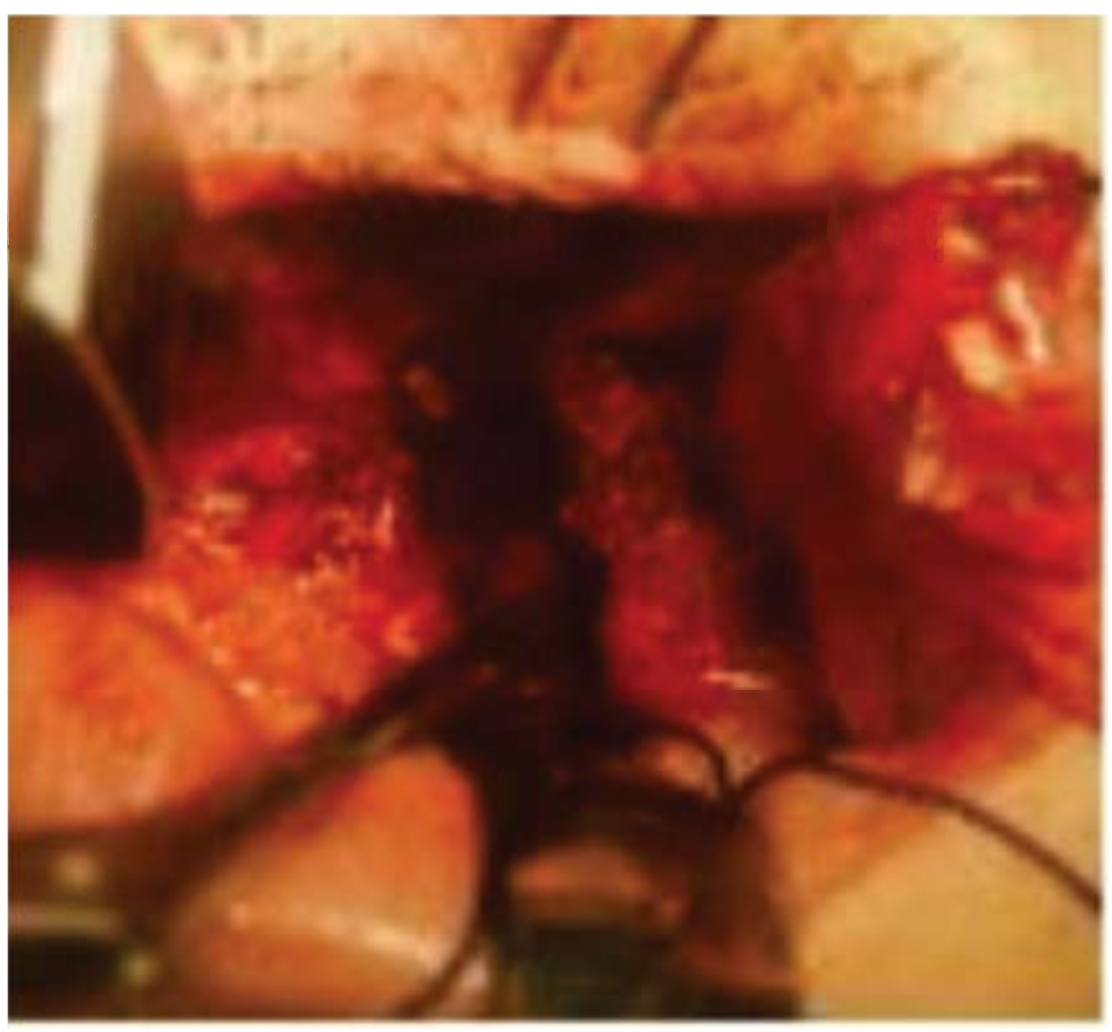

Figure 11. Maxillary segmentation in a lateral position with respect to the palatine raphe.

Figure 12. Lateral mobilization of maxillary segments.

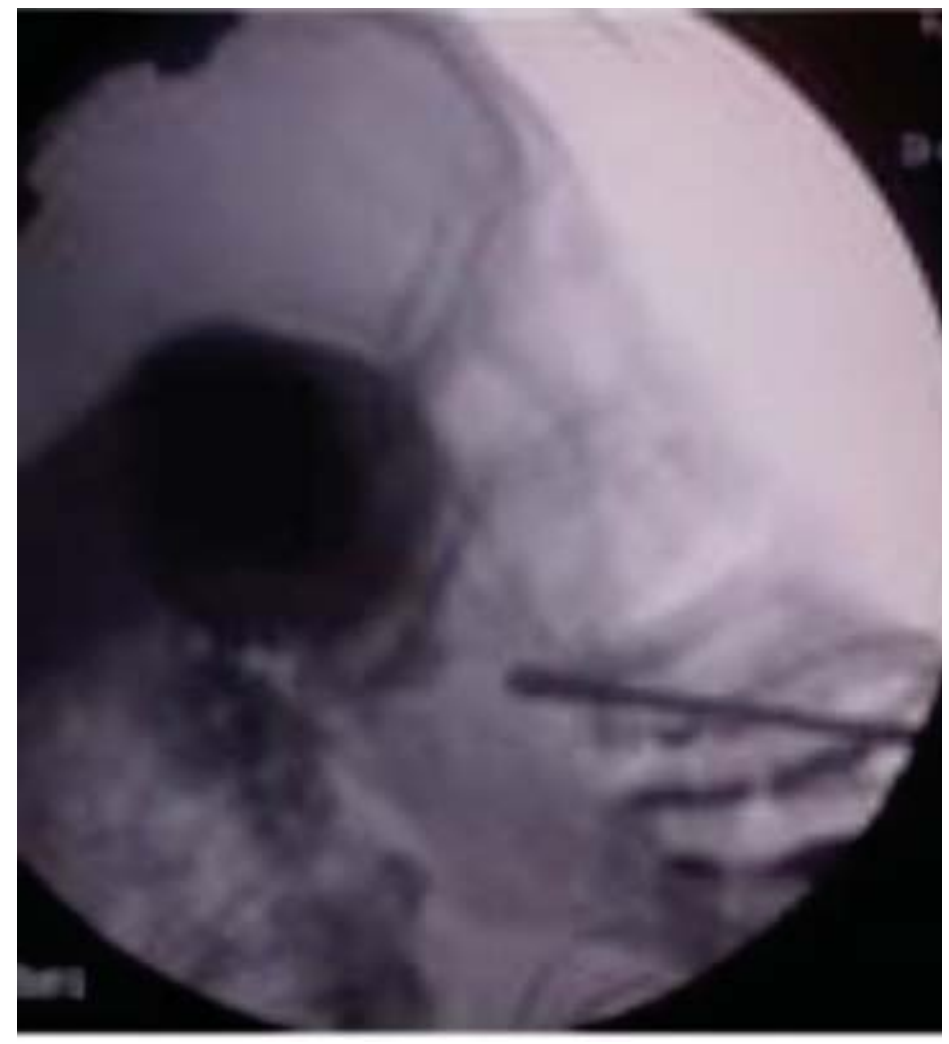

Figure 13.

Transoperative fluoroscopy.

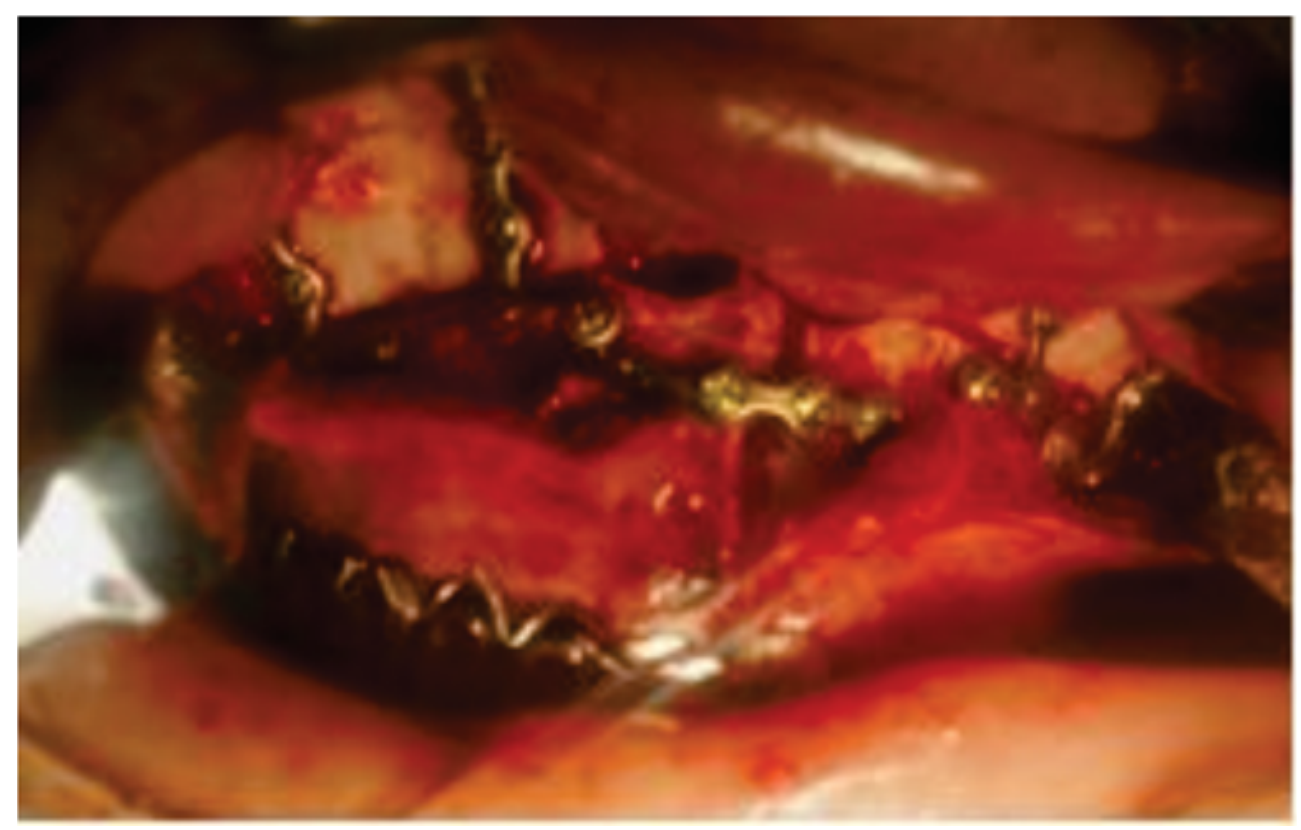

Figure 14. Rigid bone fixation.

Figure 15. Control tomography.

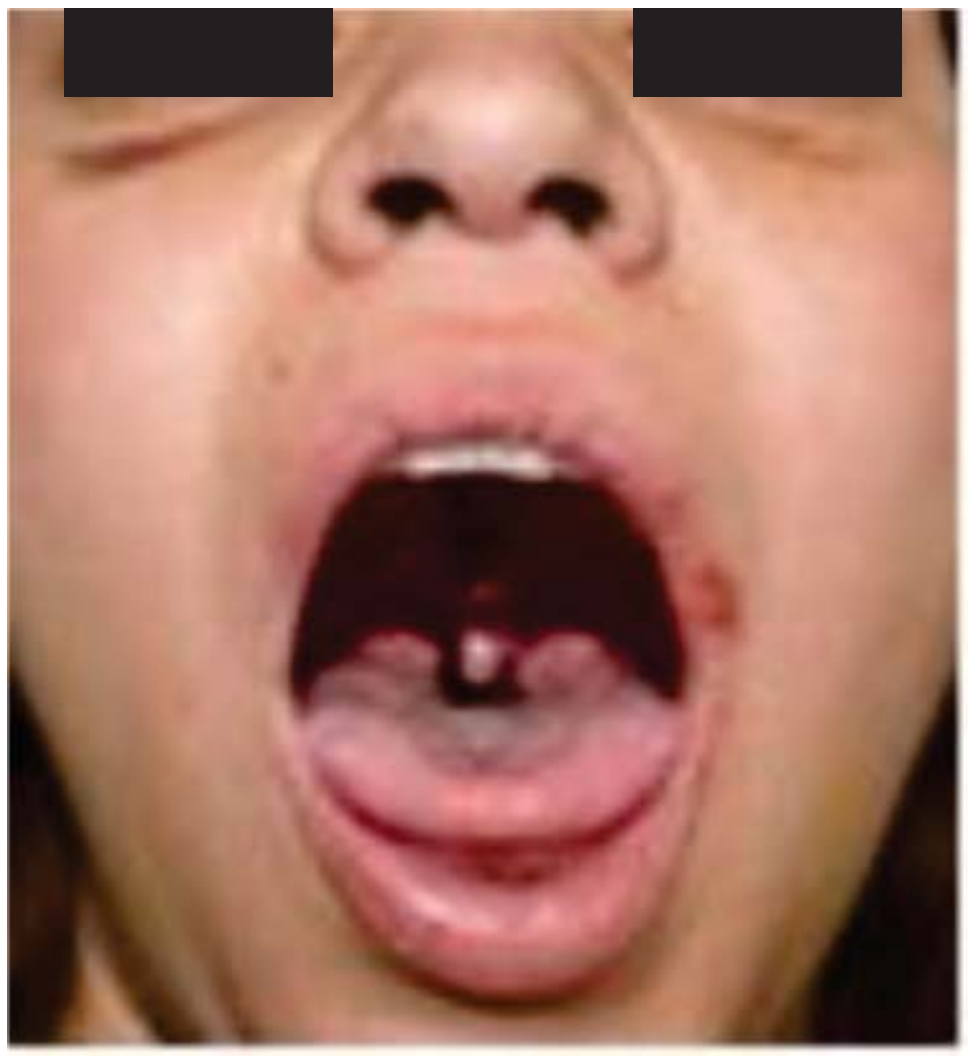

Figure 16. Postoperative appearance.

8) was initiated. After this, a palatal segmentation procedure was performed, which was located at approximately 3 mm on the right of the palatine raphe, so as to avoid damage to the neurovascular bundle found at this same location *(Figures 9 and 10)*. The soft palate was concurrently divided along the midline up to the uvula.

The upper jaw was retracted up to its extremes so as to expose the tumor area *(Figures 11 and 12)*. Once the approach was achieved, the neurosurgical team undertook to eliminate as much tumor as possible. Fluoroscopy proved to be a great adjuvant to observe at which level the operation was proceeding.[13]

Once the tumor was removed, the incision was closed; the soft palate was first sutured, and this was followed by upper jaw rigid bone fixation with the help of a 2.0 titanium plates system *(Figure 14)*.

Once the operation was deemed completed, antibiotic coverage was initiated and the patient was remitted to the Intensive Care Unit for the next four days. 24 hours after the operation, a control tomography was taken *(Figure 15)*. The patient evolved satisfactorily, therefore, she was discharged after seven days. The patient was asked to return after seven days, at that point, a suitable healing process was observed *(Figure 16)*.

DISCUSSION

Chordoma grow slowly, and are rarely metastatic. Nevertheless, even after radical intervention local recurrences are frequent. Disseminations along the surgical approach venue are also possible. The location of a clivus tumor and its proximity to two carotid arteries and multiple cranial nerves render complete resection almost impossible. Frequently treatment consist in a combination of surgery and radiotherapy (proton beams, focal radiotherapy and radio-surgery). Percentile yearly control rate published after proton beam treatment has been 55 to 70%.[3] Nevertheless, poorer prognosis is reported for female patients, for patients whose tumors manifest necrosis as seen in the images, and in cases when measured volume exceeded 70 mL.[7,8]

CONCLUSIONS

Due to their location and biological behavior, clivus chordoma represent a great challenge, especially when they are of a large size. Undoubtedly, surgery as well as approach, play a vital role in their treatment, even though total resection is hard to achieve. This type of tumors are very recurrent, tumor islands can be found at the skull base which could hardly have been observed during the surgical procedure. Nevertheless, the fact of performing an approach which might grant suitable visibility of the area will help resection of the largest possible tumor volume.

REFERENCES

1. Jatin Shah. *Cirugía y oncología de cabeza y cuello*. Capítulo 4, 3ª ed. Ed. Mosby. 2004. Madrid, España.
2. Rojas VR, Pacheco RL. Abordaje transmandibuloglosopalatino para base de cráneo. Reporte de un caso. *Revista Odontológica Mexicana*. 2005; 9 (1) 42-47.
3. Som MM, Curtin HD. *Radiología de cabeza y cuello*. 4ª ed. Ed. Elsevier. 2004, España.
4. Heffelfinger MJ, Dahlin DC, MacCarty CS, Beabout JW. Chordomas and cartilaginous tumors at the skull base. *Cancer*. 1973; 32 (2): 410-420.
5. Dalpra L, Malgara R, Miozzo M et al. First cytogenetic study of a recurrent familial chordoma of the clivus. *Int J Cancer*. 1999; 81 (1): 24-30.
6. Miozzo M, Dalpra L, Riva P et al. A tumor suppressor locus in familial and sporadic chordoma maps to 1p36. *Int J Cancer*. 2000; 87 (1): 68-72.
7. O'Connel JX, Renard LG, Liebsch NJ et al. Base of skull chordoma. A correlative study of histologic and clinical features of 62 cases. *Cancer*. 1994; 74 (8): 2261-2267.
8. Terahara A, Niemierko A, Goitein M et al. Analysis of the relationship betwen tumor dose inhomogeneity and local control in patients with skull base chordoma. *Int J Radiat Oncol Biol Phys*. 1999; 45 (2): 351-358.

RECOMMENDED READING

1. Harnsberger. *Serie de Radiología Clínica: 100 diagnósticos principales en cabeza y cuello*. Ed. Elsevier. 2004. España.
2. Langman. *Embriología médica*. Capítulo 21, 7ª ed. Ed. Médica Panamericana. 2005. Uruguay. pp. 49-55.

3. Felix I. *Tumores intracraneanos. Neuropatología*. Volumen I. Ed. Auroch. 1996. Paraguay. pp. 74-75.
4. Pardo FG. *Anatomía patológica*. Capítulo 35, Ed. El Sevier. España. pp. 1181-1270.
5. Moriki T, Takahashi T, Wada M, Ueda S, Ichien M, Miyazaki E. Chondroid chordoma fine-needle aspiration cytology with histopathological, immunohistochemical, and ultrastructural study of two cases. *Diagn Cytopathol*. 1999; 21 (5): 335-339.
6. Iwasa Y, Nakashima Y, Okajima H, Morishita S. Sacral chordoma in early childhood: clinicopathological and immunohistochemical. *Pediatr Dev Pathol*. 1998; 1 (5): 420-426.
7. York JE, Kaczaraj A, Abi-Said D, Fuller GN. Sacral cordoma: 40 years experience at a major cancer center. *Neurosurgery*. 1999; 44 (1): 74-79; discussion 79-80.
8. De Vita V, Hellman S, Rosenberg S. *Cáncer principios y práctica de oncología*. Tomo II. 2ª ed. Salvat. 1984. pp. 1244-1245.
9. Cheng EY, Ozerdemoglu RA, Transfeldt EE, Thompson RC Jr. Lumbosacral chordoma. Prognostic factors and treatment. *Spine*. 1999; 24 (16): 1639-1645.
10. Bouropoulou V, Bosse A, Roessner A, Vollmer E, Edel G, Wuisman T, Härle A. Immunohistochemical investigation of chordomas: histogenetic and differential diagnostic aspects. *Curr Top Pathol*. 1989; 80: 183-203.
11. Keisch ME, García DM, Shibuya RB. Retrospective long-term follow-up analysis in 21 patients with chordomas of various sites treated at a single institution. *J Neurosurg*. 1991; 75: 374-377.
12. Magrini SM, Papi MG, Marletta F, Tomaselli S, Cellai E, Mungai V, Biti G. Chordoma natural history, treatment and prognosis. The Florence Radiotherapy Department experience (1956-90) and a critical review of the literature. *Acta Oncol*. 1992; 31: 847-851.
13. Snow RB, Patterson RR. Surgical treatment of tumors of the clivus and basioccipital region. In: Schmidek HH, Sweet WH, editors. *Operative neurosurgical techniques*. 4ª ed. Orlando: Grune & Stratton Inc. 1988. pp. 635-646.
14. Eriksson B, Gunterberg B, Kindblom LG. Chordoma: a clinicopathologic and prognostic study of a Swedish national series. *Acta Orthop Scand*. 1981; 52: 49-58.
15. Rich TA, Schiller A, Suit HD, Mankin HJ. Clinical and pathologic review of 48 cases of chordoma. *Cancer*. 1985; 56: 182-187.
16. Gay E, Sekhar LN, Rubinstein E, Wright DC, Sen C, Janecka IP et al. Chordomas and chondrosarcomas of the cranial base: results and follow-up of 60 patients. *Neurosurgery*. 1995; 36: 887-896.
17. Guinto G, Abello J, Félix I, González J, Oviedo A. Lesions confined to the sphenoid ridge: differential diagnosis and surgical treatment. *Skull Base Surg*. 1997; 7: 115-121.

Mailing address:
Dr. Doroteo Vargas López
E-mail: doroteovargas@hotmail.com