



# Functional and aesthetical analysis of primary lip corrective surgery through the rotation and advancement modified technique of unilateral cleft lip

## *Análisis funcional y estético de labioplastia primaria mediante la técnica de rotación y avance modificada en labio hendido unilateral*

Israel Flores Clemente,\* Ana María Nieto Munguía§

### ABSTRACT

The aim of this study was to compile functional and aesthetical results obtained by the closure of unilateral cleft lip utilizing primary rotation and advancement modified technique in 5 patients (3M:2F), during a period of 8 months; these patients underwent surgery at the Regional Hospital Lic. Adolfo Lopez Mateos. Specific anatomical points were considered A, B, C, D. Measurements were monitored and recorded at the following stages: pre-surgical, one immediately after the surgery, and control measurements after one, two and three months. According to the statistical analysis significant changes were observed in relation to the vertical longitude obtained. When taking into account Friedman's Anova analysis it was found that for the longitude  $d1 = A^*-B^*$  there is a range  $P = 0.00344$ , with a vertical average response, with a 95% reliability range,  $d2 = C^*-D^*$ , range  $P: 0:001445$ ,  $d3 = A-B$ , range  $P: 0.0025$ ,  $d4 = C-D$ , range  $P: 0.01785$ , with a higher approximation to the healthy side longitude during the immediate post-surgical period. However this gained vertical longitude, after a month began to decrease getting further away from the post-surgical line, with a 27% vertical retraction and a 27% relaxation percentage and 48% stability period, bearing aesthetical impact with discreet vertical elevation of the vermillion edge in horizontal relation, simulating a triangle related to the scarring retraction which varies according to the length of the fissure. Along the scarring line reconstruction of the ridge of the affected side can be observed. The ridge can initiate in the central zone of the columella or slightly before, extending in oblique sense (lateral and inferiorly) up to the vermillion edge, forming a discrete concavity in its internal part and as well as convexity in the external part, simulating the absent philtrum crest, simultaneously contributing to the formation of the philtrum groove and bow of Cupid.

**Key words:** Cleft lip, lip corrective surgery, rotation and advancement.

**Palabras clave:** Labio hendido, labioplastia, rotación y avance.

### RESUMEN

El propósito del estudio fue el recopilar los resultados funcional y estético posterior al cierre de labio hendido unilateral mediante la técnica de labioplastia primaria de rotación y avance modificada, en 5 pacientes (3H:2M), en un periodo de 8 meses los cuales fueron operados en el Hospital Regional Lic. Adolfo López Mateos. Se tomaron en cuenta puntos anatómicos específicos A, B, C, D. Con un seguimiento y registro de longitudes: Prequirúrgica, postquirúrgica inmediata, control a uno, dos y tres meses. De acuerdo al análisis estadístico se tienen cambios significativos en relación a la longitud vertical ganada, tomando en cuenta el análisis ANOVA de Friedman encontramos que para la longitud de  $d1 = A^*-B^*$  hay un rango  $P: 0.00344$ , con una respuesta promedio vertical, con un rango de confiabilidad del 95%,  $d2 = C^*-D^*$  rango  $P: 0:001445$ ,  $d3 = A-B$  rango  $P: 0.00255$ ,  $d4 = C-D$  rango  $P: 0.01785$ , con mayor aproximación a la longitud del lado sano en el postquirúrgico inmediato, sin embargo esta longitud vertical ganada posterior al mes comienza a disminuir, alejándose del resultado obtenido en el postquirúrgico inmediato observando retracción vertical hasta un 27% con un porcentaje de relajación del 27% y un periodo de estabilidad del 48%, teniendo impacto estético con discreta elevación vertical del borde bermellón en relación horizontal simulando un triángulo relacionada con la retracción de cicatrización, la cual tiene variación dependiendo de la longitud de la hendidura. Por medio de la línea de cicatrización se observa reconstrucción de la cresta del lado afectado, la cual puede nacer en la zona central de la columna o ligeramente antes, prolongándose en sentido oblicuo (lateral e inferiormente) hasta el borde bermellón, formando discreta concavidad en su parte interna y convexidad externa, simulando la cresta filtral ausente, al mismo tiempo contribuye a la formación del surco filtral y arco de cupido.

\* Oral and Maxillofacial Surgeon.

§ Physician, Maxillofacial and Oral Service.

Regional Hospital Lic. Adolfo López Mateos -Mexico City- ISSSTE.

Received: 1 February 2008.

Accepted: 17 June 2010.

Este artículo puede ser consultado en versión completa en <http://www.medigraphic.com/facultadodontologiaunam>

### INTRODUCTION

The incidence of cleft lip and palate in Mexico is 1 per 850 of live births. 70% of the cases occur in male infants, 80% of which are unilateral, 70% on the left

side and 20% are bilateral. Relation of left cleft lip/right cleft lip/bilateral is 6:3:1. 70% of the unilateral cleft lips are associated with cleft palate and 85% of the bilateral cases are associated with cleft palate. In 7 and 13% of the cases there is an association with congenital malformations.<sup>3</sup>

Patients that present this abnormality are frequently isolated from social life and consequently suffer emotional disorders. Several techniques of lip corrective surgery have been developed to offer aesthetical results to thus enhance the emotional life of patients and their families.

The presentation of the rotation and advancement technique by Ralph Millard in 1955, contributed to change the world of lip corrective surgery. Modifications continued from 1975 onwards, and results were thus notoriously better.<sup>1,2,4</sup>

Taking into consideration the natural union zones among the facial growing processes, the rotation and advancement technique restores the structures that for any reason were not adequately united. Other techniques only close the defect, leaving scars that cross the lip.<sup>1,7-11</sup>

It is important to consider that to get the best aesthetical results the scars should be located in the union line of the facial processes. All anatomical structures are present in cleft lips. It is extremely important to identify the ridges of the bow of Cupid in both sides of the cleft.<sup>1</sup>

Lip surgery with functional, aesthetical or reconstructive purposes is known as Lip Plasty. There are several techniques according to the different alterations of congenital cleft lip which produce different aesthetical results.<sup>5</sup>

Among the described techniques are the following

**Triangular Flaps.** Based in geometrical traces, this surgical technique was created by Tennison and Randall (1952-1959). It consists on the advancement of the lateral segment that includes an inferior triangular flap to cover a similar defect in the medial segment as a result of the horizontal shift of the bow of Cupid. It has been used in the complete cleft lip and palate with moderate amplitude. After surgery the anatomy of the lip is restored. However with this technique the suture line crosses the philtrum, so, in a long term, scarring becomes more apparent; the bow of Cupid is not well outlined. In large fissures where the lip can have tension, there is a risk to suffer necrosis in the external vertex of the equilateral triangle.<sup>2,3,6</sup>

**Rectangular flaps (Le Mesurier).** From a technical point of view it could be easier to handle quadrangu-

lar flaps than triangular flaps, the necrosis risk being always lower.

In large, wide fissures when the rotation to the external flap is 90°, the estimation of the height of the cleft lip is reckoned through an accurate procedure (longitudes addition), since the scar is Z type it is not retractile. Nevertheless, the following several complications can arise:

- Transversal incision lines in the middle of the lip, cutting the philtrum
- The height of the cleft side cannot be ascertained as accurately in small fissures when the quadrangular flap is not rotated 90° as in the wider fissures where the rotation given to the quadrangular flap is 90 degrees and do not outline properly the bow of Cupid. This is frequently due to the fact that the incision line corresponding to the height of the cleft side impinges upon the arch of cupid, resuting thus in an insufficient arch of Cupid.<sup>2,3</sup>

#### MODIFIED ROTATION AND ADVANCEMENT TECHNIQUE

The incision has to be done around the nasal wing following the nasal-facial fold. In this fashion, the nasal wing can be easily dissected and re-located, furthermore this incision is used to dissect the cartilage of the nasal wing and place it in its right position.

The incision of the base of the columella is normally initiated at the middle line level. In the cases where the proximal edge it is notoriously more common, the incision can be initiated at the columella base level of the healthy side. The incision should not be prolonged beyond the base of the columella, since it would deteriorate aesthetic results. When initiating the incision, it must follow a horizontal direction, at a later point the procedure continues with a curve convex to the fissure, which is going to represent 70% of the lip's vertical dimension.

In both sides the superior curvature corresponds to 60% of the total height of the lip, the following 20% of the height makes up the edge (a straight line) and in the distal edge, by a slight concave curvature to the fissure, both curvatures represent 80% of the total height of the lip in its upper part. The 20% of the inferior curvature is concave to the fissure in both sides and determines the angle that will form the bow of cupid of the figurative side. The incidence angle to the white line is 65° and must be the same at both sides of the fissure. The upper curve determines the length of the lip due to its downward displacement, the inferior curvature compensates the direction of

the displacement, and allows a tension free encounter with the opposite side.

The tissues remaining between the fissure and the incision are to be used to reconstruct the nasal floor and the vermillion edge, this must be considered to leave enough skin and muscle of the superior third to reconstruct the nasal floor step and the leave the flaps included in the vermillion border with enough tissue to reconstruct the vermillion edge.

The nasal floor is constructed in two levels, the muscular level is dissected and a muscular flap is taken to the other side under the skin. The remaining skin is eliminated; both flaps are sutured to form the step that is found at the nostril. Finally, the lines that follow the scar are the same lines of union of the growing processes of the labial area.<sup>1,3</sup>

### SURGICAL INCISIONS

The skin is incised with a No.15 blade scalpel. A single movement is done from the base of the columella or the wing of the nose depending on the side involved up to the white line before cutting the vermillion skin.

The muscle is incised with a No. 11 blade scalpel with back and forth movements. To achieve an homogeneous thickness in the edge of the flaps, the muscular incision in the thin areas must be done in tangential direction, leaving a thicker edge if the incision had been done perpendicular to the skin surface, the border would have resulted thinner. Therefore, when suturing, the contact surface with its counterparts is more significant than what they originally had.

Once skin and muscle are incised the edge of the flap must be preserved intact. This tissue bridge is sectioned at the union of the third upper and the medium level, leaving skin in the upper flap and almost all the vermillion border in the lower one. This procedure is done in both sides. Haemostasis is achieved through traction of both flaps avoiding the use of haemostatic pliers and furthermore the use of unnecessary suture material on the muscular mass. While the flaps are retracted, 2 or 3 mm of skin of the muscle are dissected and the same is done in the mucosa, in a parallel direction to the surface of the epithelium. Care must be taken of having both flaps with same thickness all along the lip.

Lip flaps may present certain resistance to face one another, in these cases, they must be freed from their muscular insertions at the anterior wall level (primary rhynoplasty) to the maxilla.

### CLOSURE OF LIP FLAPS

The oral mucosa is sutured. It is rectangle shaped in both sides. These flaps must be stitched to each other from the vestibular base to the mucosa-vermillion union with a 3-0 polyglycolic acid suture. The mucosal vestibular edge of the flaps is stitched to the vestibular mucosa fixed in the process, this might be achieved through the mouth or through the nasal floor.

To stitch the muscle three sutures are required, the first is placed from the distal semi-circle of the flap to the corned formed at the base of the columella when tissue is separated. The second suture is applied midway to the distance between the first and third sutures. Finally, the third suture is applied at the white line level. Sutures must encompass the whole thickness of the muscle.

The skin is sutured with 5-0 nylon, the first suture is placed between the semi-circle and the base of the columella, the second suture is applied between the white lines of each flap, following the rule of the halves the suture of the skin is finished.

### NASAL FLOOR RECONSTRUCTION

The flaps that correspond to the nasal floor are brought to face each other, excess skin is eliminated and the flaps are sutured, once the nasal ala is re-set in its right position, it is stitched into the nasal-facial fold level.

Vermillion edge construction flap, the most appropriate one is chosen taking into consideration thickness, circulation and external aspect, emphasizing the matatching of the wet and dry line vermillion line surfaces with its counterpart. A tangential incision is done in the less adequate flap and then another in the same direction en the most appropriate, the purpose of this is having the second flap (the most adequate) cover the first one. In cases where a flap would have a very thin vermillion and the other a much thicker one, a muscular flap might be used to compensate the deficiency.

The wing cartilage is temporarily fixated at the nasal tip level and the nasal valve level with 2-0 nylon suture. To form the nasal tip, a suture is placed at the nasal dome level. The nasal wing is relocated and the wing lateral cartilage of the caudal border is fixated, reconstructing thus the nasal valve.<sup>1</sup>

### MATERIAL AND METHODS

In this study the primary lip corrective surgery was performed following the rotation and advance-

ment modified technique in 5 pediatric patients (3M:2F) that presented unilateral cleft lip or unilateral lip and palate cleft (3R:2L) and sought treatment at the Hospital Regional Lic. Adolfo Lopez Mateos.

The purposes were to analyze

- the vertical length of the lip in the cleft side before and after the surgical procedure.
- The aesthetical results pertaining to form and location of the philtrum ridge formed at the site of the cleft after the lip corrective surgery.
- Results pertaining vertical and horizontal continuity of the vermillion edge.

Patients were found within the parameters of the pair rules: 0 systemic diseases, 2 anesthetic risk, 4 months of age, 6 kilos of weight,  $8,000/\text{mm}^3$  of leucocytes, 10 g/mL of hemoglobin, 12 seconds in prothrombin partial time.

With respect to age, patients older than 4 months were included with provision of counting with minimum acceptable levels of hemoglobin 10 g/mL and body weight of 6 kilograms.

Patients with bilateral cleft lip or central cleft palate were excluded, as well as patients who did not reach the minimum body weight of 6 kilograms or count with the minimum hemoglobin score of 10 g/mL.

## STUDY GENERAL DESCRIPTION

A prospective, comparative research was carried out. Certain specific reference points taken in the healthy side as well as in the affected one:

Point A: Columella and upper lip union.

Point B: Philtrum ridge and vermillion edge union.

Point C: Nasal wing inner side and upper lip union.

Point D: Lip corners (*Figures 1 and 2*).

To distinguish the affected side from the healthy one an asterisk was added to the letters A\*, B\*, C\* and D\* on the analysis (*Figures 3 and 4*).

Measurements were taken (*Tables I and II*) joining points A-B and points C-D in both healthy and affected sides. These measurements were taken before and immediately after the surgery and at one, two and three months after the surgery.

With the help of these measurements the vertical length between the columella and the upper lip were analyzed in the healthy side and in the affected one.

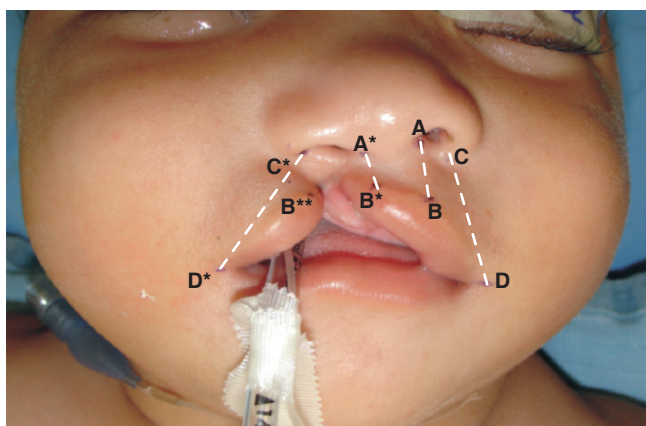
The continuity of the vermillion edge (formed between the healthy and the affected side) was assessed.

## COMPILED RESULTS

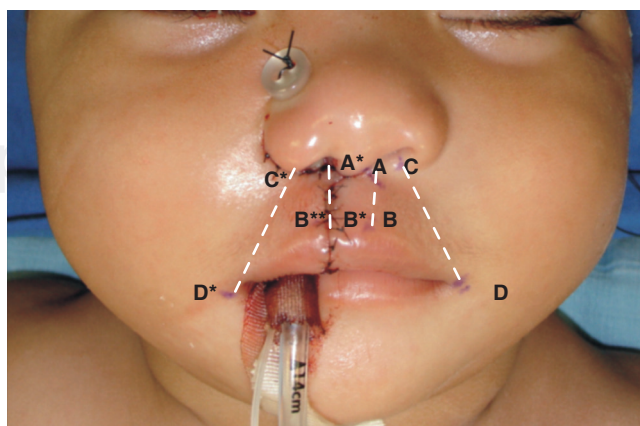
### Aesthetical analysis results

With respect to the side of the philtrum ridge, we can observe the following:

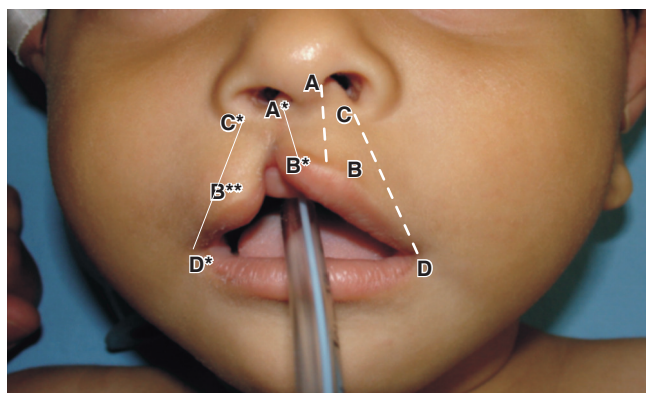
With the help of the scar line the (*Figures 5 and 6*), the reconstruction of the ridge of the affected side is observed, it can initiate at the central portion of the columella or slightly before the central zone; it originates in the healthy side and continuing in an oblique direction (laterally and inferiorly) to the vermillion edge forming a mild concavity in its internal part and a convexity in the external segment, to simulate the absent philtrum ridge, at the same



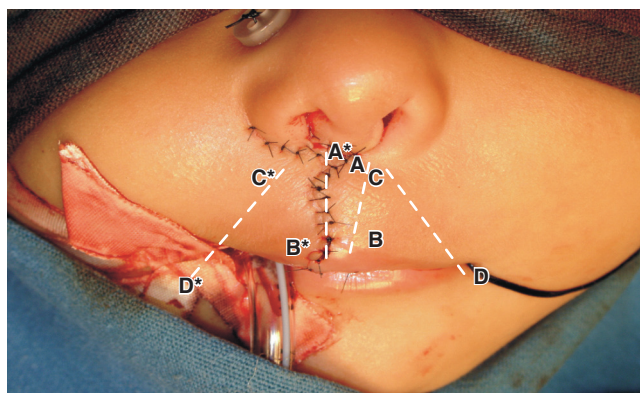
**Figure 1.** Before surgery.



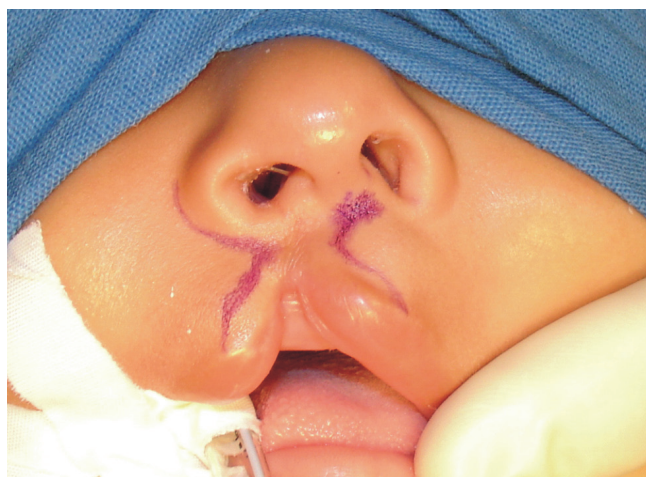**Figure 2.** Immediately after surgery.



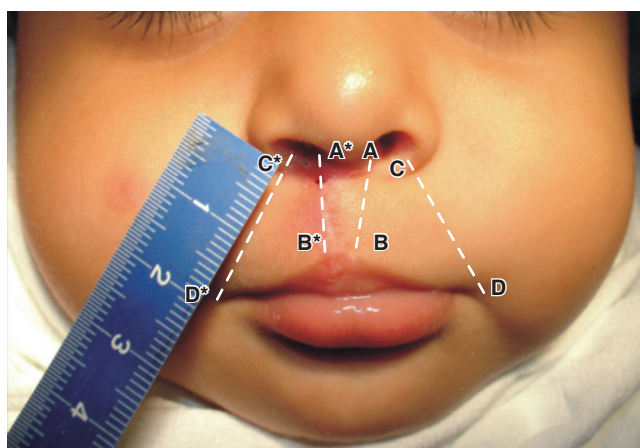
**Figure 3.** Before surgery.



**Figure 5.** Immediately after surgery.



**Figure 4.** Design for lip reconstruction surgery.



**Figure 6.** One month after surgery.

time contributing to form the philtrum and the bow of Cupid.

A slight vertical elevation is observed at the vermilion edge in horizontal relation simulating a triangle and related to the scar retraction that varies according to the length of the cleft.

### LONGITUDINAL ANALYSIS RESULTS

Through a prospective, comparative research and according to the statistical analysis, significant changes are observed in relation to the vertical length gained after the primary lip corrective surgery. Taking into consideration the ANOVA/Friedman analysis (*Figures 7, 8, 9 and 10*), it was found that for the length from:

d1 = A\*-B\* there is a range P: 0.00344, with a vertical average response with reliability range of 95%, length.

d2 = C\*-D\* range P: 0.001445

d3 = A-B range P: 0.00255

d4 = C-D range P: 0.01785 with greater approximation to the length of the healthy side in the immediate post-surgical.

In the comparative analysis (*Figures 11 and 12*) between d1 = A\*-B\* and d3 = A-B, can be seen a greater approximation of the vertical length of the affected side in relation to the healthy one in the immediately after surgery, however this vertical length tends to diminish after a month of the surgical procedure, getting further away from the immediate result.

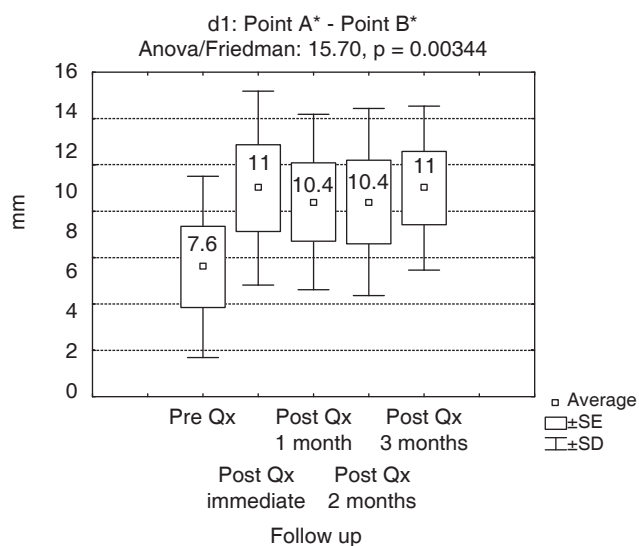
According to the distribution of the events after the lip corrective surgery (*Figure 13*) it can be observed that there is a vertical retraction up to 27% with a re-

**Table I.** Measurements obtained during the study.

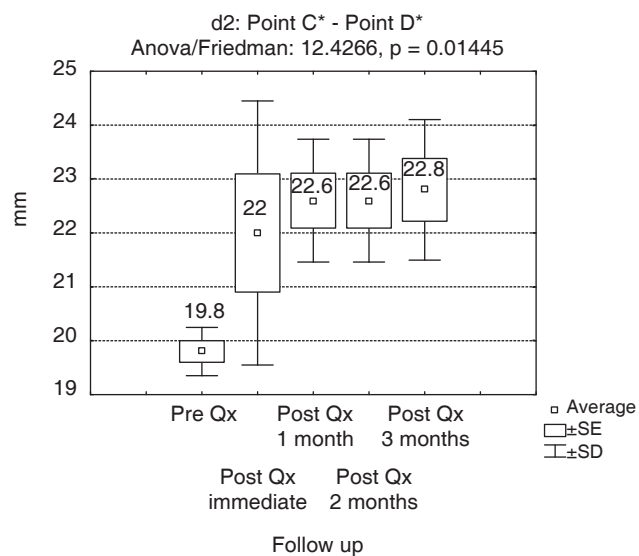
Surgery	Pre-surgical measurement	Immediate post-surgical	After a month	After two months	After three months
Patient 1					
Healthy side	Point A – Point B 9 mm	Point A – Point B 10 mm	Point A – Point B 10 mm	Point A – Point B 10 mm	Point A – Point B 11 mm
Affected side	Point A* – Point B* 6 mm	Point A* – Point B* 9 mm	Point A* – Point B* 9 mm	Point A* – Point B* 8 mm	Point A* – Point B* 9 mm
Healthy side	Point C – Point D 24 mm	Point C – Point D 25 mm	Point C – Point D 25 mm	Point C – Point D 26 mm	Point C – Point D 26 mm
Affected side	Point C* – Point D* 19 mm	Point C* – Point D* 19 mm	Point C* – Point D* 23 mm	Point C* – Point D* 23 mm	Point C* – Point D* 23 mm
Vertical length		3mm	3mm	2mm	3mm
Patient 2					
Healthy side	Point A – Point B 15 mm	Point A – Point B 17 mm	Point A – Point B 17 mm	Point A – Point B 17 mm	Point A – Point B 17 mm
Affected side	Point A* – Point B* 13mm	Point A* – Point B* 17 mm	Point A* – Point B* 16 mm	Point A* – Point B* 16 mm	Point A* – Point B* 16 mm
Healthy side	Point C – Point D 24 mm	Point C – Point D 25 mm	Point C – Point D 25 mm	Point C – Point D 26 mm	Point C – Point D 26 mm
Affected side	Point C* – Point D* 20 mm	Point C* – Point D* 25 mm	Point C* – Point D* 24 mm	Point C* – Point D* 24 mm	Point C* – Point D* 24 mm
Vertical length		4 mm	3 mm	3 mm	3mm

**Table II.** Measurements obtained during the study.

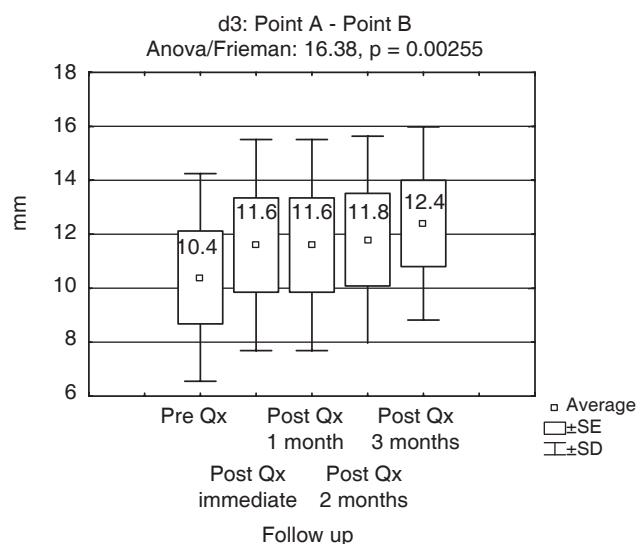
Surgery	Pre-surgical measurement	Immediate post-surgical	After a month	After two months	After three months
Patient 3					
Healthy side	Point A – Point B 5 mm	Point A – Point B 7 mm	Point A – Point B 7 mm	Point A – Point B 7 mm	Point A – Point B 8 mm
Affected side	Point A* – Point B* 3 mm	Point A* – Point B* 6 mm	Point A* – Point B* 6 mm	Point A* – Point B* 6 mm	Point A* – Point B* 7 mm
Healthy side	Point C – Point D 23 mm	Point C – Point D 23 mm	Point C – Point D 23 mm	Point C – Point D 23 mm	Point C – Point D 23 mm
Affected side	Point C* – Point D* 20 mm	Point C* – Point D* 21 mm	Point C* – Point D* 22 mm	Point C* – Point D* 22 mm	Point C* – Point D* 22 mm
Vertical length		3mm	3mm	3mm	4mm
Patient 4					
Healthy side	Point A – Point B 13 mm	Point A – Point B 14 mm	Point A – Point B 14 mm	Point A – Point B 14 mm	Point A – Point B 15 mm
Affected side	Point A* – Point B* 10 mm	Point A* – Point B* 13 mm	Point A* – Point B* 12 mm	Point A* – Point B* 13 mm	Point A* – Point B* 13 mm
Healthy side	Point C – Point D 24 mm	Point C – Point D 25 mm	Point C – Point D 25 mm	Point C – Point D 25 mm	Point C – Point D 25 mm
Affected side	Point C* – Point D* 20 mm	Point C* – Point D* 24 mm	Point C* – Point D* 23 mm	Point C* – Point D* 23 mm	Point C* – Point D* 24 mm
Vertical length		3 mm	2 mm	3 mm	3mm
Patient 5					
Healthy side	Point A – Point B 10 mm	Point A – Point B 10 mm	Point A – Point B 10 mm	Point A – Point B 11 mm	Point A – Point B 11 mm
Affected side	Point A* – Point B* 6 mm	Point A* – Point B* 10 mm	Point A* – Point B* 9 mm	Point A* – Point B* 9 mm	Point A* – Point B* 10 mm
Healthy side	Point C – Point D 22 mm	Point C – Point D 22 mm	Point C – Point D 22 mm	Point C – Point D 22 mm	Point C – Point D 22 mm
Affected side	Point C* – Point D* 20 mm	Point C* – Point D* 21 mm	Point C* – Point D* 21 mm	Point C* – Point D* 21 mm	Point C* – Point D* 21 mm
Vertical length		4 mm	3 mm	3 mm	4mm



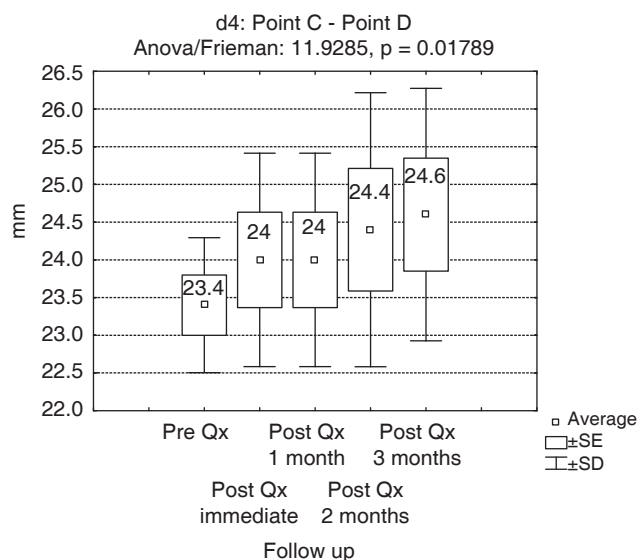
**Figure 7.** Longitudinal analysis of the vertical distance in the affected side.



**Figure 8.** Longitudinal analysis of the vertical distance in the affected side.



**Figure 9.** Longitudinal analysis of the vertical distance in the healthy side.



**Figure 10.** Longitudinal analysis of the vertical distance in the healthy side.

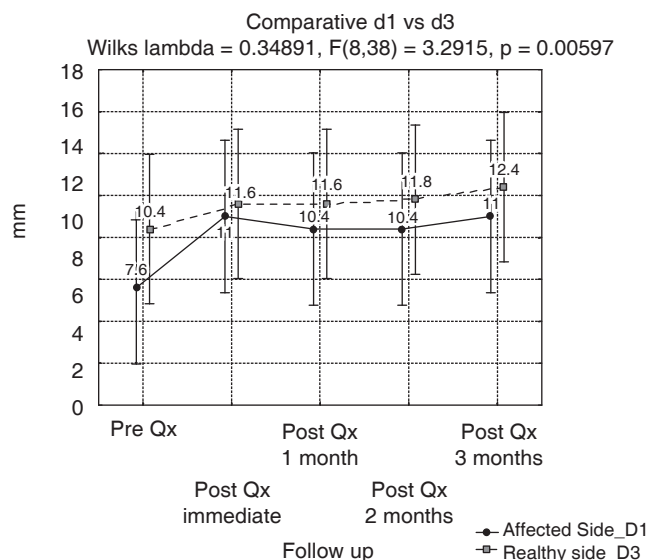
www.medigraphic.org.mx

laxation percentage of 27% and a stability period, this means, maintaining an stable length after the initial retraction of up to 48%.

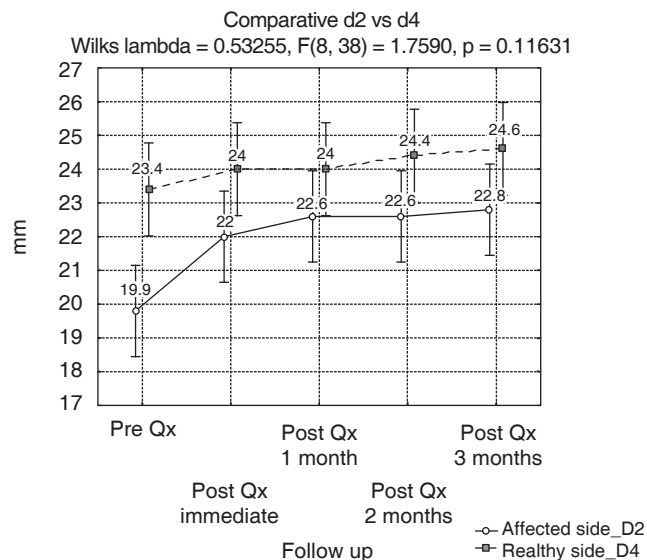
## CONCLUSIONS

The functional and aesthetical analysis of the lip corrective surgery through the rotation and advance-

ment modified technique shows satisfactory results. Achieving adequate immediate post-surgical length as well as during the evolutionary process. Emphasis is placed on the fact that aesthetic changes are proportional in longitudinal sense in the graphics and that it is evident the retraction and the relaxation of the scar comes closer to the range of the healthy side.

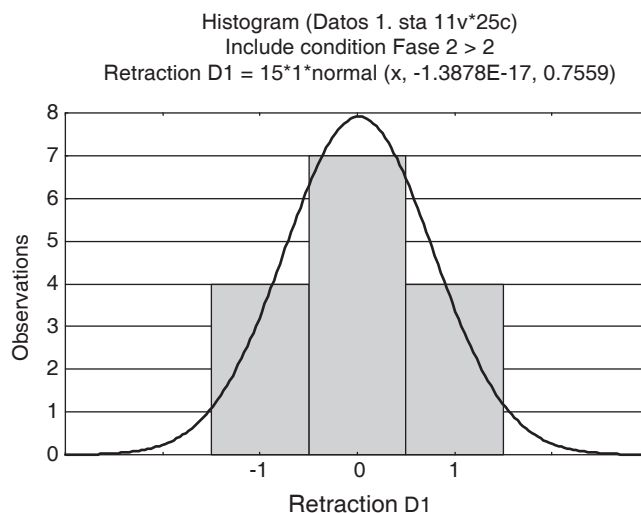


**Figure 11.** Average response of the vertical distance d1 vs d3 with confidence intervals 95% (p = 0.02535 at beginning, p = 0.00597 three months).



**Figure 12.** Average response of vertical distance d2 vs d4 with confidence intervals 95% (p = 0.02535 at beginning, p = 0.1163 three months).

With respect to the resulting scar line of the surgical procedure, it replaces successfully the philtrum ridge, however, in patients lacking adequate post surgical hygiene it can be very evident, resulting in a very thick scar which affects the philtrum ridge and the vermillion edge union line giving thus the impression of greater retraction.



**Figure 13.** Distribution of retraction events (-1) 27%, relaxation (1) 27% and no changes (0) 46% during follow up.

Scar defects are minimal in horizontal sense; these can be easily corrected during primary surgical reconstruction of the palate.

## REFERENCES

- Campos MA, López SML. Modificación a la labioplastia de rotación y avance para labios uni o bilateralmente hendidos. *Revista ADM* 1993; 1: 24-29.
- Millard DR. *Cleft craft*. Vol. 1. Boston (MA): Little Brown; 1976: 165-73.
- Rozen FI. *Labio y paladar hendido conceptos básicos*. México: Interamericana; 2000.
- Fonseca JR, Baker BS. *Oral and Maxillofacial Surgery, Cleft/Craniofacial/ Cosmetic Surgery*. USA: Edit.; W.B. Saunder Company. 2000: 27-60.
- Christofides E, Potgieter A, Chait L. A long term subjective and objective assessment of the scar in unilateral cleft lip repairs using the Millard technique without revisional surgery. *Journal of Plastic, Reconstructive & Aesthetic Surgery* 2006; 59: 380-386.
- Bilwatsch S, Kramer M, Haeusler G, Schuster M, Wurm J, Vairaktaris E, Wilhelm NF, Nkenke E. Nasolabial symmetry following Tennison-Randall lip repair: A three-dimensional approach in 10-year-old patients with unilateral clefts of lip, alveolus and palate. *Journal of Cranio-Maxillofacial Surgery* 2006; 34: 253-262.
- Kasuya M, Sawaki Y, Ohno Y, Ueda M. Psychological study of cleft palate children with or without cleft lip by kineticfamily drawing. *Journal of Cranio-Maxillofacial Surgery* 2000; 28: 373-379.
- Yamada T, Mori Y, Minami K, Mishima K, Sugahara T, Sakuda M. Computer aided three-dimensional analysis of nostril forms: application in normal and operated cleft lip patients. *Journal of Cranio-Maxillofacial Surgery* 1999; 27: 345-353.
- Yamada T, Mori Y, Mishima K, Sugahara T. Nasolabial and alveolar morphology following presurgical orthopaedic treatment in complete unilateral clefts of lip, alveolus and palate. *Journal of Cranio-Maxillofacial Surgery* 2003; 31: 343-347.

10. Powar RS, Patil SM, Kleinman ME. A geometrically sound technique of vermilion repair in unilateral cleft lip. *Journal of Plastic, Reconstructive & Aesthetic Surgery* 2006; 6: 1-4.
11. Schendel S, Montgomery K, Sorakin A, Lionetti G. A surgical simulator for planning and performing repair of cleft lips. *Journal of Cranio-Maxillofacial Surgery* 2005; 33: 223-228.
13. Yamada T, Mori Y, Minami K, Mishima K, Sugahara T. Three-dimensional facial morphology, following primary cleft lip repair using the triangular flap with or without rotation advancement. *Journal of Cranio-Maxillofacial Surgery* 2002; 30: 337-4

#### ADDITIONAL REFERENCES

12. Anastassov Y, Chipkov C; Analysis of nasal and labial deformities in cleft lip, alveolus and palate patients by a new rating scale: preliminary report. *Journal of Cranio-Maxillofacial Surgery* 2003; 31: 299-303.

Mailing Address:

**Ana María Nieto Munguía**

Hospital Regional Adolfo López Mateos ISSSTE.

Cirugía Oral y Maxilofacial.

Av. Universidad Núm. 1321

Col. Florida, 01030 Del. Álvaro Obregón.

México, D.F.

E-mail: annie\_tit@hotmail.com