Revista Médica del
Hospital General de México

PERMANYER

Check for updates

CLINICAL CASES

Endovascular repair of a complex ulcer of the descending thoracic aorta

Félix J. Monte De Oca-Hernández and Miguel A. Sierra-Juárez*

Department of Angiology and Vascular Surgery, Hospital General de México Dr. Eduardo Liceaga, Mexico City, Mexico

Abstract

Introduction: *Penetrating aortic ulcer is a focal lesion that develops in the region of an atheromatous plaque that penetrates the internal elastic lamina of the vascular wall. It can occur in any of the aortic segments and is the rarest entity of acute aortic syndrome, also composed of aortic dissection and intramural hematoma.* **Case presentation:** *It may be present together or isolated with dissection and intramural aortic hematoma, which, if not treated adequately and correctly, compromises the life of those who suffer from it.* **Conclusion:** *The study aimed to demonstrate the benefits of endovascular repair of the components of acute aortic syndrome: aortic ulcer and intramural hematoma.*

Keywords: *Aortic ulcer. Endovascular repair. Acute aortic syndrome. Descending thoracic aorta.*

Introduction

Penetrating aortic ulcer was first described by Sheenan T but differentiated from other aortic pathologies by Stanson in 1986 during his report on penetrating atherosclerotic ulcers of the thoracic aorta[1]. Penetrating aortic ulcer represents one of the entities of acute aortic syndrome, which develops in the area of an atheromatous plaque that penetrates the internal elastic lamina of the vascular wall or due to inflammatory changes in the aortic wall. Risk factors for its development include hypertension, male sex, smoking, atherosclerosis, previous aortic operations, and connective tissue disorders. These may be asymptomatic and only be detected incidentally in imaging studies, or they may cause symptoms of chest pain, mild abdominal pain, chronic low back pain, or dyspnea[2,3].

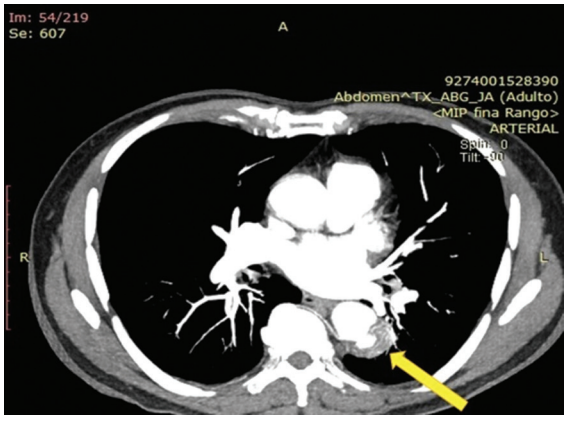

Figure 1. The ulcerated lesion of the descending thoracic aorta indicated by the yellow arrow.

The clinical tendency of penetrating aortic ulcers is variable; they may remain stable, increase in size, or progress to an intramural hematoma, dissection, pseudoaneurysm, or aortic rupture if the ulcer ruptures the adventitia.

***Correspondence:**
Félix J. Monte De Oca-Hernández
E-mail: montedeocahernandez@gmail.com

Date of reception: 06-08-2022
Date of acceptance: 12-09-2023
DOI: 10.24875/HGMX.22000051

Available online: 30-05-2024
Rev Med Hosp Gen Mex. 2024;87(Supl 1):44-47
www.hospitalgeneral.mx

0185-1063/© 2023 Sociedad Médica del Hospital General de México. Published by Permanyer. This is an open access article under the CC BY-NC-ND license (http://creativecommons.org/licenses/by-nc-nd/4.0/).

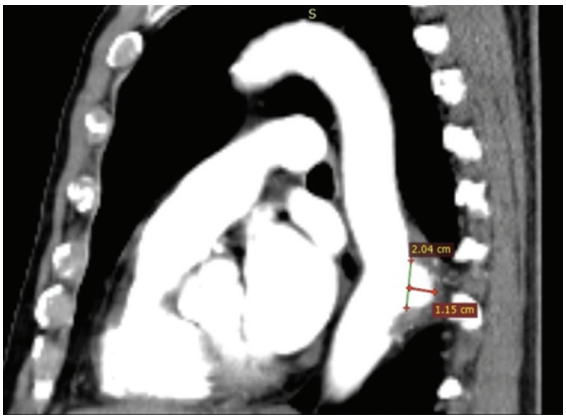

Figure 2. Ulcer measurements.



Figure 3. Aortography showing the aortic ulcer indicated by yellow arrow.

The development of multiple endovascular technologies (guides, endoprostheses, intravascular ultrasound, and catheters) has allowed a better understanding and resolution of this type of pathologies. Furthermore, endovascular aortic ulcer repair offers a less invasive approach to the treatment of affected patients, with very encouraging results in the short and medium term, thus reducing mortality and comorbidities for the benefit of those with this type of vascular disease[3].

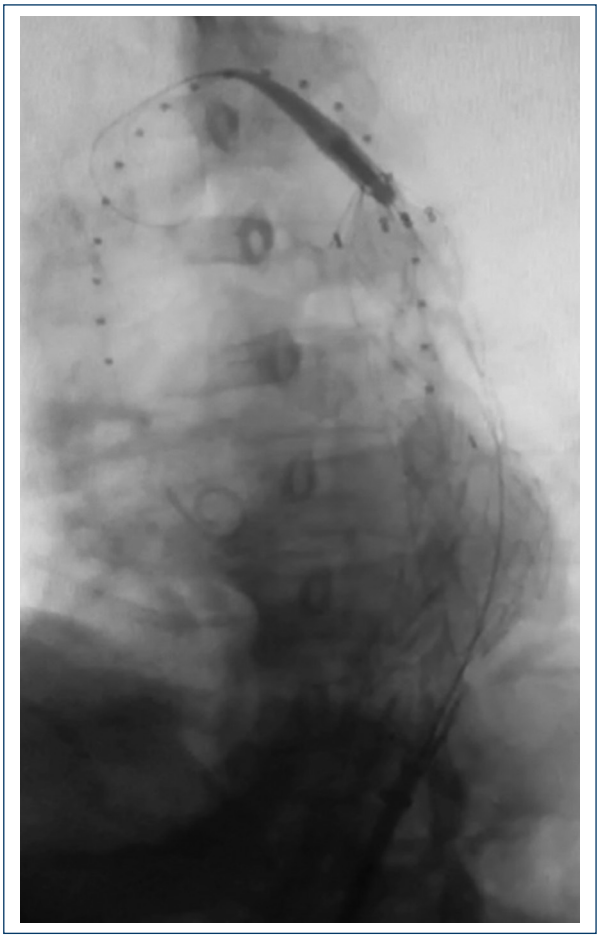

Figure 4. Endoprosthesis release to exclude aortic ulcer.

Case report

A 76-year-old male patient with a history of systemic arterial hypertension and a smoker, who came to the emergency department due to chest pain radiating to the back suddenly and progressively, without cardiac alterations. The angiotomography shows an ulcerated lesion at the level of the descending thoracic aorta measuring 2.04 cm deep by 1.15 cm long associated with intramural hematoma (Figs. 1 and 2). The patient is referred to our service for case evaluation and treatment.

Due to the clinical characteristics of the patient, the anatomical location for approaching the lesion and evaluating the high risk of aortic rupture, and endovascular repair with the Valiant™ Captivia Stent Graft



Figure 5. Post-surgical outcome.

stent graft with the Captivia™ Delivery System was scheduled, after meticulous planning surgery of the case. The lesion was excluded without complications (Figs. 3-5).

Discussion

An aortic ulcer diameter > 15 mm represents a high risk of disease progression toward aortic dissection, the appearance of pseudoaneurysm, or aortic rupture, with greater comorbidity. Patients benefit from early intervention in principle through aggressive blood pressure control with intravenous β-blockade and aggressive analgesia to control pain if present. In addition: Once the patient is stabilized, endovascular surgery should be performed. Exclusion of the aortic ulcer as long as adequate surgical planning is carried out and the aortic anatomy allows it[3-5].

In the endovascular repair of the aortic ulcer, we can obtain better data on the anatomical and topographic characteristics of the pathology, in addition, the accessibility to the affected area is faster, less morbid, and with excellent results.

One concern about performing endovascular repairs of this type of pathology lies in the potential risk of progression to aortic dissection. This iatrogenic complication could be caused by the oversizing of the graft through the aortic wall in the proximal or distal landing zones. To avoid this complication, the area of ulceration must be completely excluded and at a safe landing distance of the endoprosthesis > 20 mm from the edge.

Without a doubt, the open surgical repair procedure in these patients adds complexity and, in turn, greater

morbidity and mortality, which is why it is currently displaced by endovascular procedures. In Mexico, there is no database where the evolution results of this type of pathology can be compared.

We decided to repair this pathology using an endovascular technique to precisely prevent its progression and unfavorable repercussions for the patient's quality of life. With the procedure, we achieved complete exclusion of the injury, without complications for the patient and with a satisfactory recovery, in addition, after being discharged from the hospital 48 h after the procedure.

Conclusion

Endovascular repair of the pathologies that make up acute aortic syndrome is a highly resolving, reproducible technique that achieves the desired goal of improving the patient's quality of life and reducing major complications associated with open surgical interventions.

Funding

The authors declare that they have not received funding.

Conflicts of interest

The authors declare no conflicts of interest.

Ethical disclosures

Protection of human and animal subjects. The authors declare that no experiments were performed on humans or animals for this study.

Confidentiality of data. The authors declare that they have followed the protocols of their work center on the publication of patient data.

Right to privacy and informed consent. The authors have obtained the written informed consent of the patients or subjects mentioned in the article. The corresponding author is in possession of this document.

Use of artificial intelligence for generating text. The authors declare that they have not used any type of generative artificial intelligence for the writing of this manuscript nor for the creation of images, graphics, tables, or their corresponding captions.

References

1. Oderich GS, Kärkkäinen JM, Reed NR, Tenorio ER, Sandri GA. Penetrating aortic ulcer and intramural hematoma. Cardiovasc Intervent Radiol. 2019;42:321-34.
2. Kratimenos T, Baikoussis NG, Tomais D, Argiriou M. Ascending aorta endovascular repair of a symptomatic penetrating atherosclerotic ulcer with a custom-made endograft. Ann Vasc Surg. 2018;47:280.e1-4.
3. D'Annoville T, Ozdemir BA, Alric P, Marty-Ané CH, Canaud L. Thoracic endovascular aortic repair for penetrating aortic ulcer: literature review. Ann Thorac Surg. 2016;101:2272-8.
4. Eggebrecht H, Plicht B, Kahlert P, Erbel R. Intramural hematoma and penetrating ulcers: indications to endovascular treatment. Eur J Vasc Endovasc Surg. 2009;38:659-65.
5. Jánosi RA, Gorla R, Tsagakis K, Kahlert P, Horacek M, Bruckschen F, et al. Thoracic endovascular repair of complicated penetrating aortic ulcer: an 11-Year single-center experience. J Endovasc Ther. 2016;23:150-9.