

# Bronchial lavage role in human immunodeficiency virus-positive acid-fast negative patients in pulmonary tuberculosis diagnosis

Raúl Cicero-Sabido<sup>1</sup>, Carlos Núñez-Pérez-Redondo<sup>2</sup>, Claudia A. Bäcker<sup>3</sup>, Elizabeth Luis-Martínez<sup>2</sup>, Heleodora Gonzalez-Gonzalez<sup>2</sup>, Pablo Álvarez-Maldonado<sup>2</sup>, and Alejandro Hernández-Solís<sup>2</sup>

<sup>1</sup>Faculty of Medicine, Universidad Autónoma de México; <sup>2</sup>Division of Pulmonology and Thoracic Surgery, Hospital General de Mexico "Dr. Eduardo Liceaga"; Secretary of Health; <sup>3</sup>Institute of Epidemiological Diagnosis and Reference, Secretary of Health. Mexico City, Mexico

## Abstract

**Background:** Pulmonary tuberculosis (PTB) is a world public health problem. Its association with human immunodeficiency virus (HIV) occurs as a consequence of immunosuppression that facilitates coinfection. **Materials and methods:** A descriptive observational study of consecutive cases from January 6 to September 30, 2016, was made in a tertiary care reference center in Mexico, where HIV-positive patients suspicious of having PTB were negative for bacilli in the acid-fast stain of sputum. Bronchial lavage (BL) was performed and cultures for *Mycobacterium tuberculosis* (Mtb) were made to confirm PTB. Some cases were tested with Xpert<sup>®</sup> MTB/RIF<sup>®</sup> methodology with a polymerase chain reaction to detect Mtb and its sensitivity to rifampicin. **Results:** BL was performed on 82 HIV-positive acid-fast negative patients from whom samples were obtained to search for Mtb through culture. Expectoration smear samples of 26 patients resulted in 21 negatives for Mtb. The remaining five patients turned Ziehl-Neelsen positive as well as positive for Mtb through culture. In the 56 cases of non-expectoration and dry cough, 37 patients were negative for Mtb, seven were positive by culture, and 12 were positive by Xpert. A total of 24 (29.2%) cases were positive for Mtb. **Conclusions:** BL facilitates the early diagnosis of PTB in smear-negative HIV-positive patients. Xpert MTB/RIF positive results allowed treatment initiation within 2 h.

**Key words:** Tuberculosis. Human immunodeficiency virus. Bronchial lavage. Culture. Xpert MTB/RIF.

## Introduction

It is estimated that a quarter of the world population is infected with latent tuberculosis and 38 million with the human immunodeficiency virus (HIV)<sup>1</sup>. Pulmonary tuberculosis (PTB) coinfection in HIV patients obeys to the fact that their immunosuppression makes them highly susceptible. In 2017 in Mexico, there were more than 14,000 new cases of HIV-infected patients<sup>2</sup>. Timely tuberculosis diagnosis is of great epidemiologic relevance<sup>3</sup>

and must be carried out as soon as possible in all new suspected cases, particularly those HIV-positive having clinical respiratory symptoms or abnormal signs suggestive of pulmonary disease as well as altered thoracic x-ray images. Discarding PTB for these subjects is mandatory even in the absence of a positive Ziehl-Neelsen stain (ZN) or lack of expectoration due to dry cough. In these cases, bronchial lavage (BL) is indicated<sup>4,5</sup>. Biopsy of evident lesions could also be obtained to uncover both tuberculous and non-tuberculous lesions when fiberoptic

## Correspondence:

\*Alejandro Hernández-Solís

E-mail: drhernandezsolis@yahoo.com.mx

Date of reception: 20-06-2019

Date of acceptance: 13-11-2019

DOI: 10.24875/HGMX.19000044

Available online: 21-07-2020

Rev Med Hosp Gen Mex. 2020;83(3):100-103

www.hospitalgeneral.mx

0185-1063/© 2019 Sociedad Médica del Hospital General de Mexico. Published by Permanyer. This is an open access article under the CC BY-NC-ND license (<http://creativecommons.org/licenses/by-nc-nd/4.0/>).

bronchoscopy (FOB) is performed. Nowadays, the use of molecular technologies such as Xpert enables an almost immediate diagnosis of *Mycobacterium tuberculosis* (*Mtb*)<sup>3,6</sup>.

We made an exploratory descriptive observational study of 82 consecutive cases to assess the diagnostic usefulness of FOB with BL in HIV-positive smear-negative patients suspected of having PTB. In addition, Xpert® MTB/RIF® for fast diagnosis of *Mtb* was assayed in 13 cases.

## Materials and methods

Only outpatients with a confirmed diagnosis of HIV infection and suspected PTB in a tertiary-care level hospital were included in the study. All patients were undergoing highly active antiretroviral therapy, had a CD4 mean of 160 in a range between 28 and 644, and had a low socioeconomic status.

BL was performed by an experienced bronchoscopist under strict sterile conditions using an Olympus IT30 flexible fiberscope, undertopic anesthesia with a 10% xylocaine spray solution, and conscious sedation with midazolam. Twenty to fifty milliliters of 0.9% saline were instilled to recover aliquots of a mean of 10 ml as a sample for the bacteriological study. In all cases, cultures for *Mtb* were made to confirm the diagnosis and determine the susceptibility to first-line antituberculous drugs (isoniazid, rifampicin, pyrazinamide, and ethambutol). The flexible fiberscope was placed in the main, lobar, or segmental bronchus of the affected lung corresponding to the lesion or lesions observed on the radiographic image.

All patients gave their consent for the bronchoscopy to be performed.

ZN stain was repeated in all samples of BL for bacteriological study. Samples were decontaminated, homogenized, and concentrated according to the Petroff method, with 4% sodium hydroxide in equal amount to the sample, incubated at 37°C for 15 min, and centrifuged at 3800-3900 rpm for 5 min. The supernatant was decanted into 1% sodium hypochlorite, neutralized with 1N hydrochloric acid until the obtained sediment turned pale yellow when it was inoculated in two Löwenstein-Jensen tubes, one Stonebrink, and one MGIT960 medium. They were weekly monitored for 8 weeks until a definite positive or negative result was obtained. MGIT960 tubes were placed in a Bactec™ MGIT960 device that performed daily analyses for 42 days. In 13 cases, samples obtained by BL were studied by Xpert® MTB/RIF® to identify *Mtb* and its resistance to rifampicin in cartridges of Cepheid GENEXPERT (Cepheid®, Sunnyvale, the United States).

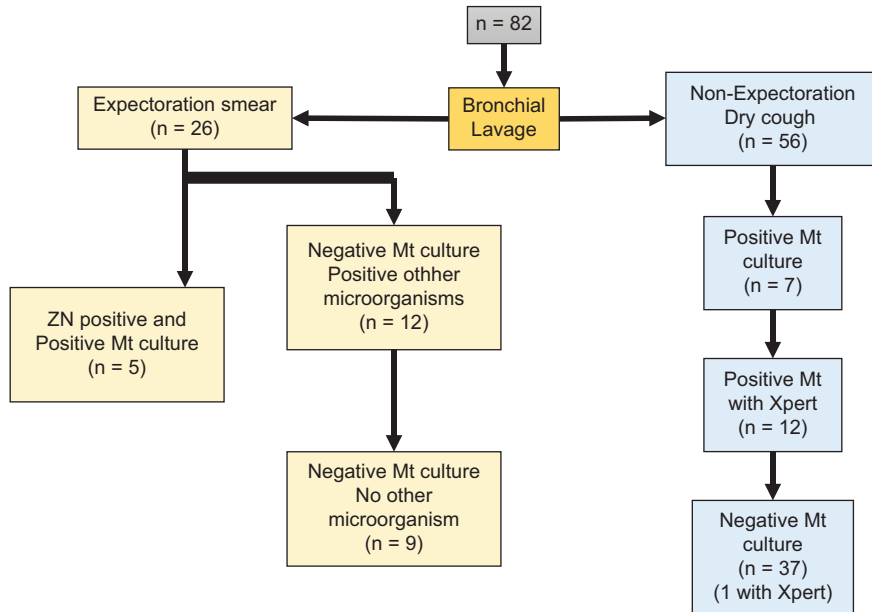
## Results

From January 6, 2016, to September 30, 2016, out of 342 suspected PTB cases, 82 were HIV-positive with acid-fast stain negative (ZN). Seventy were male and 12 were female, with age mean of 36 years (range 18-64). After 82 BL, five (6.1%) resulted in acid-fast stain positive (ZN) with positive *Mtb* culture. Out of 45 non-expectoration cases, 13 were randomly tested with Xpert MTB/RIF assay for *Mtb* (Fig. 1). Results were obtained within 2 h, having only one negative. Neither Xpert test nor cultures that resulted positive for *Mtb* showed resistance to rifampicin.

## Discussion

Tuberculosis is highly mortal in HIV-positive patients<sup>1</sup>. Therefore, asserting the definitive diagnosis to initiate treatment as soon as possible is a matter of utter relevance. All HIV-positive patients having respiratory complaints or signs of disease with abnormal x-ray chest images must be studied to either confirm or discard PT. However, the microscopic examination of expectoration by ZN has an average sensitivity of 50% and is not always feasible when dry cough limits sampling. Although induction of sputum with nebulized hypertonic saline is useful in the microscopic study of new cases, BL by means of FOB allows the obtaining of biological samples directly from the lungs in immunosuppressed patients strongly suspected of PTB<sup>7</sup>. BL is a more sensitive resource that could turn positive results for *Mtb* in initially negative cases<sup>4</sup>, allowing setting up a specific and immediate treatment and thus enabling control of disease dissemination. In this series, 5 (6.1%) patients having an initial acid-fast stain negative for bacilli, turned out positive on BL samples. Another 19 patients (23.1%) benefited from BL cultures for diagnosis and treatment initiation. In a recent cross-sectional study by Santoso et al.<sup>8</sup>, BL sampling increased the positivity level of the ZN acid-fast stain examination by 32.5%.

Initial microscopic study of expectoration is essential in all suspected cases of PTB<sup>7</sup> and must be confirmed by a positive culture of *Mtb*, considered the gold standard, which also determines the susceptibility to antituberculous drugs and mycobacterial species. However, time is required for a definitive diagnosis. Delays in PTB diagnosis bring about treatment initiation after 30 days, which currently could be avoided with the use of molecular technologies such as Xpert. Although this



**Figure 1.** Bronchial lavage results in human immunodeficiency virus positive patients with initial negative *Mycobacterium tuberculosis* (*Mt*). \*Positive *Mt* may be considered a true positive. Negative *Mt* may be considered a true negative.

study is limited by the small number of samples tested by Xpert, expedite information is provided as to the diagnostic approach of PTB in an endemic region. Xpert provides a diagnosis of *Mtb* within 2 h along with susceptibility or resistance to rifampicin, an important aspect in endemic regions with prevalent multidrug resistance<sup>3,7,9,10</sup> and a matter of paramount epidemiologic relevance in all 1<sup>st</sup> time cases that can be treated immediately, particularly if they resulted negative for acid-fast stain. Nevertheless, the use of Xpert is still not indicated to follow-up on antituberculous treatment due to its high cost.

## Conclusions

BL is of great usefulness for diagnosing PTB in HIV-positive patients with a negative acid-fast stain in sputum or absence of expectoration, allowing the identification of acid-fast (ZN) bacilli in non-diagnosed or misdiagnosed cases. With the use of Xpert MTB/RIF, in addition to obtaining results from BL samples within 2 h, susceptibility to rifampicin is also provided, an advantage that allows an immediate initiation of specific antituberculous treatment, which represents an important epidemiologic advance in controlling tuberculosis.

## Acknowledgment

To Marco Gudiño Zayas - Academic Technician for revising the manuscript.

## Conflict of interest statement

The authors deny any conflict of interest related to the preparation of this manuscript.

## Ethical disclosure

**Protection of human and animal subjects.** The authors declare that no experiments were performed on humans or animals for this study.

**Confidentiality of data.** The authors declare that they have followed the protocols of their work center on the publication of patient data.

**Right to privacy and informed consent.** The authors declare that no patient data appear in this article.

## References

1. World Health Organization. Available from: <http://www.who.int/es/news-room/fact-sheets/detail/tuberculosis>. [Last accessed on 2018 Sep 26].
2. National Center for the Prevention and Control of HIV and AIDS. Available from: [https://www.gob.mx/cms/uploads/attachment/file/391168/RN\\_2do\\_trim\\_2018.pdf](https://www.gob.mx/cms/uploads/attachment/file/391168/RN_2do_trim_2018.pdf). [Last accessed on 2018 Sep 26].

3. Gilpin C, Korobitsyn A, Migliori GB, Raviglione MC, Weyer K. The World Health Organization standards for tuberculosis care and management. *Eur Respir J*. 2018;22:51.
4. Choudhary S, Tayade BO, Kharbade S, Sontakke A, Khan S, Abraham R. Outcome of fiberoptic bronchoscopy in sputum smear negative pulmonary tuberculosis. *Panacea J Med Sci*. 2015;5:33-9.
5. Rao GN, Venu M, Rani NU, Sravani M. Induced sputum versus bronchial washings in diagnosis of sputum negative pulmonary tuberculosis. *J Fam Med Prim Care*. 2016;5:435-9.
6. Floridia M, Cicaci F, Andreotti M, Hassane A, Sidumo Z, Magid NA, et al. Tuberculosis case finding with combined rapid point-of-care assays (Xpert MTB/RIF and determine TB LAM) in HIV-positive individuals starting antiretroviral therapy in Mozambique. *Clin Infect Dis*. 2017;65:1878-83.
7. Singhal R, Myneedu VP. Microscopy as a diagnostic tool in pulmonary tuberculosis. *Int J Mycobacteriol*. 2015;4:1-6.
8. Santoso P, Soeroto AY, Juniati R, Hartantri Y, Wisaksana R, Alisjabana B, et al. Improving diagnostic of pulmonary tuberculosis in HIV patients by bronchoscopy: a cross sectional study. *Acta Med Indones*. 2017;49:330-5.
9. Sreeramareddy CT, Quin ZZ, Satyanarayana S, Subbaraman R, Pai M. Delays in diagnosis and treatment of pulmonary tuberculosis in India: a systematic review. *Int J Tuberc Lung Dis*. 2014;18:255-66.
10. Sotgiu G, Nahid P, Loddenkemper R, Abubakar I, Miravittles M, Migliori GB. The ERS-endorsed official ATS/CDC/IDSA clinical practice guidelines on treatment of drug-susceptible tuberculosis. *Eur Respir J*. 2016;48:963-71.