

Silicone oil filler induced granuloma (siliconoma), presenting as acute dacryocystitis

Carlos Fleitman-Broder^{1,2*} and Jacobo Fleitman-Chazan²

¹Ophthalmology Service, Centro Médico ABC; ²Ophthalmology Service, VistaCare. Mexico City, Mexico

Abstract

Even though silicon oil is not approved to be used as a cosmetic facial filler and despite its use has been linked to a big number of acute and late complications, many physicians still use it for this purpose. We report on a 63-year-old female who presented with a clinical picture similar to an acute dacryocystitis without any prior history of tearing, she was found to have a medial canthal tumoration that was found to be caused by a granuloma secondary to silicone oil injection (siliconoma) that the patient received in the glabellar area 3 years before her current complains started.

Key words: Facial fillers. Silicon oil. Complications. Granuloma. Side effects. Esthetic fillers.

Introduction

Liquid injectable silicone has been in use as a facial cosmetic filler for more than five decades, even though the Food and Drug Administration (FDA) has only approved its use for intraocular injection in cases of retinal detachment and several warnings about this of label use have been published¹.

The main complications arising from the use of these materials as facial fillers are granuloma formation and migration of silicone oil.

A siliconoma is a foreign body granulomatous reaction that presents a few days or even years after silicon oil fillers are injected. It usually behaves as recurrent inflammatory attacks with periods of remission between them^{2,3}.

In this paper, we report about a patient with a history of glabellar silicone oil injection that presented with a siliconoma mimicking an acute dacryocystitis.

Case report

A 63-year-old female patient presented with an acute case of pain, swelling, and erythema in her right eye medial canthal area, she had no previous ocular or systemic medical history besides the fact that she has a facial filler injection in the glabella 3 years before her symptoms started, she was diagnosed as an acute dacryocystitis and treated with systemic and topical antibiotics with resolution of her symptoms. Two weeks later, she presented with a recurrence, with fistulation and secretion of white pus-like material, she was treated again with systemic and topical antibiotics and referred for an oculoplastic consultation.

On clinical examination a 5 mm rubbery, non-mobile tumoration was found superior to the right medial canthal angle. No reflux through the lacrimal puncta was found on lacrimal sac massage, a negative fluorescein disappearance test, a positive Jones I test, and no nasolacrimal duct (NLD) obstruction on irrigation was found.

Correspondence:

*Carlos Fleitman-Broder

E-mail: cfleitman@gmail.com

Date of reception: 17-01-2019

Date of acceptance: 05-11-2019

DOI: 10.24875/HGMX.19000020

Available online: 17-01-2020

Rev Med Hosp Gen Mex. 2020;83(1):42-44

www.hospitalgeneral.mx

0185-1063/© 2019 Sociedad Médica del Hospital General de México. Published by Permanyer. This is an open access article under the CC BY-NC-ND license (<http://creativecommons.org/licenses/by-nc-nd/4.0/>).

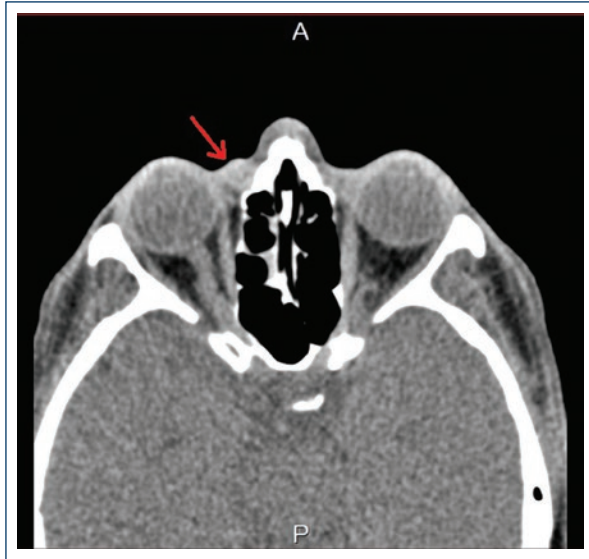


Figure 1. Orbital computed tomography showing a 6 mm diameter cystic lesion in the medial supracanthal area with a 114 Hounsfield unit density (arrow).

An orbit computed tomography (CT) scan was performed, where a supracanthal 6 mm well-defined radio-opaque mass with a 114 Hounsfield unit (HU) density was found (Fig. 1).

An excisional biopsy was done under local anesthesia, and the histopathology results demonstrated a chronic foreign body granulomatous reaction with numerous optically empty vacuoles that resulted in negative to all the special staining techniques (Figs. 2-3).

Discussion

Liquid silicon was first used as a cosmetic filler in the 1940s decade, with the off label injection of medical-grade silicone oil that was intended for use as a lab material lubricant. Thousands of patients were injected in the US and Europe. Some physicians even mixed the silicone oil with olive oil to induce an even greater fibroblast reaction. In many cases, this injection has disastrous and disfiguring results for the patients⁴.

In the 1980s decade, Webster et al. described the microdroplet injection technique, which consists of the injection of multiple 0.005-0.01 cc with a 30 g needle for a total of 0.02-0.1 cc of silicone oil injected. The volume augmentation achieved by this technique is based on the fibrosis and encapsulation of these microdroplets. Advocates of silicone oil used as a filler claim that with a proper injection technique and using medical grade purity silicon oil, the procedure is safe and

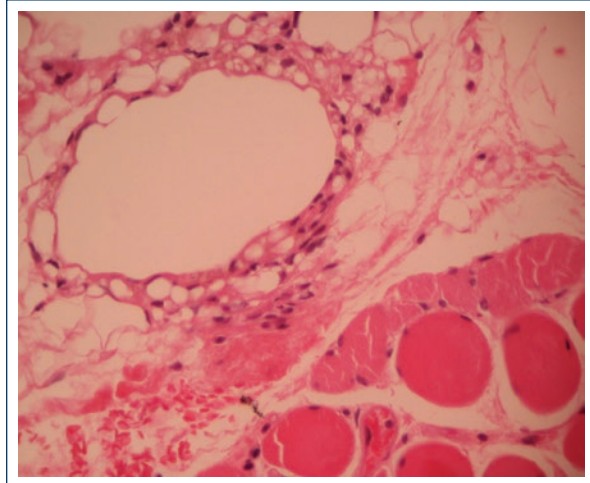


Figure 2. Microphotography showing alternation between big optically empty spaces and small vacuole like spaces (silicon) without any epithelial lining in between skeletal muscle fibers (Hematoxylin and eosin, x40).

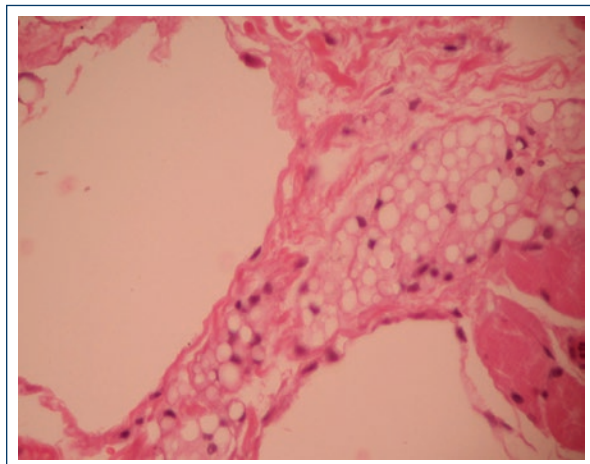


Figure 3. Microphotography showing alternation between big optically empty spaces and small vacuoles in-between soft tissue (Hematoxylin and eosin, x40).

predictable⁵. Despite this claim, up to date, there are no FDA approved silicone oil-based cosmetic fillers.

The complications have been reported from the use of silicone oil as a filler range from ecchymosis, edema, and erythema, which can happen with any cosmetic filler, up to serious complications such as granuloma^{6,7}, migration of the filler⁷, cellulitis, ulceration, disfiguring scarring⁸, pneumonitis, emboli, and death^{9,10}.

In the present clinical case, we found migration and granuloma formation in the medial canthal area 3 years after the filler was injected. The case was misdiagnosed as an acute dacryocystitis but after acute inflammation

subsided no NLD obstruction was found, and a tumefaction superior to the lacrimal sac was palpated. In the CT, the tumoration had a density of 114 HU, which is compatible with silicon oil density¹¹; histopathology confirmed that it was certainly a siliconoma and confirmed the migration of the silicon oil filler previously injected.

Conclusions

Undesirable effects from non-approved cosmetic fillers like silicon oil can have serious deleterious consequences for patients.

In cases of a suspected dacryocystitis without any previous history of tearing and a patent lacrimal system after inflammation remission, a detailed medical history and exploration should be done. Imaging techniques are of great value for diagnosis and surgical planning in case a space-occupying lesion is found since almost 55% of lacrimal sac tumors are known to be malignant¹².

Conflicts of interest

The authors declare that they have no conflicts of interest.

Ethical disclosures

Protection of human and animal subjects. The authors declare that no experiments were performed on humans or animals for this study.

Confidentiality of data. The authors declare that they have followed the protocols of their work center on the publication of patient data.

Right to privacy and informed consent. The authors have obtained the written informed consent of the patients or subjects mentioned in the article. The corresponding author is in possession of this document.

References

1. Available from: <https://www.fda.gov/medicaldevices/safety/alertsandnotices/ucm584824.htm>. [Last accessed on 2018 Dec 27].
2. Kluger N, Plantier F, Carlotti A, Guillemin L. Facial granuloma after occult silicone injection (siliconoma): a diagnosis not to be missed. *Eur J Intern Med*. 2009;20:e120-1.
3. Park ME, Curreri AT, Taylor GA, Burris K. Silicone granulomas, a growing problem? *J Clin Aesthet Dermatol*. 2016;9:48-51.
4. Bentkover SH. The biology of facial fillers. *Facial Plast Surg*. 2009;25:73-85.
5. Webster RC, Fuleihan NS, Gaunt J, Hamdan US, Smith RC. Injectable silicone for small augmentations: twenty year experience in humans. *Am J Cosmet Surg*. 1984;1:1-10.
6. Altmeyer MD, Anderson LL, Wang AR. Silicone migration and granuloma formation. *J Cosmet Dermatol*. 2009;8:92-7.
7. Ellenbogen R, Rubin L. Injectable fluid silicone therapy. Human morbidity and mortality. *JAMA*. 1975;234:308-9.
8. Rapaport MJ, Vinnik C, Zarem H. Injectable silicone: cause of facial nodules, cellulitis, ulceration, and migration. *Aesthetic Plast Surg*. 1996;20:267-76.
9. Schmid A, Tzur A, Leshko L, Krieger BP. Silicone embolism syndrome: a case report, review of the literature, and comparison with fat embolism syndrome. *Chest*. 2005;127:2276-81.
10. Gurvits GE. Silicone pneumonitis after a cosmetic augmentation procedure. *N Engl J Med*. 2006;354:211-2.
11. Mathews VP, Elster AD, Barker PB, Buff BL, Haller JA, Greven CM. Intraocular silicone oil: *in vitro* and *in vivo* MR and CT characteristics. *AJNR Am J Neuroradiol*. 1994;15:343-7.
12. Montalban A, Liétin B, Louvrier C, Russier M, Kemeny JL, Mom T, et al. Malignant lacrimal sac tumors. *Eur Ann Otorhinolaryngol Head Neck Dis*. 2010;127:165-72.