



Effects of ultraviolet radiation (UV) in domestic animals. Review



Maricela Olarte Saucedo ^{a*}

Sergio Hugo Sánchez Rodríguez ^b

Carlos Fernando Aréchiga Flores ^a

Rómulo Bañuelos Valenzuela ^a

María Argelia López Luna ^c

^a Universidad Autónoma de Zacatecas. Unidad Académica de Medicina Veterinaria y Zootecnia. Zacatecas, México.

^b Universidad Autónoma de Zacatecas. Unidad Académica de Ciencias Biológicas, Zacatecas, México.

^c Universidad Autónoma de Zacatecas. Unidad Académica de Ciencias Químicas. Zacatecas, México.

* Corresponding author: olarte61@hotmail.com

Abstract:

Solar radiation is necessary for life on Earth. Environmental pollution is contributing to global climate change, in ways such as degrading the atmospheric ozone layer, vital to controlling the type and amount of ultraviolet (UV) radiation reaching the surface. Domestic animals are constantly directly exposed to solar radiation and can consequently develop skin lesions, optical tumors and thermal stress, or even die. UV light produces oxidative stress of the skin due to excessive production of reactive oxygen species (ROS), which can damage cells, causing cell aging or cancer. Antioxidants neutralize these harmful agents, but their activity decreases with organism age and metabolic state. A review was done of the histology and physiology of the skin, and the effects of UV radiation on domestic animals using bibliographic databases (PubMed/MEDLINE, Science) as well as journals available on the Internet. Understanding the effects of UV

radiation on the health of domestic animals is vital since it can have substantial financial impacts on producers, compromise animal welfare and the quality and safety of animal-origin products.

Key words: Ultraviolet radiation, Domestic animals, Skin, Cancer.

Received: 30/09/2017

Accepted: 16/04/2018

Introduction

Solar energy is necessary for all living beings on the planet. Climate change, global warming, gas emissions and the greenhouse effect have modified the atmosphere, which mediates the sun's rays. These modifications have altered the ozone layer^(1, 2), leading to more direct entry of ultraviolet (UV) radiation to the Earth's surface. Those environments and animal species which receive direct solar radiation have been changed as a result. Livestock species are particularly vulnerable since excess exposure to solar radiation can cause skin lesions, optic tumors, caloric stress or even death, with substantial consequent financial losses in the industry⁽³⁾.

Types of radiation

Radiation can be defined as energy that travels from one point to another, as well as any energy that propagates in wave or particle form through space⁽⁴⁾. The electromagnetic radiation emitted by the Sun is generally characterized by frequency and wavelength (Figure 1), and can be classified based on two criteria:

1) By its nature:

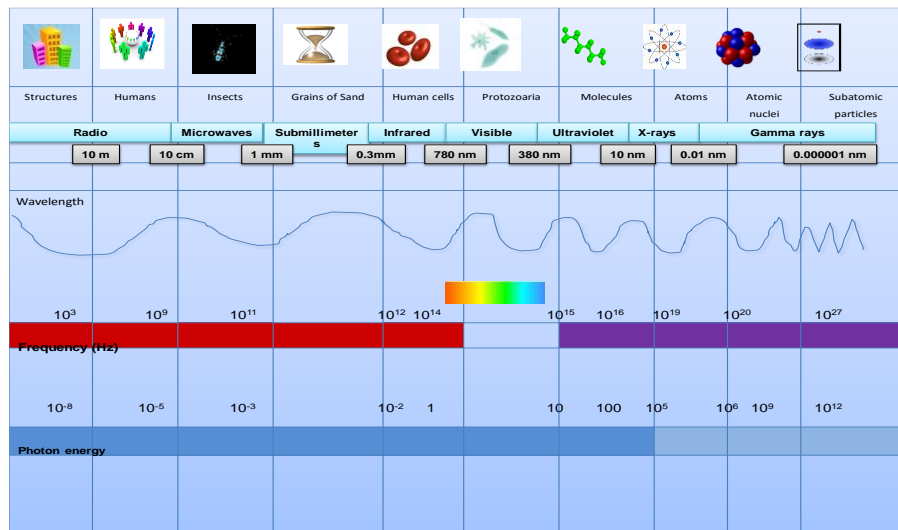
There are electromagnetic radiations^(5,6), such as wave-propagated radiations (gamma rays, X-rays); ultraviolet radiations (UVA, UVB, UVC); visible radiation (violet, blue,

green, yellow, orange, red); infrared radiation; and radio frequencies (radar, microwave). And there are corpuscular radiations such as subatomic particles (α particles, β particles, neutrons, cosmic radiations); these move at high speeds and transport large amounts of energy^(4,5,6).

2) By its biological effect:

Radiation that carries enough energy to cause ionization in the mediums it crosses is known as ionizing radiation, while radiation that cannot separate electrons from atoms or alter molecular structures is called non-ionizing radiation⁽⁷⁾. Photon energy is too weak to break chemical bonds but it has biological effects such as heating and induction of electrical currents in tissues and cells⁽⁸⁾. The ionizing or non-ionizing character of a radiation is independent of its corpuscular or electromagnetic nature⁽⁹⁾. Ionizing radiations include alpha and beta radiation, cosmic rays, gamma rays, X rays, and a portion of the UV spectrum, among others. Examples of non-ionizing radiations are UV, visible and infrared rays and radio, TV or mobile telephony waves^(7,8,9).

Figure 1: Electromagnetic radiation spectrum showing the different wavelengths emitted by the Sun⁽¹⁰⁾



Ultraviolet (UV) light

Of the entire spectrum of solar radiation only visible light (50 %), infrared (40 %) and part of the ultraviolet spectrum (10 %) reach the planet's surface, with the remaining wavelengths stopped by stratospheric ozone. Ultraviolet solar radiation is defined as the power of UV solar energy per surface unit (UV) and is measured in (w/m^2)⁽¹¹⁾. It has three wavelength spectra: UVA (315-400 nm), UVB (280-315 nm) and UVC (100-280 nm)^(4,12,13,14). The latter possesses the highest energy but is absorbed by the atmospheric ozone layer, as long as it remains intact, and thus has no adverse effects on life forms. If the ozone layer were to degenerate even slightly UVC could begin to cause harmful effects.

Both the UVA (95 %) and UVB (5 %) spectra do reach the Earth's surface and exposure to them is a known risk factor for development of skin cancer. The UVB is involved in formation of photoproducts and other complexes which impair nucleic acids, with long-term consequences, and are directly related to various skin neoplasms caused by repeated or frequent burns on the epidermis⁽¹⁵⁾. Any cytotoxicity caused by the UVA is mainly mediated by photosensitizing endogenous molecules, which absorb photons and generate reactive oxygen species, generating direct damage to the dermis and premature aging^(13,15).

The atmosphere

The atmosphere is composed mostly of nitrogen (78 %) followed by oxygen (21 %)^(16,17). The remaining percentage corresponds to myriad trace gases, including miniscule amounts of ozone at a concentration of no more than a few molecules per million air particles (0.01 %). However, ozone is essential to preserving life as we know it on the planet because it protects life forms from UV radiation, an important physical carcinogen in both terrestrial and marine animals^(16,17).

The ozone molecule consists of three oxygen atoms (O_3) and is created mainly in two places within the atmosphere. Most (90+%) occurs in the upper stratosphere, about 50 km above the Earth's surface, and is vital to reflecting damaging radiation back into space⁽¹⁶⁾. The remaining 10 % is generated at surface level (i.e. the troposphere) in large urban areas as a component of smog^(16,18).

Since at least the mid-20th Century human activity has altered the ozone layer's ecological equilibrium by production and emission of what are known as "ozone depleting substances" (ODS) into the atmosphere^(1,19). The best known ODS are chlorofluorocarbons (CFC), which were used in the manufacture of aerosols, refrigerators and air conditioning equipment until banned in 1989. The CFC are extremely reactive; for example, a single chlorine molecule can destroy a thousand ozone molecules^(1,19). Formation of ozone molecules is a slow process and as ODS concentrations have increased in the atmosphere overall ozone concentration decreases until a new equilibrium is reached between formation speed and degradation^(16,17,19).

Solar radiation is one of the main environmental factors affecting life on the planet. It governs the functioning of terrestrial and aquatic ecosystems through control of photobiological processes (e.g. photosynthesis, photoperiod, phototropisms). These in turn influence other environmental factors such as temperature, humidity and natural cycles (daily, annual and hydric cycles) which finally affect organism distribution^(19,20). This makes life possible on Earth but can be detrimental to it at high intensities or when the proportion of shortwave radiation surpasses certain limits. High intensity radiation and changes in the spectral composition can affect significant processes in organisms^(19,21).

The quantity and quality of the radiation that reaches the Earth's surface depends both on the solar energy emitted and atmospheric characteristics at a given site. A wide range of the electromagnetic spectrum reaches the surface with approximately 40 % being visible light or radiation. These wavelengths range from 400 to 700 nm and are used by plants in photosynthesis. Another range is the photobiological range, from 280 to 1,000 nm⁽²¹⁾.

Both UVA and UVB penetrate the biosphere but only UVB is absorbed by atmospheric ozone, meaning a decrease in ozone concentrations will allow a greater amount of UVB to reach the surface. Only 1.3 % of the UV radiation emitted by the sun which reaches the earth passes through the atmosphere, of which 98 % is UVA and 2 % is UVB.

Animal skin physiology

In animals the skin covers the organism surface and is in direct contact with the external environment. It consists of three strata that harbor additional structures such as sweat and sebaceous glands⁽²²⁾. Different species have developed supplementary forms of protection (hair, wool, feathers) and/or keratinized tissues (nails, hooves). The skin protects against mechanical, physical and chemical threats from the environment^(22,23); for example, skin thickness often increases at points regularly subjected to mechanical compression (e.g.

hooves, paws, hands and feet)⁽²²⁾. It is also relatively impervious to microorganisms and many poisonous and noxious substances.

The skin protects against radiation⁽²³⁾, mainly solar radiation of different wavelengths. For this reason in many animal species its superficial stratum, the epidermis, produces pigments (melanin granules) that impede the penetration of radiations to deeper tissues. An example is the skin of the polar bear which has white (refractory) fur and black (protective) skin as an adaptation to an intense luminous environment subject to direct solar radiation and indirect radiation reflected from ice and snow⁽²⁴⁾.

Sweat and sebaceous glands in the skin reach the surface through glandular ducts, making this an excretory tissue⁽²⁴⁾. Water excretion (sweat) is a means of thermoregulation unrelated to maintenance of organism hydric equilibrium, but rather controls animal thermal conditions vis-à-vis the environment. Cutaneous sebum is a mixture of lipids secreted by the sebaceous glands aimed at protecting the skin from moisture and conferring it pliability and resistance⁽²⁴⁾.

The skin plays an important role in animal growth or somatic body development because it is the primary storage area and activation site of vitamin D⁽²³⁾. Entering the organism as D2 (ergocalciferol) or D3 (cholecalciferol), depending on its source, Vitamin D reaches skin tissues via the blood. Here it is stored as calciferol or a precursor, and is transformed into cholecalciferol by UV rays from the Sun. The cholecalciferol returns to the circulatory system, passes through the liver and finally arrives in the kidneys where the parathormone (PTH) effect transmutes it into the vitamin D hormone (1, 25-dihydroxycholecalciferol). This hormone acts in the intestinal mucosa by stimulating facultative absorption of calcium, thus preventing rickets⁽²²⁾.

Skin histology

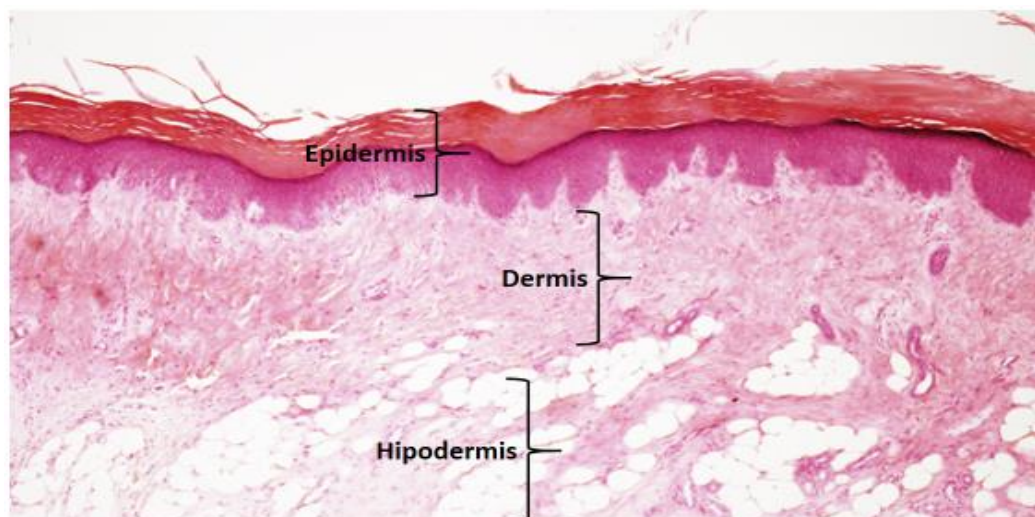
Total cutaneous area varies by animal species; for example, in adult humans it is estimated to be up to 2 m². Certain portions of the skin of different animals generate specialized formations such as hair, feathers, nails, horns, or hooves, and the presence of sweat and sebaceous glands can range from numerous, to scarce or absent⁽²⁵⁾.

Skin thickness in a given organism can vary but is generally thicker on body dorsal surfaces and limb lateral surfaces, and thinner on body ventral surfaces and limb medial surfaces. These general trends can differ by species, breed and sex⁽²²⁾. In mammals, the thinnest skin areas average from 0.4 mm in mice to 2.4 mm in Holstein dairy cows (*Bos*

taurus), while the thickest areas average from 1.9 mm in the domestic cat to 10.7 mm in male horses⁽²⁴⁾.

The skin is divided into three strata: epidermis, the epithelial or surface stratum; dermis, the connective or deep intermediate stratum; and hypodermis, the subcutaneous cellular tissue (Figure 2)^(25,26).

Figure 2: Layers of thick rat skin



Epidermis: consists of keratinized stratified layered epithelium; Dermis: connective tissue; Hypodermis: fatty tissue. Technique: paraffin, hematoxilín-eosine⁽²⁴⁾.

Epidermis. This consists of keratinized stratified layered epithelium, and is generally divided into five strata: stratum germinativum, stratum spinosum, stratum granulosum, stratum lucidum and stratum corneum^(25,26,27).

Dermis. This connective layer is divided into two regions, the papillary immediately below the epidermis, and the deeper reticular. Named for the numerous papillae projecting from it into the epidermis, the papillary region consists of a dense weave of irregular lax fibrous connective tissue with trophic functions. Its thickness varies widely between species, being thicker in ungulates than in carnivores⁽²⁵⁻²⁸⁾.

Hypodermis. This layer is mostly connective tissue that adheres the skin to the bones and muscles. Its primary function is to dampen external pressures and allow free movement of the skin over underlying structures. Adipose tissue is present in this layer, from small groups of cells to large masses in the form of pillows or fat pads. In temperate climates, the hypodermis carries out a thermoregulatory function by increasing in thickness in the winter to retain heat^(24,25). Ancillary structures such as hooves, nails, horns and spurs

originate in keratinization processes in the stratum corneum and have different thicknesses and consistencies^(24,25).

Hair. Hairs are epidermal formations that, in most mammals, are present over the entire skin surface save on specialized skin tissues such as the pads of paws, palms of hands, hooves, fingernails, part of the lips of the mouth, the glans, the inner surface of the foreskin, the vulvar labia, the nipples and the contact surface of the limbs. A hair has a root, a stem and a tip, which protrudes from the skin. Hair roots are surrounded by an invagination of epidermal strata spinosum and germinativum into the dermis that reaches the papillary region and thus accesses the blood vessels therein⁽²⁵⁾.

The cortical and medullary layers of hair occur in different proportions in different species. For instance, the hair lining the skin of horses, bovines, dogs and pigs has a thicker cortical layer than the hair of goats and cats. Also, the fine curly hairs of sheep and pigs, manifest in hedgehogs or porcupines as sharp hairs known as thorns or barbs. Hair is generally very fine in young animals and practically lacks marrow^(24,25,28,29,30).

Adaptations of the skin in response to environmental conditions

Evolutionary, morphophysiological adaptation of skin to environmental conditions involves the morphological peculiarities of the skin and its ability to allow thermal adjustments to environmental variables and thus regulate organism temperature⁽²⁸⁾. An excellent example is variation in skin thickness among and between bovine breeds. Histological studies comparing Zebu cattle (*Bos indicus*), and Holstein breeds (*Bos Taurus*) have found that skin thickness is not homogeneous across the body surface in the same areas among animals of the same species but different breeds, and can even vary with age. One study of 21 regions on the skin of Holstein-Friesian cattle (*Bos taurus*) found that skin thickness as measured by skin fold changed within the same area and that overall thickness increased with age. An analysis of different macro- and microscopic skin structures in Holstein and Zebu cows found the Zebu to be better adapted to high temperatures^(28,31). This breed has shorter, thicker hair, greater overall skin thickness with a thinner epidermis and a deeper reticulate dermis, a larger number of sweat glands exhibiting dermal implantation, and consequently a greater excretory surface and glandular density per area⁽²⁸⁾. In contrast Holstein-Friesian is a dairy breed characterized by thinner skin with a thicker epidermis and finer reticulate dermis. Even the shape of sweat glands differs between the breeds with sweat glands in the Holstein having a tubular shape with varying degrees of torsion and those in the Zebu a more sack-like shape. In the latter breed they are also more concentrated, ensuring more efficient heat dissipation and thus greater tolerance to tropical temperatures^(28,32).

How solar radiation affects animals

Animals exposed to solar radiation for long periods, that live at high altitudes and/or in the tropics tend to lack pigment in the epidermis, have little hair or suffer hair loss and/or are at higher risk of skin diseases⁽³³⁻³⁶⁾. This occurs because UV rays damage cell DNA⁽³³⁾, which induces the cyclobutane pyrimidine dimers (CPD), pyrimidine (6,4) and pyrimidinone (6,4 PP), which cause negative effects such as inhibition of replication and transcription, increased mutations, halting of the cell cycle and cell death⁽³⁷⁾. One disease associated with these factors is squamous cell carcinoma (SCC) -also known as epidermoid carcinoma⁽³⁴⁾- a malignant tumor affecting keratinocytes in the epidermis^(35,36), that is locally invasive but not necessarily metastatic⁽³³⁾, but can compromise the dermis⁽³⁸⁾.

Found mainly in bovine species, these tumors are most frequent in the Hereford, Simmental and Holstein breeds, all of which have white skin without pigmentation, particularly in the eyes^(34,35). This condition causes heavy financial losses due to eye cancer, known also as pink eye, which is common in these breeds⁽³⁹⁾. It is genetic in origin but associated with UV exposure. Older individuals are most affected although younger ones can also develop it, especially those with a white face and little pigment⁽³⁹⁾. Felids and canids are also at risk^(40,41), but it is uncommon in sheep and pigs^(33,35,36). The most sensitive horse breeds are Belgian, Clydesdale, Shire and Appaloosa, in which lesions appear largely in muco-cutaneous regions (e.g. conjunctiva, vulva, perineum)⁽³⁴⁾. Squamous cell carcinoma (SCC) occurs in 20 to 30 % of canids and 70 % of felids with no differences by sex, mostly in large breeds and animals older than 10 yr⁽⁴²⁾. Lesions in canids occur most frequently on the trunk, limbs, scrotum, lips and nail bed⁽³⁸⁾, while in felids they are mostly on the face and ears of white-haired individuals⁽⁴²⁾.

Exposure to UV light can also cause melanocytomas, formed in melanocytes in the epidermis, the cells that provide pigmentation to the skin, eyelashes and hairs⁽⁴³⁾. In bovines, from 80 to 90 % of these tumors are benign, they are located mainly in the skin of the extremities, are not age- or sex-dependent and are more prevalent in dark-colored animals (grey, red and black)⁽⁴³⁾. Called melanomas in other domestic animals, they are usually malignant, are common in canids and equids, and are rare in cats and other species^(41,43,44).

In dogs melanomas account for 4.7 % of all neoplasms and more than 7 % of malignant tumors^(44,45). They are most common in the mouth (56 %), followed by the lips (23 %), skin (11 %), toes (8 %) and other locations (2 %), including the eyes⁽⁴⁶⁾. Cutaneous melanomas are relatively frequent, but only 10 % of malignant melanomas are cutaneous and these are largely found on the head and scrotum. Melanoma incidence in canids also

varies by breed, being more frequent in those with marked cutaneous pigmentation, such as the Schnauzer or Scottish Terrier^(45,46). The Irish Setter and Golden Retriever exhibit a higher incidence of subnail melanomas, and the Irish Setter, Chihuahua, Golden Retriever and Cocker Spaniel have a greater risk of labial melanomas^(45,46). The German Shepherd and Boxer have a higher risk of developing oral melanomas^(47,48). Age at melanoma appearance ranges from 1 to 17 yr with an average of 10. Incidence is higher in males than females⁽⁴⁷⁾.

Melanoma is uncommon in cats (<1% of oral neoplasms and about 0.5 % of cutaneous neoplasms)^(49,50,51). Ocular and cutaneous melanomas are more common than intraoral ones^(52,53). The most common locations on the skin are the head, tail, distal extremities and lumbar area^(46,53,54). Prognosis is often poor given that half of cases exhibit recurrence and regional metastases^(46,54,55). Affected animals range in age from 2 to 18 yr, with a peak between 8 and 12 yr^(54,55). There is no apparent effect of sex or breed on frequency^(54,55).

Another UV-related ailment is appearance of hemangiosarcomas, malignant tumors most common in middle-aged and elderly dogs, especially large breeds such as the greyhound. It affects mainly the spleen, the right atrium of the heart, the subcutaneous/dermal tissue and the liver⁽⁵⁶⁾. Hemangiomas are also related to UV light exposure. These are relatively benign neoplasms in the skin capillaries of the trunk, limbs and soft tissues, but are frequently precursors to hemangiosarcomas⁽⁵⁷⁾.

Pathological effects of ultraviolet radiation

UVA radiation can induce erythema, immediate or delayed pigmentation, alterations of the dermal connective tissue, release of vasoactive mediators, and photo-oxidative stress. It can also exacerbate UVB erythema, carcinogenesis and elastosis, causing alterations in DNA and other structures such as elastic fibers⁽⁵⁸⁾. Exposure to UVA is responsible for many drug photosensitivity reactions, and plays a significant role in diseases such as polymorphic light eruption, chronic actinic dermatitis, actinic reticuloid, lupus erythematosus, solar urticaria, persistent reaction to light and xeroderma pigmentosum (XP)^(59,60). Experimental and clinical evidence have established a close causal relationship between prolonged exposure to UV light and skin cancer, primarily malignant melanoma (MM), squamous cell carcinoma (SCC) and basal cell carcinoma (BCC)^(59,60).

Photosensitivity in animals is classified into three main types. Type I or primary photosensitivity is caused by fluorescent compounds deposited undisturbed on the skin after ingestion since a normal liver is unable to process and excrete the original fluorescent compound. Photosensitizing compounds include hypericin, fagopyrin and

chemical products such as phenothiazine (sulfoxide phenothiazine). Type II photosensitivity, also known as abnormal synthesis of endogenous pigment or congenital porphyria is caused by accumulation of endogenous pigments from abnormal porphyrin metabolism. Photodynamic agents include uroporphyrin I, coproporphyrin I, and protoporphyrin III. These accumulate in the blood and tissues in response to dysfunction in heme group biosynthesis due to an enzymatic deficiency. For example, congenital protoporphyrin in bovines is caused by a deficiency in uroporphyrinogen III cosynthetase, a key enzyme in heme group biosynthesis. Type III or hepatotoxic photosensitivity is more common and can have financial impacts. Animals become sensitized due to accumulation of phylloerythrin, a product of chlorophyll digestion in the peripheral circulatory system. Phylloerythrin is usually excreted in bile by the liver, but in certain types of diffuse lesions, the liver is associated with a variety of vegetable, fungal, and chemical hepatotoxins that are gradually absorbed by the circulatory system until attaining levels that generate photosensitivity. This toxic matter acts directly on the cells of the liver and small bile ducts, causing them to inflame and preventing passage of bile, causing jaundice or yellow coloring⁽⁶¹⁾.

Beneficial effects of ultraviolet radiation

One of the principal benefits of solar radiation is that it allows some homeothermic animals to maintain proper internal body temperature for metabolism⁽⁶²⁾. Another well-known benefit, particularly of UVB, is enabling vitamin D metabolism, indeed, insufficient exposure can lead to vitamin D deficiency⁽⁶²⁾. This can have immediate effects on the skeletal system by increasing the risk of fractures since vitamin D₃ is produced daily to control absorption, transport and deposit of calcium (and to a lesser extent phosphorus), a vital function in bone maintenance and growth regulation. Vitamin D is also necessary for hormonal functioning, organ development and embryogenesis⁽⁶²⁾. Ultraviolet B radiation is important for animal health because it is required for the photochemical processes involved in vitamin D synthesis⁽⁶²⁾. In other words, even if animals receive an adequate diet and are in an optimum temperature, they will be unable to correctly incorporate many nutrients if not provided with the radiation needed for vitamin D production⁽⁶²⁾.

Irradiation is vital to food safety in that it contributes to preservation by preventing food from degrading and spoiling, and the appearance of undesired conditions such as emergence of tubers. It can also destroy some insects, fungi and bacteria⁽⁶³⁾.

Conclusions

Domestic animals are almost constantly exposed to ultraviolet radiation but changes in climate may increase UVB radiation exposure with possible negative health consequences. Sensitivity to exposure varies between species and even between breeds within the same species. Many may develop cutaneous pathologies, including skin cancer, which cause significant financial losses in the agricultural sector, undermine animal health and well-being, and compromise the quality and safety of animal products intended for human consumption.

Literature cited:

1. Toca TC. Impacto ambiental empresarial y fallas de la acción pública: una realidad de las localidades bogotanas. *Argos* 2011;28:244-269.
2. Albanil E, Ramírez R, Jiménez B. Reporte del Clima en México <http://smn.cna.gob.mx/climatologia/analisis/reporte/Anual2014.pdf>, Consultado 26 de Feb, 2015.
3. Alonso S, Ramírez N, Taylor PJ. El cambio climático y su impacto en la producción de alimentos de origen animal. <http://www.veterinaria.org/revistas/redvet/n111112.html>, Consultado 29 de May, 2015.
4. Ferramola SA, Sancovich HA. Interacciones de las radiaciones electromagnéticas y especies reactivas del oxígeno sobre la piel. *Rev Argent Dermatol* 2006;87:113-120.
5. Rivas AM, Rojas EE, Cortés NJ, Santander GE. Efecto de la altura en la radiación solar ultravioleta en Arica Norte de Chile. *Revista Facultad de Ingeniería, U.T.A.* 2002;10:59-62.
6. Bohórquez BJ, Pérez JF. Radiación ultravioleta. *Ciencia & Tecnología para la salud visual y ocular. Rev Lasalle* 2007;9:97-104.
7. Navas G, Jairo T, Rodrigo C. Non-Ionizing Radiation Detection. *Dyna* 2009;76:71-81.
8. Guerreo AJ, Pérez AJ. Las radiaciones no ionizantes y su efecto sobre la salud humana. *Rev Cubana Med Milit* 2006;35:3-11.

9. Pérez A, Miranda LR. Radiaciones electromagnéticas y salud en la investigación médica. *Rev Cubana Med Militar* 2010;39:35-43.
10. Mignone C, Barnes R. More than meets the eye: the exotic, high-energy Universe. *Sci in School* 2012;24:53-58.
11. Rivas A, Rojas E, Madronich S. Aumento del índice solar ultravioleta con la altura. *Rev Chilena Ing* 2008;16:383-388.
12. Gonzáles PM, Vernhes TM, Sánchez LA. La radiación ultravioleta. Su efecto dañino y consecuencias para la salud humana. *Theoria* 2009;18:69-80.
13. Vallejo EO, Vargas N, Martínez LM, Agudelo CA, Ortiz IC. Perspectiva genética de los rayos UV y las nuevas alternativas de protección solar. http://www.scielo.org.ar/scielo.php?script=sci_arttext&pid=S1851300X2013000300002Rev, Consultado 17 Sep, 2015.
14. Luigi PG, Rightler AL, Heronc M, Gabbuttc CD. Extending human perception of electromagnetic radiation to the UV region through biologically inspired photochromic fuzzy logic (BIPFUL) systems. *Chem Commun* 2016;52:1474-1477.
15. Byrne SN, Hammond KJ, Chan CY, Rogers LJ, Beaugie C, Rana S, Marsh-Wakefield F, Thurman JM, Halliday GM. The alternative complement component factor B regulates UV-induced oedema, systemic suppression of contact and delayed hypersensitivity, and mast cell infiltration into the skin. *Photochem Photobiol Sci* 2015;14:801-806.
16. Sánchez C. Consideraciones sobre la capa de ozono y su relación con el cáncer de piel. *Rev Méd Chile* 2006;134:1185-1190.
17. Erickson DJ, Sulzberger B, Zeppc RG, Austind AT. Effects of stratospheric ozone depletion, solar UV radiation, and climate change on biogeochemical cycling: interactions and feedbacks. *Photochem Photobiol* 2015;14:127-148.
18. Environment Canada. The UV Index and Ozone <http://www.ec.gc.ca/uv/Default.asp?lang=En&n=C74058DD>, Accessed Feb 16, 2015.
19. Bornman JF, Barnes PW, Robinson SA, Ballaré CL, Flinte SD, Caldwell MM. Solar ultraviolet radiation and ozone depletion driven climate change: effects on terrestrial ecosystems. *Photochem Photobiol* 2015;14:88-10.
20. Baiz AF, McKenzie RL, Bernhard G, Aucamp PJ, Ilyas M, Madronich S, Tourpali K. Ozone depletion and climate change: impacts on UV radiation *Photochem Photobiol. Sci* 2015;14:19-52.
21. Carrasco RL. Efecto de la radiación ultravioleta–B en plantas. *IDESIA Chile* 2009;3:59-76.

22. Castellanos I, Clarena G, Rodríguez T, Iregui G. Estructura histológica normal de la piel del perro. *Rev Med Vet* 2005;10:104-122.
23. Vega PC. *Manual de Histología Esquemática*. 1ra ed. La Habana, Cuba: Editorial Pueblo y Educación; 1980.
24. Dellmann HDB. *Histología veterinaria*. 2a ed. España: Editorial Acribia, Zaragoza; 1994.
25. Megías M, Molist P, Pombal MA. *Atlas de histología vegetal y animal. Órganos animales tegumento*, <https://mmegias.webs.uvigo.es/descargas/o-ategumento.pdf>, Consultado 24 Feb, 2016.
26. Paniagua R, Nistal M, Sesma P, Álvarez U, Fraile M, Anadón B, Sáez RFS, De Miguel MP. *Citología e histología vegetal y animal*. 2a ed. España: Editorial McGraw-Hill-Interamericana de España; 1997.
27. Ross MH, Pawlina W. *Histología Texto y Atlas*. 7ª ed. Barcelona, España: Editorial Wolters Kluwer; 2016.
28. Esquivel VC. La raza, el pelo y la piel en función del bienestar animal. *Mundo Pecuário* 2012;1:73-85.
29. Suro RJ, Gutiérrez FL, Ruiz AJ, Bouhann P. El pelo. Generalidades y funciones. *Dermatología CMQ* 2007;4:218-223.
30. William J. *Applied Veterinary*. 2a ed. USA: Editorial Mosby; 1993.
31. Kamwanja LA, Chase CC, Gutierrez JA, Guerriero V, Olson TA, StatusHammond AC, Hansen PJ. Responses of bovine lymphocytes to heat shock as modified by breed and antioxidant. *J Anim Sci* 1994;72:438-444.
32. Pérez EH. *Fisiología Animal II*. <http://cenida.una.edu.ni/relectronicos/RENL50P438.pdf>. Consultado 28 Sep, 2016.
33. Rosolem MC, Moroz LR, Rodigheri SM. Carcinoma de células escamosas. *Pubvet* 2012;6:6-14.
34. Ramos AT, Mollerke ND, Elias FM, Gevehr FC. Carcinoma de células escamosas em bovinos, ovinos e eqüinos: estudo de 50 casos no sul do Rio Grande do Sul. *Braz Vet Res Anim Sci* 2007;44:5-13.
35. Fabricio KL, Dantas AF, Riet CF, De Miranda NE, Simões SV, Azevedo SS. Fatores de risco associados à ocorrência de carcinoma de células escamosas em ruminantes e equinos no semiárido da Paraíba. *Pesq Vet Bras* 2012;32:881-886.

36. Targino J, Almeida S, Macedo E, Almeida BE, Santana de OR, Anjos FE, Ocampos PPM. Squamous cell carcinoma in the frontal region of the head in a goat. *Acta Scient Vet* 2013 41:4-8.
37. Tafurt Y, Marin MA. Principales mecanismos de reparación de daños en la molécula de ADN. *Rev Biosalud* 2014;132: 95-110.
38. Costa C, Ramos VD, Huppel R, Barboza DA, Gaspar RA, Rivera CL, Ramirez UR. Cryosurgery in the treatment of squamous cell carcinoma in dog. *Rev Colomb Cienc Anim* 2013;5:213-221.
39. Heather ST. Combata el cáncer de ojo. *Hereford, Bs.As.* 1999;(64):38-40.
40. Olinda RG, Frade MT, Soares GS, Aguiar GM, De Costa VM, Lucena RB, De Dantas AF. Bovine demodicosis associated with squamous cell carcinoma of the vulva. *Acta Scient Vet* 2013;41:29-32.
41. Mukaratirwa S, Chipunza J, Chitunga S, Chimonyo M, Bhebhe E. Canine cutaneous neoplasms: prevalence and influence of age, sex and site on the presence and potential malignancy of cutaneous neoplasms in dogs from Zimbabwe. *J S Afr Vet Ass* 2005;76:59–62.
42. Revista de la Asociación Madrileña de Veterinarios de Animales de Compañía. <https://es.scribd.com/document/26893256/Revista-de-La-Asociacion-Madrilena-de-Veterinarios>, Consultada 14 Ene, 2010.
43. Chávez VC, Astaiza MJ, Benavides MC, Vallejo TD. Tumor maligno derivado de melanocitos en piel de un bovino de presentación inusual: estudio de caso. *Rev Med Vet* 2015;29:63-72.
44. Iakatos I, Mirela E, Cadar, Ali B. Cutaneous tumors' incidence in dog. *Lucrări Stiințifice Medicină Veterinară* 2009;13:475-381.
45. Silva HG, Juárez BF, López VM, Dávila PM. Squamous cell carcinoma in dogs from Culiacan, Sinaloa, Mexico Retrospective Rev (2006-2014). *Rev Cient, FCV-LUZ* 2015;25:573-584.
46. Goldschmidt MH, Shofer FS. *Skin tumors of the dog and cat.* Oxford, UK: Butterworth Heinemann; 1992;2:142-151.
47. Todoroff RJ, Brodey RS. Oral and pharyngeal neoplasia in the dog: a retrospective survey of 361 cases. *J Am Vet Med Assoc* 1979;175:567-571.
48. Oakes MG, Lewis DD, Hedlund CS, Hosgood G. Canine oral neoplasia. *Contin Educ Pract Vet Comp* 1993;15:15-30.

49. Patnaik AK, Mooney S. Feline melanoma: a comparative study of ocular, oral and dermal neoplasms. *Vet Pathol* 1988;25:105-112.
50. Stebbins KE, Morse CC, Goldschmidt MH. Feline oral neoplasia: a ten-year survey. *Vet Pathol* 1989;26:121-128.
51. Miller WH, Scott DW, Anderson WI. Feline cutaneous melanocytic neoplasms: a retrospective analysis of 43 cases (1979-1991). *Vet Dermatol* 1993;4:19-26.
52. Engle CG, Brodey RS. A retrospective study of 395 feline neoplasms. *J AM Anim Hosp Assoc* 1969;5:21-31.
53. Day MJ, Lucke VM. Melanocytic neoplasia in the cat. *J Small Anim Pract* 1995;36:207-213.
54. Van Der- Linde SJS, De- Wit MML, Van- Garderen E, Molenbeek RF, Van Der- Velde ZD, De- Weger RA. Cutaneous malignant melanomas in 57 cats: identification of (amelanotic) signet-ring and balloon cell types and verification of their origin by immunohistochemistry, electron microscopy, and in situ hybridization. *Vet Pathol* 1997;34:31-38.
55. Luna LD, Higginbotham ML, Henry CJ, Turnquist SE. Feline non-ocular melanoma: a retrospective study of 23 cases (1991-1999). *J Feline Med Surg* 2000; 2:173-181.
56. Weinborn AR, Issotta CC, Agurto MM, Lara LJ. Descripción clínica de hemangiosarcoma (HSA) cutáneo metastásico en un canino galgo: estudio clínico de un caso. *Rev Med Vet* 2015;2:107-116.
57. Aita N. Hemangioma of the ileum in a dog. *J Vet Med Sci* 2010;72:1071-1073.
58. López CC, Aréchiga OE, López CM. Protein kinases and transcription factors activation in response to UV-radiation of skin: Implications for carcinogenesis. *Int J Mol Cienc* 2012;13:142-172.
59. Duro ME, Campillos P, Causín S. El sol y los filtros solares. *Medifam* 2003;13: 159-165.
60. Alvarez FE. Consecuencias del estrés oxidativo de la piel por radiaciones ultravioleta. http://scielo.sld.cu/scielo.php?script=sci_arttext&pid=S086403001995000100004, Consultado 10 Nov, 2016.
61. Cruz CF. Fotosensibilización. <http://www.ammveb.net/clinica/fotosensibilizacion.pdf>, Consultado 20 Oct, 2016.

62. Fernández L, Poletta GL, Imhof A, Siroski PA. Efectos de la radiación ultravioleta natural y artificial (UVA/ UVB) sobre la concentración plasmática de calcio y fósforo y el crecimiento en crías de *Caiman latirostris*. *InVet* 2013;15:75-82.
63. Ross LI, Watson D, Escandarani S, Miranda A, Troncoso A. La radiación a la mesa. *Rev Chilena Infect* 2009;26:318-330.