

Research note

Southern pudu (*Pudu puda*) (Artiodactyla: Cervidae) as an additional host for *Dictyocaulus eckerti* (Strongylida: Dictyocaulidae)

Pudú (Pudu puda) (Artiodactyla: Cervidae) como un hospedero adicional para Dictyocaulus eckerti (Strongylida: Dictyocaulidae)

Pablo Oyarzún-Ruiz ^{a,*}, Pamela Muñoz ^a, Gastón Valenzuela ^b

^a Unidad de Parasitología Veterinaria, Facultad de Ciencias Veterinarias, Universidad Austral de Chile, casilla 567, Valdivia, Chile

^b Unidad de Parasitología, Facultad de Recursos Naturales, Universidad Católica de Temuco, casilla 15 D, Temuco, Chile

*Corresponding author: p.oyarzunruiz@uach.cl (P. Oyarzún-Ruiz)

Recibido: 24 mayo 2017; aceptado: 04 octubre 2017

Abstract

Southern pudu (*Pudu puda* Molina, 1782) is the most austral native deer in South America, being distributed in Chile and Argentina, countries where it has conservation issues. Seven lungworms were isolated from the bronchi of one southern pudu from Los Ríos region. Such helminths were identified as adult females and males of *Dictyocaulus eckerti* Skrjabin, 1931, a lungworm isolated in wild and domestic deers from Europe, New Zealand and North America. There are previous reports of unidentified species of *Dictyocaulus* in *P. puda* from Southern Chile. However, this is the first record of *P. puda* acting as a natural host of *D. eckerti*. Due to the establishment of wild populations of European deers in Southern Chile, sharing grazing places between native and exotic deers could allow for the transmission of such parasites. Thus, the present report highlights the potential additional impact of exotic mammals over this threatened deer.

Keywords: Native deer; Helminths; Lungworm; Chile

Resumen

El pudú (*Pudu puda* Molina, 1782) es el ciervo nativo más austral de Sudamérica, se distribuye en Chile y Argentina y posee problemas de conservación. Se aislaron 7 nemátodos en los bronquios de un pudú proveniente de la región de Los Ríos. Los helmintos se identificaron como hembras y machos adultos de *Dictyocaulus eckerti* Skrjabin, 1931, un nemátodo pulmonar aislado en ciervos de Europa, Norteamérica y Nueva Zelanda. Existen reportes previos de especies no identificadas de *Dictyocaulus* en *P. puda* del Sur de Chile. Sin embargo, éste es el primer registro de *P. puda* actuando como hospedador de *D. eckerti*. Debido al establecimiento de poblaciones ferales de ciervos europeos en el Sur de Chile, se plantea que el compartir sitios de pastura permitiría la transmisión de dichos nemátodos. Es así como el presente trabajo entrega antecedentes sobre el potencial impacto adicional que poseen los mamíferos exóticos sobre este ciervo amenazado.

Palabras clave: Ciervo nativo; Helmintos; Nemátodo pulmonar; Chile

Nematodes of the genus *Dictyocaulus* Railliet et Henry, 1907 are found in the bronchial branches of the respiratory system of wild and domestic ruminants, they have a direct life cycle and are considered as important agents of respiratory disease. *Dictyocaulus eckerti* Skrjabin, 1931 (Strongylida: Dictyocaulidae) is a lungworm that parasitizes wild and farmed deers mainly from Europe and Oceania (Gibbons & Khalil, 1988; Panuska, 2006). For some time *D. eckerti* was considered a synonym of *Dictyocaulus viviparus* (Bloch, 1782) Railliet et Henry, 1907, the cattle lungworm. At present, with the aid of molecular tools, both nematodes are classified as separate species (Divina et al., 2002; Epe et al., 1995; Höglund et al., 2003; Johnson et al., 2001). The southern pudu *Pudu puda* Molina, 1782 (Artiodactyla: Cervidae) is the most austral deer in South America, being restricted to the southern temperate rainforest of Argentina and Chile (Jiménez, 2010). According to Silva-Rodríguez et al. (2016) *P. puda* is cataloged as Near Threatened with its populations decreasing. Meanwhile in Argentina and Chile it is considered as a Vulnerable species (Jiménez, 2010). Wild mammals such as the Southern pudu are threatened by anthropogenic factors, i.e., destruction of habitat, road kills, hunting activities by local residents and predation by domestic and feral dogs (Jiménez, 2010; Silva-Rodríguez et al., 2009). On the other hand, the surveillance of pathogens such as viruses, bacterias and parasites is necessary to understand the distribution of those agents and assess the potential impact on these mammal species (Pedersen et al., 2007). There are few reports with regard to the helminth fauna of *P. puda*. Some species recorded are gastrointestinal nematodes as *Nematodirus* sp. (Nematoda: Molineidae), *Oesophagostomum venulosum* Rudolphi, 1809 (Nematoda: Chabertiidae), *Cooperia* sp., *Ostertagia* sp., *Ostertagia ostertagi* Stiles, 1892, *Spiculoptera asymmetrica* Ware, 1925, *Trichostrongylus axei* Cobbold, 1879 (Nematoda: Trichostrongylidae) and parasites of the liver as *Fasciola hepatica* Linnaeus, 1758 (Platyhelminthes: Fasciolidae). Furthermore, some larval metazoan were also mentioned, i.e. as hydatid cyst of *Echinococcus granulosus* Batsch, 1786, *Cysticercus tenuicollis* of *Taenia hydatigena* Pallas, 1766 (Platyhelminthes: Taeniidae), nymphs of *Linguatula serrata* Fröhlich, 1789 (Arthropoda: Linguatulidae) and muscle cysts of the protozoan *Sarcocystis* sp. (Apicomplexa: Sarcocystidae) (Díaz et al., 1977; Duval et al., 1990; Fernández & Villalba, 1986; Fugasa, 2015; González-Acuña, 2002; Ríosco et al., 1976, 1979).

A pool of nematodes kept in the Helminthological Collection of the Laboratory of Veterinary Parasitology of the Universidad Austral de Chile (1163Parasitol. UACH) was used for the present study. The nematodes were isolated from the bronchi of a Southern pudu from

an unspecified locality of Los Ríos Region, Southern Chile (40°13'51" S; 72°19'52" O). The lungworms were mounted in Amann's lactophenol solution for 7 days in order to achieve diaphanization. Then, they were measured with the software ScopeImage v9.0 associated with a light microscope SudeLab. All measurements were expressed in μm , unless otherwise stated, and subsequently compared with published data, i.e. Bienioschek et al. (1996), Divina et al. (2000), Durette-Desset et al. (1988), Gibbons and Khalil (1988), Jansen and Borgsteede (1990) and Panayotova-Pencheva (2012).

All the nematodes were identified as ovigerous females ($n = 3$) and adult males ($n = 4$) of *Dictyocaulus eckerti* Skrjabin, 1931 (Nematoda: Dictyocaulidae) (Fig. 1-4, Table 1). The morphology and morphometric characters were coincident with those given by previous authors. However, according to Bienioschek et al. (1996), Divina et al. (2000), Durette-Desset et al. (1988), Gibbons and Khalil (1988), and Jansen and Borgsteede (1990) the buccal capsule is the most important character to distinguish *D. eckerti* from the other species of *Dictyocaulus*, being kidney- or bean-shaped and with a thick wall, as was evident in the present specimens (Fig. 1). Indeed, such morphological characters has been verified with molecular tools (Divina et al., 2000). Regarding this genus, there are previous reports of an unidentified *Dictyocaulus* in *P. puda* from Southern Chile (Díaz et al., 1977; Ríosco et al., 1979). However, this is the first report of *D. eckerti* in this cervid. Another lungworm isolated from Southern pudu was *Muellerius* sp. (Nematoda: Protostrongylidae) (Duval et al., 1990), which commonly parasitizes small ruminants such as sheep and goats (Panuska, 2006). *Dictyocaulus eckerti* have been found in various species of Cervidae (i.e., *Alces alces*, *Cervus elaphus*, *Dama dama*, *Capreolus capreolus*, *Rangifer tarandus* Linnaeus, 1758) mainly from Europe (Ács et al., 2016; Carreno et al., 2009; Divina et al., 2000, 2002; Höglund et al., 2003; Hugonnet & Cabaret, 1987; Panadero et al., 2001; Rahko et al., 1992; Rehbein et al., 2014), New Zealand (Johnson et al., 2001, 2003) and North America (Fruetel & Lankester, 1989; Kutz et al., 2012).

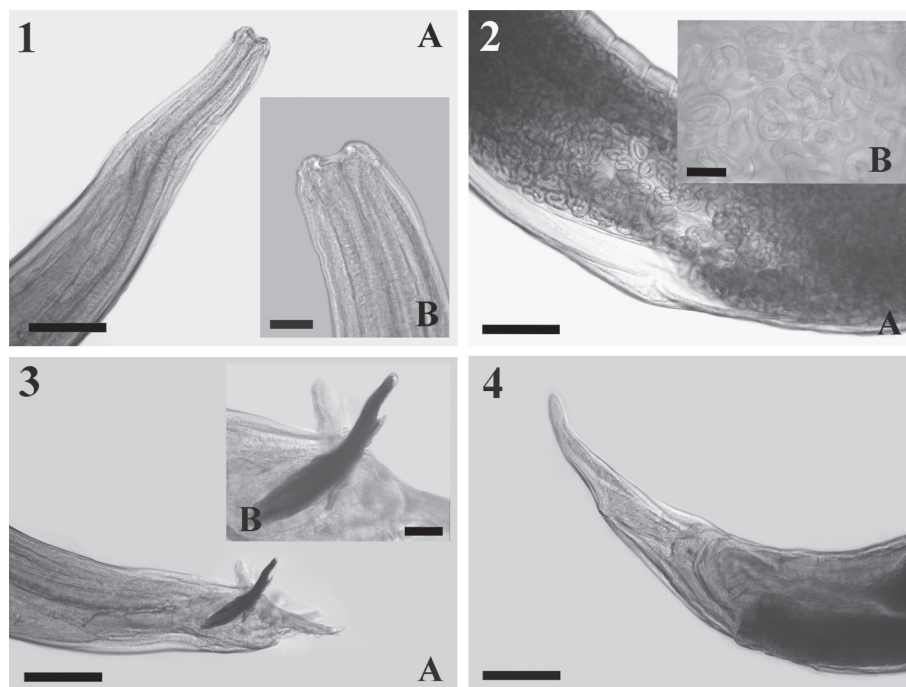
Some of the parasites recorded for the Southern pudu could have a domestic origin, with dogs acting as definitive hosts, e.g. hydatid cyst, *C. tenuicollis*, *L. serrata* and *Sarcocystis* sp. or could be acquired from wild canids such as foxes (Fugasa, 2015; Kutz et al., 2012). In the same way, other helminths are shared with livestock and free-ranging exotic ruminants, e.g. *O. ostertagi* and *S. asymmetrica* (Jiménez, 2010). *Cervus elaphus* and *D. dama* recorded as host for *D. eckerti* were introduced in Chile years ago for commercial and hunting activities. At present, also wild populations are established in national territory

Table 1

Comparison of morphometric characters of *Dictyocaulus eckerti* isolated from different hosts, including *Pudu puda*. Measurements expressed in μm as a range, unless otherwise stated.

Reference	Skrjabin, Shihobalova & Shultz (1954)**	Durette-Desset et al. (1988)	Gibbons & Khalil (1988)	Divina et al. (2000)	Panayotova-Pencheva (2012)	Present study						
Hosts	<i>Rangifer tarandus</i>	<i>Capreolus capreolus</i>	<i>Axis porcinus</i> , <i>Cervus elaphus</i> , <i>Cervus nippon</i> , <i>Dama dama</i>	<i>Capreolus capreolus</i>	<i>Cervus elaphus</i>	<i>Pudu puda</i>						
Country	Russia	France	England	Sweden	Bulgaria	Chile						
	♂	♀	♂	♀	♂	♀						
TBL*	18.9-40.5	31.8-65.0	25.0-51.0	36.8-63.9	12.0-44.0	20.0-59.0	28.0-62.0	33.0-81.0	10.9-40.0	29.0-59.0	30.0-38.5	58.0-59.0
OL*	0.9-1.2	0.9-1.2	0.9-1.2	0.9-1.3	0.6-1.3	0.8-1.5	-	-	1.0-1.4	1.0-1.4	1.1-1.2	1.0-1.2
OW	120.0-192.0	152.0-176.0	-	-	-	-	-	-	111.4-200.0	115.2-169.0	107.8-137.4	150.6
BCWM	-	-	Kidney-shaped		Kidney-shaped		Kidney-shaped		Kidney-shaped		Kidney-shaped	
BCWT	-	-	9.0-10.0		-	-	8.0-12.6	8.2-14.9	-	-	9.8-12.6	9.1
BCWL	-	-	12.0-14.0		-	-	13.2-23.8	14.5-23.4	-	-	21.5-22.3	21.0
CVL	-	-	-	-	134.0-218.0	149.0-216.0	-	-	-	-	-	-
BWDE	248.0-432.0	248.0-432.0	-	-	-	-	-	-	184.3-420.0	172.8-288.0	272.5-328.6	329.1
BWV	-	352.0-640.0	-	-	-	294.0-526.0	-	-	-	299.5-540.0	-	519.7-624.8
DAN	-	-	325.0	225.0-400.0	-	-	-	-	-	-	-	-
DAE	-	-	250.0-570.0	240.0-520.0	351.0-602.0	294.0-611.0	-	-	-	-	405.6-527.1	375.0
DAC	-	-	540.0	530.0	356.0-630.0	408.0-642.0	-	-	-	-	431.8-527.1	375.0
DAV*	-	14.4-29.9	-	15.4-36.3	-	10.4-33.0	-	-	-	20.0-28.0	-	28.0-29.0
SL	190.0-360.0	-	230.0-260.0	-	180.0-245.0	-	127.1-293.7	-	219.1-292.3	-	237.1-269.9	-
GL	40.0-52.0	-	55.00-65.0	-	31.0-67.0	-	-	-	40.8-70.0	-	53.3-55.4	-
TL	-	300.0-400.0	-	350.0-460.0	-	-	-	-	-	257.3-400.0	-	445.1-520.9
EL	-	68.0-92.0	-	75.0-100.0	-	74.0-113.0	-	-	-	84.0-99.9	-	70.1-88.0
EW	-	44.0-50.0	-	40.0-60.0	-	37.0-55.0	-	-	-	40.1-51.0	-	44.6-53.4
OL/TBL	0.030-0.048	0.018-0.028	0.024-0.036	0.020-0.026	0.030-0.050	0.025-0.040	-	-	0.035-0.092	0.024-0.034	0.032-0.043	0.021
DAV/ TBL	-	0.453-0.460	-	0.418-0.568	-	0.520-0.559	-	-	-	0.475-0.690	-	0.475-0.500
SL/TBL	0.009-0.010	-	0.005-0.009	-	0.006-0.015	-	0.005	-	0.007-0.020	-	0.006-0.009	-
GL/SL	0.144-0.211	-	0.239-0.250	-	0.172-0.273	-	-	-	0.186-0.239	-	0.205-0.225	-

TBL = total body length; OL = oesophagus length; OW = oesophagus width; BCWM = buccal capsule wall morphology; BCWT = buccal capsule wall thickness; BCWL = buccal capsule wall length; CVL = cephalic vesicle length; BWDE = body width at distal end oesophagus; BWNR = body width at nerve ring; BWV = body width at vulva; DAN = distance between anterior end-nerve ring; DAE = distance between anterior end-excretory pore; DAC = distance between anterior end-cervical papillae; DAV = distance between anterior end-vulva; SL = spicules length; GL = gubernaculum length; TL = tail length; EL = eggs length; EW = eggs width; OL/TBL = ratio oesophagus length/body length; DAV/TBL = ratio distance between anterior end-vulva/body length; SL/TBL = ratio spicule length/Body length; GL/SL = ratio gubernaculum length/spicule length; *measurements expressed in millimeters (mm); **cited in Panayotova-Pencheva (2012).



Figures 1-4. *Dictyocaulus eckerti* from *Pudu puda*. 1. A, anterior end with a wide buccal capsule. Scale bar = 200 μ m; B, buccal capsule with thick kidney-shaped wall. Scale bar = 50 μ m. 2. A, uterus full of embryonated eggs. Scale bar = 200 μ m; B, larvae coiled inside eggs, typical of lungworms. Scale bar = 50 μ m. 3. A, posterior end of a male specimen, note the small copulatory bursa with short spicules. Scale bar = 200 μ m; B, close-up of spicules and gubernaculum immediately below it. Scale bar = 50 μ m. 4. Finger-shaped posterior end of female. Scale bar = 200 μ m.

(Díaz et al., 1977; Jaksic et al., 2002). *Dictyocaulus eckerti* seems to have a wide host range (Divina et al., 2002), thus *P. puda* could not be an accidental host. In consequence, the interaction of exotic species with Southern pudu through sharing grazing areas could promote the transmission of parasites.

On the other hand, the detection of *Toxoplasma gondii* Nicolle & Manceaux, 1908 and *Neospora caninum* Dubey, Carpenter, Speer, Topper & Uggla, 1988 (Apicomplexa: Sarcocystidae) should be of interest because they can infect deers with the risk of causing abortions and neonatal mortality (De Craeye et al., 2011; Dubey et al., 2008; Kutz et al., 2012), thus being of importance for species with conservancy issues. Finally, the finding of this lungworm, as well as previous records of adult and larval parasites, highlight the additional impact of non-native mammals over this threatened deer (Díaz et al., 1977; Río-seco et al., 1979).

We are grateful of Dr. Enrique Paredes who donated to us the specimens isolated from a Southern pudu. Also to the Drs. Anna Pyziel, Marion Johnson, Steffen Rehbein and Sinasi Umur for helping us with the literature, and to the anonymous reviewers for their valuable comments.

References

- Ács, Z., Hayward, A., & Sugár, L. (2016). Genetic diversity and population genetics of large lungworms (*Dictyocaulus*, Nematoda) in wild deer in Hungary. *Parasitology Research*, 115, 3295–3312.
- Bienioschek, S., Rehbein, S., & Ribbeck, R. (1996). Cross-infections between fallow deer and domestic ruminants with large lungworms (*Dictyocaulus* spp.). *Applied Parasitology*, 37, 229–238.
- Carreno, R., Díez-Baños, N., Hidalgo-Argüello, M., & Nadler, S. (2009). Characterization of *Dictyocaulus* species (Nematoda: Trichostrongyloidea) from three species of wild ruminants in northwestern Spain. *Journal of Parasitology*, 95, 966–970.
- De Craeye, S., Speybroeck, N., Ajzenberg, D., Dardé, M. L., Collinet, F., Tavernier, P. et al. (2011). *Toxoplasma gondii* and *Neospora caninum* in wildlife: common parasites in Belgian foxes and Cervidae?. *Veterinary Parasitology*, 178, 64–69.
- Díaz, L., Río-seco, H., & Cubillos, V. (1977). Prospección y patología del parasitismo en cérvidos autóctonos y exóticos en el Sur de Chile. *Boletín Chileno de Parasitología*, 32, 86–89.
- Divina, B. P., Wilhelmsson, E., Mattsson, J. G., Waller, P., & Höglund, J. (2000). Identification of *Dictyocaulus* spp.

- in ruminants by morphological and molecular analyses. *Parasitology*, 121, 193–201.
- Divina, B. P., Wilhelmsson, E., Mörner, T., Mattsson, J. G., & Höglund, J. (2002). Molecular identification and prevalence of *Dictyocaulus* spp. (Trichostrongyloidea: Dictyocaulidae) in Swedish semi-domestic and free-living cervids. *Journal of Wildlife Diseases*, 38, 769–775.
- Dubey, J. P., Velmurugan, G. V., Ulrich, V., Gill, J., Carstensen, M., Sundar, N. et al. (2008). Transplacental toxoplasmosis in naturally-infected white-tailed deer: Isolation and genetic characterisation of *Toxoplasma gondii* from foetuses of different gestational ages. *International Journal for Parasitology*, 38, 1057–1063.
- Durette-Desset, M. C., Hugonnet, L., & Chabaud, A. G. (1988). Redescription de *Dictyocaulus noerteri* Railliet et Henry, 1907, parasite de *Capreolus capreolus* en Europe. Comparaison avec *D. viviparus* (Bloch, 1782) parasite du bétail. *Annales de Parasitologie Humaine et Comparee*, 63, 285–295.
- Duval, S., Sievers, G., & Valverde, M. (1990). Contribución al diagnóstico de los parásitos del Pudú. Congreso de Medicina Veterinaria, 25-27 Octubre 1990, Valdivia, Chile. *Archivos de Medicina Veterinaria*, Número Ext. VIII.
- Epe, C., Bienioschek, S., Rehbein, S., & Schnieder, T. (1995). Comparative RAPD-PCR analysis of lungworms (Dictyocaulidae) from fallow deer, cattle, sheep, and horses. *Journal of Veterinary Medicine Series B*, 42, 187–191.
- Fernández, J., & Villalba, C. (1986). Presencia de *Linguatula serrata* Froelich, 1789 en el ciervo chileno *Pudu pudu* (Molina, 1782). *Parasitología al Día*, 10, 29–30.
- Fruetel, M., & Lankester, M. W. (1989). Gastrointestinal helminths of woodland and barren ground caribou (*Rangifer tarandus*) in Canada, with keys to species. *Canadian Journal of Zoology*, 67, 2253–2269.
- Fugassa, M. H. (2015). Checklist of helminths found in Patagonian wild mammals. *Zootaxa*, 4012, 271–328.
- Gibbons, L. M., & Khalil, L. F. (1988). A revision of the genus *Dictyocaulus* Railliet & Henry, 1907 (Nematoda: Trichostrongyloidea) with the description of *D. africanus* n. sp. from African artiodactylids. *Revue de Zoologie Africaine*, 102, 151–175.
- González-Acuña, D. (2002). *Cysticercus tenuicollis* en Pudues (*Pudu pudu*). *Ciencia Ahora*, 5, 75–78.
- Höglund, J., Morrison, D. A., Divina, B. P., Wilhelmsson, E., & Mattsson, J. G. (2003). Phylogeny of *Dictyocaulus* (lungworms) from eight species of ruminants based on analyses of ribosomal RNA data. *Parasitology*, 127, 179–187.
- Hugonnet, L., & Cabaret, J. (1987). Infection of roe-deer in France by the lung nematode, *Dictyocaulus eckerti* Skrjabin, 1931 (Trichostrongyloidea): influence of environmental factors and host density. *Journal of Wildlife Diseases*, 23, 109–112.
- Jaksic, F., Iriarte, J., Jiménez, J., & Martínez, D. (2002). Invaders without frontiers: cross-border invasions of exotic mammals. *Biological Invasions*, 4, 157–173.
- Jansen, J., & Borgsteede, F. (1990). *Dictyocaulus* species, lungworms in cattle and deer in the Netherlands. *Tijdschrift voor Diergeneeskunde*, 115, 155–158.
- Jiménez, J. (2010). Southern pudu *Pudu pudu* (Molina 1782). In J. M. Barbanti-Duarte, & S. González (Eds.), *Neotropical Cervidology. Biology and medicine of Latin American deer* (pp. 140–150). Jaboticabal: Editorial Funep/IUCN.
- Johnson, M., Mackintosh, C., Labes, R., & Taylor, M. (2001). *Dictyocaulus eckerti*, lungworm infecting farmed red deer in New Zealand. *New Zealand Veterinary Journal*, 49, 34–35.
- Johnson, M., Mackintosh, C., Labes, R., Taylor, M., & Wharton, D. (2003). *Dictyocaulus* species: cross infection between cattle and red deer. *New Zealand Veterinary Journal*, 51, 93–98.
- Kutz, S. J., Ducrocq, J., Verocai, G. G., Hoar, B. M., Colwell, D. D., Beckmen, K. B. et al. (2012). Parasites in ungulates of arctic North America and Greenland. A view of contemporary diversity, ecology, and impact in a world under change. *Advances in Parasitology*, 79, 99–252.
- Panadero, R., Carrillo, E., López, C., Díez-Baños, N., Díez-Baños, P., & Morrondo, M. (2001). Bronchopulmonary helminths of roe deer (*Capreolus capreolus*) in the northwest of Spain. *Veterinary Parasitology*, 99, 221–229.
- Panayotova-Pencheva, M. (2012). Morphometric data on *Dictyocaulus eckerti* (Nematoda: Trichostrongyloidea) in materials from Bulgaria. *Comptes Rendus de l'Academie Bulgare Sciences*, 65, 1225–1232.
- Panuska, C. (2006). Lungworms of Ruminants. *Veterinary Clinics of North America - Food Animal Practice*, 22, 583–593.
- Pedersen, A. B., Jones, K. E., Nunn, C. L., & Altizer, S. (2007). Infectious diseases and extinction risk in wild mammals. *Conservation Biology*, 21, 1269–1279.
- Rahko, T., Saari, S., & Nikander, S. (1992). Histopathological lesions in spontaneous dictyocaulotic pneumonia of the reindeer (*Rangifer tarandus tarandus* L.). *Rangifer*, 12, 115–122.
- Rehbein, S., Visser, M., Jekel, I., & Silaghi, C. (2014). Endoparasites of the fallow deer (*Dama dama*) of the Antheringer Au in Salzburg, Austria. *Wiener Klinische Wochenschrift*, 126, 37–41.
- Rioseco, H., Cubillos, V., González, H., & Díaz, L. (1976). Sarcosporidiosis en pudues (*Pudu pudu*, Molina, 1782) Primera comunicación en Chile. Primer Congreso Nacional de Medicina Veterinaria 20 Octubre 1978, Chillán, Chile. *Archivos de Medicina Veterinaria*, 8, 122–123.
- Rioseco, H., Cubillos, V., & Díaz, L. (1979). Patología en cérvidos. *Archivos de Medicina Veterinaria, Suplem. 1*, 108–110.
- Silva-Rodríguez, E., Verdugo, C., Aleuy, A., Sanderson, J., Ortega-Solis, G., Osorio-Zúñiga, F. et al. (2009). Evaluating mortality sources for the vulnerable pudu *Pudu pudu* in Chile: implications for the conservation of a threatened deer. *Oryx*, 44, 97–103.
- Silva-Rodríguez, E., Pastore, H., & Jiménez, J. (2016). *Pudu pudu*. The IUCN Red List of Threatened Species 2016: e.T18848A22164089. <http://dx.doi.org/10.2305/IUCN.UK.2016-1.RLTS.T18848A22164089>.