

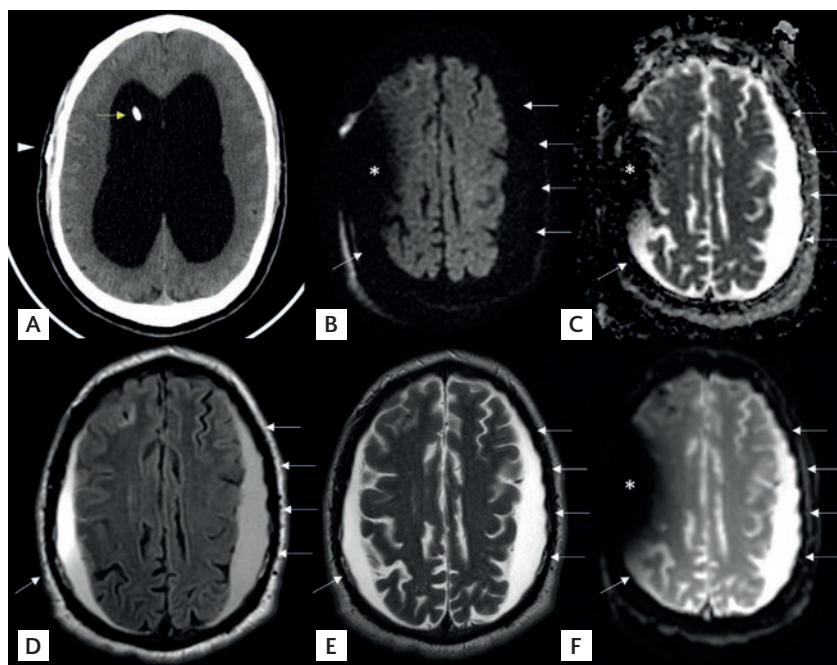
REDISCOVERING EXTRA-AXIAL COLLECTIONS ON MEDICAL IMAGING: SUBDURAL LYMPHATIC HYGROMA

Dear Editor,

Recent literature has sparked interest in the nature of subdural hygromas, particularly regarding their content and etiology. Studies like the one carried out by Albayram et al.¹ utilizing 3D T2 FLAIR magnetic resonance imaging (MRI) sequences have revealed the potential visualization of meningeal lymphatic vessels, which share a similar signal intensity with the lymphatic content. This discovery has led to a reevaluation of subdural hygromas, especially in the context of their relationship with the meningeal lymphatic system.

Recently, a case from our institution caught our attention. A 50-year-old man presented with urinary urgency, vertigo, and gait disturbance. Initial investigations revealed hydrocephalus due to aqueductal stenosis. After ventriculoperitoneal shunt implantation, the patient experienced symptomatic worsening attributed to shunt hyperdrainage. A follow-up MRI (Fig. 1) showed subdural collections with characteristics divergent from typical cerebrospinal fluid and absent hemorrhagic or purulent content.

Figure 1. Lymphatic subdural hematoma secondary to shunt hyperdrainage. **A:** non-enhanced brain computed tomography, axial image. Significant dilation of the lateral ventricles consistent with supratentorial hydrocephalus. Note the presence of a ventricular shunt catheter in the right ventricle (yellow arrow) and a metallic implant device in the subcutaneous tissue (arrowhead). **B-F:** magnetic resonance imaging of the brain, axial; **B:** DWI; **C:** ADC; **D:** T2 FLAIR; **E:** T2-TSE; and **F:** T2-GRE images. Bilateral subdural collections (white arrows) showing increased diffusion, and high signal intensity in T2 FLAIR, T2 and T2-GRE sequences, consistent with lymphatic content. Note the susceptibility artifact in the right hemisphere in **B, C,** and **F** secondary to the subcutaneous metallic shunt valve shown in **A**.



Historically, such collections were identified as subdural hygromas, with CSF-like content but richer in proteins^{2,3}. However, the meningeal lymphatic content would also display this appearance, in agreement with the findings by Albayram et al.¹. Our case supports this notion, indicating a meningeal vessel tear due to shunt-induced rapid intracranial pressure changes as a plausible mechanism.

The term “lymphatic subdural hygroma” is proposed for collections displaying this radiological pattern. This new perspective challenges traditional theories and underscores the need for further research into the cerebral and meningeal lymphatic systems. Our findings suggest broader implications for the interpretation of extra-axial collections in various clinical

scenarios. This expands our understanding and enhances our ability to differentiate the primary diagnostic challenges posed by extra-axial collections on imaging, which include subdural hematoma (chronic, subacute, or acute), subdural empyema, and cerebral atrophy associated with subarachnoid space enlargement.

ACKNOWLEDGMENTS

The study was conducted in agreement with the protocols of the Institutional Review Board of the Hospital Universitario Virgen de las Nieves (Granada, Spain). Written informed consent of the patient was obtained.

REFERENCES

1. Albayram MS, Smith G, Tufan F, Tuna IS, Bostancıoğlu M, Zile M, et al. Non-invasive MR imaging of human brain lymphatic networks with connections to cervical lymph nodes. *Nat Commun.* 2022;13:203.
2. Wittschieber D, Karger B, Niederstadt T, Pfeiffer H, Hahnemann ML. Subdural hygromas in abusive head trauma: pathogenesis, diagnosis, and forensic implications. *AJNR Am J Neuroradiol.* 2015;36:432-9.
3. Wittschieber D, Karger B, Pfeiffer H, Hahnemann ML. Understanding subdural collections in pediatric abusive head trauma. *AJNR Am J Neuroradiol.* 2019;40:388-95.

JOSÉ P. MARTÍNEZ-BARBERO^{1,2}, LUCÍA BUENO-CARAVACA^{1,2}, AND ANTONIO J. LÁINEZ-RAMOS-BOSSINI^{1,2*}

¹Department of Radiology, Hospital Universitario Virgen de las Nieves, Granada, Spain; ²Advanced Medical Imaging Group (TeCe22), Instituto de Investigación Biosanitaria de Granada (IBS Granada), Granada, Spain

*Corresponding author:

Antonio J. Láinez Ramos-Bossini
E-mail: ajbossini@ugr.es

Received for publication: 21-02-2024

Approved for publication: 12-04-2024

DOI: 10.24875/RIC.24000042

0034-8376 / © 2024 Revista de Investigación Clínica. Published by Permanyer. This is an open access article under the CC BY-NC-ND license (<http://creativecommons.org/licenses/by-nc-nd/4.0/>).