Mexican Journal of Oncology
Gaceta Mexicana de Oncología

Check for updates

CLINICAL CASE

Recurrence of pulmonary carcinoid tumor 16 years after primary resection: case report

Paola Palomares-Capetillo, Marco A. Cruz-López, Jorge A. Ramírez-Vidales, and Marco A. Iñiguez-García*

Department of Thoracic Surgery, Instituto Nacional de Enfermedades Respiratorias, Mexico City, Mexico

Abstract

Pulmonary carcinoid tumors are a type of neuroendocrine tumor, considered low-grade with an indolent clinical course. We report the case of a 31-year-old female who presented with hemoptysis 16 years after undergoing a right upper lobectomy for an atypical carcinoid tumor. Bronchoscopy revealed a well-rounded, well-vascularized lesion occluding the bronchus of the left upper lobe; histopathological analysis confirmed a neuroendocrine tumor, and she subsequently underwent a video-assisted lobectomy, which revealed a typical carcinoid tumor. The risk of recurrence in these tumors persists, underscoring the importance of long-term follow-up to detect recurrences and provide timely treatment.

Keywords: *Carcinoid tumor. Lung cancer. Surgical treatment. Surveillance. Case report.*

Recurrencia de tumor carcinoide pulmonar 16 años después de la resección primaria: reporte de caso

Resumen

Los tumores carcinoides pulmonares son del tipo neuroendocrino; se consideran de grado bajo, con curso clínico indolente. Reportamos el caso de una paciente de 31 años que presentó hemoptisis 16 años después de una lobectomía superior derecha por un tumor carcinoide atípico. La broncoscopia mostró una lesión definida, vascularizada, ocluyendo el bronquio del lóbulo superior izquierdo; el análisis histopatológico reveló un tumor neuroendocrino. Se sometió a lobectomía asistida por video, que reveló un carcinoide típico. El riesgo de recurrencia en estos tumores es latente, por ello la importancia del seguimiento a largo plazo para identificar recidivas y ofrecer tratamiento adecuado.

Palabras clave: *Tumor carcinoide. Cáncer pulmonar. Tratamiento quirúrgico. Vigilancia. Reporte de caso.*

***Correspondence:**
Paola Palomares-Capetillo
E-mail: paopalomarescapetillo@gmail.com

Date of reception: 04-08-2024
Date of acceptance: 30-04-2025
DOI: 10.24875/j.gamo.25000061

Available online: 13-08-2025
Gac Mex Oncol. 2025;24(Supl):62-66
www.gamo-smeo.com

2565-005X/© 2025 Sociedad Mexicana de Oncología. Published by Permanyer. This is an open access article under the terms of the CC BY-NC-ND license (http://creativecommons.org/licenses/by-nc-nd/4.0/).

Introduction

Pulmonary carcinoid tumors are part of the spectrum of neuroendocrine tumors and represent 1-5% of all lung neoplasms. They are classified as typical or atypical carcinoids based on the number of mitoses and the presence of necrosis[1-5].

Compared to other lung cancers, carcinoid tumors, especially typical carcinoids, are less aggressive, with a low recurrence rate and low cancer-related mortality after surgical treatment[6,7]. Surgery remains the only curative treatment modality for well-differentiated neuroendocrine tumors, including both typical and atypical carcinoids.

Figure 1. Axial computed tomography. Mediastinal window showing a tumor in the right upper lobe bronchus, which was resected 16 years ago.

Case report

A 31-year-old female with no family history, and with a history of cystic mature teratoma in the right ovary and right oophorectomy in 2004, underwent a right superior lobectomy for atypical carcinoid in 2007 (Fig. 1). In 2021, she was diagnosed with hypothyroidism, without other relevant medical history. In October 2021, she presented with non-threatening hemoptysis, cough, mild chest pain, and a history of prior pneumonia. Bronchoscopy revealed a well-rounded, well-vascularized lesion occluding the bronchus of the left upper lobe; biopsies were taken, and histopathology confirmed a neuroendocrine tumor. During the procedure, a cryoresection was performed, achieving 50% bronchial patency. Immunohistochemistry stains were positive for synaptophysin, with a Ki-67 proliferation index of < 5%.

In 2022, she experienced a normal pregnancy, and surgical treatment was offered postpartum. An 18-F-fludeoxyglucose positron emission tomography scan revealed a 31 mm tumor in the left upper lobe, with an SUVmax of 69.1, and no metabolic activity in other sites (Fig. 2). She underwent VATS and left upper lobectomy with nodal dissection. Intraoperative analysis confirmed free margins and a nodal status negative for malignancy (Fig. 3). The final histopathological diagnosis was a typical carcinoid. During the hospitalization, laboratory tests, monitoring, and management of the chest tube were performed, with all parameters remaining within normal limits. No complications were observed following surgery, and the patient was discharged 5 days later without any issues. Two years after surgery, she remains asymptomatic and has no evidence of a new tumor in imaging studies (Fig. 4).

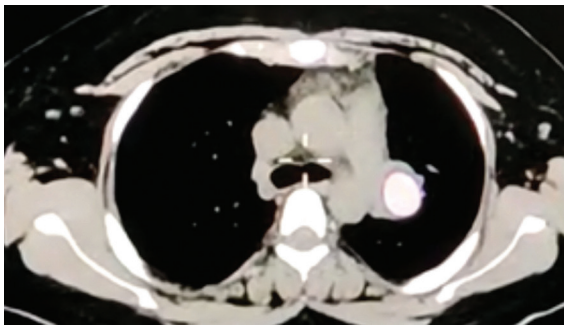

Figure 2. Axial fludeoxyglucose-18 positron emission tomography-computed tomography. Tumor in the left upper lobe bronchus, 2 months before left upper lobectomy.

Discussion

Pulmonary neuroendocrine tumors are well-differentiated tumors, representing 1-2% of all lung cancers in the adult population and 20-30% of all neuroendocrine tumors. The incidence is 2/100,000 people, but it is increasing due to better imaging techniques. Almost 90% are low-grade tumors, typical carcinoids, and 10% are of intermediate grade (atypical carcinoids).

Neuroendocrine cells originate from the neural crest; they contain secretory granules and produce hormonal substances with paracrine or endocrine function. While the majority of neuroendocrine tumors arise in the gastrointestinal tract, 25-30% arise in the lung. According to the World Health Organization (WHO), these tumors are subdivided into four groups based on histopathological characteristics and outcome, resulting in two categories of tumors with different prognosis: well-differentiated and

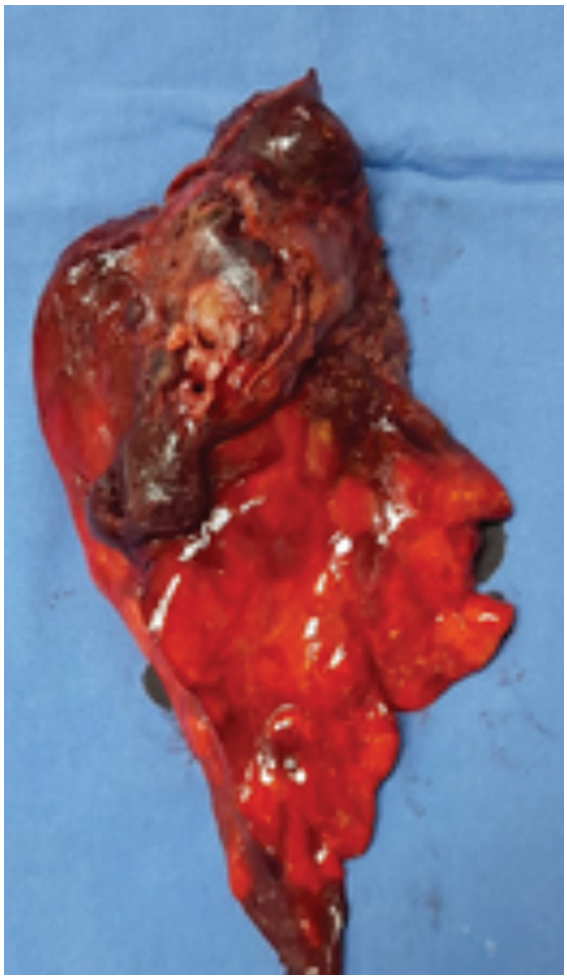

Figure 3. Left upper lobe with a tumor in the superior division of the left upper lobe bronchus.

Figure 4. A post-discharge chest radiograph showing satisfactory re-expansion of the left lung after surgery.

low/intermediate grade (typical and atypical carcinoids); and poorly differentiated and of high grade (large cell neuroendocrine carcinomas and small-cell lung cancers). Majority of the carcinoid tumors are sporadic neoplasms. Unlike high-grade neuroendocrine tumors, carcinoid tumors tend to appear in younger patients, without sex predominance, and are not related to smoking[1], as seen in our patient, whose initial tumor was diagnosed at 15 years of age. About 5% of cases, pulmonary carcinoids arise in the context of multiple endocrine neoplasia type 1, mostly the atypical carcinoids.

Carcinoid tumors can secrete different types of products such as serotonin, histamine, and prostaglandins. These products cause symptoms such as diarrhea and skin flushing, more frequently in gastrointestinal neuroendocrine tumors. Pulmonary carcinoid tumors tend to be asymptomatic or can produce wheezing, dyspnea, cough, hemoptysis, and recurrent pneumonia due to bronchospasm and obstruction[3]. Our patient presented with post-obstructive pneumonia before the diagnosis of the initial tumor; at recurrence, she presented with hemoptysis. About 30% of patients, the diagnosis is incidental due to a long, asymptomatic course. Urinary excretion of 5-hydroxyindoleacetic acid is not helpful in pulmonary carcinoid tumors, as they secrete less serotonin than gastrointestinal carcinoid tumors[3,4].

Bronchoscopy is the cornerstone in the evaluation of pulmonary carcinoids. In our case, a well-rounded and vascularized lesion was observed in the left upper lobe bronchus, as described in 75% of cases[3,4,8,9].

Computed tomography (CT) scan can be used as an approach to assess lymph node involvement, with a 90-93% specificity. However, endobronchial ultrasound shows superiority over CT scanning in mediastinal lymph node evaluation[4]. Based on the evidence, somatostatin receptor imaging (68Ga-DOTA-PET) is the method of choice to fully stage patients with neuroendocrine tumors[5].

In our case, no significant diagnostic challenges were identified, as imaging studies and bronchoscopy allowed for a timely and accurate diagnosis due to the prompt management by the service, given the patient's known medical history.

The most consistent histopathological finding is the cytological uniformity of the cell nuclei, with little

variation from cell to cell, and chromatin with a salt-and-pepper pattern. Neuroendocrine markers include synaptophysin, chromogranin, and CD56. Ki-67 can be useful to distinguish between low-grade and high-grade tumors. Unlike typical carcinoids, atypical carcinoids have a higher number of mutations in *TP53*, *MEN1, BCL2*, and *PIK3CA*, which may explain their aggressive behavior[1,5,7,9,10]. The final diagnosis of our case was typical carcinoid, with immunohistochemistry positive for synaptophysin (++/+++), Ki-67 (+++/+++ in less than 5%), chromogranin A (++/+++), CD56 (+/+++).

While bronchogenic carcinoma could have been a differential diagnosis, the diagnostic impression focused on ruling out a carcinoid tumor due to the patient's history, which was confirmed through histopathology and immunohistochemistry.

Given the indolent conduct of these tumors, complete surgical resection is mandatory, with R0[1,3-4,8-11]. The recommended surgical strategy for typical carcinoids is lobectomy or sublobar resection, with free margins and lymph node analysis, as in our patient[1]. Typical carcinoid tumors of the lung are low-grade neoplasms, characterized by their slow growth and favorable long-term prognosis. These characteristics justified deferring definitive treatment, allowing the patient to safely complete her pregnancy and undergo a PET scan before surgery, ensuring the absence of metastases before the procedure. Previous studies have supported the safety of this strategy in specific patients, with individualized evaluation[12,13]. For atypical carcinoids, lobectomy or pneumonectomy with systemic lymphadenectomy should be performed, as lymph node metastases are present in approximately 30% of cases[3,4,8]. According to the SEER database, sublobar resection is not inferior to lobectomy in stage T1-2N0M0. Therefore, sublobar resection may be considered to preserve pulmonary function and reduce post-surgical complications; however, randomized studies are required to confirm these findings[11].

Carcinoid tumors are not sensitive to chemotherapy or radiotherapy. Because of this, there is a growing interest in exploring targeted therapies against molecular targets for patients with unresectable or metastatic disease. At the moment, the only Food and Drug Administration-approved therapy is everolimus[1,7,9].

The most important prognostic factors in pulmonary carcinoids are histology (atypical), lymph node status, mitotic index, Ki-67 index, and the presence of necrosis[1,3,5].

The primary tumor of our patient was an atypical carcinoid, which, according to the evidence, has a higher risk of recurrence than the typical carcinoids. Lou y cols[6] reported a 6% recurrence rate, after a mean follow-up of 3.5 years. In our patient, recurrence occurred 16 years after the initial resection. Distant sites of recurrence are primarily the liver and bone. 5-year survival rate varies from 89-92% in typical carcinoids, and from 66-75% in atypical carcinoids.

Given the rarity of these tumors, current data do not allow a precise definition of their natural history and the best follow-up modality in accordance with the WHO and Tumour, Node, Metastasis classification. Regarding tumor staging, it was classified as T1cN0M0 according to the 2024 American Joint Committee on Cancer manual, corresponding to a clinical Stage IA3, with a favorable prognosis and a survival rate exceeding 90%[14].

However, long-term follow-up is necessary, as local or distant recurrence may occur years after the initial diagnosis[3,4,9]. The intensity of follow-up, or even the necessity for surveillance after surgical treatment, has not been fully evaluated. Recent recommendations advise intervals of 3-4 months during the first 3-5 years and extending surveillance for at least 20 years, including CT scans of the chest and upper abdomen with intravenous contrast[6,8].

We present a case of a pulmonary carcinoid tumor that recurred more than 15 years after resection of the primary tumor, presenting with hemoptysis. As described in the literature, bronchoscopy plays a central role in diagnosis and aids in planning the optimal treatment approach, not only by enabling biopsies for histological and immunohistochemical study but also by defining the anatomy before surgical resection. Surgical resection remains the curative treatment modality for patients with low- to intermediate-grade pulmonary carcinoid tumors. Following treatment, long-term follow-up is essential, given the potential for late recurrences as reported in the literature and observed in this case. The prognosis is generally favorable.

Conclusion

We report a case of pulmonary carcinoid tumor recurrence 15 years after resection, presenting with hemoptysis. Bronchoscopy was key for diagnosis, biopsy, and surgical planning. Surgery remains the curative treatment for low/intermediate-grade tumors. Long-term follow-up is essential due to potential late recurrences.

Acknowledgments

To all the nursing staff whose effort and dedication make the hospital's operation and quality patient care possible.

Funding

This research has not received any specific grant from agencies of the public, commercial, or for-profit sectors.

Conflicts of interest

The authors declare that they have no conflicts of interest.

Ethical considerations

Protection of humans and animals. The authors declare that no experiments involving humans or animals were conducted for this research.

Confidentiality, informed consent, and ethical approval. The authors have followed their institution's confidentiality protocols, obtained informed consent from patients, and received approval from the Ethics Committee. The SAGER guidelines were followed according to the nature of the study.

Declaration on the use of artificial intelligence. The authors declare that no generative artificial intelligence was used in the writing of this manuscript.

References

1. Armas-Zárate FJ, Valencia-Sánchez LD, Iñiguez-García MA. Institutional experience in Mexico in the surgical management of pulmonary carcinoid tumors. Neumol Cir Tórax. 2021;80:244-50.
2. Hamad AM, Rizzardi G, Marulli G, Rea F. Nodal recurrence of pulmonary carcinoid 30 years after primary resection. J Thorac Oncol. 2008;3:680-1.
3. Surani S, Tan J, Ahumada A, Surani SS, Sudhakaran S, Varon J. Delayed recurrence of atypical pulmonary carcinoid cluster: a rare occurrence. Case Rep Pulmonol. 2014;2014:620814.
4. Papaporfyriou A, Domayer J, Meilinger M, Firlinger I, Funk GC, Setinek U, et al. Bronchoscopic diagnosis and treatment of endobronchial carcinoid: case report and review of the literature. Eur Respir Rev. 2021;30:200115.
5. Lamarca A, Clouston H, Barriuso J, McNamara MG, Frizziero M, Mansoor W, et al. Follow-up recommendations after curative resection of well-differentiated neuroendocrine tumours: review of current evidence and clinical practice. J Clin Med. 2019;8:1630.
6. Lou F, Sarkaria I, Pietanza C, Travis W, Roh MS, Sica G, et al. Recurrence of pulmonary carcinoid tumors after resection: implications for postoperative surveillance. Ann Thorac Surg. 2013;96:1156-62.
7. Sun TY, Hendifar A, Padda SK. Lung neuroendocrine tumors: how does molecular profiling help? Curr Oncol Rep. 2022;24:819-24.
8. Marciello F, Mercier O, Ferolla P, Scoazec JY, Filosso PL, Chapelier A, et al. Natural history of localized and locally advanced atypical lung carcinoids after complete resection: a joined French-Italian retrospective multicenter study. Neuroendocrinology. 2018;106:264-73.
9. Prinzi N, Rossi RE, Proto C, Leuzzi G, Raimondi A, Torchio M, et al. Recent advances in the management of typical and atypical lung carcinoids. Clin Lung Cancer. 2021;22:161-9.
10. Reuling EM, Naves DD, Kortman PC, Broeckaert MA, Plaisier PW, Dickhoff C, et al. A multimodal biomarker predicts dissemination of bronchial carcinoid. Cancers (Basel). 2022;14:3234.
11. Yang H, Mei T. Sublobar resection versus lobectomy for patients with stage T1-2N0M0 pulmonary typical carcinoid tumours: a population-based propensity score matching analysis. Interact Cardiovasc Thorac Surg. 2022;35:ivac125.
12. Raz DJ, Nelson RA, Grannis FW, Kim JY. Natural history of typical pulmonary carcinoid tumors: a comparison of nonsurgical and surgical treatment. Chest. 2015;147:1111-7.
13. Mayne NR, Elser H, Lin BK, Raman V, Liou D, Li X, et al. The impact of extended delayed surgery for indolent lung cancer or part-solid ground glass nodules. Ann Thorac Surg. 2022;113:1827-34.
14. Detterbeck FC, Ostrowski M, Hoffmann H, Rami-Porta R, Osarogiagbon RU, Donnington J, et al. The international association for the study of lung cancer lung cancer staging project: proposals for revision of the classification of residual tumor after resection for the forthcoming (ninth) edition of the TNM classification of lung cancer. J Thorac Oncol. 2024;19:1052-72.