



Left atrial myxoma: the importance of cardiovascular imaging in the long-term follow-up of breast cancer survivors

Mixoma auricular izquierdo: importancia de la imagen cardiovascular en el seguimiento a largo plazo de las sobrevivientes de cáncer de mama

José Martín Alanís-Naranjo,* Cielmar Galeana-Abarca,† Marco Antonio Rentería-Galicia,§ Esbeidira Aranet Arroyo-Martínez,¶ María Azalea Loredo-Alanís,|| Thelma Rodríguez-López**

Keywords:

atrial myxoma, breast cancer, cardiovascular imaging, second primary tumor, oncologic follow-up, cardio-oncology.

Palabras clave:

mixoma auricular, cáncer de mama, imagen cardiovascular, segundo tumor primario, seguimiento oncológico, cardio-oncología.

ABSTRACT

The incidence of cancer patients with cardiac diseases requiring surgery is rising as the population ages, and early detection of cancer and the use of new therapies are increasing survival rates. Cardiac tumors, despite their rarity, are an integral part of the cardio-oncology practice and require diagnosis and treatment. In recent years, the incidence of cardiac tumors has risen due to advancements in multimodality imaging, which have become more accessible and widespread. The association between treated breast cancer and myxoma could be considered a mere coincidence, but a few documented cases exist. We report the case of a patient with a history of breast cancer who presented, upon follow-up, a left atrial cardiac mass on cardiovascular imaging and underwent immediate surgery. This case illustrates the importance of Cardio-Oncology Clinics during the follow-up of breast cancer survivors.

RESUMEN

La incidencia de pacientes con cáncer y enfermedades cardíacas que requieren cirugía aumenta a medida que la población envejece. La detección temprana del cáncer y el uso de nuevas terapias aumentan las tasas de supervivencia. Los tumores cardíacos, a pesar de su rareza, son una parte integral de la cardio-oncología, requiriendo diagnóstico y tratamiento. En los últimos años, la incidencia de tumores cardíacos ha aumentado debido a los avances en los estudios de imagen, que se han vuelto más accesibles. La asociación entre el cáncer de mama y el mixoma podría considerarse una mera coincidencia, pero hay pocos casos documentados. Presentamos el caso de una paciente con antecedente de cáncer de mama que, durante el seguimiento, presentó una masa cardíaca en la aurícula izquierda en estudios de imagen cardiovascular y, de inmediato, fue intervenida quirúrgicamente. Este caso ilustra la importancia de las clínicas de Cardio-Oncología durante el seguimiento de las sobrevivientes de cáncer de mama.

INTRODUCTION

Cancer patients with a cardiac disease requiring surgery are becoming more common as the population ages, and early cancer diagnosis and new therapies are increasing survival rates.¹ Despite the rarity of cardiac tumors, they are an integral part of the cardio-oncology practice and require diagnosis and treatment. According to their site of origin,

neoplastic tumors can be primary or secondary (metastatic).^{2,3} Most primary cardiac tumors are benign (up to 90%).⁴ These tumors have increased in incidence in the last ten years due to advances in multimodality imaging, which has become more accessible and widespread.^{3,4} The most common benign heart tumor is cardiac myxoma, a mobile, intracavitary, round, or oval-shaped tumor. When it is present in the left atrium, it is frequently attached to the fossa

* Internist, Cardiology Resident.

† Cardiologist, Cardiovascular Imaging Specialist.

§ Cardiovascular Surgeon.

¶ Cardiologist, Echocardiographer.

|| Pathologist.

** Cardiologist.

Hospital Regional 1° de Octubre ISSSTE, Mexico City, Mexico.

Received: 03/09/2023

Accepted: 06/08/2023

How to cite: Alanís-Naranjo JM, Galeana-Abarca C, Rentería-Galicia MA, Arroyo-Martínez EA, Loredo-Alanís MA, Rodríguez-López T. Left atrial myxoma: the importance of cardiovascular imaging in the long-term follow-up of breast cancer survivors. *Cardiovasc Metab Sci.* 2023; 34 (2): 66-71. <https://dx.doi.org/10.35366/111549>

ovalis by a stalk. The patient may be symptomatic (with obstructive, embolic, or constitutional symptoms) or asymptomatic, and the tumor may be found incidentally during routine cardiac imaging.^{2,5} The association between treated breast cancer and cardiac myxoma could be considered a mere coincidence, but a few documented cases exist.¹

We report the case of a patient with a history of breast cancer who presented, upon follow-up, a left atrial cardiac mass on cardiovascular imaging and underwent immediate surgery.

CASE PRESENTATION

A 59-year-old Mexican woman presented at the Cardio-Oncology (C-O) clinic was referred by her oncologist due to the finding of an intracardiac mass in her routine transthoracic echocardiogram (TTE). In 2013 she was diagnosed with invasive ductal breast carcinoma (Node + ER-/PR-/ERBB+). She received four cycles of neoadjuvant chemotherapy (TAC: docetaxel, doxorubicin, and cyclophosphamide). Then she continued with trastuzumab. The patient also underwent right breast mastectomy, axillary lymph node

resection and radiation therapy (total dose of 50 Gy). Because of the potentially cardiotoxic therapy received, periodic echocardiograms were performed. Since then, the patient has been asymptomatic and cancer-free, according to a recent oncological examination.

Eight years after the breast cancer diagnosis, a transthoracic echocardiogram revealed a heterogeneous, pedicled, mobile mass attached to the interatrial septum without obstruction to the flow across the mitral orifice, suggesting a left atrial myxoma. Because of these findings, the oncologist referred her to the C-O clinic.

In addition, her past medical history revealed metabolic syndrome and non-alcoholic fatty liver disease. Her family history was negative for cardiovascular disease and cancer. Physical examination revealed stable vital signs, no murmurs, clear lungs, and a previous mastectomy scar. Routine laboratory parameters were within normal limits. The electrocardiogram (*Figure 1*) and chest radiograph were unremarkable.

Transesophageal echocardiography revealed a 26 × 16 × 14 mm heterogeneous, lobulated, mobile mass in the left atrium, attached to the interatrial septum, and without obstruction to the flow across the mitral orifice (*Figure 2*).

Furthermore, a cardiac tomography showed a mass suggesting myxoma adjacent to the interatrial septum (*Figure 3*). There were no significant lesions in the coronary arteries, and the calcium score was 0 Agatston units.

Two months later, the patient underwent cardiac surgery, which revealed an atrial multilobular mass with hemorrhagic areas (*Figure 4*). A histopathological examination confirmed the diagnosis of cardiac myxoma (*Figure 5*). The patient remained symptom-free after the surgery and during follow-up.

DISCUSSION

Oncologists and hematologists refer cancer patients to the C-O clinic to assess chemotherapy or radiotherapy's potential deleterious cardiovascular effects. Echocardiography is the most commonly used imaging technique for assessing these effects and detecting lesions within the heart.⁶

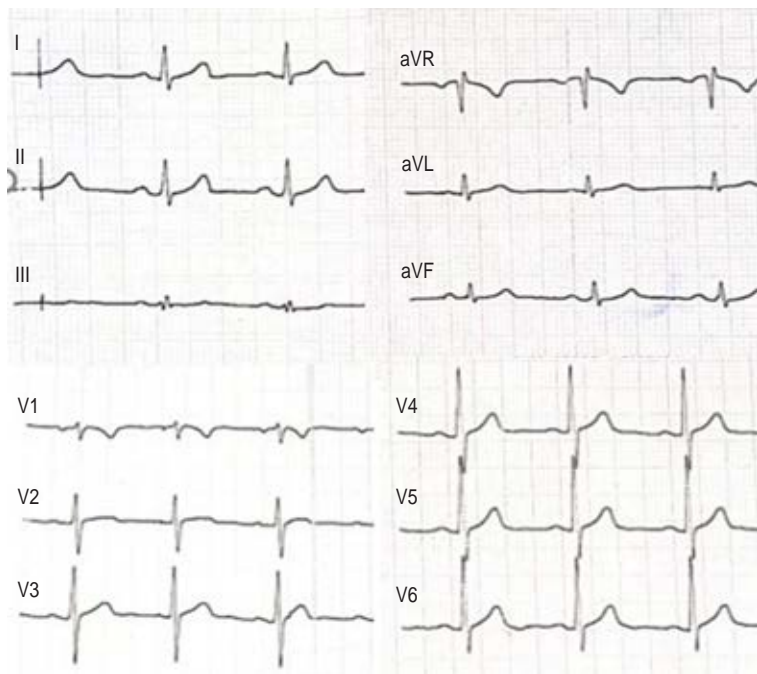


Figure 1: 12-lead electrocardiogram.

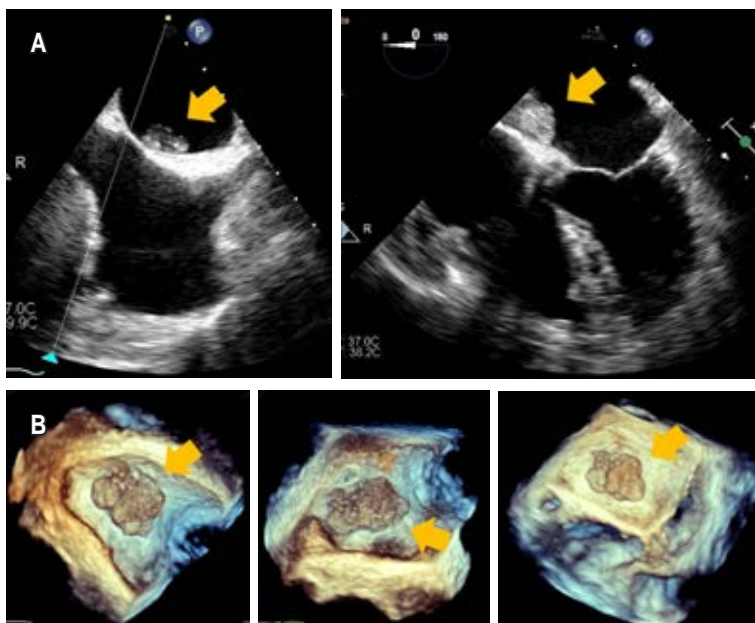


Figure 2: Transesophageal echocardiography. **A)** Heterogeneous, lobulated mass in the left atrium attached to the interatrial septum. **B)** Real-time 3-dimensional echocardiography (RT3DE) image.

A high risk of long-term cardiovascular toxicity is associated with specific cancer treatments, including anthracycline chemotherapy and radiotherapy. These effects may occur 5-10 years after the initial treatment, resulting in up to six times more common coronary artery disease and heart failure than in the general population. The long-term effect of trastuzumab is unknown beyond ten years. A cancer survivor with a very high risk of future cardiovascular disease fulfills the following characteristics: 1) Very high baseline cardiovascular toxicity risk pre-treatment, 2) Doxorubicin ≥ 400 mg/m², 3) Radiotherapy > 25 Gy, 4) RT > 15-25 Gy + Doxorubicin ≥ 100 mg/m². Therefore, TTE should be considered at years 1, 3, and 5 after completion of cardiotoxic cancer therapy and every five years after that in asymptomatic, very high-risk adult cancer survivors.⁷

The literature on cardiac surgery in patients previously treated for breast cancer remains limited.¹ A cardiac tumor diagnosed after breast

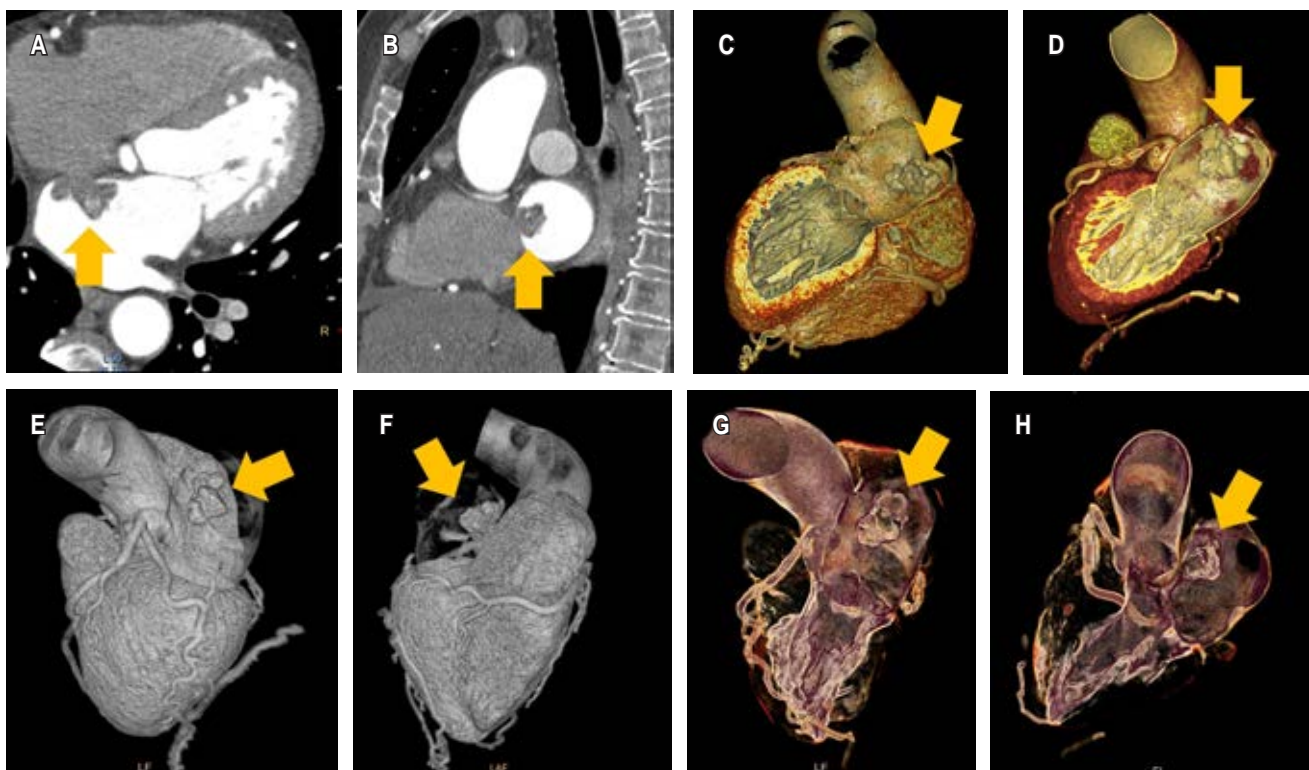


Figure 3: Cardiac computed tomography. **A)** and **B)** A mass in the left atrium on contrast-enhanced cardiac computed tomography (arrow). **C-H)** 3D reconstruction of the left atrial chamber with a mass (arrow).

cancer is a rare finding.⁸ The patient may be asymptomatic, and the lesion can be found incidentally, as in the present case. In imaging diagnoses of a cardiac mass, 47% corresponded to benign masses, including myxomas (20%); 64% of patients had a history of malignancy, which included breast cancer (5%).⁹

The authors of a case-control study of autopsy cases concluded that it is challenging to assess the correlation between cardiac myxoma and other neoplasms because it is a condition that is uncommon in life and sometimes goes undetected. As a result of diagnosis suspicion bias, the knowledge that the patient has been diagnosed with one disease (neoplasm) influences the intensity of their search for another condition.¹⁰ Some case reports, however, describe cardiac myxomas as a late complication in cancer survivors, hypothesizing that chemotherapy, radiotherapy, or immunosuppression¹¹⁻¹³ may have contributed to the tumor's growth.^{14,15}

Cardiac tumors are rare, and any space-occupying mass noted on cardiovascular imaging modalities should be considered as part of the differential diagnosis. Many types of tumors exist, including neoplastic and nonneoplastic lesions and masses. Neoplastic lesions are further classified into primary and secondary tumors (metastatic), all of which can be classified as benign or malignant.

Primary cardiac tumors may originate from the pericardium or the myocardium but are generally benign.^{2,4} Myxomas represent about 50% of all benign intracardiac tumors. They are predominant in the left atrium in 75% of cases, and in the right atrium, in 20% of cases. Bronchial, breast, melanoma, lymphoma, and leukemia are the most common cancers metastasizing to the heart.⁶

A cardiac tumor may be symptomatic or discovered incidentally during an evaluation for an unrelated physical condition or problem.² The tumor's size, location, and mobility determine symptoms and signs of myxoma. The tumor can produce symptoms by interfering with valvular function, resulting in left ventricle obstruction or congestive heart failure. Myxomas of the left atrium have a high incidence of brain embolisms; therefore, surgical treatment should be performed as soon as possible.^{4,5}

A Carney complex (CNC) is a rare hereditary genetic condition that can be inherited autosomally dominant or sporadic.⁶ This syndrome is caused in most patients by a defect of the *PRKAR1A* gene. It consists of multiple endocrine neoplasms and lentiginosis characterized by abnormal pigmentation of the skin and mucosa, myxomas primarily of the heart, skin, and breast, endocrine neoplasms, psammomatous melanotic schwannomas, breast ductal adenomas, osteochondromyxomas, and

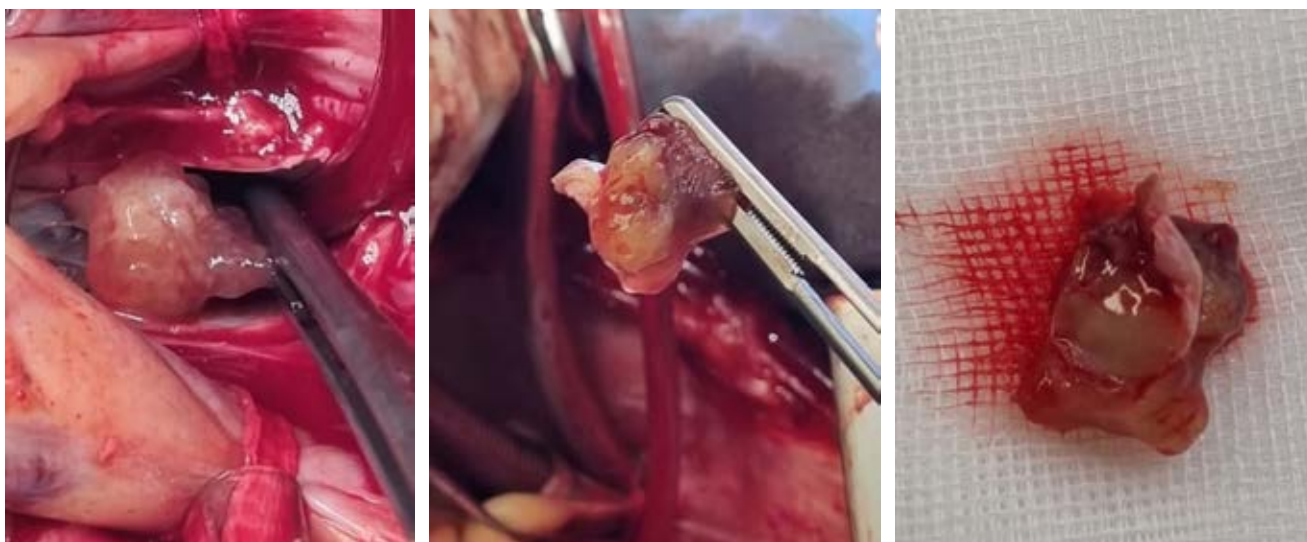


Figure 4: Intraoperative view of a left atrial multilobulated mass with hemorrhagic areas.

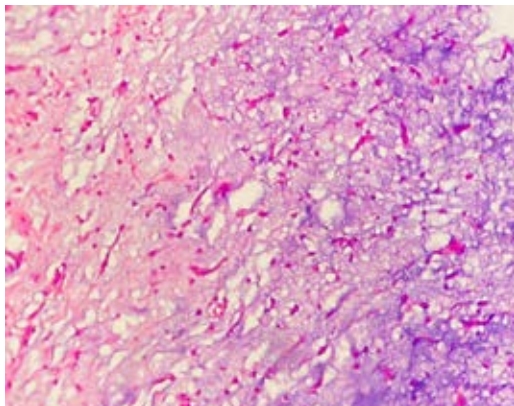


Figure 5: Photomicrograph showing spindle-shaped cells in a myxoid and hemosiderin background.

other non endocrine tumors.¹⁶ To exclude this possibility, measurement of endocrine hormone levels in patients with recurrent myxomas is necessary.^{4,6} In C-O clinics, cardiac myxomas are sometimes seen in breast cancer patients; however, the relationship between breast cancer and cardiac myxoma is seldom reported in patients without the Carney complex.⁶

Although obtaining a histopathologic specimen is the gold standard for diagnosis, multimodality imaging can often pinpoint the cause of a cardiac mass.^{2,17} Since two-dimensional transthoracic echocardiography is available and portable, it is often used first for diagnosis. It provides radiation-free and inexpensive images of tumors and minor, highly mobile masses, such as masses originating from valves, as well as assessing the size and location of tumors.² Paolisso et al. have recently identified some echocardiographic parameters that help predict malignancies and minimize diagnostic delay. It is important to recognize that contrast echocardiography is a valuable tool, but not all echocardiography laboratories have access to ultrasound-enhancing agents.¹⁸ However, in addition to inadequate acoustic windows, which are particularly problematic in obese and chronic pulmonary disease patients, these studies lack tissue characterization.²

The use of computed tomography (CT) for assessing cardiac masses has become increasingly popular, mainly when other imaging modalities are not diagnostic or contraindicated. As a result of electrocardiographic gating, motion-related

artifacts are minimized, and lesion margins and their relationship to tissue planes are more precisely delineated, which is especially beneficial when planning surgical procedures. However, radiation exposure, risk of contrast-induced nephropathy, and limited soft tissue and temporal resolution of CT scans are disadvantages compared to magnetic resonance imaging.²

A cardiac CT usually reveals a smooth or slightly villous intracavitary mass with low attenuation. Therefore, arterial phase contrast enhancement may not appear, and cine image reconstruction may be used to determine the lesion's mobility and attachment. Malignancy may be suspected, however, if local invasion, feeding vessels, hemorrhage, involvement of more than one cardiac chamber, and pericardial effusion are detected.²

Surgical resection is essential for a histological diagnosis and prevents significant complications such as embolization. It has a low mortality rate and a favorable long-term outcome. As approximately 10 to 15% of these tumors recur, generally near the original site, an echocardiogram should be performed annually for at least four years.^{2,5}

CONCLUSIONS

Asymptomatic patients with previously treated breast cancer may present a second primary tumor, as in this case: a cardiac myxoma. Furthermore, chemotherapy, radiotherapy, or immunosuppression may contribute to the development of a second primary tumor. Therefore, as part of the long-term survivorship care after breast cancer treatment, it is imperative to perform regular clinical examinations and cardiovascular imaging to establish an early diagnosis and treatment. This case illustrates the importance of Cardio-Oncology Clinics during the follow-up of breast cancer survivors. In addition, echocardiography provides a method of detecting small tumors in breast cancer survivors who are still asymptomatic.

REFERENCES

1. Narin C, Ege E, Onoglu R, Yazici M, Sarigül A. Surgery of left atrial myxoma as a second primary tumor in a patient previously treated for breast cancer. *Turk Gogus Kalp Dama*. 2012; 20 (1): 133-135.

2. Tyebally S, Chen D, Bhattacharyya S, Mughrabi A, Hussain Z, Manisty C et al. Cardiac tumors: JACC cardiooncology state-of-the-art review. *JACC CardioOncol.* 2020; 2 (2): 293-311.
 3. Maleszewski JJ, Bois MC, Bois JP, Young PM, Stulak JM, Klarich KW. Neoplasia and the heart: pathological review of effects with clinical and radiological correlation. *J Am Coll Cardiol.* 2018; 72 (2): 202-227.
 4. Mahavar RK, Arora D, Singh A, Mishra M. Recurrent cardiac myxoma: a case report. *Ann Card Anaesth.* 2021; 24 (4): 490-492.
 5. Pinede L, Duhaut P, Loire R. Clinical presentation of left atrial cardiac myxoma. A series of 112 consecutive cases. *Medicine (Baltimore).* 2001; 80 (3): 159-172.
 6. Alizadehasl A, Rahbar Z. Relationship between breast cancer and cardiac myxoma. *Int J Hematol Oncol Stem Cell Res.* 2021; 15 (2): 75-76.
 7. Lyon AR, López-Fernández T, Couch LS, Asteggiano R, Aznar MC, Bergler-Klein J et al. 2022 ESC Guidelines on cardio-oncology developed in collaboration with the European Hematology Association (EHA), the European Society for Therapeutic Radiology and Oncology (ESTRO) and the International Cardio-Oncology Society (IC-OS). *Eur Heart J.* 2022; 43 (41): 4229-4361.
 8. Cardinali Ré BA, Olgiati FJ, Ortiz LM, Mancini LF, Echazarreta D, Portis M. Metástasis cardíaca sintomática intracavitaria 12 años después del diagnóstico de cáncer de mama. *Rev Argent Cardiol.* 2018; 86 (2): 133-134.
 9. Mousavi N, Cheezum MK, Aghayev A, Padera R, Vita T, Steigner M et al. Assessment of cardiac masses by cardiac magnetic resonance imaging: histological correlation and clinical outcomes. *J Am Heart Assoc.* 2019; 8 (1): e007829.
 10. Suman VJ, Tazelaar HD, Bailey K, Melton J, Longaker MT, Stern R et al. Are patients with neoplasia at an increased risk for cardiac myxomas? *Hum Pathol.* 1993; 24 (9): 1008-1011.
 11. Singh P, Bajaj N, Agrawal G, Sharma A. Atrial myxoma-related to chronic immunosuppression: a case report. *J Saudi Heart Assoc.* 2012; 24 (4): 265-267.
 12. Hill G, Castellino S, Williams D. Cardiac myxoma after treatment for childhood neuroblastoma. *Pediatr Cardiol.* 2009; 30 (3): 340-342.
 13. Dadkhah R, Decoodt P. Cardiac myxoma: related to immunosuppression? A case report. *Acta Cardiol.* 2009; 64 (4): 571-573.
 14. Baronciani D, Angelucci E, Polchi P, Martinelli F, Mariotti E, Marzocchi A et al. An unusual marrow transplant complication: cardiac myxoma. *Bone Marrow Transplant.* 1998; 21 (8): 825-827.
 15. Reulen RC, Winter DL, Frobisher C, Lancashire ER, Stiller CA, Jenney ME et al. Long-term cause-specific mortality among survivors of childhood cancer. *JAMA.* 2010; 304 (2): 172-179.
 16. Kamilaris CDC, Faucez FR, Voutetakis A, Stratakis CA. Carney complex. *Exp Clin Endocrinol Diabetes.* 2019; 127 (2-03): 156-164.
 17. Liu F, Kong L, Chen L, Xiang W, Shen D. Concurrence of left atrial myxoma and breast cancer: underestimated value of echocardiography. *Authorea.* April 19, 2022. doi: 10.22541/au.165035357.70696853/v1.
 18. Paolisso P, Foà A, Bergamaschi L, Graziosi M, Rinaldi A, Magnani I et al. Echocardiographic markers in the diagnosis of cardiac masses. *J Am Soc Echocardiogr.* 2023; 36 (5): 464-473.e2.
- Funding:** no financial support was received for this study.
- Declaration of interests:** the authors declare no conflict of interest.
- Declaration of patient consent and data confidentiality:** the authors declare they have followed their workplace protocols for using patient data. Also, they certify that the patient has received sufficient information and has given written informed consent for his/her/their images and other clinical information to be reported in the journal, without names or initials, to protect the right to privacy.
- Correspondence:**
Thelma Rodríguez-López, M.D.
E-mail: thelma8rl@gmail.com