



# Trap-door thoracotomy as an ideal access route for internal cardiac massage and repair of subclavian vessels

## Toracotomía Trap-door como vía de acceso ideal para masaje cardíaco interno y reparación de vasos subclavios

Osvaldo Valdés-Dupeyrón,<sup>\*,‡</sup> Gino K Alvia-del Castillo,<sup>‡</sup> Lidia Espinales-Casanova,<sup>‡</sup> Javier Gonzáles-Robles,<sup>§</sup> Lisette Rodríguez-Marcos,<sup>¶</sup> Natacha Lois-Mendoza<sup>§</sup>

### Keywords:

subclavian artery lesions, Trap-door thoracotomy, subclavian artery revascularization, internal cardiac massage.

### Palabras clave:

lesiones de arteria subclavia, toracotomía Trap-door, revascularización de arteria subclavia, masaje cardíaco interno.

\* ORCID:

0000-0003-3419-2381

<sup>‡</sup> Hospital Regional «Dr. Verdi Cevallos Balda» Manabí, Ecuador.

<sup>§</sup> Department of Health Specialties of the Technical University of Manabí, Ecuador.

<sup>¶</sup> Department of Internal Medicine, Hospital de Especialidades de Portoviejo, Manabí, Ecuador.

Received:  
11/06/2022

Accepted:  
02/17/2023

### ABSTRACT

**Introduction:** subclavian vessel injuries remain rare and highly lethal. Patients with these types of injuries can present with neck and upper chest hematoma, hemorrhage, and signs of upper limb ischemia. Trap-door thoracotomy allows wide exposure of the thoracic cavity and base of the neck, providing rapid access to the heart, subclavian vessels, pulmonary ileus, and other anterior mediastinal structures. **Objective:** to describe the trap-door thoracotomy as the ideal approach for internal cardiac massage and subclavian vascular repair in hemodynamically unstable patients. **Cases presentation:** two patients with severe subclavian artery injuries are presented. They underwent emergency surgery using a trap-door thoracotomy, where bypass was performed from the ascending aorta to the left axillary artery with a polytetrafluoroethylene prosthesis in the first case and bypass from the left carotid artery to the left subclavian artery with an inverted saphenous vein in the second patient. **Conclusion:** the trap-door thoracotomy allows optimal access to the subclavian vessels and the heart if cardiopulmonary resuscitation is needed in critically ill patients.

### RESUMEN

**Introducción:** el traumatismo de vasos subclavios no es frecuente. Pueden presentarse en forma de hemorragia, hematoma en cuello y tórax superior, signos de hipoperfusión distal y choque. La toracotomía Trap-door permite una exposición amplia de la cavidad torácica y base del cuello que proporciona un acceso rápido a corazón, vasos subclavios, íleo pulmonar y demás estructura del mediastino anterior. **Objetivo:** describir la toracotomía de Trap-door como vía de acceso ideal para masaje cardíaco interno y reparación de vasos subclavios en pacientes graves. **Presentación de casos:** se presentan dos pacientes con lesiones severas de arterias subclavias que fueron intervenidos de forma emergente mediante toracotomía Trap-door, donde se realizó derivación de aorta ascendente a arteria axilar izquierdas con prótesis de politetrafluoroetileno en el primer caso y derivación de arteria carótida izquierda a arteria subclavia izquierdas con vena safena invertida en el segundo paciente. **Conclusión:** la toracotomía Trap-door permite el acceso óptimo de vasos subclavios y corazón en caso de necesitar realizar reanimación cardiopulmonar en pacientes graves.

### INTRODUCTION

Subclavian vein (SV) and subclavian artery (SA) injuries are relatively uncommon because they are vessels of short extension protected by osteoarticular structures of the

thoracic cavity. These injuries represent 1 to 9% of all vascular trauma cases, with 90% being caused by a penetrating mechanism secondary to stab and firearm injuries, and only 5% originate from the blunt trauma mechanism.<sup>1-3</sup>

**How to cite:** Valdés-Dupeyrón O, Alvia-del Castillo GK, Espinales-Casanova L, Gonzáles-Robles J, Rodríguez-Marcos L, Lois-Mendoza N. Trap-door thoracotomy as an ideal access route for internal cardiac massage and repair of subclavian vessels. Cardiovasc Metab Sci. 2023; 34 (2): 59-65. <https://dx.doi.org/10.35366/111548>

A subclavian vascular injury is suspected when trauma to the upper third of the chest wall located in the clavicle or supraclavicular fossa is associated with a decreased or absent pulse in the upper limb of the same name, hemorrhage, local hematoma, shock, and first rib fracture.<sup>1</sup> Concomitant involvement of the subclavian vein and subclavian artery occurs in 20% of cases, with brachial plexus injury occurring in a third of these traumas, increasing mortality from 10 to 35%.<sup>4</sup>

The unilateral anterior cervico-sternothoracotomy or «Trap-door» incision was first described in 1979 by Masaoka et al. It is performed in a supine position with the neck extended; it includes a high median sternotomy (MS) that communicates with an anterior incision at the level of the fourth intercostal space and another transverse incision at the base of the neck, dividing the infrahyoid muscles. The anterior flap is retracted as an open book to expose structures such as the pulmonary apex and hilum, subclavian vessels and brachial plexus.<sup>5</sup> It also offers access to other structures, such as the supra-aortic arteries, for proximal vascular control and heart if a more effective cardiopulmonary resuscitation is required to perform direct cardiac massage in patients with hemodynamic instability.

## CASES PRESENTATION

### Case 1

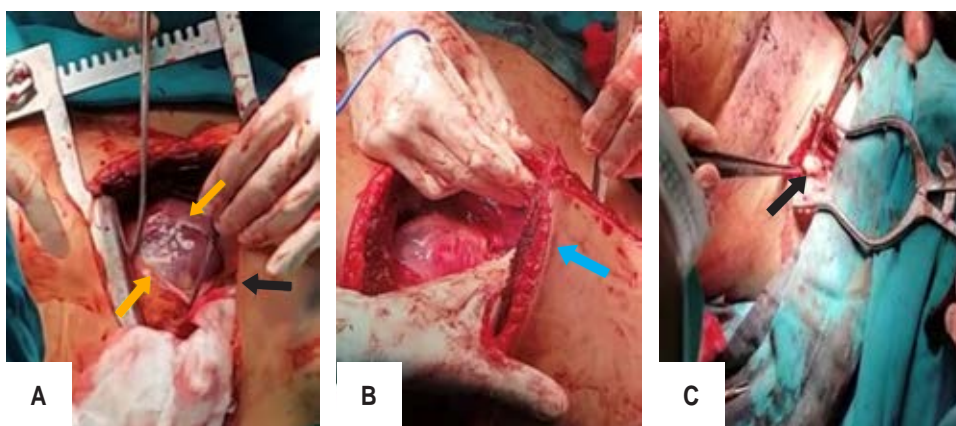
A 19-year-old male was brought by relatives with a penetrating injury caused by a gunshot

to the left shoulder. On physical examination, the patient was hypotensive (85/55 mmHg), with a giant hematoma in the shoulder and left hemithorax. The neurological examination revealed spastic paraplegia of the lower limbs, absence of left axillary, brachial, and radial pulses, homonymous hand coldness and cyanosis.

Chest X-ray revealed a bullet in the upper left hemithorax at the level of the fourth cervical vertebrae. Four units of red blood cells and two plasma were requested, and two grams of intravenous (IV) cefazolin were given. Emergency surgery is then indicated.

The patient suffered cardiac arrest during anesthetic induction. The left anterior thoracotomy was done through the fourth intercostal space. The ventricles appeared to be fluctuating on palpation when the pericardium was opened (*Figure 1A*), and the cardiac monitor demonstrated fine ventricular fibrillation. Manual cardiac massage and external electrical defibrillation with 250 Joules were performed until hemodynamic stabilization was achieved.

A large hematoma displacing the left lung is found, and the trap-door incision is completed with dislocation of the left sternoclavicular joint (*Figure 1B*), exposing the subclavian vessels and anterior mediastinum. After hematoma evacuation, a neurovascular injury with loss of the subclavian segments of the SV, SA, and brachial plexus was found. In addition, an aortic hematoma was found at the origin of the subclavian artery, making it impossible to perform the anastomosis to the descending aorta or left carotid (LC) artery.



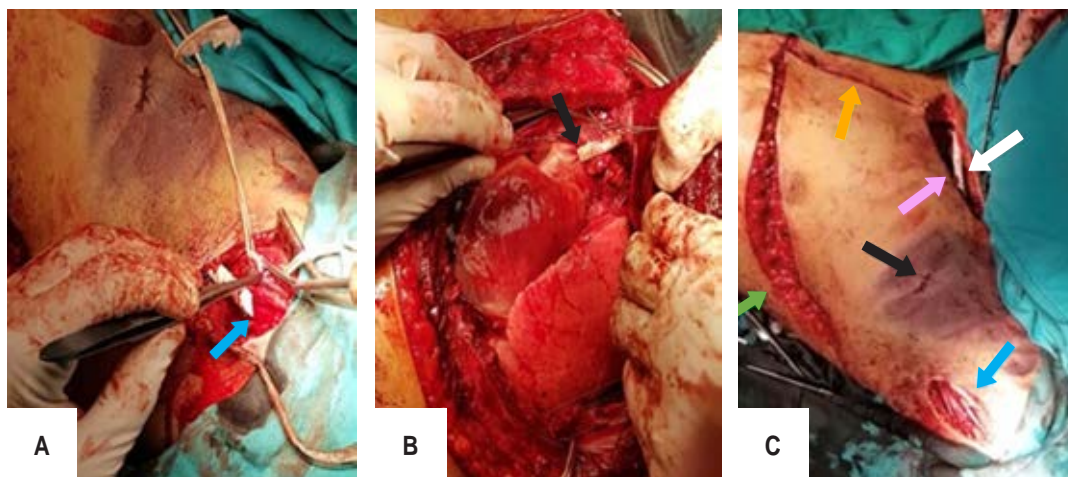
**Figure 1:**

Surgical procedure of case 1.

**A)** Opening of pericardium and exposure of the heart (yellow arrows), heart in ventricular fibrillation (black arrow).

**B)** Trap-door thoracotomy showing wide exposure of the mediastinum (blue arrow).

**C)** Left axillary artery dissection (black arrow).



**Figure 2:** Surgical procedure of case 1. **A)** Preparation for suturing the polytetrafluoroethylene prosthesis with the left axillary artery (blue arrow). **B)** Suture of polytetrafluoroethylene prosthesis and ascending aorta (black arrow). **C)** Trap-door thoracotomy with sternotomy closure (yellow arrow), anterolateral thoracotomy closure (green arrow), cervicotomy closure (pink arrow), extrathoracic course of the polytetrafluoroethylene prosthesis (white arrow) suture between the prosthesis and axillary artery (blue arrow), bullet entry hole (black arrow).

The bleeding source was controlled with ligation of subclavian vessels and dissection of the left axillary artery (Figure 1C). Partial clamping and bypass of the ascending aorta to the left axillary artery with a polytetrafluoroethylene (PTFE) prosthesis were performed (Figure 2A), (Figure 2B) and arterial flow restoration of the left upper limb was achieved. Hemostasis was checked, and the chest wall was closed, showing how the trap-door thoracotomy was left. The thorax outlet of the PTFE prosthesis is also observed (Figure 2C). Five minutes after the closure of the thoracic cavity, the patient presented ventricular fibrillation that resolved with defibrillation with 300 Joules.

The patient was transferred to the recovery room with inotropic support with a mean arterial pressure above 60 mmHg. Twelve hours after the surgical procedure, about 500 mL of blood was drained from the chest tube. Prolonged prothrombin time (PT) and activated partial thromboplastin time (aPTT) were found in coagulation tests. There was no evidence of residual hemothorax on chest X-ray images. Transfusion of two red blood cells and two plasma units were requested, and 500 mg of IV tranexamic acid every eight hours was indicated. There was a hemodynamic improvement within 48 hours postoperatively,

but extreme bradycardia persisted, and the possibility of referring the patient to a tertiary center for pacemaker placement was assessed. Epinephrine and atropine were added, but the heart rate did not improve. The patient died 72 hours after the surgical procedure.

### Case 2

An 18-year-old male was brought to the emergency department with blunt chest trauma and a left humerus fracture due to a motorcycle accident. On physical examination, the patient was hypotensive (90/57 mmHg), with a giant hematoma in the shoulder and left hemithorax. Left upper limb deformity due to humerus fracture was observed. There were signs of limb ischemia with absence of axillary and radial pulses.

Chest X-ray revealed a left humerus fracture, and a chest tomography showed a giant hematoma in the upper left hemithorax. Three red blood cells and two plasma units were requested, and two grams of IV cefazolin were given.

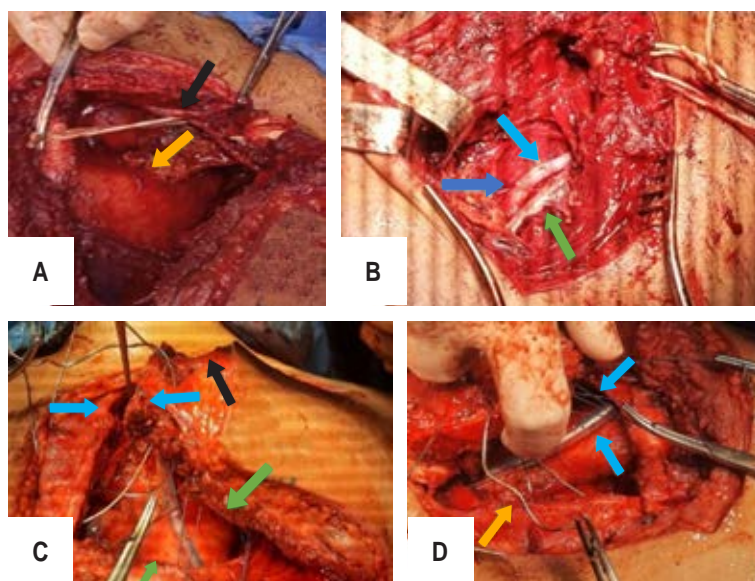
Emergency surgery was decided due to the patient's hemodynamic instability. General endotracheal anesthesia was indicated, and inotropic support with norepinephrine was started due to severe hypotension. Left anterior



thoracotomy was done through the fourth intercostal space, where the patient presented bradycardia and asystole, for which it was necessary to perform cardiac massage. After hemodynamic stabilization, a giant hematoma displacing the left lung is found. Vascular control of the mammary artery was performed, and the trap-door thoracotomy was completed with the dislocation of the left external clavicular joint to expose the subclavian vessels and the anterior mediastinum (Figure 3A).

A five centimeter SA laceration with lesions of the SV and brachial plexus were found.

Ligation of various bleeding sources and hematoma drainage was done. The intrathoracic LC artery was dissected, and a vascular bypass was performed from this artery to the distal end of the SA with the left greater saphenous vein (Figure 3B). A spontaneous arterial pulse and an arterial saturation greater than 95% of the upper left limb were observed. The SV was repaired with a 6/0 polypropylene suture.



**Figure 3:** Surgical procedure of case 2. **A)** Trap-door thoracotomy with control of the mammary artery (black arrow) and exposure of the heart and pericardium (yellow arrow). **B)** Anastomosis of the saphenous vein with the left subclavian artery, saphenous vein (light blue arrow), subclavian artery (blue arrow), subclavian vein (green arrow). **C)** Closing trap-door thoracotomy: sternotomy closure (blue arrows), anterolateral thoracotomy closure (green arrows), cervicotomy closure (black arrow). **D)** Thoracic cavity closure: sternum wires (yellow arrow), anterolateral thoracotomy closure with pericostal stitches (blue arrow), chest tube (light blue arrow).

Hemostasis was checked, and a chest tube was placed in the extrapleural space. The thoracotomy was closed with wires in the sternum and pericostal sutures on the thoracotomy (Figure 3C and D). A fasciotomy was performed due to humerus fracture in the proximal third of the arm.

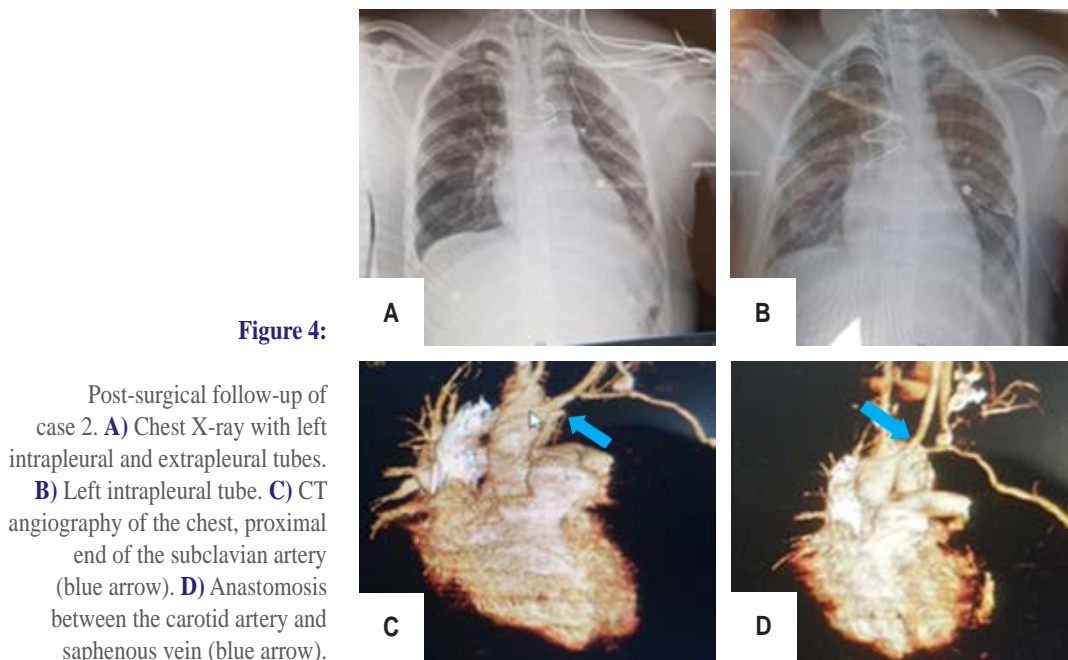
The patient was transferred to the recovery room with inotropic support of norepinephrine 8 mL/h, 1 gram of ceftriaxone IV every 8 hours and 500 mg of amikacin IV every 12 hours. The chest tube output was low. However, the X-ray showed moderate effusion, so repositioning a new chest tube in the intrapleural space was required (Figure 4A), which drained 700 mL of hematic fluid. The extrapleural chest tube was removed 28 hours later (Figure 4B).

Endotracheal extubation and intrapleural chest tube removal were performed within 72 hours postoperatively. The patient remained in the intensive care unit for 5 days and was then transferred to the ward, where was assessed by the neurosurgery and traumatology team for brachial plexus injury and humerus fracture, respectively. The patient was discharged from the hospital 15 days later. Since then, the patient has been in constant evaluation for 2 years, with a chest CT angiography that demonstrated graft patency (Figure 4C and D), although the brachial plexus injury has caused immobility and atrophy of the left shoulder and upper limb.

## DISCUSSION

The prognosis of trauma to the subclavian vessels depends on variables such as type of injury, affected vessel, degree of hemorrhage, and the time between injury and specific treatment. Demetriades et al. reported that 44% of his patients had isolated SV lesions, 39% had SA lesions, and 17% had combined artery and vein injuries.<sup>6</sup> Similar results were obtained by Lin et al, where the concomitant arterial and venous injuries were identified in 24 of the 54 patients of their study.<sup>4</sup> In the present study, the severity of the clinical picture indicated emergency surgical treatment in both patients.

Mortality from isolated SV lesions can be up to 80%, significantly higher than in the presence of arterial or combined subclavian injury.<sup>6</sup> Another study reported death in half of the



**Figure 4:**

Post-surgical follow-up of case 2. **A)** Chest X-ray with left intrapleural and extrapleural tubes. **B)** Left intrapleural tube. **C)** CT angiography of the chest, proximal end of the subclavian artery (blue arrow). **D)** Anastomosis between the carotid artery and saphenous vein (blue arrow).

patients with isolated SV lesions.<sup>3</sup> This could be associated with embolus or continuous venous bleeding. Some authors state that subclavian vessel injuries can sometimes be suspected clinically. Physical examination findings in SA lesions include the absence of pulses in upper extremities, brachial plexus palsy, audible murmur, supraclavicular hematoma, first rib fracture, and active bleeding.<sup>7,8</sup>

Primary identification of subclavian vascular injuries is often made intraoperatively due to the patient's hemodynamic instability, which precludes the possibility of obtaining imaging studies to corroborate the diagnosis. The patients in our report presented with giant hematomas of the upper left hemithorax, with a humerus fracture and a gunshot wound to the cervical spine, respectively. Computed tomography angiography provides the best diagnostic information to identify subclavian vascular injuries.<sup>9</sup>

The choice of surgical approach and incision type is one of the essential points to maintaining the patient's hemostasis; this depends on the injured side and the location of arterial and venous interruption. For some authors, the standard approach for left-sided trauma is anterolateral thoracotomy with a posterior

supraclavicular or infraclavicular incision, while right-sided injuries are generally treated with an MS with supraclavicular extension.<sup>10</sup> MS has also been successfully used to expose the left subclavian artery, which provides a wide operative field, and allows rapid vascular control.<sup>9</sup> In our cases, the classic «Trap-door» thoracotomy surgical technique was used, which has been associated with a higher incidence of severe postoperative bleeding and respiratory complications.<sup>3,11</sup>

The unilateral anterior cervical-sternothoracotomy incision or «Trap-door» incision was first described as a route of exposure for Pancoast tumors of the superior sulcus.<sup>5</sup> Since then, it has been used by thoracic surgeons as an approach to lung and upper mediastinum tumors. It also allows a better view of large vessels of the mediastinum and neck.<sup>12</sup> In our patients, this approach was considered an ideal technique, with the minor modification of performing sternoclavicular dislocation due to its rapid access to the subclavian vessels. It was also possible to expose the heart to perform internal cardiac massage and, at the same time, perform proximal vascular control to avoid profuse bleeding.

The lack of exposure of the medial and distal subclavian vessels is a disadvantage of

this approach. Supraclavicular or infraclavicular incisions expose the subclavian vessels but require the surgeon to perform external cardiac massage with the impossibility of proximal vascular control if profuse bleeding is presented. The trap-door technique should be considered an ideal approach to perform an effective cardiac massage to achieve cardiopulmonary resuscitation and control of SA lesions.

The endovascular approach as a treatment option for penetrating and blunt injuries of the subclavian vessels is relatively new. It includes polytetrafluoroethylene (PTFE)-coated endoprostheses with an expandable or self-expandable balloon.<sup>13,14</sup> This approach has been commonly used for pseudoaneurysms and left SA lesions due to its thoracic location compared to the right SA, which is extrathoracic.<sup>2</sup>

Most subclavian vascular injuries require significant open intervention for proper management.<sup>15</sup> Posner concluded that open anatomic repair is the most desirable option to prevent subclavian steal syndrome, claudication, or ischemia leading to limb amputation.<sup>16</sup>

Long-term morbidity is closely related to the presence of associated brachial plexus injuries.<sup>17</sup> In the study conducted by Graham, brachial plexus injuries were observed in 34% of the patients.<sup>18</sup> Unfortunately, cases of complete brachial plexus transection and secondary nerve repair may only return minimal functional improvement and leave the patient with permanent functional disability. In our study, brachial plexus injury was present in both patients.

## CONCLUSION

The trap-door thoracotomy allows optimal access to structures like the mediastinum, hilum and lung parenchyma. Its wide exposure provides proximal and distal vascular control of the great vessels, an essential requirement to achieve adequate repair of such structures. Its cervical extension offers exposure of the proximal and medial course of the subclavian vessels below the clavicle. It also helps to expose the heart and pericardium to perform an effective internal cardiac massage in critically ill patients.

## REFERENCES

1. Cabral JRB, da Silva KC, Signorini IA, Tenorio AAR, Nunes JVP, Teixeira AC et al. Artery and subclavian vein injury due to blunt trauma: a case report and literature review. *Panam J Trauma, Crit Care Emerg Surg.* 2022; 10 (3): 126-129. Available in: <https://www.pajttccs.com/doi/10.5005/jp-journals-10030-1350>
2. Smith AA, Gupta N. Subclavian artery trauma. [Internet] StatPearls Publishing, Treasure Island (FL); 2021. Available in: <http://europepmc.org/books/NBK554471>
3. Demetriades D, Chahwan S, Gomez H, Peng R, Velmahos G, Murray J et al. Penetrating injuries to the subclavian and axillary vessels. *J Am Coll Surg.* 1999; 188 (3): 290-295. Available in: <https://linkinghub.elsevier.com/retrieve/pii/S1072751598002890>
4. Lin PH, Koffron AJ, Guske PJ, Lujan HJ, Heilizer TJ, Yario RF et al. Penetrating injuries of the subclavian artery. *Am J Surg.* 2003; 185 (6): 580-584. Available in: <https://linkinghub.elsevier.com/retrieve/pii/S0002961003000709>
5. Masaoka A, Ito Y, Yasumitsu T. Anterior approach for tumor of the superior sulcus. *J Thorac Cardiovasc Surg.* 1979; 78: 413-415.
6. Demetriades D, Rabinowitz B, Pezikis A, Franklin J, Palexas G. Subclavian vascular injuries. *Br J Surg.* 2005; 74 (11): 1001-1003. Available in: <https://academic.oup.com/bjs/article/74/11/1001/6186234>
7. Tran KT. Life-threatening left subclavian arterial rupture following blunt thoracic trauma: a case report. *June 2019.* doi: 10.25373/ctsnet.8307314.
8. Fares A, Shaikh N. Subclavian artery injury following blunt trauma: a report of three cases. *J Emerg Med Trauma Acute Care.* 2012; 2012 (1). Available in: <https://www.qscience.com/content/journals/10.5339/jemtac.2012.3>
9. Tennyson C, Karunaratne D, McLaughlin KE, Hasan R, Grant SW. Delayed subclavian artery rupture secondary to a traumatic first rib fracture. *Trauma Case Reports.* 2018; 16: 1-3. Available in: <https://linkinghub.elsevier.com/retrieve/pii/S2352644018300165>
10. Tanmit P, Angkathip P, Teeratakulpisarn P, Thanapaisal C, Wongkonkitsin N, Prasertcharoensuk S et al. Treatment outcome of traumatic subclavian artery injuries. *Vasc Health Risk Manag.* 2021; 17: 481-487. Available in: <https://www.dovepress.com/treatment-outcome-of-traumatic-subclavian-artery-injuries-peer-reviewed-fulltext-article-VHRM>
11. Fabregues OA, Zarain OL, Perez-Diaz D, Turégano FF. Trap-door incision for penetrating thoracic trauma: an obsolete approach? *Case Rep Surg.* 2014; 2014: 1-3. Available in: <http://www.hindawi.com/journals/cris/2014/798242/>
12. Christison-Lagay ER, Darcy DG, Stanelle EJ, Dasilva S, Avila E, La Quaglia MP. "Trap-door" and "clamshell" surgical approaches for the management of pediatric tumors of the cervicothoracic junction and mediastinum. *J Pediatr Surg.* 2014; 49 (1): 172-176; discussion 176-177. doi: 10.1016/j.jpedsurg.2013.09.049.
13. Elkbuli A, Shaikh S, McKenney M, Boneva D. Successful management with endovascular stent graft

- repair following gunshot wound to the subclavian artery: case report and literature review. *Int J Surg Case Rep.* 2019; 64: 75-79. Available in: <https://linkinghub.elsevier.com/retrieve/pii/S2210261219305395>
14. Biagioni RB, Burihan MC, Nasser F, Biagioni LC, Ingrund JC. Endovascular treatment of penetrating arterial trauma with stent grafts. *Vasa.* 2018; 47 (2): 125-130. Available in: <https://econtent.hogrefe.com/doi/10.1024/0301-1526/a000672>
  15. Elkbuli A, Kinslow K, Dowd B, McKenney M, Boneva D, Whitehead J. Subclavian artery injury secondary to blunt trauma successfully managed by median sternotomy with supraclavicular extension: a case report and literature review. *Ann Med Surg.* 2020; 54: 16-21. Available in: <https://linkinghub.elsevier.com/retrieve/pii/S2049080120300406>
  16. Posner MP, Deitrick J, McGrath P, Mendez-Picon G, Sobel M, Lower RR, Lee HM. Nonpenetrating vascular injury to the subclavian artery. *J Vasc Surg.* 1988; 8 (5): 611-617. Available in: <https://pubmed.ncbi.nlm.nih.gov/3054174/>
  17. Sciarretta JD, Asensio JA, Vu T, Mazzini FN, Chandler J, Herreras F et al. Subclavian vessel injuries: difficult anatomy and difficult territory. *Eur J Trauma Emerg Surg.* 2011; 37 (5): 439-449. Available in: <http://link.springer.com/10.1007/s00068-011-0133-2>
  18. Graham JM, Mattox KL, Feliciano DV, DeBakey ME. Vascular injuries of the axilla. *Ann Surg.* 1982; 195 (2): 232-238. Available in: <http://journals.lww.com/00000658-198202000-00020>

**Funding/support:** no financial support was received for this study.

**Conflict of interest:** the authors declare no conflict of interest.

**Correspondence:**

**Oswaldo Valdés-Dupeyrón**

**E-mail:** [osvaldovaldesdupeyron@gmail.com](mailto:osvaldovaldesdupeyron@gmail.com)