



## Acute myocarditis after administering the BNT162b2 (Pfizer-BioNTech) vaccine against COVID-19 in an adolescent patient

### *Miocarditis aguda tras la administración de la vacuna BNT162b2 (Pfizer-BioNTech) contra COVID-19 en un paciente adolescente*

Samuel Isai López-Martínez,\* Edgar Nicéforo Monroy-Sánchez,† Rodrigo Alejandro Solís-Reyna,§ Monica Vanesa Pasos-Caamal,¶ Javier Jesús Onofre-Castillo||

#### Keywords:

COVID-19, SARS-CoV-2, vaccine, magnetic resonance, myocarditis, Pfizer-BioNTech.

#### Palabras clave:

COVID-19, SARS-CoV-2, vacuna, resonancia magnética, miocarditis, Pfizer-BioNTech.

#### ABSTRACT

Myocarditis is a multifactorial inflammatory condition of the myocardium. Recently myocarditis has been recognized as an adverse event in patients vaccinated against COVID-19 with Pfizer-BioNTech and Moderna (mRNA vaccines), mainly in adolescents and young adults. Cardiac magnetic resonance (CMR) allows the characterization of myocardial tissue and cardiac function and has become the non-invasive diagnostic gold standard in patients with suspected acute myocarditis. The authors present a 16-year-old male case with stabbing chest pain after the second dose of immunization against SARS-CoV-2 with the BNT162B2 (Pfizer-BioNTech) vaccine. The electrocardiogram (ECG) showed disclosed ST-segment elevation, and increased myocardial injury markers were also observed. Angio tomography (AngioCT) showed subtle signs of myocardial hypoperfusion and left ventricular dysfunction. Gadolinium CMR was performed, identifying global hypokinesis of the left ventricle (LV), myocardial edema hyperemia and late gadolinium enhancement (LGE) as evidence of myocardial injury, and markers of non-ischemic intramyocardial inflammatory lesion. Having excluded other etiologies, this presentation of acute myocarditis is proposed to be an adverse reaction associated with the BNT162b2 vaccine against COVID-19. The long-term risks of the COVID-19 vaccine in children, adolescents and young adults are still unknown, and further investigation will be needed.

#### RESUMEN

La miocarditis es una condición inflamatoria multifactorial del miocardio. La miocarditis ha sido reconocida recientemente como un evento adverso, en pacientes vacunados contra COVID-19 con Pfizer-BioNTech y Moderna (vacunas de ARNm), principalmente en adolescentes y adultos jóvenes. La resonancia magnética cardíaca (RMC) permite caracterizar el tejido miocárdico y la función cardíaca y se ha convertido en el estándar de oro no-invasivo en pacientes con sospecha de miocarditis aguda. Los autores presentan a un paciente masculino de 16 años con dolor torácico punzante tras la segunda dosis de inmunización contra el SARS-CoV-2 con la vacuna BNT162B2 (Pfizer-BioNTech). El electrocardiograma (ECG) mostró elevación del segmento ST y aumento de los biomarcadores de lesión miocárdica. La angiotomografía (AngioTC) mostró signos sutiles de hipoperfusión miocárdica y disfunción ventricular izquierda. Se realizó RMC con gadolinio, identificando hipocinesia global del ventrículo izquierdo (VI), hiperemia por edema miocárdico y realce tardío de gadolinio (RTG) como evidencia de lesión miocárdica y marcadores de lesión inflamatoria intramiocárdica no-isquémica. Habiendo excluido otras etiologías, se propone que esta presentación de miocarditis aguda sea una reacción adversa asociada a la vacuna BNT162b2 contra COVID-19. Los riesgos a largo plazo de la vacuna contra la COVID-19 en niños, adolescentes y adultos jóvenes aún se desconocen, por lo que será necesario seguir investigando.

\* Radiology resident. Christus Muguerza Hospital Alta Especialidad, Monterrey, Nuevo León, México.  
† Cardiovascular imaging cardiologist. Christus Muguerza Hospital Alta Especialidad, Monterrey, Nuevo León, México.  
§ Medical internship. Christus Muguerza Hospital Alta Especialidad, Monterrey, Nuevo León, México.

**How to cite:** López-Martínez SI, Monroy-Sánchez EN, Solís-Reyna RA, Pasos-Caamal MV, Onofre-Castillo JJ. Acute myocarditis after administering the BNT162b2 (Pfizer-BioNTech) vaccine against COVID-19 in an adolescent patient. Cardiovasc Metab Sci. 2022; 33 (3): 118-122. <https://dx.doi.org/10.35366/107625>



† Medical internship.  
Hospital Regional  
de Mérida «Elvia  
Carrillo Puerto»,  
ISSSTE, Mérida,  
Yucatán, México.  
‡ Radiologist-in-  
Chief. Christus  
Muguerza Hospital  
Alta Especialidad.

Received:  
02/07/2022  
Accepted:  
07/26/2022

## INTRODUCTION

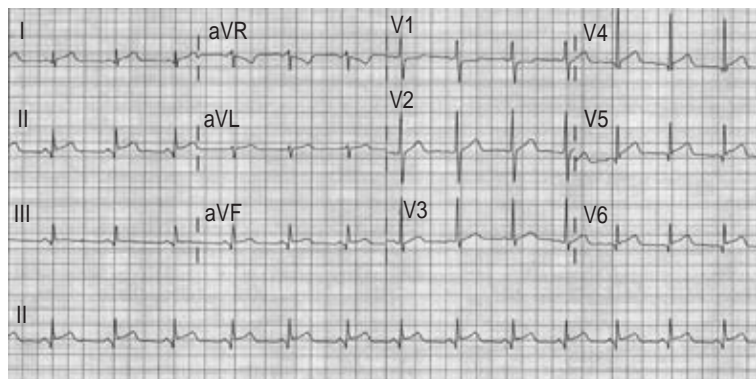
Myocarditis is an inflammatory disease of the myocardium diagnosed by histological, immunological and immunohistochemical criteria. The World Health Organization and the working group of the Society and International Federation of Cardiology on the definition and classification of cardiomyopathies histologically define myocarditis as the presence of inflammatory infiltrates in the myocardium with degeneration and necrosis of myocytes of non-ischemic origin (Dallas criteria). Regarding immunohistochemical criteria the diagnosis would be made in the presence in the myocardium of  $\geq 14$  leukocytes/mm<sup>2</sup>, including up to 4 monocytes/mm<sup>2</sup> and  $\geq 7$  CD3-positive T lymphocytes/mm<sup>2</sup>. The working group defines inflammatory dilated cardiomyopathy (DCM) as myocarditis associated with cardiac dysfunction.<sup>1,2</sup> Myocardial damage leads to humoral and cellular response initiated in an attempt to eliminate the causal agent accompanied by edema, necrosis and regional or global alterations of myocardial contractility. Complete recovery of tissue and function can be seen in uncomplicated cases, whereas in severe cases an autoimmune reaction is triggered in the heart with myocardial necrosis and the release of antigens that perpetuate the damage. Progression to DCM occurs predominantly in patients with persistent inflammation who cannot eliminate the causal agent or develop antibodies against myocardial structures.<sup>3-6</sup>

Myocarditis has several different etiologies as infections, immune disorders, toxic agents,

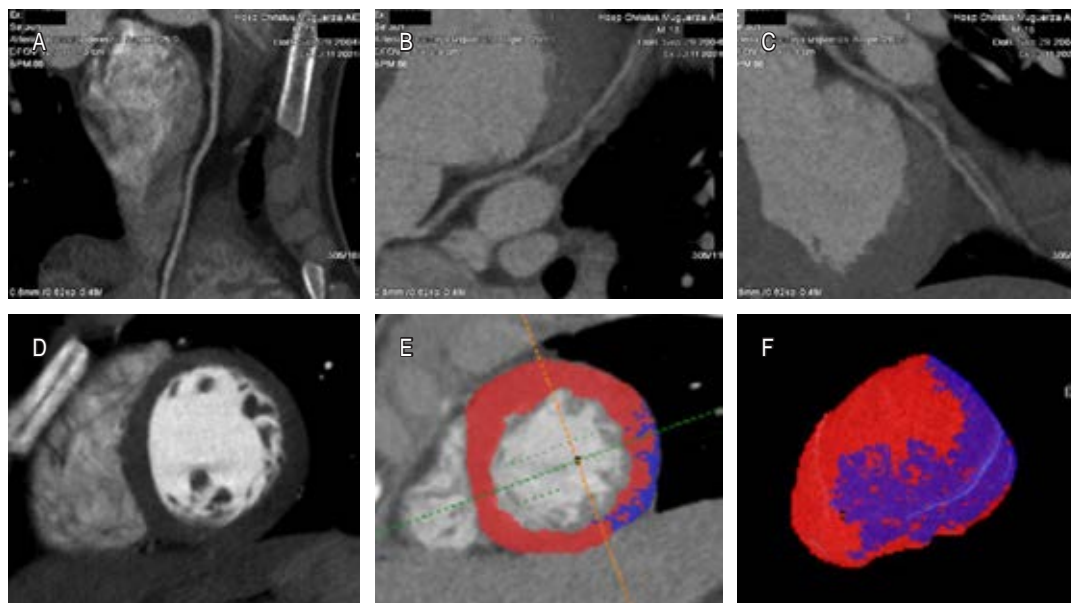
etc. The most common viruses implicated in myocarditis are coxsackie B, adenovirus, hepatitis C, cytomegalovirus (CMV), echovirus, influenza, Epstein-Barr, parvovirus B19 and herpes virus. In the past few years, myocarditis has been recognized as a complication of severe COVID-19.<sup>2,4-6</sup> With the emerging use of the vaccine against COVID-19, post-vaccination-related acute myocarditis has been described.<sup>7-9</sup> COVID-19 vaccine related myocarditis diagnosis is based on an appropriate clinical data scenario, cardiac biomarkers, and imaging studies, including echocardiogram, AngioCT and CMR. CMR allows the characterization of tissue and cardiac function and has become the non-invasive diagnostic gold standard in patients with suspected acute myocarditis.<sup>10-12</sup>

## CASE PRESENTATION

The authors describe a 16-year-old male case with no past relevant medical history. The patient had full immunization against SARS-CoV-2 with the BNT162B2 (Pfizer-BioNTech) vaccine; the second dose was administered in May 2021. On July 7, 2021, the patient complained of stabbing chest pain and was evaluated at another institution. A transthoracic echocardiogram was performed with global and segmental hypokinesia of the posteroinferior and mid-apical region. Left ventricular ejection fraction (LVEF) was normal with no pericardial effusion. Anti-inflammatory treatment was prescribed. The patient was admitted to our institution on July 10, 2021, with an improvement in symptoms. On emergency physical examination, vital signs were normal. An electrocardiogram (ECG) showed sinus rhythm, 81 bpm, normal QRS and elevation of ST-segment (*Figure 1*). Chest-X Ray was normal. Blood tests revealed elevated myocardial injury biomarkers: ultrasensitive troponin T 2123 ng/L, creatine phosphokinase (CPK) 1297 IU/L, MB fraction of creatine phosphokinase (CPK-MB) 105 ng/mL, brain natriuretic peptide (proBNP) 493 pg/mL, D-dimer 618 ng/mL and C-reactive protein (CRP) of 14.97 mg/L. Coronary AngioCT was performed on July 11, 2021 with normal coronary arteries (*Figure 2A*). Slightly depressed left ventricular function with an ejection fraction of 47%, hypokinesia in non-



**Figure 1:** The ECG showed elevation of the ST-segment.



**Figure 2:** AngioCT with normal coronary arteries (A, B and C). Inferolateral hypodensity of myocardial wall (D) with hyperperfusion demonstrated after the post-process (E and F).

contiguous segments and lower attenuation of inferolateral myocardium were observed (Figure 2B and 2C). Post-process was made, and inferolateral wall hypoperfusion was demonstrated (Figure 2D to 2F).

CMR (Optima™ MR450W GEM 1.5T, GE Healthcare, Chicago, IL, USA) with endovenous gadobutrol (Gadovist®) (0.1 mmol / kg) was performed to identify global hypokinesis of the LV with LVEF of 41%. The STIR sequence showed areas of increased myocardial signal intensity in the inferolateral, basal and medial, lateral-apical and anterior-apical segments, compatible with edema (Figure 3A). After administration of gadolinium, areas of the myocardium with early enhancement were identified in the anteroseptal basal, inferolateral basal, inferolateral medial, lateral-apical and anterior-apical segments compatible with hyperemia (Figure 3B). Non-ischemic pattern LGE in lateral subepicardial and midwall at the apical septal level was observed (Figure 3C). Pericardium was normal. The findings represent markers of non-ischemic intramyocardial inflammatory lesion. The viral serology was negative (Cytomegalovirus, Epstein Barr, Coxsackie A and B, Echovirus, as well as anti-Salmonella typhi and paratyphi, Brucella and

Proteus). Due to the temporal relationship between vaccination and the development of signs and symptoms and having excluded other etiologies, this presentation of acute myocarditis is proposed to be an adverse reaction associated with the BNT162b2 vaccine against COVID-19. Beta-blocker, antihypertensive and anti-inflammatory treatment was prescribed. Due to the low-risk profile and favorable clinical evolution, an endomyocardial biopsy was not considered. The patient was discharged after five days without complications.

## DISCUSSION

Acute myocarditis has been recognized as an adverse event in patients vaccinated with Pfizer-BioNTech and Moderna (mRNA vaccines), mainly in adolescents and young adults. The Vaccine Adverse Event Reporting System (VAERS) had received 1,783 reports of myocarditis or pericarditis in the 12 and 29-year-old age group who received COVID-19 vaccines (November 4, 2021). Most cases in adolescents or young men after the second dose. The Centers for Disease Control and Prevention (CDC) and the Food and Drug Administration (FDA) confirmed 1,031 reports

of myocarditis or pericarditis. The Clalit Health Services database in Israel reports its highest incidence in male patients aged 16-29 years, up to 10.69 cases per 100,000 persons.<sup>7-9,13</sup>

The Pfizer-BioNTech vaccine has been shown to be 94% to 95% effective in preventing COVID-19 infection in the 16- to 55-year-old population and 100% effective in the 12-to-15-year age group. To date, the FDA has authorized its emergent use in the population aged 5 to 15 years and full approval in 16 years and older. The long-term risks are still unknown. The adverse reactions described in different vaccines within the cardiovascular sphere are isolated cases of the acute coronary syndrome, atrial fibrillation, ventricular extrasystole and cardiac arrest.<sup>14-17</sup>

Under the clinical suspicion of acute myocarditis, the diagnostic approach includes a 12-lead ECG (changes in ST-segment, T wave, Q waves, AV and bundle branch block, arrhythmias; limited use), biomarkers of cardiac injury (high sensitivity, although low specificity), transthoracic echocardiography, CMR and endomyocardial biopsy in selected cases. Echocardiography helps to rule out other entities and to monitor changes in cavity size, myocardial thickness, ventricular function and pericardial effusion. Some alterations such as global ventricular dysfunction, alterations in segmental contractility or diastolic dysfunction

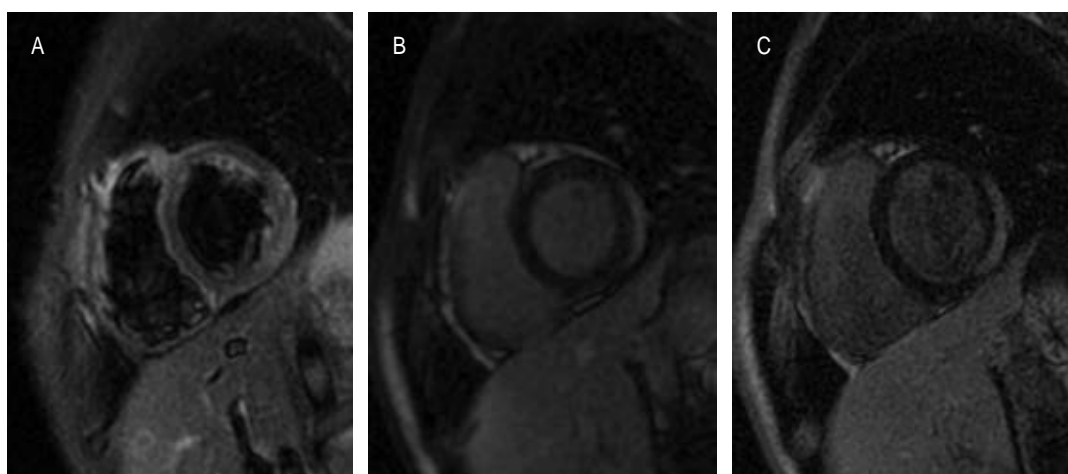
are nonspecific. Myocardial deformation analysis by speckle tracking shows greater sensitivity for the detection of myocardial damage in patients with preserved LVEF and its prognostic evaluation.<sup>18,19</sup>

In patients who undergo AngioCT, hypodensity of the myocardium has been described. Post-process demonstrated hypoperfusion could be an indicator of edema, although further investigation on this topic is needed.<sup>20</sup>

CMR modified Lake Louise criteria (sensitivity 87.5%, specificity 96.2%) consists in identifying three diagnostic targets for myocarditis: edema, hyperemia and LGE. A positive case is defined as the presence of at least one T2 criterion (sensitivity 84.6%, specificity 88.5, precision 86.2%) with at least one additional T1 criterion (sensitivity 90.0%, specificity 76.9%, accuracy 84.8%). Pericardial effusion and LV wall abnormality are considered supporting criteria.<sup>10-12</sup>

## CONCLUSIONS

Acute myocarditis is a multifactorial inflammatory condition of the heart that can be assessed non-invasively by using CMR-modified Lake Louise criteria. Post COVID-19 vaccine related myocarditis is a rare adverse event most likely seen in children, adolescents and young



**Figure 3:** The CMR short axis STIR sequence showed increased myocardium signal (edema) in the inferolateral, basal and medial, lateral-apical, and anterior-apical segments (A). Early gadolinium enhancement (B) is compatible with hyperemia. Non-ischemic pattern late enhancement in lateral subepicardial and midwall is shown (C).



male adults. However, the authors believe that future research is needed to provide more evidence that can establish recommendations for immunization based on the well-known benefits of SARS-CoV-2 vaccination and better identification of patients with increased vaccine-related risk of adverse effects.

**Acknowledgement.** Radiology Department of Christus Muguerza Hospital Alta Especialidad.

#### REFERENCES

- Richardson P, McKenna W, Bristow M, Maisch B, Mautner B, O'Connell J et al. Report of the 1995 World Health Organization/International Society and Federation of Cardiology Task Force on the Definition and Classification of cardiomyopathies. *Circulation*. 1996 Mar 1; 93 (5): 841-842.
- Aretz HT. Myocarditis: the Dallas criteria. *Hum Pathol*. 1987 Jun; 18 (6): 619-624.
- Lampejo T, Durkin SM, Bhatt N, Guttman O. Acute myocarditis: aetiology, diagnosis and management. *Clin Med (Lond)*. 2021 Sep 1; 21 (5): e505-510.
- Sally AH. Viral Myocarditis and Dilated Cardiomyopathy: Etiology and Pathogenesis. *Curr Pharm Des*. 2016 Jan 31; 22 (4): 408-426.
- Gravanis MB, Sternby NH. Incidence of myocarditis. A 10-year autopsy study from Malmö, Sweden. *Arch Pathol Lab Med*. 1991 Apr; 115 (4): 390-392.
- Daniels PR, Berry GJ, Tazelaar HD, Cooper LT. Giant cell myocarditis as a manifestation of drug hypersensitivity. *Cardiovasc Pathol*. 2000 Oct; 9 (5): 287-291.
- Witberg C, Barda N, Hoss S, Richter I, Wiessman M, Aviv Y et al. Myocarditis after Covid-19 Vaccination in a Large Health Care Organization. *N Engl J Med*. 2021 Dec 2; 385 (23): 2132-2139.
- Dionne A, Sperotto F, Chamberlain S, Baker AL, Powell AJ, Prakash A et al. Association of Myocarditis With BNT162b2 Messenger RNA COVID-19 Vaccine in a Case Series of Children. *JAMA Cardiol*. 2021; E1-5.
- Albert E, Aurigemma G, Saucedo J, Gerson DS. Myocarditis following COVID-19 vaccination. *Radiol Case Rep*. 2021 Aug; 16 (8): 2142-5.
- Mas-Stachurska A, Sitges M, Prat-Gonzalez S. Diagnóstico de la miocarditis. Papel de las técnicas de imagen. *CardiCore*. 2012 Oct; 47 (4): 143-146.
- Liguori C, Farina D, Vaccher F, Ferrandino G, Bellini D, Carbone I. Myocarditis: imaging up to date. *Radiol Med*. 2020 Nov; 125 (11): 1124-1134.
- Luetkens JA, Faron A, Isaak A, Dabir D, Kuetting D, Feisst A, et al. Comparison of Original and 2018 Lake Louise Criteria for Diagnosis of Acute Myocarditis: Results of a Validation Cohort. *Radiology: Cardiothoracic Imaging*. 2019 Jul 25; 1 (3): 1-8.
- CDC. COVID-19 Vaccination. Centers for Disease Control and Prevention. 2020. Available: <https://www.cdc.gov/vaccines/covid-19/covid19-vaccination-guidance.html>
- Caforio ALP. Receipt of mRNA Vaccine against Covid-19 and Myocarditis. *N Engl J Med*. 2021 Dec 2; 385 (23): 2189-90.
- Marshall M, Ferguson ID, Lewis P, Jaggi P, Gagliardo C, Collins JS, et al. Symptomatic Acute Myocarditis in 7 Adolescents After Pfizer-BioNTech COVID-19 Vaccination. *PEDIATRICS*. 2021; 148 (3): 1-11.
- CDC. COVID-19 Vaccines for Children & Teens. Centers for Disease Control and Prevention. 2021. Available: <https://www.cdc.gov/coronavirus/2019-ncov/vaccines/recommendations/children-teens.html>
- Bautista García J, Peña Ortega P, Bonilla Fernández JA, Cárdenes León A, Ramírez Burgos L, Caballero Dorta E. Miocarditis aguda tras administración de vacuna BNT162b2 contra la COVID-19. *Rev Esp Cardiol*. 2021 Sep 1; 74 (9): 812-814.
- Friedrich MG, Sechtem U, Schulz-Menger J, Holmvang G, Alakija P, Cooper LT, et al. Cardiovascular magnetic resonance in myocarditis: A JACC White Paper. *J Am Coll Cardiol*. 2009 Apr 28; 53 (17): 1475-1487.
- Caforio ALP, Pankuweit S, Arbustini E, Basso C, Gimeno-Blanes J, Felix SB, et al. Current state of knowledge on aetiology, diagnosis, management, and therapy of myocarditis: a position statement of the European Society of Cardiology Working Group on Myocardial and Pericardial Diseases. *Eur Heart J*. 2013 Sep; 34 (33): 2636-48, 2648a-2648d.
- Busch JL, Alessio AM, Caldwell JH, Gupta M, Mao S, Kadakia J, et al. Myocardial hypo-enhancement on resting computed tomography angiography images accurately identifies myocardial hypoperfusion. *Journal of Cardiovascular Computed Tomography*. 2011 Nov; 5 (6): 412-420.

**Funding/support:** no financial support was received for this study.

**Conflict of interest:** the authors declare to have no conflict of interest.

#### Correspondence:

**Samuel Isai López-Martínez**

**E-mail:** dr-samuel.lopez@outlook.com