

# Emergency esophagojejunostomy in type IV hiatal hernia: A case report

## *Esofagoyeyunostomía de emergencia en hernia hiatal tipo IV: reporte de caso*

Carlos J. Perez-Rivera\*, Maria Oviedo, Alejandro Gonzalez-Orozco, Akram Kadamani, and Paulo Cabrera

Departamento Cirugía General, Fundación Cardioinfantil, Instituto de Cardiología, Bogotá, Cundinamarca, Colombia

### Abstract

*Reconstruction of the digestive tract is a surgical challenge; we propose a novel and successful alternative using a large vascularized pedicled jejunum anastomosed to the cervical esophagus in an emergency situation. A 65-year-old female patient in follow-up due to a gigantic type IV paraesophageal hernia, whom underwent surgical hernial defect correction, had friable gastric tissue and esophageal lesions that forced an urgent esophagojejunostomy. Immediate post-operative recovery had no incidents and during the outpatient follow-up no complications were reported. This case report represents a paradigm change in the impossibility of raising the vascularized pedicled jejunum to the neck in an emergency situation.*

**Key words:** Esophageal reconstruction. Esophagojejunostomy Roux-en-Y. Hiatal hernia. Paraesophageal hernia. Total gastrectomy.

### Resumen

*La reconstrucción del tracto digestivo es un reto quirúrgico. Proponemos una alternativa novedosa y exitosa utilizando un gran yeyuno pediculado vascularizado anastomosado al esófago cervical en situación de emergencia. Una paciente de 65 años en seguimiento por una hernia paraesofágica tipo IV requirió corrección quirúrgica del defecto herniario; tenía tejido gástrico friable y lesiones esofágicas que forzaron una esofagoyeyunostomía urgente. La recuperación posoperatoria inmediata no tuvo incidentes y el seguimiento ambulatorio no mostró complicaciones. Este reporte de caso rompe el paradigma de la imposibilidad de ascender el yeyuno pediculado vascularizado al cuello en una situación de emergencia.*

**Palabras clave:** Reconstrucción esofágica. Esofagoyeyunostomía en Y de Roux. Hernia hiatal. Hernia paraesofágica. Gastrectomía total.

### Introduction

An emergency esophageal reconstruction is a gastrointestinal surgical challenge, especially when time and preparation play a critical role. The usual approach

involves using the stomach; however, when this is not possible, there are other intra-abdominal alternatives such as the colon and jejunum. In rare cases, when intra-abdominal organs are not an option, a fasciocutaneous thigh flap can be considered. In the scientific

#### Correspondence:

\*Carlos J. Perez-Rivera  
Calle 163 A N° 13B-60  
Bogotá, Cundinamarca, Colombia  
E-mail: cjperezrivera@gmail.com

Date of reception: 24-04-2019  
Date of acceptance: 09-12-2019  
DOI: 10.24875/CIRU.19001259

Cir Cir. 2020;88(S1):14-18  
Contents available at PubMed  
www.cirugiaycirujanos.com

0009-7411/© 2019 Academia Mexicana de Cirugía. Published by Permanyer. This is an open access article under the terms of the CC BY-NC-ND license (<http://creativecommons.org/licenses/by-nc-nd/4.0/>).

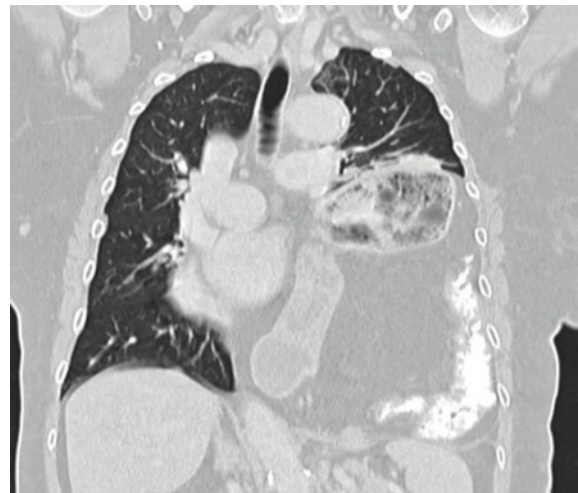literature, there are no clear indications or methodology as to how to proceed in an emergency esophageal reconstruction. The use of colon or jejunum remains controversial; the jejunum considered as more advantageous<sup>1,2</sup>. In this case report, a raised large vascularized pedicled jejunum was used to achieve the continuity of the digestive tract as a successful emergency alternative repair in type IV paraesophageal hernia when there is no viability of the thoracic esophagus or stomach. This approach was performed in the Fundación Cardioinfantil – Instituto de Cardiología, Bogotá, Colombia.

## Case presentation

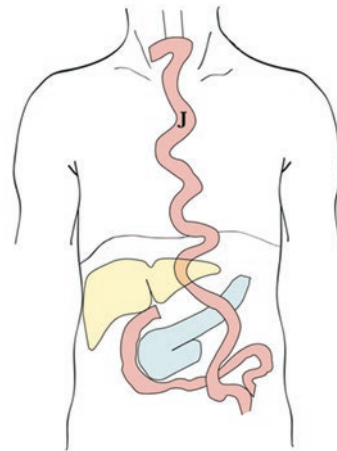
A 65-year-old, mestizo-race female with prior history of arterial hypertension, ST-elevation myocardial infarction, mild mitral insufficiency (left ventricular ejection fraction of 68%), diverticulosis, and closed thoracic trauma that did not require intra-hospital treatment, was admitted into a fourth level hospital. The patient was in a 2-year follow-up of a gigantic type IV paraesophageal hernia, with the purpose of evaluating a surgical correction in Bogotá, Colombia.

In the initial assessment, the patient was dyspneic with New York Heart Association classification III/IV and American Society of Anesthesiologists score of 3, a body mass index of 28.18 kg/m<sup>2</sup> and no other pathological findings in physical examination. Normal initial laboratory results led to a thoracoabdominal computed tomography scan that reported a 7-cm hernial defect in the distal third of the left hemidiaphragm containing the gastric bubble and colic splenic flexure without strangulation (Fig. 1). The herniation consequently produced a pulmonary collapse and a cardiac compression resulting in deterioration of the patient's functionality. The hospital's board of general surgery decided an elective surgical paraesophageal hernia defect correction was warranted. Intraoperatively, an emergency reconstruction of the digestive tract was completed by performing an esophagojejunal anastomosis with raising the jejunum-en-Y to the neck. This case is presented in accordance with the Surgical Case Report guidelines<sup>3</sup>.

At first, the usual laparoscopic approach hernial defect correction was successfully performed, reducing the transverse colon and the greater omentum in the abdominal cavity. However, reduction of the proximal stomach was not possible due to chronic strangulation and a shortened esophagus. The esophagus was poorly visualized forcing a medial supraumbilical

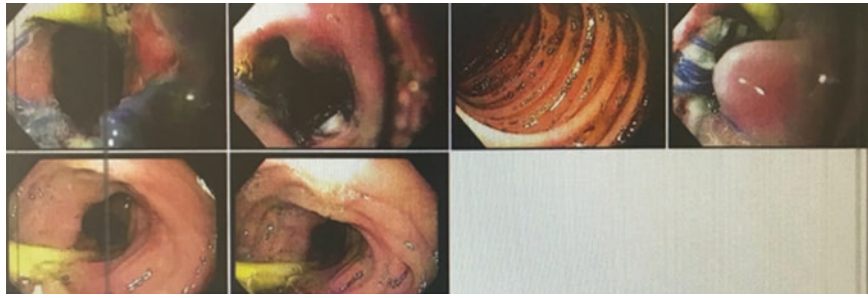


**Figure 1.** Thoracoabdominal computed tomography image. This pulmonary image reveals the type IV paraesophageal hernia.



**Figure 2.** Animation of the surgical procedure. The pedicled jejunum (J) is risen to the neck through Y-en Roux, with termino-lateral esophagojejunal anastomosis and total gastrectomy.

laparotomy incision, wherein erosions in the proximal stomach and distal thoracic esophagus led to an emergency resection and reconstruction of the gastrointestinal tract. These erosions could have been iatrogenic when the reduction of the hernia defect was corrected. Due to this, a thoracic anastomosis was not possible and a pedicled jejunum loop in Roux-en-Y was prepared. The latter failed to complete a transhiatal esophagojejunostomy due to friable tissue of the distal thoracic esophagus caused by inflammation. This forced a conversion of the procedure to a transhiatal esophagectomy, as well rising and elongating the pedicled jejunum into the neck to complete a manual esophagojejunostomy and a total gastrectomy (Fig. 2). Separate stitches of polyglactin suture 3-0



**Figure 3.** Upper gastrointestinal endoscopic images. These endoscopic images reveal adequate esophagojejunal anastomosis without bleeding.

were used as well as closure of the diaphragm defect completed without any complications. Subsequently, a neck drain and an advanced nasogastric tube for enteral nutrition were applied.

Patient's immediate postoperative had no incidents. Nevertheless, 5 days later patient required intensive care unit due to a pulmonary thromboembolism successfully treated. Seventeen days after surgery, oral nutrition was tolerated and subsequent hospital discharge. In the follow-up, an upper gastrointestinal endoscope showed adequate esophagojejunal anastomosis (Fig. 3). Three weeks later, a video fluoroscopic swallowing exam showed adequate passage of the contrast through the anastomosis and risen jejunum loop without evidence of stenosis or extravasation. Six months later, the RAND-36 health scale was applied with an average score of 93% in all nine categories, with the fatigue category being the lowest at 70%.

## Discussion

The paraesophageal hernia correction is one of the most challenging and complex gastrointestinal surgeries, specifically due a high recurrence rate particularly in type IV hernias. The most common life-threatening complications are ulcer bleeding, strangulation, and perforation of organs within the hernial sac<sup>4</sup>. Most patients are asymptomatic, hence why surgical correction is indicated on the appearance of symptoms or any of the complications described. A non-operative approach has a 27% mortality rate<sup>5</sup>, often opting for the surgical treatment as the best alternative.

According to the 2019 North American guidelines, previously all paraesophageal hernias were corrected on diagnoses regardless of symptoms; however, new indications are associated with the appearance of symptoms and a case-by-case decision<sup>6</sup>. Exceptions are based on diagnosis of any of the complications stated, which warrant an urgent intervention. Alternatively,

elective surgery versus observation depends on the risk-benefit course that should be consulted with the patient, especially in asymptomatic of mild symptoms, without taking into account comorbidities. Obese and overweight patients run a higher recurrence rate, often opting for a Roux-en-Y gastric bypass along with hernial correction; however, alternatively a temporal hernial correction with gastropexy can be performed until ideal weight loss is achieved.

In addition, intraoperative complications can arise converting the procedure into an urgent intervention, although only in rare cases (1.8%)<sup>7</sup>. Iatrogenic gastric perforations, when recognized early, can be corrected with a linear stapler, while esophageal perforations can be reinforced with a gastric wrap, or a fundoplication, or partial posterior fundoplication can also be applied. In either case, the post-operative has to be confirmed with a contrast swallow study before initiating the oral route. Although in our case report the patient did not present gastrointestinal complications and was overweight, the progressive deteriorating respiratory functionality warranted an elective intervention. However, intraoperatively the surgery was converted due to complications and forced an urgent reconstruction of the digestive tract that had not been taken into account before undergoing surgery.

In cases where there is no viability in the esophagus or stomach, a digestive tract reconstruction is necessary to restore its continuity. Typically, the first choice is raising the stomach, second, the colon or the jejunum, and finally there have been reports on the use of a fasciocutaneous thigh flap (lateral face)<sup>8</sup>. Table 1 summarizes the principal advantages and disadvantages of each type of organ that can be used.

In this case report, the jejunum reconstruction was considered due to: prolonged durability of the anastomosis, simple preparation of the large vascularized pedicled jejunum loop, rare pathologies associated, and presence of the colon within the hernial sac – which in itself complicates the procedure. The

**Table 1. Advantages and disadvantages of the alternatives for esophageal reconstruction**

Type of conduct	Stomach	Colon	Jejunum	Antero-lateral thigh graft
Advantages	Easy preparation	Adequate graft length	Adequate peristalsis	Alternative when there is no intra-abdominal graft available
	One and only anastomosis		Similar diameter	
	Adequate vascular supply		Rare pathologies associated <sup>1</sup>	
Disadvantages		Malignant and benign neoplasia	Larger segment of the jejunal loop is harder to prepare	Required surgical expertise in the technique
		Requires three anastomoses		
		Anatomic variations of colonic arteries	Inadequate vascular supply <sup>2</sup>	Higher probability of loss of graft
		Atherosclerosis of the colonic arteries		
		Gastroesophageal reflux	Required surgical expertise in the technique	Could require multiple interventions
		Feeling of fullness		

<sup>1</sup>In comparison to the colon, <sup>2</sup>If the microvascular pedicle ("super-charged") technique is not used.

**Table 2. Advantages and disadvantages of the surgical approaches of using the jejunum for esophageal reconstruction**

Approach	"Supercharged"	Free segment	Pedicled
Advantages	Successful functional results	Prevents gastroesophageal reflux and dissection of thoracic esophagus	Most physiologic
		Low mortality	Lower risk of fistulas
			Lower risk of stenosis
Disadvantages	Complex technique when there are no other alternatives	Risk of cervical dehiscence is higher with two anastomoses	Higher surgical time required
	Catastrophic anastomotic dehiscence		Added risks of laparotomy
	Significant postoperative morbidity	Higher risk of thrombotic ischemic-necrosis of the graft (small caliber vascular anastomosis)	Less support of the neck vessels
	Essential microsurgical expertise required		

disadvantages include inadequate vascular supply and a surgical cervical approach – which tends to be of higher risk than the thoracic approach. Some authors recommend the colon as the best option<sup>9,10</sup>, although this approach requires additional studies and an adequate preparation to reduce the rate of anastomosis-related complications.

The indications for the esophageal reconstruction from the cervical segment include: ingestion of caustics; lesions from ionized radiation; traumatic lesions from neoplasms, congenital disease, or surgical complications<sup>11</sup>. Duranceu et al. in 1980 determined the esophagus as a surgical challenge<sup>12</sup>, while Cooper and collaborators concluded that the reconstruction

was the most difficult aspect in thoracic surgery<sup>13</sup> – considerations that still resonate today.

Different surgical methods for the rising of the jejunum have been proposed: pedicled, "supercharged," or the free segment; the advantages and disadvantages of each one are listed in table 2. In this report, the vascularized jejunum was pedicled, as it has been one of the methods with lower rates of leakage and high successful anastomosis rates<sup>14,15</sup>. Modern surgery has accomplished a solution to this microvascular anastomosis complication, known as the "supercharged". However, this technique requires certain experience performing the pedicled alternative of choice.

## Conclusions

The cornerstone of the reconstruction of the digestive tract includes: preparation of the pedicled jejunum, restoring the anatomy, and reestablishing patient's ability to swallow. The surgical expertise and the multidisciplinary work play a key role in the outcomes. In emergency cases such as this one, the large vascularized pedicled jejunum approach should be considered. Finally, it is important to individualize each surgery and patient to choose the best surgical alternative for the reconstruction of the gastrointestinal tract and reduce morbidity and mortality.

## Conflicts of interest

The author declares that they have no conflicts of interest.

## Ethical disclosures

**Protection of human and animal subjects.** The authors declare that no experiments were performed on humans or animals for this study.

**Confidentiality of data.** The authors declare that they have followed the protocols of their work center on the publication of patient data.

**Right to privacy and informed consent.** The authors have obtained the written informed consent of the patients or subjects mentioned in the article. The corresponding author is in possession of this document.

## References

1. Urschel JD. Late dysphagia after presternal colon interposition. *Dysphagia*. 1996;11:75-7.
2. Cense HA, Visser MR, van Sandick JW, de Boer AG, Lamme B, Obertop H, et al. Quality of life after colon interposition by necessity for esophageal cancer replacement. *J Surg Oncol*. 2004;88:32-8.
3. Agha RA, Fowler AJ, Rajmohan S, Barai I, Orgill DP, PROCESS Group. Preferred reporting of case series in surgery; the PROCESS guidelines. *Int J Surg*. 2016;36:319-23.
4. Larusson HJ, Zingg U, Hahnloser D, Delport K, Seifert B, Oertli D. Predictive factors for morbidity and mortality in patients undergoing laparoscopic par-aesophageal hernia repair: age, ASA score and operation type influence morbidity. *World J Surg*. 2009;33:980-5.
5. Obeidat FW, Lang RA, Knauf A, Thomas MN, Hüttl TK, Zügel NP, et al. Laparoscopic anterior hemifundoplication and hiataloplasty for the treatment of upside-down stomach: mid-and long-term results after 40 patients. *Surg Endosc*. 2011;25:2230-5.
6. Choi S, Tang A, Murthy S, Raja S. Preoperative evaluation and clinical decision making for giant paraesophageal hernias. *Thorac Surg Clin*. 2019;29:415-9.
7. Imai TA, Soukiasian HJ. Management of complications in paraesophageal hernia repair. *Thorac Surg Clin*. 2019;29:351-8.
8. LoGiudice JA, von Ballmoos MC, Gasparri MG, Lao WW. When the gastrointestinal conduit for total esophageal reconstruction is not an option: review of the role of skin flaps and report of salvage with a single-stage tubed anterolateral thigh flap. *Ann Plast Surg*. 2016;76:463-7.
9. Skinner DB. Esophageal reconstruction. *Am J Surg*. 1980;139:810-4.
10. Watson TJ, DeMeester TR, Kauer WK, Peters JH, Hagen JA. Esophageal replacement for end-stage benign esophageal disease. *J Thorac Cardiovasc Surg*. 1998;115:1241-7.
11. Zhang Z, Guo Y, Liang C, Feng H, Liu D. Free jejunum interposition as salvage surgery after cervical esophagus injury. *J Thorac Dis*. 2016;8:E513-6.
12. Duranceau A. Foreword. *Surg Clin N Amer*. 1983;63:775-6.
13. Cooper J. Overview of operative techniques. In: Pearson FG, Cooper JD, Deslauriers J, Ginsberg RJ, Hiebert C, Patterson GA, et al, editors. *Esophageal Surgery*. 2<sup>nd</sup> ed. New York: Churchill Livingstone; 2002. p. 793.
14. Doki Y, Okada K, Miyata H, Yamasaki M, Fujiwara Y, Takiguchi S, et al. Long-term and short-term evaluation of esophageal reconstruction using the colon or the jejunum in esophageal cancer patients after gastrectomy. *Dis Esophagus*. 2008;21:132-8.
15. Ascioti AJ, Hofstetter WL, Miller MJ, Rice DC, Swisher SG, Vaporciyan AA, et al. Long-segment, supercharged, pedicled jejunal flap for total esophageal reconstruction. *J Thorac Cardiovasc Surg*. 2005;130:1391-8.