

Posterior extrapelvic tributaries to the internal iliac veins: Morphometrics, types, and variants

Venas extrapélvicas posteriores tributarias de las venas ilíacas internas: morfometría, tipos y variantes

Daniel Sat-Muñoz^{1,2*}, Luz M^a A. Balderas-Peña^{2,3}, Edgar J. Cortés-Torres⁴, Rocío G. Gómez-Álvarez⁵, Jesús C. Mora-Mora² y Eduardo Gómez-Sánchez⁶

¹Departamento Clínico de Oncología Quirúrgica, Unidad Médica de Alta Especialidad (UMAE), Hospital de Especialidades, Centro Médico Nacional de Occidente (CMNO), Instituto Mexicano del Seguro Social (IMSS); ²Departamento de Morfología, Centro Universitario de Ciencias de la Salud (CUCS), Universidad de Guadalajara (UdG); ³Unidad de Investigación Biomédica 02, Unidad Médica de Alta Especialidad (UMAE), Hospital de Especialidades, CMNO, IMSS; ⁴Departamento Clínico de Oncología Quirúrgica, Unidad Médica de Alta Especialidad Hospital de Especialidades, CMNO, IMSS; ⁵Departamento de Coordinación de la Licenciatura Médico Cirujano y Partero, Centro Universitario de Ciencias de la Salud (CUCS), Universidad de Guadalajara; ⁶División de Disciplinas Básicas para la Salud, Centro Universitario de Ciencias de la Salud, Universidad de Guadalajara (UdG). Guadalajara, Jalisco, México

Abstract

Background: In the distribution of the veins, it corresponds in the path and by its affluent to their arterial counterpart. For the pelvic surgeon faced with pelvic surgical pathology, the knowledge of the distribution of the venous vessels is especially important in view of novel surgical techniques and current approaches. The majority of the reports are on common iliac vein (CIV) or the inferior vena cava. To the best of our knowledge, there are no papers describing posterior extrapelvic affluents that drain into the internal iliac vein (IIV). **Objective:** The aim of this work was to describe the pattern of the constitution of the IIV in 17 dissection specimens taken at our institution. **Materials and methods:** We dissected and registered the anatomic variations of the posterior extrapelvic tributaries to the IIVs. **Results:** Moreover, we describe the presence of a vein here that is, as far as we know, the first report of a vein that is formed from the posterior extrapelvic veins that drain exactly onto the anterior surface of the CIV. We also describe herein the variants that we have found. **Conclusions:** The ignorance of the anatomic variations in the posterior extra-pelvic tributaries to the IIVs (internal iliac veins) can lead to fatal consequences in the patients undergoing pelvic surgery.

Key Words: Pelvic surgery. Posterior extrapelvic veins. Common iliac vein.

Resumen

Antecedentes: En la descripción de los trayectos venosos, estos corresponden casi exactamente a la distribución de su contraparte arterial, como es el caso de la vena iliaca interna. Para el cirujano que se enfrenta a la patología pélvica, el conocimiento de la distribución de los vasos venosos es de particular importancia. Los reportes que describen los grandes vasos venosos pélvicos se enfocan en las venas ilíacas comunes o la vena cava inferior. En nuestro conocimiento, no existen reportes

Correspondencia:

*Daniel Sat-Muñoz

Belisario Domínguez, 1000

Col. Independencia

C.P. 44340, Guadalajara, Jalisco, México,

E-mail: daniel.sat@academicos.udg.mx

0009-7411/© 2019 Academia Mexicana de Cirugía. Publicado por Permayer. Este es un artículo *open access* bajo la licencia CC BY-NC-ND (<http://creativecommons.org/licenses/by-nc-nd/4.0/>).

Fecha de recepción: 27-05-2019

Fecha de aceptación: 17-10-2019

DOI: 10.24875/CIRU.19001325

Cir Cir. 2020;88(3):306-313

Contents available at PubMed

www.cirugiaycirujanos.com

que describan los afluentes venosos posteriores que drenan a la vena iliaca interna ni las distancias que separan los vasos entre sí. **Objetivo:** Describir el patrón de constitución de la vena iliaca interna en 17 especímenes cadavéricos disecados en nuestra institución. **Material y métodos:** Se identificaron los trayectos vasculares de los afluentes venosos posteriores extrapélvicos de las venas iliacas primitivas. **Resultados:** En específico, describimos la presencia de una variante venosa que, hasta donde hemos revisado, es el primer reporte, pues esta vena posterior extrapélvica drena exactamente en la superficie anterior de la vena iliaca común. También describimos otras variantes encontradas. **Conclusiones:** Conocer las variantes de los afluentes venosos posteriores extrapélvicos es de vital importancia para el cirujano que realiza cirugía pélvica.

Palabras Clave: Cirugía pélvica. Venas extrapélvicas posteriores. Vena iliaca interna.

Introduction

The distribution of the veins is described according to their arterial counterparts; this is not different for the pelvic veins¹. According to the latter, Testut and Ruiz-Liard present the most precise description of the internal iliac artery (IIA), dividing it and its venous branches into intrapelvic and extra-pelvic. The former divided into parietal (iliolumbar and lateral sacral) and visceral vessels (umbilical, middle rectal, and vesical in both sexes, plus the uterine and vaginal in women), and the extra-pelvic, divided into the anterior (obturator) and the posterior (superior gluteal, inferior gluteal, and internal pudendal) vessels².

The internal iliac vein (IIV) is a 4 cm long trunk with an internal diameter of 10-15 mm. This vein is the result of the confluence of its affluents at the superior border of the greater sciatic foramen. According to Gregoire, there are three types of IIV, with this division based on the relationship that this vein maintains with its arterial counterpart: Type A, unique or common, in which the IIV is behind the artery; Type B, double vein, which consists of two trunks, one anterior to the artery that anastomoses with the external iliac vein (EIV) and a posterior one that anastomoses above the previous anastomosis; the anastomosis between the venous trunks is quite variable but always lateral to the artery, and Type C, or plexiform, which is a variant of the double type, but the anastomosis between the trunks is in front of and medial to the artery².

Knowledge of the distribution of venous circulation is crucial when the retroperitoneal or pelvic areas are approached by the surgical oncologist, orthopedist, gynecologist/oncological gynecologist, or neurosurgeon, on their being approached for benign or malignant pathologies and the presence of massive bleeding forces to suture or ligate the damaged vessel^{3,4}.

Materials and methods

From June 2016 to June 2018, all of the cadaveric specimens assigned for anatomy classes at the morphology department of our institution were evaluated to fulfill the criteria for inclusion in this work. Eligibility criteria included that the pelvic retroperitoneum was not approached in any way that the retroperitoneal major vessels were not dissected or cut (traumatically or dissect-intended) and that the integrity of pelvic retroperitoneum was not broken by any sign of macroscopic disease. A total of 17 male cadaveric specimens previously kept in formaldehyde at 10%⁵ were included and dissected by one of the authors (DS-M). On day 1, the specimens were approached by a medial supra- and infraumbilical incision, and the abdominal retroperitoneum was dissected to obtain access to the inferior vena cava (IVC). Then, the IIV was isolated by the occlusion of the IVC (at the level of the inferior mesenteric artery) and the EIV (at the level of the deep inguinal ring). A blue-stained liquid latex material (Ward science®, catalog number 470024-614, density: 0.95 g/mL, Rochester, NY, USA) was infiltrated through a manual method with a 50 cc syringe and Tuohy needle (1.65 mm diameter 16 G, Becton Dickinson® Franklin Lake, NJ, USA) into the IVC, the density and viscosity do not affect the highlighted veins because we are looking for great and medium vessels. After 72 h, the pelvis was approached to dissect the IIV branches and to classify the IIV into one of the three types proposed by Gregoire. After that, the IIA and its branches were removed. Photographs were taken when variants were found. Then, the length of the IVC was measured from the confluence of the left common iliac vein (LCIV) and the right common iliac vein (RCIV), at midline and at their inferior borders, and from there to the site of drainage of the IIV. Then, the IIV was cut at its drainage point, and the distance from the superior limit of IIV to the superior border of superior gluteal vein

(SGV) was measured. The same procedure was carried out for the inferior gluteal vein (IGV). Finally, the distance from the upper limit of the IGV to the superior margin of the fourth sacral nerve was measured and taken as the length of the internal pudendal vein (this for surgical issues). The results were analyzed to obtain the mean, standard deviation, and range. For this, we used the SPSS Statistics ver. 21 statistical software program (Chicago, IL, USA).

Results

From June 2016 to June 2018, a total of 17 cadaveric specimens were studied. These specimens are used for the medical students at our university in their anatomy class. The cadaveric specimens are embalmed with formaldehyde at 10% and, due to the logistics involved, the specimens were studied once the academic period ended. Not all of the cadaveric specimens matched the criteria for inclusion in this work. Since September 2017, changes in local laws made the number of cadaveric specimens authorized for medical schools diminish drastically.

All of the 17 specimens were approached bilaterally, except for specimen number 10, which presented what appeared to be a testicular cancer with right-sided massive pelvic lymphatic metastasis. Thus, the dissection of the IIV affluents was not possible. Therefore, this study comprises 33 dissected sides.

Length of venous parietal posterior affluents

The first that we measured was the length of the common iliac vein (CIV); the mean on the right side was 34 mm (range, 30-41 mm) and 56.24 mm (range, 50-68 mm) on the left side. The distance between the IIVs (measured from its inferior border) to the confluence of the superior border of the SGV had a mean length of 35.8 mm (23-44 mm) on the right side and of 32.4 mm (15-67 mm) on the left side. The distance between the inferior border of the IIV and the superior border of the IGV had a mean length of 42.44 mm (38-47 mm) and, for the left side, this was 66.3 mm (52-82 mm). We considered the pudendal internal vein as the vein that ran from the inferior border of the IGV to the superior border of the fourth anterior sacral nerve (this solely for surgical purposes), and the mean length of this remaining vessel was 11.6 mm (9-13 mm) on the right side and, for the left side, the mean was 15.5 mm (12-19 mm) (Table 1).

Table 1. Morphometry of the pelvic venous vessels

Origin internal iliac vein (mm)						
Right side			Left side			p value
Mean	Standard deviation	Range	Mean	Standard deviation	Range	
32	8.97	30-41	56.23	5.94	50-68	0.000
Superior gluteal vein (mm)						
Right side			Left side			p value
Mean	Standard deviation	Range	Mean	Standard deviation	Range	
33.65	10.29	23-44	32.35	17.73	15-67	0.743
Ischiatic vein (mm)						
Right side			Left side			p value
Mean	Standard deviation	Range	Mean	Standard deviation	Range	
39.94	10.78	38-47	66.35	10.61	52-82	0.000
Internal pudendal vein (mm)						
Right side			Left side			p value
Mean	Standard deviation	Range	Mean	Standard deviation	Range	
11.59	3.76	12-18	14.88	2.34	12-19	0.022

Table 2. Anatomic variants: relationship right side/left side

Relationship right/left	n (%)	Cadaveric specimen
I:I	1 (6.25)	7
I:II	1 (6.25)	4
I:II modified	1 (6.25)	14
I:III	4 (25)	6, 12, 13 y 17
II:I	2 (12.5)	2 y 8
II modified:I	1 (6.25)	9
II:III	1 (6.25)	1
II modified:II modified	1 (6.25)	3
III:I	2 (12.5)	15 y 16
III:II	2 (12.5)	5 y 11

IIV Types (Gregoire based)

For this section see table 2. In two of the cadaveric specimens (numbers 3 and 7), the same IIV type was found on both sides: Type II and Type I, respectively. Type I was present in 7/16 and 7/17 cases for the right and left sides, respectively, and Type II was present in 4/16 and 4/17. Type II modified (Discussion section) was present in 1/16 and 1/17, and Type III was found in 4/16 and 5/17 cases for the right and left sides, respectively. Specimen number 3 was unique with a bilateral variant, that is, Type II modified (Discussion section). The frequency in relationship of type appearance both sides (right to left) was of frequency,

Table 3. Frequency by the side of types of internal iliac vein according to Gregoire

Type	Right (n = 16)	(%)	Left (n = 17)	(%)
I	7	43.75	7	41.18
II	4	25.00	4	23.53
II modified	1	6.25	1	5.88
III	4	25.00	5	29.41
Non-valuable*	---	---	0	0.00
Total	16	100.00	17	100.00

*In one cadaveric specimen, the right side was non-dissectable by metastatic activity in pelvis (case not considered in the total)

combination I:III in 4 specimens (25%); II:I, III:I, and III:I in 2 specimens (12.5%) for every one of the combinations; and in 1 specimen (6.25%) for the rest of the combinations (Table 3).

Variants

We found a total number of 5 (15.5%) variants in 33 dissected sides, 2 (12.5%) variants in 16 right-sided dissections, and 2/17 (11.8%) in dissections on the left side. In specimen 3, we found both sides with a variant in the distribution of the IIV. These variants were in the so-called Type II, which is why we denominated these Type II modified. We did find one case of a double left IVC.

SPECIMEN NUMBER 3

On the right side, the main distribution was that of a Type II, but the posterior trunk received the iliolumbar vein as a wide trunk presents in the shape of an uppercase letter T (Fig. 1). The left side showed a variant that, to our knowledge, has not been described; this consisted mainly of a Type II, but the posterior trunk, instead of draining onto the posterior surface of the LCIV, drained onto the anteromedial surface of the LCIV 4 mm ahead of the confluence of the anterior trunk of the IIV and the EIV (Fig. 2).

SPECIMEN NUMBER 4

In this, we found that the left iliolumbar vein drained with the EIV onto the lateral surface of the IIV, taking the shape of an uppercase letter H (Fig. 3).

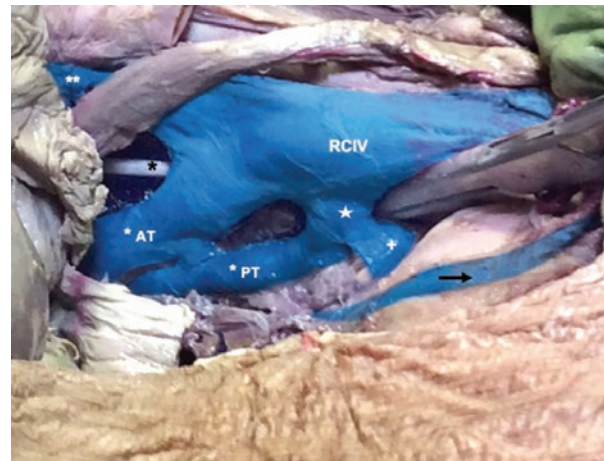


Figure 1. Specimen 3 right side a type II internal iliac vein. RCIV: right common iliac vein. Black asterisk: obturator nerve. White asterisk AT: internal iliac vein anterior trunk. White asterisk PT: internal iliac vein posterior trunk. Double white asterisk: right external iliac vein. Plus sign: ascending lumbar vein. Star: common trunk that drains the posterior extrapelvic veins with ascending lumbar vein into the right common iliac vein. Black arrow: medial sacral vein.

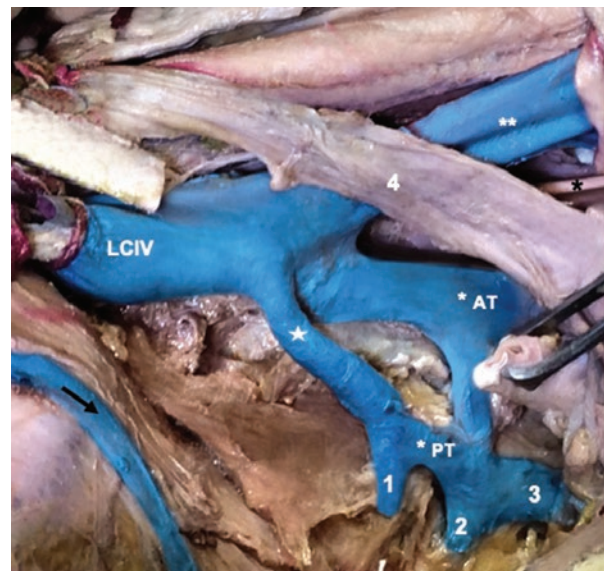


Figure 2. Specimen 3 left side, a type II modified internal iliac vein. LCIV: left common iliac vein. Black asterisk: obturator nerve. White asterisk AT: left internal iliac vein anterior trunk. White asterisk PT: left internal iliac vein posterior trunk. Double white asterisk: right external iliac vein. Star: intermediate iliac vein that drains at the confluence of internal and external iliac veins. Black arrow: medial sacral vein. 1: superior gluteal vein. 2: inferior gluteal vein. 3: internal pudendal vein. 4: left ureter.

SPECIMEN NUMBER 7

This specimen showed, in the right pelvis, an anastomosis that formed an annulus, which, in turn, joined the EIV with the IIV, always lateral to the artery (Fig. 4).

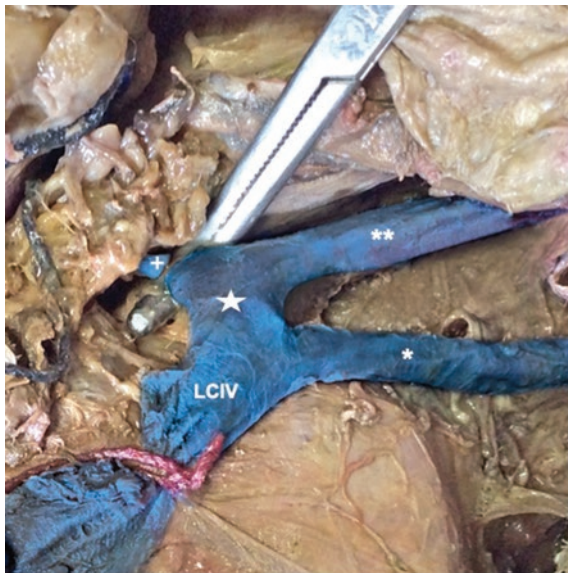


Figure 3. Specimen 4 left side a type I internal iliac vein where the left ascending lumbar vein drained with the external iliac vein in the lateral surface of the internal iliac vein taking the shape of a capital H. LCIV: left common iliac vein. White asterisk: left internal iliac vein. Double white asterisk: left external iliac vein. Plus sign: ascending lumbar vein. Star: confluence of the left external iliac vein with the ascending lumbar vein and the internal iliac vein with left common iliac vein taking the shape of H.

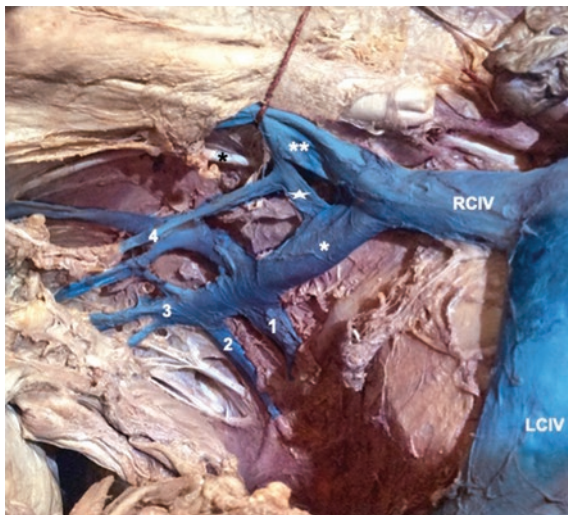

Figure 4. Specimen 7 right side, a type I internal iliac vein where we found an anastomosis that formed an annulus that joined the external iliac vein with internal iliac vein always lateral to the artery. RCIV: right common iliac vein. White asterisk: right internal iliac vein. Double white asterisk: right external iliac vein. Star: anastomosis that formed an annulus that joined the external iliac with the internal iliac veins. Black asterisk: Obturator nerve. 1: superior gluteal vein. 2: inferior gluteal vein. 3: internal pudendal vein. 4: intrapelvic visceral veins.

SPECIMEN NUMBER 10

In this specimen, the right side was unable to be dissected due to the finding of what it appeared to be a testicular cancer associated with a right-sided

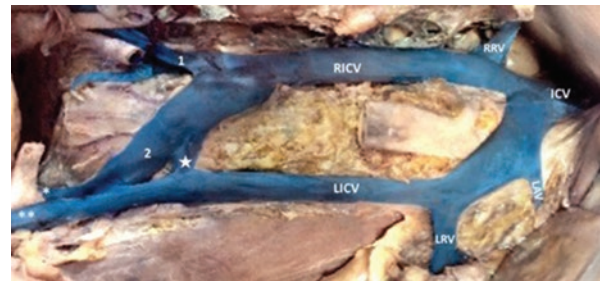


Figure 5. Specimen 17. Double inferior cava vein: RICV: right inferior cava vein. LICV: left inferior cava vein. IVCV: inferior cava vein. RRV: right renal vein. LRV: left renal vein. LAV: left adrenal vein. Star: accessory iliac vein. White asterisk: left internal iliac vein. Double white asterisk: left external iliac vein.

massive pelvic lymphatic metastasis. For this reason, in this specimen, only the left side was dissected and, in this, we found a variant in the iliolumbar vein.

SPECIMEN NUMBER 17

In this, we found an anomaly of the IVC, a double vena cava (Fig. 5).

Discussion

At present, there are surgical techniques that approach the pelvis facing the IIV tributaries, and the bleeding associated with the non-adverted tearing or damage of these is associated with high morbidity or even mortality. That is why a profound knowledge of the distribution and constitution of the IIV is, in the majority of cases, bleed sparing. This is true for the scheduled as well as for the urgent surgical scenario⁶⁻⁸.

It has been nearly 20 years since a new, ultraradical surgical technique to treat recurrent cervical cancer was described by Höckel and Höckel et al., in Germany. This embryological-based surgical technique includes the resection of the Mueller compartment derivatives and with these, all of the IIV tributaries on the affected side^{9,10}.

The main aim of this work was to obtain the distance between the extrapelvic posterior tributaries of the IIV. In addition, we classified the IIV on the basis of a Gregoire classification because, to our knowledge, this is the most complete and precise description. The majority of the papers published in this area are on the great venous vessels of the retroperitoneum or, when the IIV is reported, these reports concern the main vein, but not the type of constitution, the tributaries of the IIV, or the frequency of the same type in the same individual. The sole work on the morphometrics

is, to our knowledge, that of Teli et al.; these authors measured the length and the internal diameter of the iliolumbar artery and veins⁴.

As far as we know, this is the first work that describes the distance between the extrapelvic posterior tributaries of the IIV. In this line of thought, we found that the LCIV was longer than the RCIV by more than 2 cm, this corresponding with what has been reported Venieratos et al.¹¹ Our findings show that the mean distance that separates the drainage of the IIV from the V was longer on the right side than on the left while, in the remainder of the measurements taken, the lengths were longer on the left side. Because there are, to our knowledge, no reports on these measurements, we are unable to attempt to explain the difference found in the distance between the IIV and the SGV on the right side. There are three works on the morphometrics of the veins, but, unfortunately, there are none on the extrapelvic tributaries of the IIV. Two of these works are included under the surgical anatomy of the ascending lumbar and iliolumbar veins, the latter understandable in the face of minimally invasive orthopedic surgical techniques^{4,11,12}.

We describe the types of the IIV based on the classification proposed by Gregoire, and we employed this classification due to its simplicity. As can be observed in table 2, the most common type is Type I or the common type, found in 14 of 33 sides (42.4%). The second most frequent type was Type II, with 10 of 33 (30.3%), and here, we included the two variants of Type II that we found. The least frequent was Type III, in nine of 33 (27.3%). As we can observe, and even when the number of specimens was insufficient for arriving at generalizations, the types found correspond to the classification proposed by Gregoire, and we think that this classification could continue to be used. If we consider the frequency at which the same type appears on both sides in the same specimen, we found that this situation was present in only two of 16 (11.7%) specimens; we did not take specimen number 10 into account because, in that specimen, only one side could be dissected. In the 14 specimens remaining, the right-to-left relationship comprised four cases of I:III, the II:I relationship with three cases, and the I:II, III:I, and III:II relationships with two cases each (Table 3).

We found 5 anomalies (15.5%) on 33 dissected sides; in terms of the constitution of the IIV, this corresponds to what has been reported by Venieratos

et al., who reported 15.5% of variations in 59 specimens¹¹. These anomalies must be explained on the basis of the ontogenesis of the retroperitoneal and pelvic venous system, which is based on the three-paired sets of veins and their modifications. The iliac veins, the iliac bifurcation, and the root of the azygos vein are the sole adult derivatives of the postcardinal system⁵.

On the right side of specimen number 3, we found that the iliolumbar vein did not drain onto the lateral surface of the CIV. Instead, it formed a common trunk with the posterior trunk of the IIV and drained into the medial aspect of the CIV (Fig. 1). This anomaly does not correspond to any of the types described elsewhere¹¹⁻¹³. On the left side, we found, to our knowledge, a not to date reported anomaly. This was a Type II-based anomaly, in which the posterior trunk of the IIV drained onto the anterior surface of the IIV, and not in its inferior and medial aspect, as has been reported (Fig. 2). Morita et al. (2007) used multidetector computed tomography to describe the variations of the IIV. These authors described 63 patients and proposed a classification in six types, A-F, Type A being the most common and that which is known as normal (frequency 69.8%). Types B and C are related to the drainage of the left IIV, Types D and E are related to the drainage of the right IIV, and in Type F, both IIVs drain in one trunk¹⁴. In 2015, Shin et al. described the results in 2488 patients using multidetector computed tomography, and these authors classified their findings into eight types (Types 1-8). The authors reported a frequency of variants of 20.9%¹³. The anomaly that we found on the left side of specimen 3 does not correspond to any of the types proposed in any of those classifications, although the latter is the most complete one published to date. Other authors have published reports on the variations of the iliac veins based on the IIV¹⁵, but none of the types exposed are applicable to the anomaly found on the left side of specimen 3.

In specimens 4 and 10, we found variations of the ascending lumbar vein (ALV), both on the left side, and, in specimen 4, the ALV and LCIV formed the upper part of an uppercase letter H. Meanwhile, the LIIV and the LEIV formed the inferior half of the H. In specimen 10, only the left side could be dissected, and, in this, there was a hypertrophied ALV, which we think was a result of the previously mentioned finding of a right testicular tumor with massive pelvic lymphatic metastasis. In the former case, there was no

correspondence with the types already described, while in the latter case, the anomaly corresponded to the IA type described by Lolis et al.¹²

On the right side of specimen 7, we found an anastomosis that formed an annulus that joined the EIV to the IIV, always lateral to the artery. In this annulus, the superior vesical vein drained into and closer to the EIV than the IIV. Curiously, this specimen was one of two that presented the same type (Type I) on both sides. In the work of Shin et al. dedicated to classifying the iliac vein variations in computed tomography, the closest type that would match with our finding is Type 8b¹³. Djedovic and Putz¹⁶ described a venous annulus formed by the EIV around the external Iliac artery; this is more consist with Type 8b described by Shin et al.¹³ Vidal et al. also reported five cases of what the authors have called an ectopic IIV in a series of 90 patients, but neither of these ectopic IIVs correspond to our findings¹⁷.

While not the main objective of this work, we found a duplicated IVC. This variation was first reported in 1916, and the reported incidence is 0.2-3%. It is the result of the persistence of both postrenal segments of the supracardinal veins^{5,6,18}. Others have reported isolated cases of variants in the constitution of the IVC or even to the agenesis of the IVC; this being associated with surgical implications derived from the approaches to the retroperitoneum^{7,15,19-22}. The case we found corresponds to Type IIb (the type most frequently reported) in the classification proposed by Chen et al.⁷

Our work is the first, to our knowledge, that reports on the type of the IIV and the morphometry of the posterior extrapelvic tributaries of the IIV. We consider that beyond the percentage and frequency of a specific anatomic variation, the knowledge of the mean distance between the tributaries or the variants that we have found could be time sparing for the gynecological, onco-gynecological, orthopedical, and oncologist surgeons and could even be lifesaving.

Conclusions

Our work is the first, to our knowledge, that reports on the type of the IIV and the morphometry of the posterior extrapelvic tributaries of the IIV. We consider that beyond the percentage and frequency of a specific anatomic variation, the knowledge of the

mean distance between the tributaries or the variants that we have found could be time sparing for the gynecological, onco-gynecological, orthopedical, and oncologist surgeons and could even be lifesaving.

Conflicts of interest

Authors declare that have not any conflict of interest in the manuscript, including financial, consultant, institutional and other relationships that might lead to bias or a conflict of interest.

Funding

This work was supported by a grant by PRODEP (Programa para el Desarrollo Profesional Docente) Convocatoria 2017 de "Fortalecimiento de Cuerpos Académicos", with number: 511-6/17-7354

Ethical disclosures

Protection of human and animal subjects. The authors declare that the procedures followed were in accordance with the regulations of the relevant clinical research ethics committee and with those of the Code of Ethics of the World Medical Association (Declaration of Helsinki).

Confidentiality of data. The authors declare that they have followed the protocols of their work center on the publication of patient data.

Right to privacy and informed consent. The authors have obtained the written informed consent of the patients or subjects mentioned in the article. The corresponding author is in possession of this document.

References

1. Nayak SB, Shetty SD, Sirasanagandla SR, Vasanthakumar P, Jetli R. Multiple variations in the pelvic vasculature a case report. *J Clin Diagn Res.* 2015;9:AD01-2.
2. Latarjet M, Liard AR. *Anatomía Humana.* 4th ed. Mexico: Médica Panamericana; 2006.
3. Dzsinih C. Ligation of the large vessels in the pelvis. *CME J Gynecologic Oncol.* 2004;9:38-40.
4. Teli CG, Kate NN, Kothandaraman U. Morphometry of the iliolumbar artery and the iliolumbar veins and their correlations with the lumbosacral trunk and the obturator nerve. *J Clin Diagn Res.* 2013;7:422-6.
5. Cardinot TM, Aragão AH, Babinski MA, Favorito LA. Rare variation in course and affluence of internal iliac vein due to its anatomical and surgical significance. *Surg Radiol Anat* 2006;28:422-5.
6. Morita S, Higuchi M, Saito N, Mitsuhashi N. Pelvic venous variations in patients with congenital inferior vena cava anomalies: classification with computed tomography. *Acta Radiol.* 2007;48:974-9.
7. Chen H, Emura S, Nagasaki S, Kubo KY. Double inferior vena cava with interiliac vein: a case report and literature review. *Okajimas Folia Anat Jpn.* 2012;88:147-51.

8. Chong GO, Lee YH, Hong DG, Cho YL, Lee YS. Anatomical variations of the internal iliac veins in the presacral area: clinical implications during sacral colpopexy or extended pelvic lymphadenectomy. *Clin Anat*. 2015; 28:661-4.
9. Höckel M. Cancer permeates locally within ontogenetic compartments: clinical evidence and implications for cancer surgery. *Future Oncol*. 2012;8:29-36.
10. Höckel M, Hentschel B, Horn LC. Association between developmental steps in the organogenesis of the uterine cervix and locoregional progression of cervical cancer: a prospective clinicopathological analysis. *Lancet Oncol*. 2014;15:445-56.
11. Venieratos D, Panagouli E, Lolis E. Variations of the iliac and pelvic venous systems with special attention to the drainage patterns of the ascending lumbar and ilio lumbar veins. *Ann Anat*. 2012;194:396-403.
12. Lolis E, Panagouli E, Venieratos D. Study of the ascending lumbar and ilio lumbar veins: surgical anatomy, clinical implications and review of the literature. *Ann Anat* 2011;193:516-29.
13. Shin M, Lee JB, Park SB, Park HJ, Kim YS. Multidetector computed tomography of iliac vein variation: prevalence and classification. *Surg Radiol Anat*. 2015;37:303-9.
14. Morita S, Saito N, Mitsuhashi N. Variations in internal iliac veins detected using multidetector computed tomography. *Acta Radiol*. 2007;48:1082-5.
15. Hayashi S, Naito M, Hirai S, Terayama H, Miyaki T, Itoh M, et al. Proposal for a new classification of variations in the iliac venous system based on internal iliac veins: a case series and a review of double and left inferior vena cava. *Anat Sci Int*. 2013;88:183-8.
16. Djedovic G, Putz D. Case report: description of a venous annulus of the external iliac vein. *Ann Anat*. 2006;188:451-3.
17. Vidal V, Monnet O, Jacquier A, Bartoli JM, Tropiano P. Accessory iliac vein: surgical implications. *J Spinal Disord Tech*. 2010;23:398-403.
18. Strauss A, Kuemper C, Mundhenke C, Schaefer F, Jonat W, Hilpert F. Congenital retroperitoneal vascular anomalies: impact on pelvic surgery. *Arch Gynecol Obstet*. 2011;284:1169-73.
19. Coco D, Cecchini S, Leanza S, Viola M, Ricci S, Campagnacci R. Inferior vena cava duplication: incidental case in a young woman. *Case Rep Radiol*. 2016;2016:3071873.
20. Guo F, Li T, Liu W, Wang G, Ma R, Wu R. Wilms tumor with inferior vena cava duplication: a rare case report. *BMC Urol*. 2018;18:88.
21. Chentanez V, Nateniyom N, Huanmanop T, Agthong S. Co-existence of the double inferior vena cava with complex interiliac venous communication and aberrant common hepatic artery arising from superior mesenteric artery: a case report. *Folia Morphol (Warsz)*. 2018;77:151-5.
22. Singh SN, Bhatt TC. Inferior vena cava agenesis: a rare cause of pelvic congestion syndrome. *J Clin Diagn Res*. 2017;11:TD06-8.