ORIGINAL ARTICLE

October-December 2026
Vol. 4, no. 4 / pp. 308-313

Received: January 13, 2026
Accepted: March 24, 2026

doi: 10.35366/123548

CC BY NC ND

Postoperative Horner's syndrome after cervical spine surgery: a single-center case series and clinical considerations

Síndrome de Horner postquirúrgico en cirugía cervical: serie de casos institucional y consideraciones clínicas

Daniel Macías Ávila,*,‡ Ernesto Grimaldo Urrutia,*,§ Víctor Demetrio Castillo Coronado*,¶

Keywords:
Horner's syndrome, cervical spine surgery, sympathetic nervous system injuries, anterior cervical discectomy and fusion, risk factors.

Palabras clave:
síndrome de Horner, cirugía de columna cervical, lesiones del sistema nervioso simpático, discectomía cervical anterior y fusión, factores de riesgo.

ABSTRACT

Introduction: Horner's syndrome (HS) may occur after cervical spine surgery as a result of injury or traction of the cervical sympathetic chain during anterior approaches. The literature reports low incidence rates (0.06-0.6%); however, cases continue to be documented, particularly in technically demanding surgical scenarios. **Objective:** to estimate the incidence, describe the clinical course, and identify technical considerations associated with postoperative Horner's syndrome in a consecutive cohort of cervical spine surgeries, and to compare the findings with those reported in the literature. **Material and methods:** a retrospective review was conducted of all cervical spine surgeries performed by two spine surgeons between October 1, 2019, and September 30, 2025, at three private hospitals in Guadalajara, Mexico. Demographics, surgical approach, operated levels, procedure type, complications, and clinical course were recorded. Minimum follow-up was 12 months in patients who reached this period. **Results:** forty-two patients were included (mean age 57.8 ± 12.4 years; 61.9% male). The most common approach was right anterior (90.5%), and anterior cervical discectomy and fusion was the predominant procedure (66.7%). Postoperative complications occurred in 12 patients (28.5%), most frequently dysphagia and radiculopathy (7.1% each). Two patients (4.7%) developed postoperative Horner's syndrome, both with immediate onset and partial clinical improvement documented at three months. **Conclusions:** in this consecutive cohort, the incidence of postoperative Horner's syndrome was 4.7%, higher than that reported in the literature (0.06-0.6%). Technical conditions such as revision surgery, extensive dissection, calcified pathology, and prolonged operative time may be associated with its occurrence. Early recognition and explicit inclusion of this complication in the informed consent process should be considered in anterior cervical spine surgery, particularly in complex cases.

Level of evidence: IV. Retrospective case series.

RESUMEN

Introducción: *el síndrome de Horner (SH) puede presentarse después de cirugía cervical, asociado a lesión o tracción de la cadena simpática durante abordajes anteriores. La literatura reporta incidencias bajas (0.06-0.6%), pero los casos continúan documentándose, en particular en escenarios técnicos*

* Hospital Puerta de Hierro. Zapopan, Jalisco, México.
‡ Traumatología y Ortopedia, Cirugía de Columna. Consultorio de Columna Vertebral. ORCID: 0000-0003-1804-3001
§ Neurocirugía, Cirugía de Columna. Consultorio de Columna Vertebral. ORCID: 0009-0005-6166-3152
¶ Traumatología y Ortopedia, Cirugía de Cadera. Consultorio de Cadera. ORCID: 0009-0007-3453-5045

Correspondence:
Dr. Daniel Macías Ávila
E-mail:
contacto@drdanielmacias.com

How to cite: Macías ÁD, Grimaldo UE, Castillo CVD. Postoperative Horner's syndrome after cervical spine surgery: a single-center case series and clinical considerations. Cir Columna. 2026; 4 (4): 308-313. https://dx.doi.org/10.35366/123548

complejos. ***Objetivo:*** *estimar la incidencia, describir el curso clínico e identificar consideraciones técnicas asociadas a SH postoperatorio en una cohorte consecutiva de cirugía cervical, y contrastar los hallazgos con lo reportado en la literatura.* ***Material y métodos:*** *estudio de cohorte retrospectivo que incluyó pacientes sometidos a cirugía de columna cervical por dos cirujanos de columna entre el 1 de octubre de 2019 y el 30 septiembre de 2025, en tres hospitales privados de Guadalajara, México. Se registraron datos demográficos, abordaje, niveles operados, tipo de procedimiento, complicaciones postoperatorias y evolución clínica. El seguimiento mínimo fue de 12 meses en los pacientes que alcanzaron este periodo.* ***Resultados:*** *se incluyeron 42 pacientes (edad media 57.8 ± 12.4 años; 61.9% hombres). El abordaje más frecuente fue anterior derecho (90.5%) y el procedimiento predominante fue discectomía cervical anterior y fusión (66.7%). Se documentaron complicaciones postoperatorias en 12 pacientes (28.5%); las más frecuentes fueron disfagia y radiculopatía (7.1% cada una). Dos pacientes (4.7%) presentaron SH postoperatorio, ambos de inicio inmediato y con mejoría clínica parcial a los tres meses.* ***Conclusiones:*** *en esta cohorte consecutiva, la incidencia de SH postoperatorio fue de 4.7%, superior a la reportada en la literatura (0.06-0.6%). Condiciones técnicas como cirugía de revisión, disección amplia, patología calcificada y tiempos quirúrgicos prolongados pueden asociarse a su presentación. El reconocimiento temprano y su inclusión explícita en el consentimiento informado deben considerarse en la práctica de cirugía cervical anterior, especialmente en casos complejos.*

Nivel de evidencia: *IV (serie de casos retrospectiva).*

Abbreviations:

ACDF = Anterior Cervical Discectomy and Fusion
HS = Horner's syndrome

INTRODUCTION

The anterior approach to the cervical spine, independently described by Smith and Robinson[1] and Cloward[2] in 1958, has become a standard surgical technique for the treatment of degenerative cervical pathology. Its effectiveness and clinical outcomes have been widely documented, although a well-defined spectrum of postoperative complications has also been recognized.[3,4]

Horner's syndrome (HS), characterized by ptosis, miosis, and facial anhidrosis, may occur after cervical spine surgery as a consequence of injury or traction of the cervical sympathetic chain. Anatomical studies have demonstrated that the sympathetic trunk courses along the lateral border of the *longus colli* muscle beneath the prevertebral fascia, with increased vulnerability at the C5-C6 level.[5]

Previous clinical series have reported an incidence of postoperative HS ranging from 0.06 to 0.6%.[6-8] Despite these relatively low reported rates, HS continues to be documented, particularly in technically demanding surgical scenarios such as revision procedures, calcified disc herniations, multilevel exposure, and extensive lateral dissection.[9-14]

Given the limited number of consecutive cohort studies evaluating this complication, uncertainty persists regarding its true incidence and clinical behavior in contemporary cervical spine surgery practice.

The objective of this study was to estimate the incidence, describe the clinical course, and analyze surgical considerations associated with postoperative Horner's syndrome in a consecutive six-year cohort of cervical spine surgeries performed by a specialized spine team in private hospitals in Guadalajara, Mexico.

MATERIAL AND METHODS

Study design and patient selection

A retrospective cohort study was conducted including all consecutive adult patients who underwent cervical spine surgery between October 1, 2019, and September 30, 2025. Patients were identified through institutional surgical registries and electronic medical records.

Most surgeries were performed at Hospital Puerta de Hierro Zapopan (90.2%), with additional cases at Hospital Real San José (7.1%) and Hospital México Americano (2.4%). Surgical indications were primarily degenerative cervical spine disorders.

Patients were included if they underwent any surgical procedure involving the cervical spine during the study period. Patients with incomplete clinical records or insufficient postoperative follow-up to assess complications were excluded from the final analysis.

Data collection

Collected variables included demographic data (age and sex), primary diagnosis, surgical approach, operated levels, type of procedure, occurrence of postoperative complications, and clinical evolution. Clinical follow-up was recorded for all patients, with a minimum follow-up of 12 months in those who reached this time point.

Statistical analysis

Given the descriptive objective of the study, statistical analysis was limited to descriptive measures. Continuous variables are presented as mean ± standard deviation, and categorical variables as absolute values and percentages. No comparative or inferential statistical analysis was performed due to the small sample size and low number of Horner's syndrome cases.

Ethical considerations

This study was based on retrospective analysis of anonymized clinical records obtained during routine medical care. Surgical informed consent was obtained from all patients as part of standard clinical practice.

Table 1: Baseline characteristics of the cohort (2019-2025) (N = 42).

Variable	n (%)
Age, years*	57.8 ± 12.4 [33-84]
Sex	
Male	26 (61.9)
Female	16 (38.1)
Surgical approach	
Anterior	38 (90.5)
Posterior	3 (7.1)
Combined	1 (2.4)
Most frequent levels	
C4-C5	33 (78.6)
C5-C6	23 (54.8)
Procedures performed	
ACDF	28 (66.7)
Corpectomy	4 (9.5)
Laminoplasty	3 (7.1)
Others	7 (16.7)
Minimum follow-up	≥ 12 months (for those reaching this period); overall range 3-60 months

* Values expressed as mean ± standard deviation [range].

Table 2: Postoperative complications in the cohort.

Complication	n (%)	Outcome
Dysphagia	3 (7.1)	Mostly transient
Radiculopathy	3 (7.1)	Improved with follow-up
Axial neck pain	2 (4.7)	Conservative management
Infection	1 (2.4)	Required antibiotics/drainage
Instability	1 (2.4)	Required revision
Horner's syndrome	2 (4.7)	Partial improvement at 3 months
Total complications	12 (28.5)	

Additional consent for publication of identifiable clinical images was obtained when required.

RESULTS

Cohort characteristics

A total of 42 patients who underwent cervical spine surgery during the study period were included. Surgical approaches were predominantly anterior (right-sided in 90.5% of cases), Although the study focused on postoperative Horner's syndrome associated with cervical surgery, the cohort included both anterior and posterior procedures performed during the study period.

Procedures included anterior cervical discectomy and fusion in 28 patients (66.7%), corpectomy in six (14.3%), laminoplasty in three (7.1%), total disc replacement in two (4.8%), and combined procedures in three (7.1%). Baseline characteristics of the cohort are presented in *Table 1*.

Postoperative complications

Postoperative complications were documented in 12 patients (28.5%). The most frequent were dysphagia in three patients (7.1%) and postoperative radiculopathy in three (7.1%). Other complications included axial neck pain in two (4.7%), superficial infection in one (2.4%), segmental instability in one (2.4%), and postoperative Horner's syndrome in two patients (4.7%). Detailed distribution of complications is shown in *Table 2*.

Clinical presentation of Horner's syndrome within the cohort

Two patients developed postoperative Horner's syndrome. Clinical characteristics and surgical context are described below.

Case 1. A 63-year-old woman with prior Anterior Cervical Discectomy and Fusion (ACDF) at C5-C6 presented with adjacent segment disease at C4-C5. Imaging showed plate migration into the disc space. Revision via right anterior approach included wide dissection from C4 to C6, hardware removal, and C4-C5 ACDF with stand-alone cage (two screws). Operative time: 160 min. Immediate postoperative right-sided ptosis developed, with partial improvement at three months *(Figures 1 and 2)*.

Case 2. A 42-year-old male former professional baseball player presented with progressive right C5 weakness and paresthesia. Magnetic resonance imaging revealed calcified disc herniations at C4-C6 with foraminal stenosis. Right anterior two-level ACDF (C4-C6) with stand-alone cages was performed. Operative time: 130 min. He developed ptosis, miosis, and anhidrosis immediately postoperatively. Ophthalmologic management included loteprednol etabonate, bromfenac, cyclosporine ophthalmic solution, artificial tears, and oxymetazoline nasal spray. Partial improvement was documented at 1 and 3 months *(Figure 3)*.

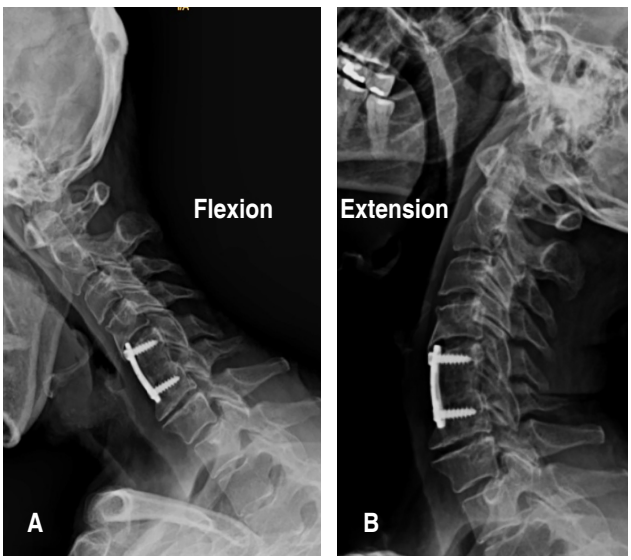

Figure 1: Preoperative dynamic cervical radiographs of case 1. **A)** Flexion. **B)** Extension. Anterior cervical arthrodesis at C5-C6 with plate and autologous bone graft (20-year evolution) showing adequate consolidation. Adjacent segment disease is evident at C4-C5, with disc space compromise and anterior plate invasion into the superior disc, findings that prompted hardware removal and new fusion.



Figure 2: Clinical images of case 1. **A)** Immediate postoperative photograph showing right-sided ptosis, consistent with Horner's syndrome secondary to the anterior cervical approach. **B)** Three-month follow-up photograph demonstrating partial improvement of ptosis with mild persistent asymmetry of the eyelids.

DISCUSSION

This consecutive single-center series provides clinical information regarding the occurrence of postoperative HS following cervical spine surgery. In this cohort, HS presented immediately after surgery and showed partial recovery during early follow-up.

Postoperative complications after anterior cervical surgery have been widely described, including dysphagia, recurrent laryngeal nerve injury, hematoma, infection, and instability.[3,4] Large clinical series report overall complication rates ranging between 10 and 30%,[3,4,15-17] which is comparable to the rate observed in the present cohort (28.5%).

The reported incidence of postoperative HS ranges from 0.06 to 0.6%.[6-8] In the present six-year consecutive cohort, the observed incidence was 4.7%. This proportion may be influenced by the small sample size and the inclusion of technically demanding surgical scenarios. This higher proportion should be interpreted cautiously given the limited sample size, which increases proportional variability. Additionally, the inclusion of complex degenerative pathology, calcified disc herniations, and revision surgeries may have contributed to a greater risk of sympathetic chain compromise.

Anatomical studies help explain this vulnerability. Civelek et al.[5] demonstrated that the cervical sympathetic

trunk lies approximately 11.6 ± 1.6 mm lateral to the medial border of the *longus colli* muscle at the C6 level, with an average diameter of 3.3 mm. The superior cervical ganglion is consistently located at C4, while the middle ganglion is most commonly found at C5-C6. These findings support the concept that wider lateral dissection, excessive retraction, or disruption of the *longus colli* muscle may increase the likelihood of sympathetic injury, particularly at caudal cervical levels.

In this series, both HS cases occurred under specific technical circumstances, including revision surgery with hardware removal requiring multilevel exposure and prolonged operative time, as well as calcified disc herniations necessitating extended decompression and soft-tissue manipulation. Similar risk factors have been described in previous reports.[9-14]

Most published cases of postoperative HS develop immediately after surgery and demonstrate gradual clinical improvement within months.[7-9] Delayed or progressive onset has also been reported.[10,14] In the present cohort, both patients presented with immediate postoperative symptoms and showed partial clinical recovery at three months.

Management of postoperative HS is typically conservative and may include topical anti-inflammatory therapy, ocular lubrication, and alpha-adrenergic nasal agonists, with generally favorable neurological outcomes.

Approximately 50 cases of postoperative HS have been reported worldwide, most as isolated case reports.[6-19] Consecutive cohort analyses addressing its incidence in routine cervical spine surgery practice remain limited, particularly in Latin American populations.

Considering the anatomical relationships of the cervical sympathetic chain and the operative characteristics observed in this series, certain surgical precautions may be considered in technically demanding scenarios. These include maintaining dissection medial to the longus colli muscle, minimizing prolonged lateral retraction, and avoiding unnecessary exposure during revision procedures or in the presence of calcified pathology.

Limitations

This study is limited by its retrospective design, small sample size (42 patients), and low number of HS cases. Most procedures were performed in a specialized private hospital setting, which may limit external validity. No inferential statistical comparisons were performed; therefore, results should be interpreted as descriptive observations. Future prospective multicenter studies are necessary to better define the incidence and clinical relevance of postoperative Horner's syndrome.



Figure 3: Clinical images of case 2. **A)** Immediate postoperative photograph showing right-sided ptosis, miosis, and mild anhidrosis, consistent with Horner's syndrome following anterior cervical approach. **B)** One-month follow-up under ophthalmologic management with loteprednol etabonate (LotereX®), bromfenac (Zebesten®), cyclosporine ophthalmic solution (Grimal®), artificial tears (Systane Ultra®), and oxymetazoline nasal spray (Afrin®), showing marked improvement in ptosis and miosis. **C)** Three-month follow-up photograph showing mild residual ptosis and miosis.

CONCLUSION

In this consecutive retrospective cohort, postoperative Horner's syndrome was identified in 4.7% of patients undergoing cervical spine surgery. This proportion was higher than previously reported rates, which may relate to sample size variability and surgical complexity. These findings highlight the importance of recognizing this complication during perioperative assessment in technically demanding cervical procedures.

REFERENCES

1. Smith GW, Robinson RA. The treatment of certain cervical-spine disorders by anterior removal of the intervertebral disc and interbody fusion. J Bone Joint Surg Am. 1958; 40: 607-624. doi: 10.2106/00004623-195840030-00009.
2. Cloward RB. The anterior approach for removal of ruptured cervical disks. J Neurosurg. 1958; 15: 602-617. doi: 10.3171/jns.1958.15.6.0602.
3. Fountas KN, Kapsalaki EZ, Nikolakakos LG, et al. Anterior cervical discectomy and fusion associated complications. Spine (Phila Pa 1976). 2007; 32: 2310-2317. doi: 10.1097/BRS.0b013e318154c57e.
4. Wang MC, Chan L, Maiman DJ, Kreuter W, Deyo RA. Complications and mortality associated with cervical spine surgery for degenerative disease in the United States. Spine (Phila Pa 1976). 2007; 32: 342-347. doi: 10.1097/01.brs.0000254120.25411.ae.
5. Civelek E, Karasu A, Cansever T, et al. Surgical anatomy of the cervical sympathetic trunk during anterolateral approach to the cervical spine. Neurosurgery. 2008; 63: ONS1-ONS5. doi: 10.1007/s00586-008-0696-8.
6. Traynelis VC, Malone HR, Smith ZA, et al. Rare complications of cervical spine surgery: Horner's syndrome. Global Spine J. 2017; 7: 103S-108S. doi: 10.1177/2192568216688184.
7. Lubelski D, Pennington Z, Sciubba DM, et al. Horner syndrome after anterior cervical discectomy and fusion: case series and systematic review. World Neurosurg. 2020; 133: e68-e75. doi: 10.1016/j.wneu.2019.08.101.
8. Yee TJ, Swong K, Park P. Complications of anterior cervical spine surgery: a systematic review of the literature. J Spine Surg. 2020; 6: 302-322. doi: 10.21037/jss.2020.01.14.
9. Umimura T, Maki S, Koda M, et al. Horner's syndrome after anterior decompression and fusion for cervical spine pathologies: report of two cases. Cureus. 2021; 13: e16633. doi: 10.7759/cureus.16633.
10. Jiawen F, Wong WSY, Yilun H. Postoperative Horner syndrome: a case report describing a rare complication after anterior cervical discectomy and fusion. J Minim Invasive Spine Surg Tech. 2024; 9 (Suppl 2): S199-S205. doi:10.21182/jmisst.2024.01221.
11. Aleid AM, Alvi MA, Bydon M. Postoperative complications across different cervical spine surgical procedures: a systematic review and meta-analysis. F1000Res. 2024; 13: 1489. doi: 10.12688/f1000research.158120.1.
12. Tavanaei R, Ansari A, Hatami A, Heidari MJ, Dehghani M, Hajiloo A, et al. Postoperative complications of anterior cervical discectomy and fusion: a comprehensive systematic review and meta-analysis. N Am Spine Soc J. 2025; 21: 100596. doi:10.1016/j.xnsj.2025.100596.
13. Farrokhi MR, Haghnegahdar A, Ghaffarpasand F. Recent progress in surgical treatment of the cervical spine. Neurol India. 2025; 73(2): 315–325. doi:10.4103/0028-3886.421923
14. Cehov B, Truong K, Vesterager JD, Riis JJ, Bjarkam CR. Horner's syndrome as a complication after anterior cervical discectomy and fusion (ACDF) surgery. Int Med Case Rep J. 2025; 18: 1183-1185. doi:10.2147/IMCRJ.S544466.
15. Safran MJ, Greenwald MJ, Rice HC, Polin KS. Cervical spine dislocation presenting as an isolated Horner's syndrome. Arch Ophthalmol. 1990; 108(3): 327-328. doi:10.1001/archopht.1990.01070050025010.
16. Leone A, Cerase A, Tarquini E, Mulè A. Chordoma of the low cervical spine presenting with Horner's syndrome. Eur Radiol. 2002; 12(Suppl 3): S43-S47. doi:10.1007/s00330-002-1590-0.
17. Hassold N, Pina Vegas L, Jelin G, Forien M, Palazzo E, Dieudé P, et al. Horner syndrome after cervical spine corticosteroid injection. Int J Rheum Dis. 2022; 25(4): 501-503. doi:10.1111/1756-185X.14297.
18. Sherin PP, Shibu I, Neyaz O, Gupta A. Horner syndrome after anterior cervical spine surgery for traumatic spinal cord injury: a rare complication. Cureus. 2023; 15(6): e40134. doi:10.7759/cureus.40134.
19. Lubelski D, Pennington Z, Sciubba DM, Theodore N, Bydon A. Horner syndrome after anterior cervical discectomy and fusion: case series and systematic review. World Neurosurg. 2020; 133: e68-e75. doi:10.1016/j.wneu.2019.08.101.

Ethical approval: all patients provided written informed consent for data and image use. The study was conducted in accordance with the principles of the Declaration of Helsinki.

Funding: this research received no external financial support.

Disclosures: the authors report no financial conflict of interests related to the materials, methods, or findings of this study. One of the authors serves as an editor of Cirugía de Columna; however, he had no involvement in the editorial handling, peer review, or decision-making process for this manuscript, which was managed independently in accordance with the journal's editorial policies.