

CLINICOPATHOLOGICAL CASE

Multiple lung complications in a patient with myeloblastic leukemia treated with chemotherapy

Edgar Bustos Córdova,¹ Israel Herrera Flores,² Argelia Escobar Sánchez,³ José Luis Lezana Hernández,⁴ Sarbelio Moreno Espinoza,⁵ and Olga Balbina Martínez Pantaleón¹

CLINICAL HISTORY SUMMARY (A-08-63)

We present the case of a 1-year, 9 month-old female patient who was seen at the Emergency Service due to fever, loss of appetite, weakness, adynamia and pallor. The patient's mother is 32 years of age and her father is 33 years of age. Both parents are healthy and without addictions. The patient has two older brothers, 5 and 10 years of age and both are healthy. The family is native and resident of Naucalpan, State of Mexico. They are from a low socioeconomic level, living in an overcrowded home with dogs as pets. The patient was breastfed during her first year of life, and weaning occurred at 5 months of age. She was adapting to the family diet upon admission.

Psychomotor development showed head control at 2 months, social smile at 2 months, sitting posture at 4 months, and walking at 17 months. The patient had a complete immunization scheme according to age (without evidence).

Perinatal and Pathological Antecedents

The patient was the product of a third pregnancy and was born after 38 gestation weeks through cesarean delivery.

The newborn cried and breathed at birth and had a birth weight of 3,800 g. No Apgar score was recorded, and there were no perinatal complications recorded. She presented chickenpox at 1 year of age without complications. There was no history of surgery, trauma, transfusion or allergic history, and there were no previous hospitalizations.

Current Illness

The patient presented a 1-month evolution profile with intermittent, nonmeasured fever (6-7 febrile peaks a day) accompanied by diaphoresis, piloerection and shivering that partially receded after physical therapy and antipyretics, loss of appetite, weakness (increase in sleep hours and decrease of daytime activity) and pallor (1 week of evolution with cephalocaudal progression). The patient received one rectal dosage of paracetamol (43 mg/kg).

At physical exploration we found 11.5 kg weight, 76 cm height, 47cm head perimeter, 170/min heart rate, 26/min respiratory rate, 100/60 mmHg arterial tension, and 38.3°C body temperature.

The patient presented an apparent age similar to chronological age. Her pupils were equal, round and reactive to light. She had permeable nostrils, hyperemic pharynx with white plaques, a 1.5-cm diameter painless, right mobile retroauricular adenopathy. There were mobile, painless bilateral axillary adenomegalies, two on the right side (1.5 cm and 2 cm in diameter) and one on the left side (1.5 cm in diameter). The chest was normal and clear with well-ventilated lung fields without signs of respiratory difficulty. Heart sounds were rhythmic, well-toned, and of normal intensity and frequency with systolic heart murmur (level II/VI over second left intercostal space). Abdomen was distended, and the splenic border was at 3 cm below the left rib border. Hepatic border was at 4-4-3 cm from the right rib border. There

¹ Servicio de Urgencias,
² Servicio de Radiología Pediátrica,
³ Departamento de Patología,
⁴ Departamento de Fisiología Pulmonar,
⁵ Departamento de Infectología, Hospital Infantil de México Federico Gómez, México, D.F., México

Correspondence: Dr. Edgar Bustos Córdova
 Servicio de Urgencias
 Hospital Infantil de México Federico Gómez
 México, D.F., México
 E-mail: edgarbus@yahoo.com.mx

Received for publication: 11-18-10
 Accepted for publication: 11-24-10

was normal peristalsis without peritoneal inflammatory data. There were mobile, nonpainful bilateral inguinal (1.5-cm diameter) adenopathies. There were normal genitalia, normal perianal area, legs with bilateral malleolar edema, muscular strength 5/5, osteotendinous reflects ++/++++, distal pulse present, and 2-sec capillary filling time. Widespread skin pallor was noted, ecchymosis on chest and upper and lower limbs. There were no apparent neurological alterations.

October 17th, 2008 (Admission)

Laboratory and clinical tests reported the following: hemoglobin (Hb) 4.8 g/dL, hematocrit (Hct) 14.1%, leukocytes 900 U/L, platelets 16,000, Na 131 mEq/L, K 4.2 mEq/L, Cl 97 mEq/L, Ca 7.5 mg/dL, P 3.2 mg/dL, prothrombin time (PT) 12.6 sec, partial thromboplastin time (PTT) 18.7 sec, total bilirubin (TB) 4.95 mg/dL, direct bilirubin (DB) 4.75 mg/dL, indirect bilirubin (IB) 0.20 mg/dL, T protein 4.9 g/dL, albumin (Alb) 1.9 g/dL, alanine aminotransferase (ALT) 256 U/L, aspartate aminotransferase (AST) 131 U/L, lactate dehydrogenase (LDH) 1179 U/L, alkaline phosphatase (ALP) 2736 U/L, blood urea nitrogen (BUN) 17 mg/dL, uric acid 4.2 mg/dL, glucose 88 mg/dL, cholesterol 410 mg/dL, triglycerides 441 mg/dL, and creatinine 0.6 mg/dL.

Chest x-ray showed no alterations, and there was no mediastinum widening.

Management

Management included fasting, base solutions 1500/mL, 2:1 solutions with K 30 meq/m² SC/day, omeprazole 0.7 mg/kg/day and paracetamol 10 mg/kg/dose; red cell concentrate 5 mL/kg/dose and platelet concentrate 4 U/m² SC/dose. Subsequently, the patient was managed with normal diet and calcium and phosphorus supplements.

Oncology

A bone marrow aspiration (BMA) was carried out, finding hypocellularity with myeloid blasts. The study was nonconclusive.

October 19th, 2008. The patient was admitted to oncology because of febrile peaks. Infectology recommended no antimicrobial therapy. A new BMA was carried out, demonstrating M4 acute myeloid leukemia.

Cardiology

Echocardiography was carried out with 70% ejection fraction and 39 shortening fraction. There was no chemotherapy contraindication.

October 20, 2008. Fever persisted with white plaques on tongue and palate. Oral sample revealed blastoconidia and pseudomycelia along with data suggesting esophagitis. Infectology reported antibiotic therapy using cefotaxime (150 mg/kg/day), amikacin (15 mg/kg/day) and amphotericin B (1 mg/kg/day).

October 22, 2008. Oncology reported negative immunohistochemistry and cytogenetics. Chemotherapy was started using Ara C, etoposide and mercaptopurine.

October 26, 2008. After 2 days without fever, the patient presented isolated fever peaks and diarrhea with nonbloody mucous. There was significant neutropenia.

October 27, 2008. Infectology reported suspension of cefotaxime and addition of cefepime (150 mg/kg/day). Amphotericin administration was continued. On the last day of chemotherapy, one dose of dexrazoxane (400 mg) and one dose of doxorubicin (40 mg) were given.

October 31, 2008. After 4 days without fever, isolated peaks of fever returned. The patient continued with diarrhea.

November 1, 2008. Fever persisted. CT scan was performed showing maxillary sinusitis and abdominal findings were pneumatosis intestinalis. Positive galactomannans reported. Infectology reported that cefepime was suspended. Meropenem (100 mg/kg/day) was suggested as well as amikacin (15 mg/kg/day) and voriconazole. Otorhinolaryngology reported bilateral occupation of ethmoidal and maxillary sinuses, not requiring surgical management.

November 6, 2008. Fever returned after 3 days. There were isolated tachycardias. Diarrhea persisted. Continuity solution in oral mucosa and sphacelation at perianal region was carried out. Soft diet began with patient rejection. Buprenorphine was administered due to pain. Thrombocytopenia is 5000 and transfusion of packed platelets was scheduled.

November 7, 2008. Infectology reported that vancomycin 40 mg/kg/day was added.

November 11, 2008. Surgery reported a failed attempt to place a catheter at the internal jugular, apparently puncturing the carotid artery. Central venous catheter was placed in external right jugular through venosection.

Chest x-ray demonstrated pleural effusion. Thoracentesis obtained 45 mL of blood, pleura is sealed and 15 mL/kg transfusion of packed red cells is applied because of hemodynamic instability. Patient entered the Intensive Care Unit (ICU) for close monitoring.

November 12, 2008. Patient presented wheezing and crepitant rales; therefore a viral screening of pleural fluid is requested. Screening results positive for RSV. Pleural sealing is removed after 48 h because of clinical improvement and minimal expense. Total parenteral nutrition was initiated and continued during the patient's hospitalization.

November 13, 2008. Control CT scan demonstrated persistent sinusitis. Patient was sent back to oncology. Laboratory result showed DB 0.23 mg/dL, IB 0.25 mg/dL, T Protein 4.5 g/dL, Alb 1.8 g/dL, ALT 47 U/L, AST 24 U/L, and creatinine 0.3 mg/dL.

November 14, 2008. Patient presented 38.6°C fever. Breathing difficulty continued and patient required additional oxygen. Chest x-ray revealed reticular infiltrate. There was poor evolution of mucositis, possibly associated with herpesvirus or cytomegalovirus. Acyclovir (80 mg/kg/day) was initiated. CT scan showed no evidence of aspergillosis.

November 15, 2008. Poor evolution was attributed to nosocomial pneumonia and postviral pulmonary disease. Bronchoalveolar lavage was carried out to isolate organisms.

November 18, 2008. Hypothermia began 4 days after patient remained eutermic. Persistent breathing difficulty, hypotension and tachycardia improved with 0.9% to 20 mL/kg/dose physiologic solutions. Noninvasive mechanical ventilation was begun, parameters: FiO₂ 50%, FR 25x', IPAP 11, EPAP 5. Patient returned to intensive therapy. CT scan was reviewed, revealing generalized esophageal compromise with mucous edema and periesophageal edema in upper mediastinum and mucous increase. Infectology requested antigenemia for cytomegalovirus, C-reactive protein and indirect immunofluorescence for *Pneumocystis jiroveci*. Ganciclovir was begun and also trimethoprim-sulfamethoxazole (20 mg/kg/day). Acyclovir was empirically suspended.

November 20, 2008. There were isolated hypothermias. Patient presented progressive respiratory deterioration with severe hypoxemia. Patient was intubated and conventional mechanical ventilation was begun, which was insufficient and then switched to high-frequency ventilation.

November 21, 2008. There was relapse of isolated hypothermias and tachycardia continued. Norepinephrine (0.1 µg/kg/min) was given and red cell transfusion was carried out. Milrinone was administered due to poor response. Severe hypoxemia persisted. Chest x-ray showed increased infiltrate and pneumomediastinum. Oncology reported that bone marrow biopsy showed hypocellular bone marrow and negative neoplastic cells. Granulocyte-colony stimulating factor (G-CSF) was begun. Laboratory tests revealed DB 0.1 mg/dL, IB 0.6 mg/dL, T protein 5.4 g/dL, Alb 2.8 g/dL, ALT 119 U/L, AST 76 U/L, and creatinine 0.3 mg/dL.

November 25, 2008. There was hemodynamic improvement. Aminergic support was suspended. Blood showed 5600 leukocytes, 5300 neutrophils. G-CSF was suspended. Hypothermia and one isolated 38.1°C peak after 5 eutermic days. Cytology for bronchial aspiration was negative for fungi and viruses. Cytomegalovirus showed IgG positive, IgM negative, no titers.

November 28, 2008. Patient was transferred to Pediatric Intensive Care Unit (PICU). She presented subcutaneous emphysema, failed to reduce ventilatory parameters, and had persistent thrombocytopenia. Packed platelets were administered every hour. Transitory anisocoria reverted spontaneously. Cranial CT scan was canceled due to hemodynamic and ventilatory instabilities. There were isolated ventricular extrasystoles and arrhythmia. Amiodarone and lidocaine were added. Blood showed BUN 14 mg/dL, creatinine 1.0 mg/dL, glucose 130 mg/dL, Na 132 mEq/L, K 3.8 mEq/L, Cl 98 mEq/L, Ca 7.9 mg/dL, P 2.2 mg/dL, Mg 1.6 mg/dL.

November 29, 2008. There was persistent tachycardia and isolated 38.0°C peak after 4 days without fever. Ventilatory parameters failed to decrease. Blood showed DB 2.79 mg/dL, IB 0.62 mg/dL, T protein 5.8 g/dL, Alb 3.1 g/dL, ALT 227 U/L, AST 229 U/L, and creatinine 0.3 mg/dL.

December 1, 2008. PICU reported widespread edema and disseminated petechiae. There was severe, progressive emphysema involving face, chest and abdomen, absent peristalsis, and persistent tachycardia not associated with fever. There was progressive ventilatory deterioration despite mechanical ventilation management with <84% saturation. Infectology reported cultures without isolated strains, negative cytomegalovirus serological test, and interruption of meropenem, vancomycin and ganciclovir was suggested because it was unnecessary to continue

their administration and their adverse effects. Voriconazole and trimethoprim-sulfamethoxazole were suggested to continue. Laboratory results were DB 5.0 mg/dL, IB 1.06 mg/dL, TB 6.06 mg/dL, T protein 5.1 g/dL, Alb 2.6 g/dL, ALT 295 U/L, AST 111 U/L, LDH 830 U/L, ALP 791 U/L. Gasometry revealed pH 7.27, pCO₂ 55.1 mmHg, pO₂ 33.7 mmHg, SatO₂ 54.1%, BE 1.4 mmol/L, HCO₃ 25 mmol/L, lactate 5.6 mmol/L, A gap 13.9 mmol/L.

December 2, 2008. At 17:00 h, there was bleeding through the endotracheal cannula. Patient presented hypoxemia, hypercapnia, tachycardia and arterial hypotension and finally cardiorespiratory arrest.

During the patient's hospitalization, we took urine culture (1), blood tests (4) and peripheral hemocultures (7), which were reported. During the patient's hospitalization she received 34 packed platelet transfusions, two fresh plasma transfusions and seven red cell transfusions. Evolution and care schema are shown in Figure 1.

CASE DISCUSSION

Dr. Bustos. This is a very interesting case regarding an oncological problem that is relevant even for those who do not work at tertiary care hospitals. Initially, management of

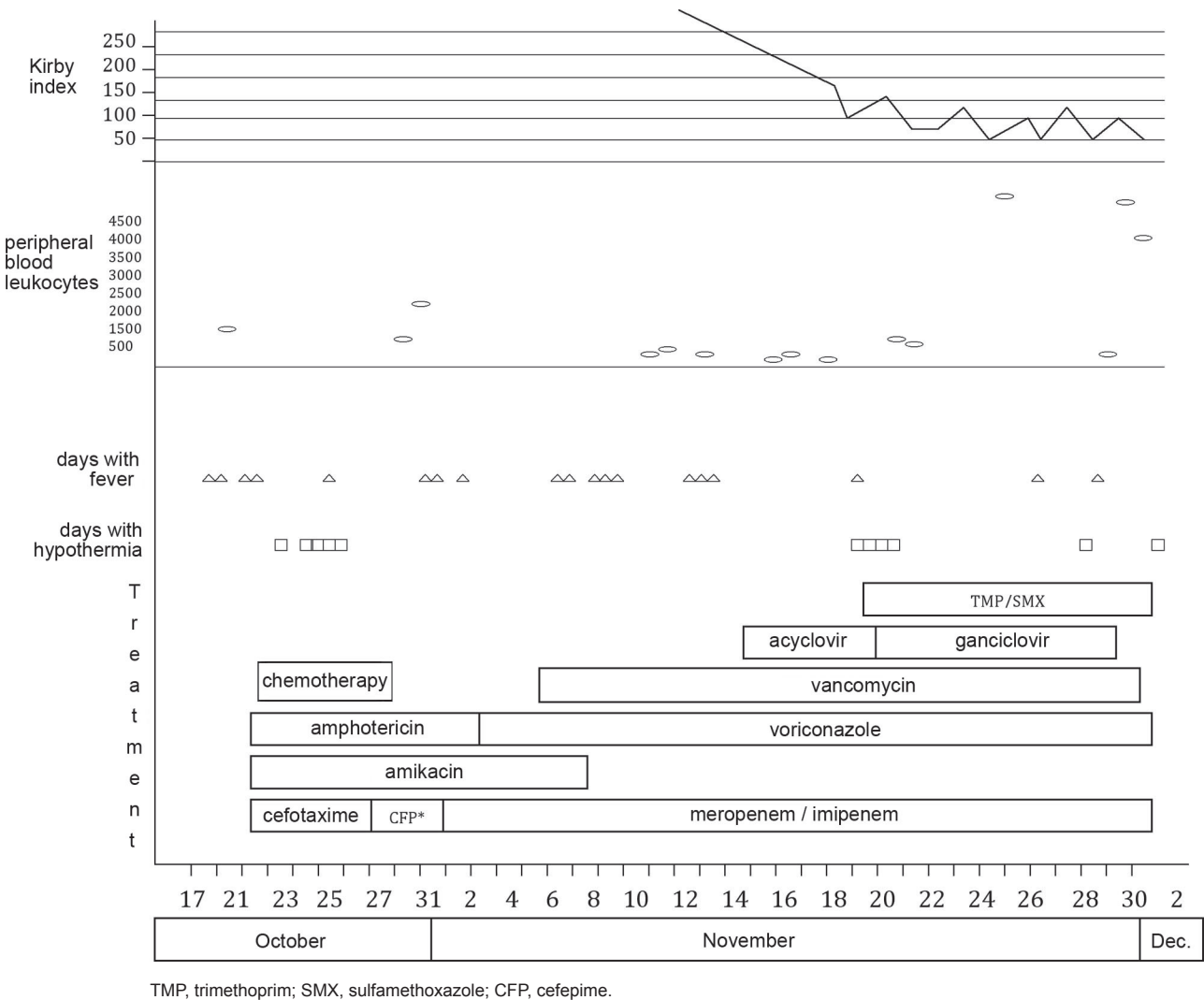


Figure 1. Clinical evolution and treatment.

these cases can be performed at primary and secondary care units. The purpose of this session is to review some alterations associated with oncological therapy, especially pulmonary complications and infections during chemotherapy. Dr. Diana Asia, which patients should we suspect leukemia?

Dr. Diana Asia (2nd year resident, Pediatrics). We should suspect leukemia in patients with initial manifestations of hemorrhagic syndrome (bleeding at any level, petechiae and/or ecchymoses), infiltrative syndrome (visceral growths and adenopathies), fever syndrome and anemic syndrome. A combination of two or more of the above are reason to suspect leukemia.

Dr. Bustos. Dr. Mauricio Cortina: when a patient begins with leukemia symptoms and usually attends primary or secondary care units, the first-contact physician becomes alarmed in general and refers the patient to a specialty hospital. What can we do to ensure the patient will arrive under better conditions?

Dr. Mauricio Cortina. The patient's hematological condition is usually altered and should be assessed to begin with. It may be convenient to apply hemoderivatives in order to stabilize the patient before referring him/her to another care unit. Some neoplasms with high cell-turnover rate may trigger tumor lysis syndrome, which combines two or more of the following alterations: hyperkalemia, hyperphosphatemia, hypocalcemia and hyperuricemia; corrective measures for these alterations should be carried out before transferring the patient. Finally, we should remember that some neoplasms may produce compression because of the size of one or more tumors; it is particularly important to review those in the neck and mediastinum because they may obstruct airways. We must ensure that air supply is not compromised during the transfer.

Dr. Israel Herrera Flores (4th year resident, Pediatric Radiology). We received a chest computed tomography (dated November 13) showing interstitial infiltrate in the parahilar region that becomes more evident at both pulmonary bases (Figure 2). There is also an infiltrate in the right parahilar region extending towards the bases having a "ground glass pattern", which suggests changes from the toxic effects of chemotherapy. Chest x-ray (dated November 21) showed a loosely defined, mixed infiltrate, which evidences interstitial inflammation and fluid/secretions occupying alveoli. Figure 3 shows the above with greater detail and there are evident consolidation images, especially at the ba-

ses. Subsequent radiographs show extended pneumonia images and aerial bronchogram. Between November 29 and 30, we detected bilateral subcutaneous emphysema in thoracic soft tissue that increased gradually (Figures 4 and 5). Afterwards, pneumomediastinum was evident because according to the chest x-ray done on December 1, emphysema had extended to the abdomen and there are images compatible with pneumoperitoneum (Figure 6). The last x-rays showed well-defined, round, radiolucent images without a defined capsule that can be associated with bullae, characteristic of barotrauma. These can eventually break and produce bronchopleural leaks. Diagnoses from imaging were bronchopneumonia, infiltrate compatible with pneumonitis secondary to chemotherapy, images compatible with barotrauma and gas leakage to subcutaneous tissue at mediastinum and peritoneum.

Dr. Bustos. Dr. Herrera, how can images help differentiate pneumonia from pneumonitis secondary to chemotherapy?

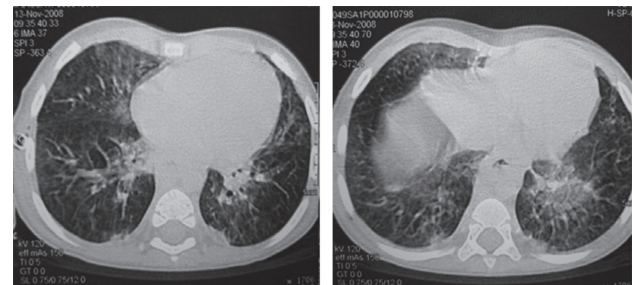


Figure 2. Tomography with pulmonary parenchyma window where diffuse interstitial infiltrate can be identified. "Ground-glass pattern" is present at medial segment of right medial lobe associated with pneumonitis.

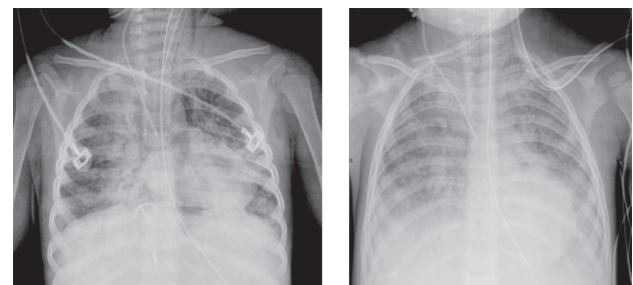


Figure 3. Mixed parahilar infiltrate with right prevalence associated with bronchopneumonia profile (Nov-21-2008 and Nov-27-2008).

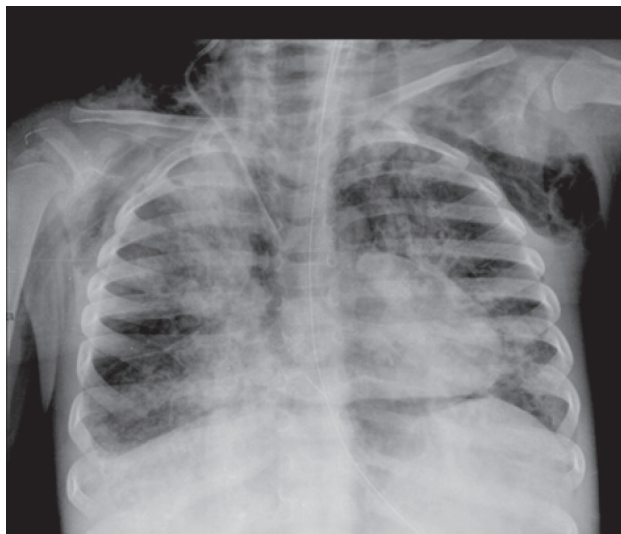


Figure 4. Progressive mixed infiltrate with subcutaneous emphysema towards right axillary region and pneumopericardium (Nov-29-2008).

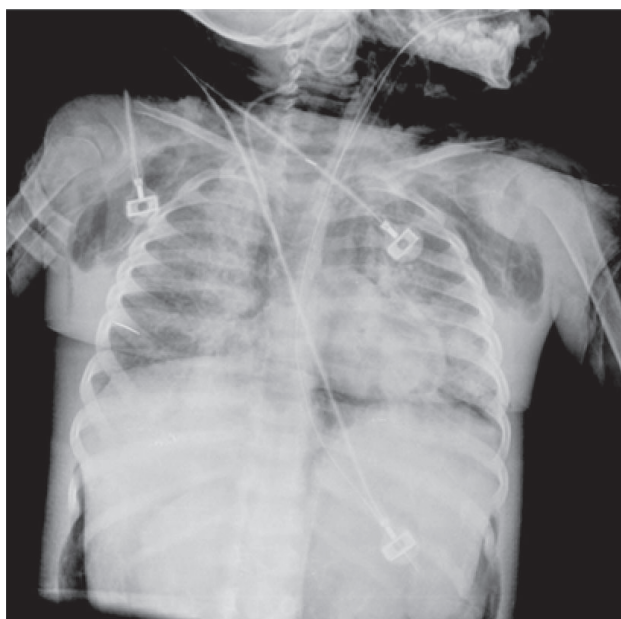

Figure 5. Subcutaneous emphysema towards bilateral axillary region, pneumomediastinum and pneumoperitoneum (Nov-30-2008).

Dr. Herrera. Alveolar infiltrate appears only during infectious processes; on the other hand, interstitial infiltrate can be found in both conditions and it shows the “ground-glass pattern” on pneumonitis from chemotherapy.

Dr. Jose Karam Bachera (Head of Pneumology Dept.). We should keep in mind that there are three classic image types associated with pneumonia: 1) alveolar

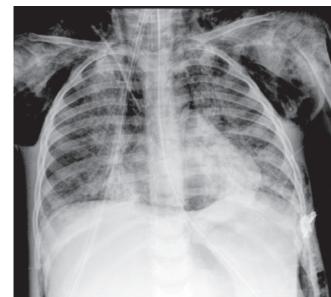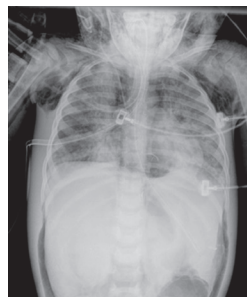


Figure 6. Mixed infiltrate with subcutaneous emphysema, pneumomediastinum and pneumoperitoneum suggesting barotrauma (Dec-01-2008, Dec-02-2008).

infiltrate shows homogeneous images and is characteristic of lobar pneumonia, 2) bilateral parahilar infiltrate also known as bronchopneumonia and 3) interstitial infiltrate, which is usually attributed to viral etiology. This is a mixed case that combines the three image types.

Dr. Elisa Dorantes (Oncology Department). We received a 1 year and 9-month-old female patient at the Hospital Infantil de Mexico Federico Gomez (HIMFG). She was eutrophic with an appropriate weight for age. It is worth mentioning that before being treated at HIMFG, she received a rectal paracetamol dose higher than recommended, which can be associated with hepatic, renal and hematological toxicity. In our patient, this manifested as transaminasemia and cholestasis, both reversible. We should keep in mind that the maximum number of paracetamol doses is 5/24 h. Additionally, when intoxication is suspected, serum levels should be determined and considered toxic when ≥ 200 ng/mL at 4 h or 50 ng/mL at 12 h after administration.¹

At admission, the patient showed infiltrative anemic and hemorrhagic and fever syndromes.

It is worth noting that the patient presented hemodynamic instability symptoms with tachycardia, heart murmur, hepatomegaly and edema that, combined with hemoglobin levels, can be associated with heart failure. All of the above are severe manifestations of anemic syndrome.

As for infiltrative syndrome, she was diagnosed with acute myelomonocytic leukemia (AML-M4) according to FAB classification (French-American-British), based on morphology and histochemical stains.²

According to the World Health Organization (WHO), acute myeloid leukemia is diagnosed when there are $>20\%$ of myeloblasts at bone marrow by determining the

percentage of all medullary nucleated cells and confirming myeloid differentiation with $\geq 3\%$ blasts positive to myeloperoxidase and, of them, $>20\%$ are positive to monocyte nonspecific esterases.³ Flow cytometry immunophenotyping is also required.

The patient also presented hemorrhagic syndrome, frequent in acute myeloid leukemia. In this case, the patient received several platelet transfusions upon admission and during her hospitalization.

At admission, coagulation times were not prolonged; however, it is advisable to evaluate coagulation profile, which includes determination of procoagulation and fibrinolytic system molecules as well as anticoagulant expenditure. There are a number of substances to be determined. We recommend the following: coagulation times (prothrombin time and thromboplastin partial time), fibrinogen, D-dimer and platelet count because patients with myeloid leukemia can present laboratory results compatible with disseminated intravascular coagulation and this represents a hematological emergency to begin an appropriate transfusion program.⁴

As for fever, the patient presented a 1-month evolution syndrome and was diagnosed with neutropenia at admission. According to Pizzo and Poplack, fever due to proinflammatory factors is associated with 60% of acute leukemias; however, 40% of cases have no direct relationship with neoplastic infiltration and, therefore, should be approached as neutropenic fever patients.⁵ Infectious processes are the leading cause of death in up to 80% of acute leukemia patients.

The relationship between neutropenia and infections has been studied in-depth for acute leukemia patients. We know neutropenia and its duration increase the possibility that an infection will threaten the patient's life. Also, these patients present scarcely evident infection signs because they cannot develop an appropriate inflammatory response.⁶

Not all neutropenic patients are at the same risk to develop severe complications when they present fever. Nowadays it is possible to classify them according to risk groups using clinical and laboratory criteria at fever onset. Our patient was considered to be at high risk for developing infectious complications because of a nonreceded hematological neoplasm (LMA M4) and its associated comorbidities, altered hepatic functions and loss of mucocutaneous barriers. In addition, we are aware that these

patients present defects of the phagocytic mononuclear system.⁷

According to international reports, AML M4 is the second most common subtype of acute myeloid leukemias. This is consistent with cases prevalent at HIMFG where AML M4 represents 21% of acute myeloid leukemias.⁸ In this case, chemotherapy was initiated 48 h after antibiotic and antifungal treatments. It is important to highlight that cultures were negative at that point.

The patient received a chemotherapy schema according to findings from the Nordic Society for Paediatric Haematology and Oncology (NOPHO), offering a remission prognosis ~90% for AML children. Of these, ~50% remain disease-free 5 years after diagnosis.⁹ One strategy to achieve remission is the use of intensive polychemotherapy blocks, using cytarabine, anthracycline and epipodophyllotoxin at particularly high cumulative doses. At HIMFG, remission percentage after first chemotherapy cycle is 86%.

The patient demonstrated a torpid evolution after chemotherapy administration because 4 days after antineoplastic drugs were administered, a new gastrointestinal infection began with reduced consistency excretions; therefore, we added an antimicrobial schema.

Systemic inflammatory response and mucositis were documented during the patient's evolution. Therefore, according to current neutropenia and fever guidelines, we added vancomycin. The patient was also diagnosed with respiratory syncytial virus (RSV) in pleural fluid. This seriously compromised lung parenchyma, which was corroborated through several oxygenation index measurements (a rate between arterial O_2 tension and aspired oxygen fraction). When this index began to decrease, it never improved during the patient's hospitalization.

The patient presented hypothermia after 4 days without fever, clinical data compatible with respiratory insufficiency and hemodynamic instability; therefore, she was transferred to intensive care. Respiratory deterioration was progressive because she presented severe hypoxemia and required high-frequency ventilation and aminergic support.

Because of severe neutropenia, the patient was administered granulocyte colony-stimulating factor (G-CSF) after a bone marrow biopsy revealed that the patient was receding. The use of G-CSF factor is not standard for these patients; however, the American Society for Infectious Diseases (ASID) recommends its application under special

conditions where there is torpid evolution and medullary recovery is required. These conditions include pneumonia (as in our patient), hypotension, systemic fungal infections or multiple organ dysfunction secondary to sepsis.

Despite the above, respiratory status was unsatisfactory and this contributed initially to cytomegalovirus detection, which was confirmed negative by serology report.

It is possible that pulmonary damage demonstrated by this patient was associated with medications such as cytarabine, which is similar to cytidine and may become toxic at pulmonary level, producing noncardiogenic pulmonary edema and diffuse interstitial pneumonitis.¹⁰ The patient presented renal damage, showing increased creatinine levels and hepatic damage, increased transaminases and cholestasis, possibly as an adverse effect of medications. Finally, the clinical history describes a generalized deterioration with gradual ventilatory complications that lead to the patient's death.

This case is relevant because of the lack of documentation of infectious agents and possible pulmonary damage from chemotherapy toxicity. This should be a differential diagnosis to be considered during torpid evolution of patients who receive high cytarabine doses and that could be documented by taking biopsies during therapy.

Dr. Victor Olivar Lopez (Head of Emergencies Department). I would like to comment on the ventilatory strategy used with this patient. This case was quite difficult to manage and demanded complicated decisions about the most appropriate ventilatory equipment to be used. It is evident that the use of noninvasive mechanical ventilation is not justified for cases such as this one. It has been demonstrated that when Kirby is <200, the possibilities of respiratory failure or even death increase drastically.¹¹⁻¹³ When we analyze patients like this with acute respiratory failure, mortality rate increases noticeably;¹³ the problem is associated with a delayed invasive mechanical ventilation. I consider that noninvasive mechanical ventilation should have been used for a very short period of time and then switched to invasive mechanical ventilation. The patient was intubated with Kirby = 100, which suggested a severe respiratory compromise. Early use of invasive mechanical ventilation may have improved the outcome on this case.

Dr. Argelia Escobar Sanchez (Pathology Department). This patient was subjected to three biopsies. First, a bone marrow biopsy (2074/2008) that was diagnosed as myelodysplastic hypocellular bone marrow;

cellularity was ~60%-70% as obtained from the proportion of cells vs. adipose tissue. At this point, it was not possible to diagnose acute leukemia, so the patient was diagnosed with myelodysplastic hypocellular bone marrow (Figure 7).

After receiving treatment, the second biopsy was obtained from trabecular bone and periosteum. Unfortunately, it was unsuitable for diagnosis and a third biopsy was obtained. This presented scarce intertrabecular spaces with some elements of myeloid series and erythroid cells and was negative for neoplastic cells. Cytology from bronchial lavage showed no viral or other associated microorganisms.

The patient's weight at the time of death was 9 kg (12 kg expected). External aspect revealed a possible chemosis or left eyelid eversion and some skin petechiae; patient had presented mediastinal emphysema and subcutaneous emphysema extending to genital area (labium majus showed significant subcutaneous emphysema).

We found bilateral pneumothorax in cavities and mediastinal emphysema characterized by visible bubbles as well as abdominal emphysema. We observed hepatomegaly because the liver occupied the entire abdominal cavity. Mediastinal emphysema was perfectly distinguishable at a greater magnification. We included several sections from bone marrow, iliac crest, ribs and vertebrae for analysis. A bone marrow section showed several intertrabecular spaces and another recovered after treatment. These show a cellularity ~70% with some cells that belong to bone marrow. At a higher magnification, we observed that most cells belong to myeloid series with halted maturation. There are others at early developmental stages and from erythroid series. Most cellularity can be attributed to myeloid elements. We observed very scarce mature cells, most were immature and there were scarce megakaryocytes. Immunohistochemical stain showed a large myeloperoxidase area, indicating a prevalence of granulocytes. However, we found negative markers for blasts, CD34, CD117 and CD14, which has a monocyte differentiation like CD56. This means they are immature cells but not neoplastic cells, indicating that the patient presented a recovering bone marrow. I consider that these immature forms are secondary to administration of G-CSF (Figure 8).¹⁴⁻¹⁶

Therefore, the primary disease is M4-myelomonocytic myeloid leukemia in remission.

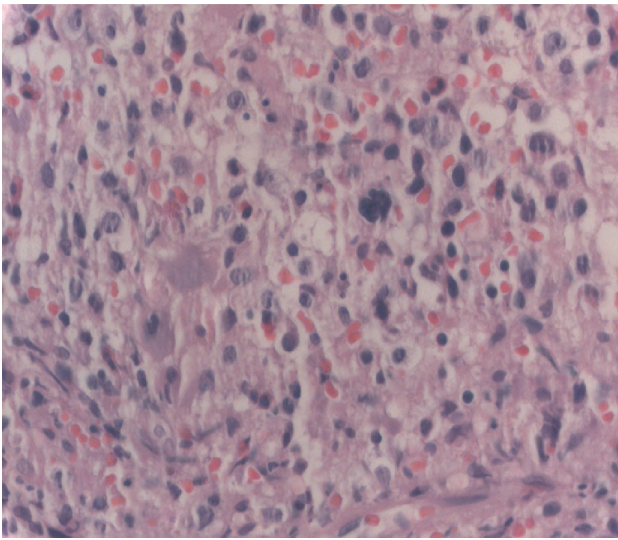


Figure 7. Bone marrow with myelod series dysplasia and scarce megakaryocytes.

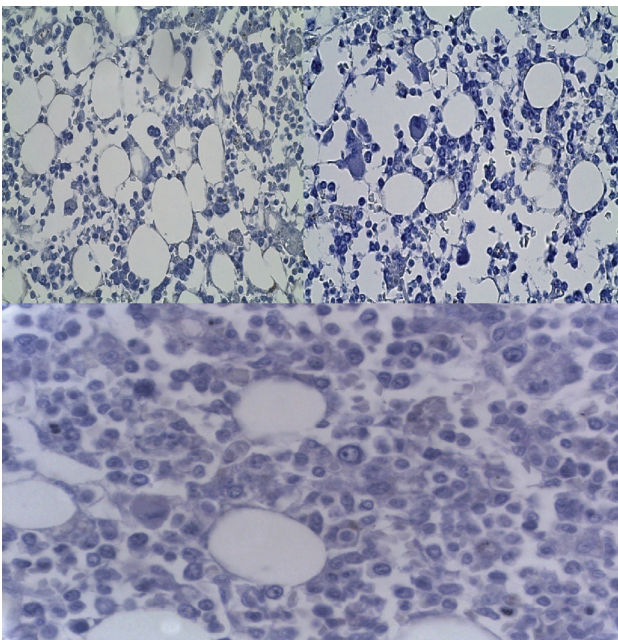


Figure 8. Negative CD34, CD117 y CD14.

The most important findings are corroborated through radiological images and Dr. Dorantes statements. Both lungs had a 250 g weight (130 g expected), and we observed an irregular pleural surface. Section revealed predominant consolidation areas at upper and lower left lobes and medial right lobe where there are consolidation and congestion areas plus increased bronchial tissue.

Histological tests revealed several lesion patterns, so I consider that this patient presented a multifactorial etiology because there were consolidation areas with reduced alveolar spaces, emphysema areas, and organizing pneumonia areas with interstitial prevalence. Masson's trichrome stain was carried out, revealing fibrosis that was not corroborated although there was emphysema. Patient presented intraalveolar edema and incipient development of hyaline membranes.

This clinical picture shows perialveolar inflammatory infiltrate and extensive recent and previous hemorrhagic areas as well as giant multinucleated cells typical of foreign body reaction. We searched intentionally for giant cells with viral inclusion from RSV; however, giant cells showed a random distribution of nuclei that corresponded to foreign-body giant cells and some vacuoles positive to Oil Red O stain. Electronic microscopy sections revealed another picture showing RSV. We observed our sample was negative and carried multiple stains to search for other microorganisms, especially *Pneumocystis jirovecii*. This is a silver stain, gram-negative and PAS and all were negative.¹⁷

Oil Red O staining was positive and vacuoles were from lipophages (Figure 9). There is an extensive vascular lesion, which I consider was important for pulmonary damage. Arteriole lumen is reduced with some being practically occluded. Masson's trichrome stain for elastic fibers showed the same changes. Some arterioles presented calcium deposits, revealing that there were plexiform changes with necrosis and repair through dystrophic calcification.

All these findings help us to conclude that this patient suffered multiple pulmonary alterations, possibly a lipoid pneumonia (endogenous or exogenous) because of multiple bronchoaspiration events or an endogenous pneumonia secondary to administered medications. I believe that the patient presented infection sequelae, although RSV could not be documented at the time of death. I find that we have the necessary elements to associate pulmonary alterations to toxic effects of cytarabine such as edema, pulmonary vascular disease, alveolar damage and hemorrhage. I would like to comment that patterns associated with chemotherapy patients include pulmonary edema, organizing pneumonia and recent and previous hemorrhages, which were observed in our patient. As previously noted, pulmonary vascular disease in this patient seemed to be secondary to chemotherapy. There are several drugs

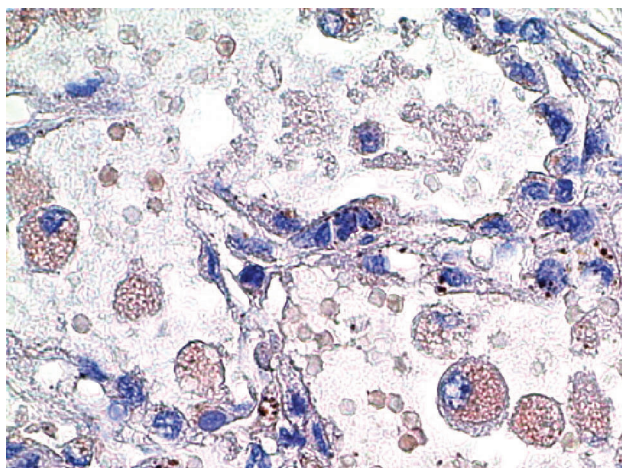


Figure 9. Oil Red O stain positive to lipophages.

that can produce pulmonary lesion such as alkylating agents and methotrexate. Pulmonary toxicity in children is usually associated with dose administered. This is different from adult reactions where it seems to be an idiosyncratic reaction. There are several reports for adults, but reports for children are scarce, even though it is well known that cytosine arabinoside may produce these lesions.¹⁷

Other findings show that the spleen cut revealed a lymphoid tissue infarction with important depletion as a result of intense chemotherapy. The best-preserved areas show reduced lymphoid tissue and iron deposits.

Periaortic, peritracheal and peribronchial lymph nodes are small and show a significant lymphoid tissue decrease. It is difficult to distinguish medulla from cortex and paracortical areas. Thymus showed epithelial calcification and reduced lymphoid tissue. It is worth mentioning that no other organs presented neoplastic evidence.

Liver presented a weight of 800 g (380 g expected), occupied the entire abdominal cavity and had a light green color. At microscopic level, liver structure was preserved but presented panlobular steatosis and macrovesicular panlobular steatosis, possibly secondary to drug administration and intracytoplasmic cholestasis. The patient suffered from malnutrition and received parenteral nutrition. There were granulocytes at portal spaces and immunohistochemical stains revealed mature cells. We searched for hemophagocytosis because leukemia produces alterations in mononuclear phagocytic system and found no evidence of hemophagocytosis in organs. We found an ulcer of the digestive tract confirmed by muco-

sitis. We carried out special stains and found no evidence of yeasts or herpes. Considering that the patient had pneumonia with multinucleated giant cells, we searched for reflux data and found no esophagitis secondary to reflux.

Small intestine and colon presented a macroscopically integral mucous and we found no microscopic data for colitis or enteritis. We only observed contraction bands, which were evident as a final outcome from shock. Therefore, the patient presented hepatomegaly, macrovesicular panlobular steatosis and acute ulcerated esophagitis.

Kidneys presented a weight according to expected, medulla-cortex relationship was well preserved and there was congestion at bladder mucosa. Different sections showed no glomerular alterations and there was bile pigment within the tubules of the lumen. There were data of tubular necrosis. At higher magnification we observed pigment. There was no evidence of neoplastic cell infiltration.

In the central nervous system, brain had a 980 g weight (1059 g expected) with congestion from convexity and microscopic data of neuronal hypoxia. These findings are secondary to shock (Figure 10).

Postmortem cultures showed the following: positive hemoculture for *Enterococcus faecium* and *Staphylococcus epidermidis*; *Sphingomonas paucimobilis* at spleen and two gram negative, nonfermenting bacilli morphotypes.

In summary, this patient presented acute myelomonocytic leukemia at remission. She also presented multifactorial pulmonary damage associated with cytarabine toxicity and hepatic damage secondary to administered drugs.

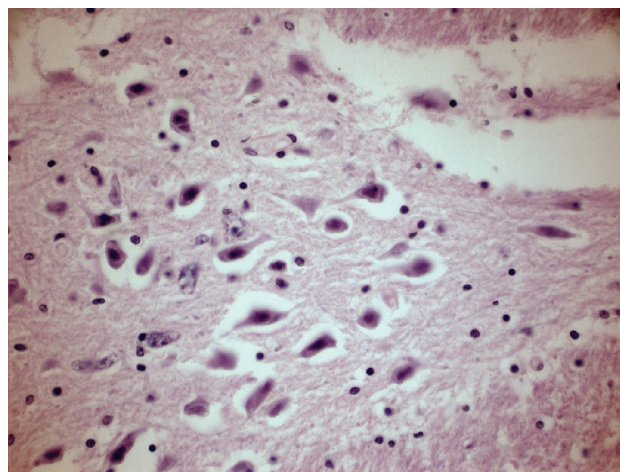


Figure 10. Neurons with hypoxia (shock).

Dr. Bustos. Without a doubt, this case was very difficult to manage and exemplifies a frequent situation in oncological patients where chemotherapy is very effective but implies a very high cost because it produces extensive damage at different levels along with complications that lead to this patient's death. We must continue learning about possible pulmonary damage secondary to chemotherapy.

Dr. Jose Luis Lezana Fernandez (Pulmonary Physiology). Infiltrative lung disease is one of the most frequently induced respiratory diseases by medications. It is present in 10%-30% of patients who receive chemotherapy and manifests as interstitial damage, alveolar damage or both. Multiple agents used in chemotherapy are able to produce pulmonary damage. The most common onset is diffuse interstitial pneumonitis with the subsequent development of pulmonary fibrosis; however, other syndromes include hypersensitivity lung disease (eosinophilic pneumonia), acute respiratory distress syndrome, diffuse alveolar damage, noncardiogenic pulmonary edema, alveolar hemorrhages and bronchiolitis obliterans.^{18,19}

Lung disease associated with different chemotherapy agents usually depends on doses, but it is also associated with patient's idiosyncrasies to certain drugs and genetic factors. Risk factors associated with the development of lung disease include cumulative dose, use of multiple toxic drugs, concomitant radiotherapy, oxygen requirements and patient's age.²⁰

Clinical profile onset can be acute or gradually settle between 1 and 28 days, usually presenting cough, dyspnea, breathing difficulty and hypoxemia. Chest x-ray revealed an interstitial infiltrate with or without occupying alveolar air space. The diagnostic approach should include a respiratory function test (children >6 years old) showing a reduced diffusion lung capacity for carbon monoxide (DLCO) without initial changes on flows and volumes; however, a restrictive pattern may develop at later stages compromising life. Diagnostic approach should include a bronchoalveolar lavage for cytology tests where there are an increased number of lymphocytes, eosinophils or a reduced CD4/CD8 ratio. Also, this should include microbiology and virology tests to rule out other causes of pulmonary damage.²⁰

Differential diagnosis includes malignant infiltration (leukemias), infectious pneumonitis (CMV, *Pneumocystis jirovecii*), diffuse alveolar hemorrhage or lung damage produced by radiation.²⁰

There are several mechanisms associated with pulmonary damage induced by medications such as the following: a) cellular dysfunction and apoptosis, b) changes in tissue and cell repair mechanisms, c) neutrophil migration, and d) oxidative damage. Each one of these may be present alone, although it is common for pulmonary damage to be associated with a combination of these.¹⁸⁻²⁰

Apoptosis activation seems to play an important role in pulmonary restructuring after acute pulmonary damage, to clear mesenchymatic epithelial cells at lesion. Type II pneumocytes are responsible to rebuild epithelium and restore alveolar structure. During the lung damage process, these cells usually divide and differentiate into Type I alveolar cells. Activation of apoptosis follows two paths: chiefly 1) death of cell membrane receptor and 2) mitochondrial pathway. These pathways are closely connected with cysteine protease pathways and may activate enzyme degradation, which destroys cells.¹⁸⁻²⁰ Apoptotic stimuli increase mitochondrial membrane permeability, which releases cytochrome C that, in turn, activates cysteine protease pathway leading to cellular death.

Alterations in cell and tissue repair mechanisms are associated with the production of growth factors, both tissue and vascular, expressed on bronchial epithelium basal membrane through proliferation of fibroblasts and in collagen deposits required for tissue repair.¹⁸⁻²⁰

Patients who receive chemotherapy usually experience an initial massive migration of neutrophils to airways with the subsequent release of proteolytic enzymes and cytokines, inducing a capillary blocking syndrome and acute pulmonary damage. Some studies suggest the concomitant use of G-CSF in septic patients, increasing the number of neutrophils and, therefore, a larger migration of these to lung tissue, which increases damage.¹⁸⁻²¹

Reactive oxygen species generated during phagocyte activation lead to fatty acid oxidation, myeloperoxidation, cellular membrane distress and cellular death. This damages Type I pneumocytes and capillary endothelium, which initiates an inflammatory process.¹⁸⁻²⁰

This case shows clear evidence of the development of an infiltrative lung disease with alveolar and interstitial damage, development of noncardiogenic pulmonary edema and alteration of lung vascular structure, which represent several lesion mechanisms possibly attributed to Ara-C.²¹⁻²³ It is essential to have an early diagnosis and the use of methylprednisolone, although mortality is still high.

Dr. Bustos. I ask Dr. Olga Martínez Pantaleón for her comments on the amount of medications administered to this patient, considering their toxicity and their pharmacological interactions.

Dr. Olga B. Martínez Pantaleón (Toxicologist, Emergency Department). The increasing number of oncological diseases is associated with the design of new drugs and pharmacotherapies, which has allowed the improvement in life expectancy. However, medications can produce other medical problems. It is important to consider this patient's evolution as an Adverse Drug Event (ADE), which is little acknowledged within the medical environment and produces prolonged hospitalization and even death.²⁴

At the present time, studies on medications are oriented towards testing their effectiveness, without consideration of patient safety while receiving them, along with adverse effects. Medication interactions and lack of adherence are scarcely detected, leading to drug ineffectiveness; therefore, it is important to encourage the rational use of medications.

In 2008, the Emergency Department reviewed 230 files in 3 months from patients who were admitted to the Emergency Department. We found that 10.4% of them were admitted because of ADR and another 10.4% presented ADR during hospitalization.²⁵ Physicians should always be aware of hospital pharmacovigilance programs and their therapeutic goal to administer medications with patient safety and effectiveness.

Dr. Bustos. It is important to comment on the infectious aspects in this case. Infectious complications in patients are very frequent and their management is difficult. While analyzing this case, we perceive an upward spiral where the patient received several antimicrobial schemes because of relapsing fever, reaching broad-spectrum antimicrobial therapies. However, we have the impression that she never received the appropriate schema.

Dr. Sarbelio Moreno Espinoza (Head of Infectology Department). We currently tend to overuse broad-spectrum antibiotics and antifungal drugs so that our patients do not become infected or to stabilize their infections. This was not the case for our patient. Preventive antifungal therapy is justified in patients who have a high risk to become infected by fungus due to a deteriorated immunological system. I completely agree with Dr. Dorantes: this patient has particular characteristics such as leukemia type, high

ablative chemotherapy administered at high doses, which justified spiraling antibiotic scheme.

Regarding RSV infection, it is interesting that in this case it occurred at this time of the year, even though the international literature describes this as a winter entity. It seems that its behavior is different in Mexico. There are three reports from studies carried out in Mexico City: first, a community study where HIMFG participated,²⁶ second, a thesis that reported nosocomial transmission²⁷ and third, a report from HIMFG patients with a prevalence of cases during autumn (such as this case).²⁸ The importance of this has influenced the use of preventive measures proposed for susceptible hosts, such as the use of monoclonal antibodies during winter and perhaps they should be adapted to our situation.

Pulmonary damage described by Dr. Lezana can be applied to immunocompromised patients, but it is important to highlight that acute changes that occur with these types of patients are different. In this case, there is a prevalence of focal interstitial infiltrates, sometimes associated with lobar consolidation and extensive tissue damage, even resembling acute respiratory distress syndrome, which agrees with observations collected from influenza patients during the last outbreak.

Dr. Bustos. Some of the comments received mention the possibility of fever secondary to antibiotics. Can you please provide your point of view?

Dr. Moreno. This concept can be applied to fever that occurs only during medication administration and recedes when therapy is stopped. According to Rawlins and Thompson classification, fever secondary to medications can be classified as A (predictable), which can affect any individual, and B (unpredictable), which occurs only in susceptible individuals. This is an exclusion diagnosis and is suspected when there is no clinical or paraclinical evidence of infectious or noninfectious processes that can explain fever. This situation is not associated with the case presented here.

Dr. Olivar. I think alveolar aspiration received too much attention and this process generally shows very low precision, even more if we consider that the patient required high positive pressures. The patient should have been subjected to bronchial brushing with an appropriate technique or even pulmonary biopsy at an early stage when the problem was first suspected and not when the patient had greatly deteriorated.

Dr. Bustos. We reviewed the case of a female patient with an oncological problem and who was subjected to chemotherapy. Her base problem was controlled but she experienced severe complications, highlighting infectious and pulmonary complications that led to her death. Those of us who treat oncological patients should develop new and highly effective strategies to face complications of new cancer therapies.

REFERENCES

1. Taketomo CK, Hoddind JH, Krauss DM. Manual de prescripción pediátrica. USA: Lexi-Comp Inc; 2004. p. 30.
2. Xie Y, Davies SM, Xiang Y, Robinson LL, Ross JA. Trends in leukemia incidence and survival in the United States (1973-1998). *Cancer* 2003;97:2229-2235.
3. Rubnitz JE, Gibson B, Smith FO. Acute myeloid leukemia. *Pediatr Clin North Am* 2008;55:21-51.
4. Arcenci RJ, Hann IM, Smith OP. Pediatric Hematology. Reading, MA, USA: Blackwell; 2006. pp. 624-642.
5. Pizzo PA, Poplack DG. Principles and Practice of Pediatric Oncology. Philadelphia: Lippincott Williams & Wilkins; 2006. pp. 538-590.
6. Rolston KV. The Infectious Diseases Society of America 2002 guidelines for the use of antimicrobial agents in patients with cancer and neutropenia: salient features and comments. *Clin Infect Dis* 2004;39(suppl 1):S44-S48.
7. Ammann RA, Hirt A, Luthy AR, Aebi C. Predicting bacteremia in children with fever and chemotherapy-induced neutropenia. *Pediatr Infect Dis J* 2004;23:61-67.
8. Bojórquez Steffani L. Asociación entre el inmunofenotipo al diagnóstico en pacientes con leucemia mieloide aguda infantil y el curso clínico de la enfermedad. Tesis para obtener el grado de Oncóloga Pediatra. Hospital Infantil de México Federico Gómez. México, D.F.; 2010.
9. Lie SO, Abrahamsson J, Clausen N, Forestier E, Hasle H, Hovi L, et al. Long term results in children with AML: NOPHO-AML Study Group—report of three consecutive trials. *Leukemia* 2005;19:2090-2100.
10. Chabner B, Longo DL. Cancer Chemotherapy and Biotherapy. Principles and Practice. Philadelphia: Lippincott Williams & Wilkins; 2006. pp. 183-204.
11. Esteban A, Frutos-Vivar F, Ferguson ND, Arabi Y, Apezteguía A, González M, et al. Non-invasive positive-pressure ventilation for respiratory failure after extubation. *N Engl J Med* 2004;350:2452-2460.
12. Antonelli M, Conti G, Rocco M, Bufi M, De Blasi RA, Vivino G, et al. A comparison of noninvasive positive-pressure ventilation and conventional mechanical ventilation in patients with acute respiratory failure. *N Engl J Med* 1998;339:429-435.
13. Ferrer M, Esquinas A, León M, González G, Alarcón A, Torres A. Noninvasive ventilation in severe hypoxemic respiratory failure. *Am J Respir Crit Care* 2003;168:1438-1444.
14. Hsi ED. Hematopathology: A Volume in Foundations in Diagnostic Pathology Series. Philadelphia: Churchill Livingstone/Elsevier; 2007. pp. 397-445.
15. Foucar K, Viswanatha D, Wilson SC. Non-Neoplastic Disorders of Bone Marrow (Atlas of Nontumor Pathology V.6). American Registry of Pathology; 2008. pp. 1-37.
16. Swerdlow S, Campo E, Lee Harris N, Jaffe E, Pileri SA, Stein H, et al. WHO Classification of Tumours of Haematopoietic and Lymphoid Tissues. World Health Organization; 2008.
17. Travis WD, Colby TV, Koss MN, Rosado de Chistenson MI, Müller NL, King TE Jr. Non-Neoplastic Disorders of the Lower Respiratory Tract (Atlas of Nontumor Pathology V. 2). American Registry of Pathology; 2001. pp. 321-340.
18. Dimopoulou I, Bamias A, Lyberopoulos P, Dimopoulos MA. Pulmonary toxicity from novel antineoplastic agents. *Ann Oncol* 2006;17:372-379.
19. Charpidou AG, Gkiozos I, Tsimpoukis S, Apostolaki D, Dilana KD, Karapanagiotou EM, et al. Therapy-induced toxicity of the lungs: an overview. *Anticancer Res* 2009;29:631-639.
20. Camus PH, Foucher P, Bonniaud PH, Ask K. Drug-induced infiltrative lung disease. *Eur Respir J* 2001;18(suppl):93s-100s.
21. Briasoulis A, Pavlidis M. Noncardiogenic pulmonary edema: an unusual and serious complication of anticancer therapy. *Oncologist* 2001;6:153-161.
22. Shearer P, Katz J, Bozeman P, Jenkins J, Laver J, Krance R, et al. Pulmonary insufficiency complicating therapy with high dose cytosine arabinoside in five pediatric patients with relapsed acute myelogenous leucemia. *Cancer* 1994;74:1953-1958.
23. Andersson BS, Cogan BM, Keating MJ, Estey EH, McCredie KB, Freireich EJ. Subacute pulmonary failure complicating therapy with high-dose Ara-C in acute leukemia. *Cancer* 1985;56:2181-2184.
24. Tune-Valls L, García-Peláez M, López-Sánchez S, Serra-Soler G, Aranda GA, Irala IC, et al. Problemas relacionados con los medicamentos en pacientes que visitan un servicio de urgencias. *Pharm Care Esp* 2000;2:177-192.
25. Quintana BG, Viso GF. Evaluación de los problemas relacionados con los medicamentos en el Departamento de Urgencias del Hospital Infantil de México Federico Gómez. Tesis de Licenciatura de la UAEH. Área Académica de Farmacia. Hospital Infantil de México Federico Gómez. México, D.F.; 2009.
26. Pimentel C, López X, Bustamante F, Moreno S, Muñoz T, Sierra J, et al. Epidemiología de las IRAs en una cohorte de niños menores de 2 años. Reunión Anual de Investigación. México, D.F.: Hospital Infantil de México Federico Gómez; 2000.
27. De la Rosa-Zamboni D. Incidencia y patrón estacional de virus respiratorios en pacientes con neumonía que requieren hospitalización. Tesis para obtener el título de Subespecialista en Infectología Clínica. FM-UNAM. Instituto Nacional de Ciencias Médicas y Nutrición Salvador Zubirán. México, D.F.; 2007.
28. Rodríguez-Ahuad JP. Características clínicas y epidemiológicas de la infección por virus sincitial respiratorio en pacientes pediátricos atendidos en un hospital de alta especialidad. Tesis para obtener el título de Subespecialista en Infectología Pediátrica. Hospital Infantil de México Federico Gómez. México, D.F.; 2010.