Acta Ortopédica Mexicana 2026; 40(3): May.-Jun. 201-208

Surgical technique

doi: 10.35366/123292

# Managing discoid lateral meniscus in children and adolescents: a review of recent advances

*Manejo del menisco discoide lateral en niños y adolescentes: una revisión de los avances recientes*

Masquijo JJ,* Pedraza-Corbi A‡

Sanatorio Allende, Córdoba, Argentina.

**ABSTRACT.** Discoid lateral meniscus (DLM) is a structural anomaly characterized by an increased volume and altered collagen fibers, primarily affecting the lateral meniscus. Although its incidence varies, DLM is often present in the pediatric population and may present with acute or chronic knee symptoms, such as joint line pain, mechanical symptoms, and the inability to achieve terminal extension. Diagnosis is typically confirmed through magnetic resonance imaging and clinical evaluation. Histological studies have revealed disorganization and decreased collagen density in DLM, predisposing it to tears and instability. Various classification systems exist, with recent advancements focusing on meniscal width, height, stability, and tears, to guide treatment decisions. Conservative management is suitable for asymptomatic cases, whereas symptomatic patients may benefit from saucerization to restore meniscal function. Surgical intervention, including saucerization and repair, is indicated in cases of peripheral instability or tears. Additionally, addressing mechanical axis deviations in skeletally immature patients is crucial for optimizing the outcomes. This review provides insights into the pathogenesis, classification, and treatment strategies of DLM in children and adolescents.

**Keywords:** meniscus, discoid, children, meniscal preservation, saucerization, guided growth.

**RESUMEN.** El menisco discoide lateral (MDL) es una anomalía estructural que se caracteriza por un aumento de volumen y alteración de las fibras de colágeno, afectando principalmente al menisco lateral. Aunque su incidencia varía, el MDL se presenta con frecuencia en la población pediátrica y puede presentarse con síntomas agudos o crónicos de rodilla, como dolor en la línea articular, síntomas mecánicos e incapacidad para lograr la extensión terminal. El diagnóstico se confirma generalmente mediante resonancia magnética y evaluación clínica. Los estudios histológicos han revelado desorganización y disminución de la densidad de colágeno en el MDL, lo que predispone a desgarros e inestabilidad. Existen diversos sistemas de clasificación, con avances recientes centrados en la anchura, la altura, la estabilidad y los desgarros del menisco, para orientar las decisiones terapéuticas. El tratamiento conservador es adecuado para casos asintomáticos, mientras que los pacientes sintomáticos pueden beneficiarse de la saucerización para restaurar la función meniscal. La intervención quirúrgica, que incluye saucerización y reparación, está indicada en casos de inestabilidad periférica o desgarros. Además, abordar las desviaciones del eje mecánico en pacientes con esqueleto inmaduro es crucial para optimizar los resultados. Esta revisión proporciona información sobre la patogénesis, la clasificación y las estrategias de tratamiento de la MDL en niños y adolescentes.

**Palabras clave:** menisco, discoide, niños, preservación meniscal, saucerización, crecimiento guiado.

**Level of evidence: V**

* Department of Pediatric Orthopedics and Traumatology, Sanatorio Allende. Córdoba, Argentina.
‡ Hospital Universitario y Politécnico La Fe de Valencia. Valencia, España.

*Correspondence:*
Dr. Javier Masquijo
Independencia 757, 1st Floor, Córdoba.
**E-mail:** jmasquijo@gmail.com

*Received: 11-14-2024. Accepted: 02-01-2025.*

**How to cite:** Masquijo JJ, Pedraza-Corbi A. Managing discoid lateral meniscus in children and adolescents: a review of recent advances. Acta Ortop Mex. 2026; 40(3): 201-208. https://dx.doi.org/10.35366/123292

**Abbreviations:**
DLM = discoid lateral meniscus
MRI = magnetic resonance imaging
PRI = peripheral rim instability
PRISM = Pediatric Research in Sports Medicine

## Introduction

Discoid lateral meniscus (DLM) is a structural alteration characterized by increased volume and decreased and disorganized collagen fibers affecting its shape and stability, predisposing it to tears at an early age.[1] The frequency of presentation varies from 0.4 to 20%[2] and is almost exclusively located in the lateral meniscus *(Figure 1)*. This condition can be incidentally detected in asymptomatic patients or presents with mechanical symptoms (pain, swelling, joint catching, and locking). Magnetic resonance imaging (MRI) is an important diagnostic tool that, combined with clinical characteristics, confirms the diagnosis, analyzes meniscal morphology and the presence of associated tears, and evaluates signs of peripheral rim instability (PRI). PRI occurs due to acute or chronic meniscocapsular junction tears or abnormal, attenuated, or absent meniscocapsular attachments of the discoid meniscus and is postulated to occur in areas of higher stress.[3,4] If the rim can be everted or translated to the other half of the tibial plateau after saucerization, it is considered unstable.[5] The incidence of rim instability in pediatric patients has variable rates in the existing literature, from 28 to 77%.[2,3,5] In a recent study that assessed 470 patients,[6] rim instability was identified in 49% of the cohort. The same authors observed a higher prevalence of rim instability in the younger age group (< 14 years), particularly among those with complete discoid meniscus variants. Regarding the type of instability, a slightly elevated incidence of anterior instability was noted in patients over 14 years of age, contrasting with a predominance of posterior instability in the younger age group.

## Histology and pathogenesis

The etiology of discoid meniscus is still not fully understood, and several theories have been proposed. Smillie, in the 1940s, proposed the theory that the discoid lateral meniscus is a normal fetal developmental stage in which the central area of the cartilage plate fails to resorb.[7] However, embryological studies have shown that the lateral meniscus does not have a discoid shape during development,[8,9] and histological findings suggest that the discoid shape of the meniscus may be a pathological entity. Atay et al.[10] conducted a study examining partial thickness biopsies of symptomatic discoid lateral menisci. These results revealed that a highly organized collagen matrix was not present in DLM. The collagen fibers were disorganized and decreased in number, and the collagen concentration was low. These factors contribute to a decrease in the ability of the meniscus to act as a stress absorber, similar to that observed in adult patients with degenerated menisci. Papadopoulos et al.[11] conducted a histomorphological study of the discoid lateral meniscus, taking samples during arthroscopy. They found no significant difference in the architecture of the radially arranged collagen. However, there was significant distortion of circumferential fibers, especially throughout the height of the anterior and posterior thirds and in the middle and posterior thirds of the discoid meniscus near the tibial surface. In addition, the posterior third showed signs of extensive myxoid degeneration and bone metaplasia. Choi et al., in their transmission electron microscopy study, also mentioned low density and disorganization in the ultrastructure of collagen in the discoid lateral meniscus, which may lead to meniscal tears.[12] The absence of proper meniscofemoral insertion and changes in meniscal vascularization may also be involved in this malformation.[13] In summary, DLM represents a spectrum with high variability in collagen architecture density and disorganization, vascularization, and peripheral

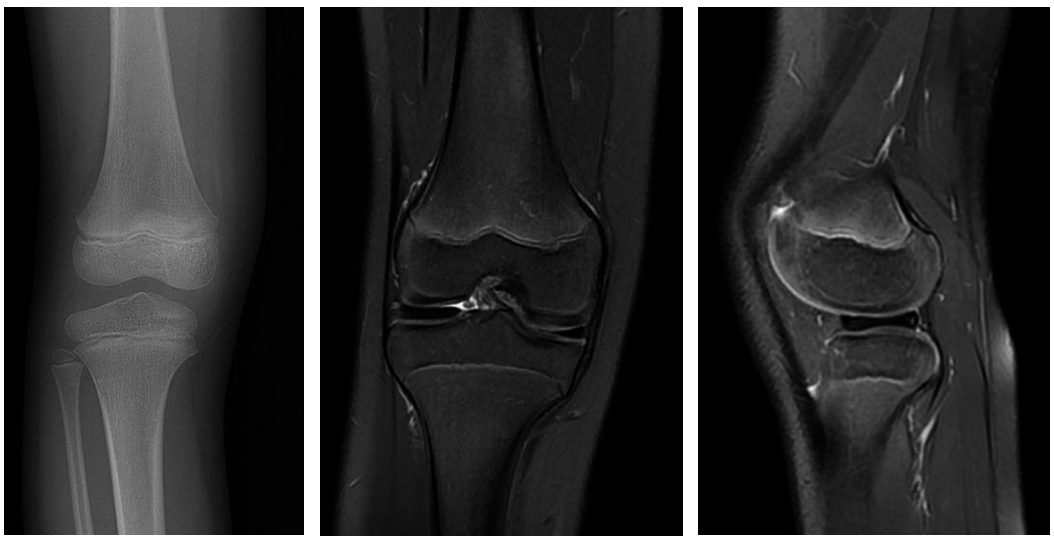

**Figure 1:**

Anteroposterior radiograph, and coronal/sagittal MRI slices of a lateral discoid meniscus without evidence of tears or peripheral instability.

insertions, which predispose patients to tears to a greater or lesser extent, occurring with or without traumatic events.

## Classification

Watanabe and Ikeuchi proposed the most commonly used classification in 1969.[14] The authors classified DLM into three types based on arthroscopic findings. Type I refers to complete and stable DLM that covers the entire lateral tibial plateau. Type II is a stable partial DLM, covering up to 80% of the tibia. Type III DLM is unstable because it lacks menisco-tibial insertions and is probe-displaceable. This variant is also called the Wrisberg type because the Wrisberg posterior meniscofemoral ligament is the only posterior anchor. Although this classification system is the most mentioned in the literature, it has certain limitations, as it does not differentiate DLM with or without tears and does not provide any guidance for management or prognosis. Klingele et al., in a series of symptomatic DLMs, found that hypermobility due to peripheral rim instability was nearly 28%.[15] The authors established that it could be found in both complete and incomplete discoid menisci, and could be located in the anterior or posterior horn. Accordingly, Good et al.[5] proposed a new classification system. They recommended classifying DLMs as either complete or incomplete. Additionally, these could be subclassified as stable or unstable, and this instability could be anterior or posterior depending on the location. Furthermore, tears in the meniscal body should be noted. This classification is useful for making surgical decisions and formulating treatment strategies. Ahn et al. proposed an MRI-based classification to help surgeons choose treatment methods in symptomatic DLMs, based on the type of meniscal «displacement» due to peripheral capsular detachments.[3] The described types were without displacement (no capsular detachment), anterocentral displacement (posterior horn detachment), posterocentral displacement (anterior horn detachment), and central displacement (posterolateral detachment with displacement of the entire meniscus). More recently, a study group from the Pediatric Research in Sports Medicine (PRISM) society developed a classification system through a comprehensive review of existing classification systems, followed by a consensus method of the expert group. This classification includes four main characteristics: meniscal width, meniscal height, peripheral stability, and meniscal tear[16] *(Table 1)*.

**Treatment:** the current algorithm used by the authors is illustrated in *Figure 2*.

### Asymptomatic

Patients incidentally diagnosed with a discoid meniscus on MRI examination in the absence of symptoms do not require formal treatment. However, close follow-up is recommended to monitor symptom development.

**Table 1: PRiSM (Pediatric Research in Sports Medicine) classification system for lateral discoid meniscus.[17]**

| Component | Description |
|---|---|
| Width | |
| W0 | Normal |
| W1 | Incomplete, wider than normal, covering < 90% of the tibial plateau |
| W2 | Almost complete/full, covering ≥ 90% of the tibial plateau |
| Height | |
| H0 | Normal, similar to a normal meniscus |
| H1 | Abnormal, greater than a normal meniscus |
| Instability | |
| S0 | Normal stability |
| SA | Abnormal stability in the anterior half of the meniscus |
| SP | Abnormal stability in the posterior half of the meniscus |
| SAP | Abnormal stability in the anterior and posterior meniscus |
| Tear type | |
| T0 | No tear or tear in the central/flatten zone |
| THA | Horizontal in the anterior half |
| THP | Degenerative/complex/radial |
| THAP | Tear location |
| TDA | Radial, complex, or degenerative tear in the anterior half |
| TDP | Radial, complex, or degenerative tear in the posterior half |
| TDAP | Radial, complex, or degenerative tear in the anterior and posterior halves |

### Symptomatic without tears

While the vast majority of patients presenting with symptoms have meniscal tears, there is a subgroup that may experience joint catching, a locking sensation, or even pain without findings of tears on MRI. The initial treatment for these patients should be conservative. Preserving meniscal function is important; therefore, saucerization should be reserved for cases that remain symptomatic after a period of rehabilitation. The goal of saucerization is to create a more normal-functioning meniscus with sufficient tissue to absorb the load *(Figure 3)*. This treatment allows for satisfactory short- and medium-term outcomes.[17,18] While it is traditionally recommended to preserve a peripheral rim of 6-8 mm on the lateral meniscus, there is currently controversy regarding the amount of residual tissue that should be preserved. This recommendation has been applied without considering the patient's age or knee size, and lacks support from long-term clinical observations and biomechanical studies. Studies on cadavers of pediatric patients have shown that meniscal width progressively increases with patient age,[19] and a width of at least 10 mm is considered normal for eight-year-olds and at least 15 mm for adolescents.[20] Recent clinical research has revealed that a residual width of 6-8 mm for the lateral meniscus may be insufficient and may increase the risk of meniscal extrusion and lateral femoral condyle osteochondritis dissecans.[21,22]

Liu et al.[23] conducted a study using a finite element model of the knee and observed that when the residual width of the lateral meniscus exceeded 12 mm, there were no significant changes in maximum stress at the knee joint compared to preoperative levels. However, decreasing the width from 12 to 8 mm resulted in a slight increase in peak contact stress. When the width was reduced from 8 to 0 mm, the peak contact stress significantly increased. These findings are supported by a similar study conducted in pediatric patients.[24] This research suggests that it is important to consider a residual width greater than 10 mm to avoid complications and preserve proper knee function in patients with a discoid lateral meniscus.

## Symptomatic tears or peripheral instability

Patients with a discoid lateral meniscus who experience mechanical symptoms often present with intrasubstance meniscal tears, or peripheral rim instability due to unstable peripheral tears or Wrisberg-type discoid meniscus. Ahn et al. have reported that a prolonged duration of symptoms before surgical treatment is an independent risk

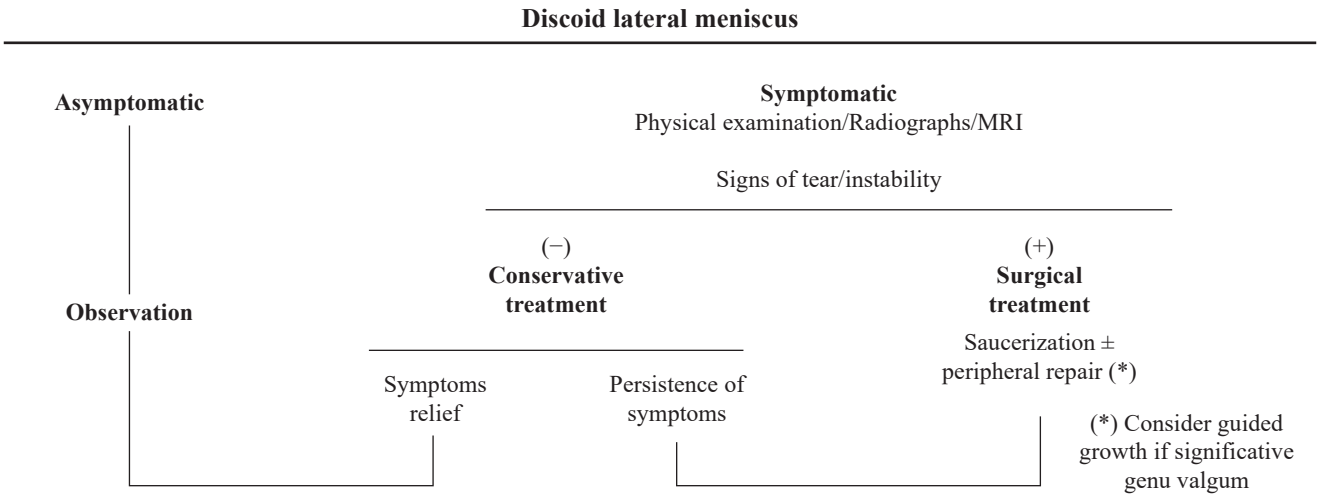


**Figure 2:** Author's preferred current treatment algorithm for discoid meniscus.

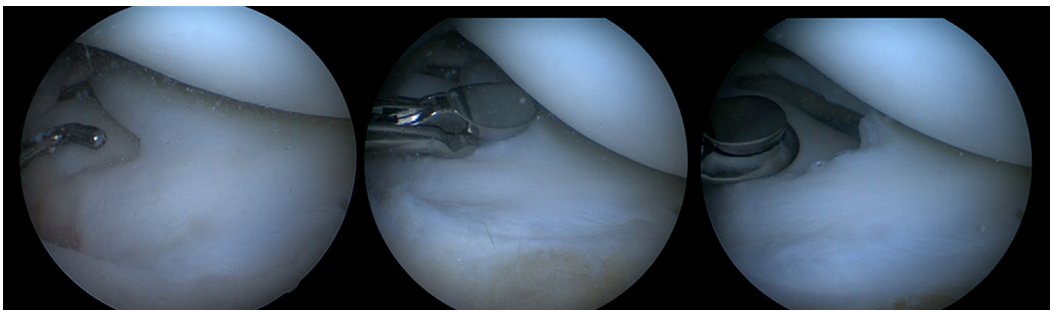

**Figure 3:** Arthroscopic saucerization procedure for lateral discoid meniscus.

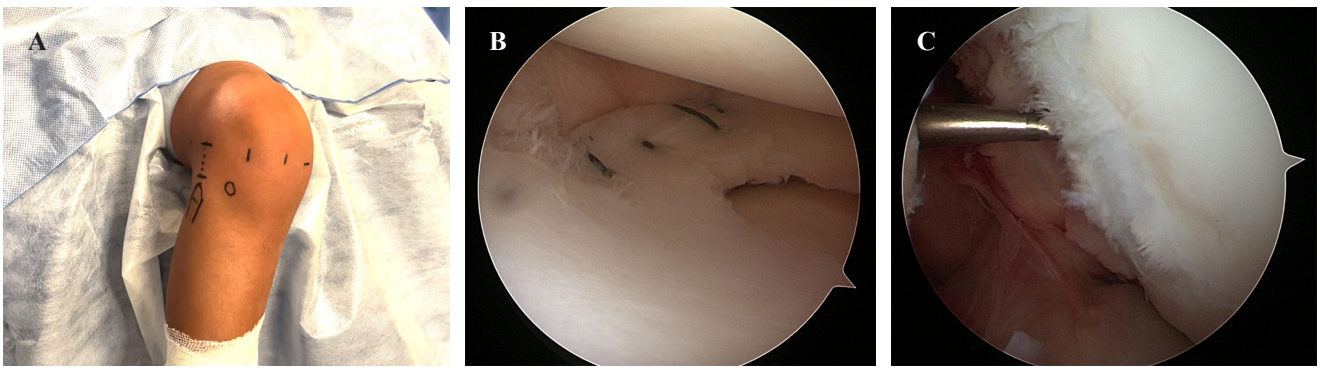


**Figure 4:** Arthroscopic saucerization, and peripheral repair with inside-out technique. **A)** Anatomic landmarks. **B)** Arthroscopic image after saucerization and peripheric repair. **C)** Marrow venting.

**Table 2: Evidence regarding meniscal rim preservation surgery.**

| Author | Journal | Year | LOE | N (knees) | Mean age | Gender (M/F) | Treatment | | | Follow-up (months) | Complications | Revision rate (%) |
|---|---|---|---|---|---|---|---|---|---|---|---|---|
| | | | | | | | S | S+R | STM | | | |
| Bellier[34] | Arthroscopy | 1989 | IV | 16 (19) | 10.5 | 10/6 | 18 | 0 | 1 | 36 | Residual symptoms (2) | 15.7 |
| Aichroth PM[35] | J Bone Joint Surg Br | 1991 | IV | 52 (62) | 10.5 | 28/24 | 6 | 0 | 48 | 66 | Arthritic changes (3) | 7.4 |
| Ogüt T[36] | J Pediatr Orthop | 2003 | IV | 11 | 11.5 | 6/5 | 11 | 0 | 0 | 54 | Ossificans myositis (1) | NR |
| Atay OA[37] | Arthroscopy | 2003 | IV | 33 (34) | 5.6 | 19/14 | 33 | 0 | 1 | 60 | NR | NR |
| Adachi N[38] | Arthroscopy | 2004 | IV | 5 | 15.4 | 4/1 | 0 | 5 | 0 | 24 | Residual pain (1) | 20 |
| Good C[5] | Arthroscopy | 2007 | IV | 27 (30) | 10.1 | 8/19 | 7 | 21 | 2 | 29.8 | Residual pain (3), intermitent symptoms (4) | 11.1 |
| Ahn J[3] | Arthroscopy | 2008 | IV | 23 (28) | 9 | 10/13 | 0 | 23 | 0 | 50.9 | Residual pain (2), growth discrepancy (1) | NR |
| Wasser L[39] | Orthopaedics & Traumatology: Surgery & Research | 2011 | III | 18 (20) | 9 | 7/13 | 9 | 8 | 3 | 37 | OCD (1), re-tear (2) | 10 |
| Stilli S[40] | Knee Surg Sports Traumatol Arthrosc | 2011 | IV | 97 (104) | 8 | 33/64 | 0 | 0 | 104 | 102 | NR | NR |
| Carter C[41] | J Pediatr Orthop | 2012 | III | 51 (57) | 11.7 | 22/29 | 33 | 24 | 0 | 15 | Residual symptoms (3), re-tear (3) | 3.5 |
| Ahn J[42] | Arthroscopy | 2015 | IV | 38 (48) | 9.9 | 33/15 | 22 | 18 | 8 | 120 | Arthritic changes (19) | 6.3 |
| Yoo WJ[43] | Arthroscopy | 2015 | IV | 86 (100) | 10.7 | 56/30 | 45 | 42 | 13 | 108 | OCD (5), re-tear (5) | 12 |
| Lee C[44] | Arthroscopy | 2016 | IV | 20 (21) | 15.3 | 10/10 | 15 | 6 | 0 | 81.6 | Arthritic changes (19) | NR |
| Matsuo T[45] | Knee Surg Sports Traumatol Arthrosc | 2017 | IV | 9 | 14 | 5/4 | 0 | 9 | 0 | 6 | NR | NR |
| Hagino T[46] | Arch Orthop Trauma Surg | 2017 | IV | 34 (39) | 12.9 | 13/21 | 32 | 6 | 1 | 14 | OCD (2) | 5.4 |
| Haskel J[32] | Knee Surg Sports Traumatol Arthrosc | 2018 | IV | 17 (19) | 9.3 | NR | 4 | 15 | 0 | 132 | Residual pain (9), locking sensation (2) | 20.6 |
| Ohnishi Y[47] | The Knee | 2018 | III | 52 (56) | 19.4 | 28/24 | 39 | 17 | 0 | 30 | Re-tear (1) | 2 |
| Kinugasa K[48] | The Knee | 2019 | IV | 4 | 16.2 | 2/2 | 0 | 4 (repair only) | 0 | 24 | NR | NR |
| Lins L[33] | J Pediatr Orthop | 2021 | IV | 25 (30) | 10.8 | 8/17 | 20 | 10 | 0 | 234 | Arthritic changes (2) | 44 |
| Perkins C[30] | J Pediatr Orthop | 2021 | IV | 30 (32) | 12 | 15/15 | 0 | 32 | 0 | 54 | Residual pain (1), re-tear (2) | 9 |
| Silverstein R[6] | Am J Sports Med | 2023 | III | 274 | 12.4 | 142/129 | 83 | 148 | 43 | 17 | NR | 22.1 |
| Bauwens PH[49] | Knee Surg Sports Traumatol Arthrosc | 2023 | III | 51 (60) | 11 | 22/29 | 3 | 57 | 0 | 41.5 | Instability (10) | 18.3 |
| Lu X[50] | International Orthopaedics | 2023 | IV | 128 | 24.1 | 40/88 | 75 | 33 | 20 | 23.3 | NR | NR |
| Rublev G[51] | Arthrosc Sports Med Rehabil | 2024 | III | 20 (22) | 8.4 | 9/11 | 9 | 11 | 0 | 36 | NR | NR |

F = female. LOE = level of evidence. M = male. NR = not reported. S = saucerization. S+R = saucerization + repair. STM = subtotal meniscectomy.

factor for poor outcomes and progression to high-grade osteoarthritis.[25] Therefore, delaying surgical treatment is not recommended once the patient presents with mechanical symptoms and MRI shows signs of instability or tears. Traditionally, the treatment for symptomatic unstable discoid meniscus has been total or subtotal meniscectomy. However, long-term studies have shown poor outcomes with this approach, including instability and degenerative changes in the lateral compartment.[26,27,28] Recent research recommends preserving the meniscal rim using techniques such as saucerization and peripheral stabilization, which have shown encouraging mid-term results[29,30,31] *(Figure 4)*. Although patient-reported outcomes are still favorable in the long term, they tend to decline over time,[32] and nearly half of patients may require revision saucerization with or without meniscal repair[33] *(Table 2)*.

### The role of guided growth

In all patients considered suitable candidates for surgery, it is crucial to thoroughly assess the mechanical axis. Diagnostic imaging should include standing hip-to-ankle alignment films to identify and measure any coronal plane deformities. These radiographs not only help evaluate preoperative limb alignment but also serve as a baseline for tracking changes after treatment. In a neutrally aligned knee, the mechanical axis runs between the tibial spines (located laterally in valgus alignment), with both the mechanical lateral distal femoral angle and medial proximal tibial angle typically measuring 87º, falling within the normal range of 85º to 90º. Additionally, alongside lower extremity radiographs, assessing the patient's skeletal age is crucial and can be achieved through a single radiographic view of the left hand[52] or knee[53] for calculating the remaining growth potential.

Guided growth holds significant importance for pediatric patients with DLM and genu valgum, utilizing their skeletal growth potential to correct angular deformities and avoiding the necessity for more invasive procedures like osteotomies. By addressing lower limb malalignment through guided growth techniques *(Figure 5)*, orthopedic surgeons can enhance the biomechanical conditions of the knee joint, potentially minimizing the risk of symptom advancement, meniscal tears, and prolonged joint degeneration in the long term.

## Future directions

Exploring future avenues in studying the discoid lateral meniscus may entail refining repair techniques to account for abnormal tissue morphology and optimizing approaches that consider the unique anatomical characteristics of the discoid meniscus. Additionally, investigating biologic augmentation strategies could enhance the healing potential of meniscal repairs in DLM cases. Furthermore, conducting long-term follow-up studies may help elucidate the natural history of DLM and shed light on how rim-preserving procedures may prevent the onset of degenerative processes. Lastly, delving into the role of meniscal transplantation, including various types of grafts such as meniscus allografts,[54] collagen implants, synthetic polymers, 3D printed scaffolds,[55,56] and semitendinosus allografts[57] in patients with DLM and meniscal deficiency could offer insights into the effectiveness, safety, and long-term advantages of restoring knee function and mitigating degenerative changes.

## Conclusion

Discoid menisci represent a congenital variation of the meniscus, characterized by an abnormal shape, stability, and histological structure, which predisposes children to a higher incidence of tears and mechanical symptoms. Although the precise etiology is not fully elucidated, advancements in imaging and histological studies have provided valuable insights into its pathogenesis. Early recognition and appropriate management are crucial for optimizing

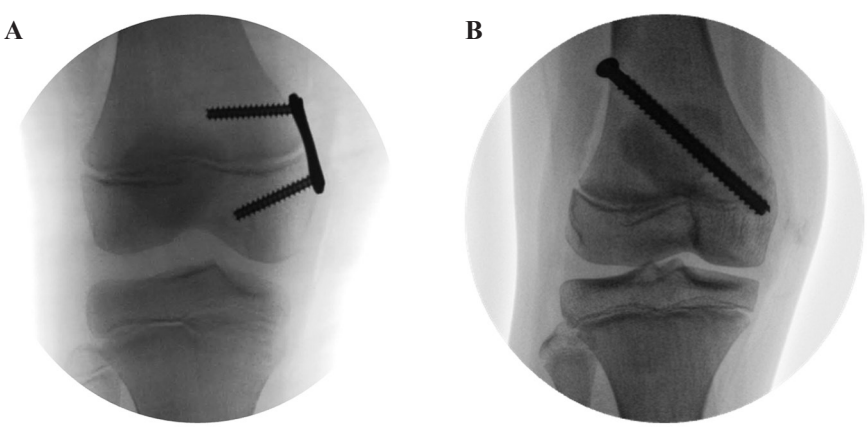


**TBP**
Tension Band Plate

**PETS**
Percutaneous Transphyseal Screws

**Figure 5:**

Guided growth with tension band plates **(A)** and transphyseal screws **(B)**.

outcomes and preventing long-term complications. The evolution of classification systems has provided clinicians with a more nuanced understanding of DLM morphology and stability, aiding in treatment decision-making. Conservative management is appropriate for asymptomatic cases with close monitoring of symptom development. For symptomatic cases, saucerization offers a viable option for restoring meniscal function and alleviating symptoms. Surgical intervention, including saucerization and repair, is indicated for cases with peripheral instability or tears. Additionally, addressing mechanical axis deviations can be crucial for optimizing outcomes, particularly in skeletally immature patients.

## References


1. Kocher MS, Logan CA, Kramer DE. Discoid lateral meniscus in children: diagnosis, management, and outcomes. *J Am Acad Orthop Surg*. 2017; 25(11): 736-43. doi: 10.5435/JAAOS-D-15-00491.
2. Rohren EM, Kosarek FJ, Helms CA. Discoid lateral meniscus and the frequency of meniscal tears. *Skeletal Radiol*. 2001; 30(6): 316-20. doi: 10.1007/s002560100351.
3. Ahn JH, Lee SH, Yoo JC, Lee YS, Ha HC. Arthroscopic partial meniscectomy with repair of the peripheral tear for symptomatic discoid lateral meniscus in children: results of minimum 2 years of follow-up. *Arthroscopy*. 2008; 24(8): 888-98.
4. Kim JH, Bin SI, Lee BS, et al. Does discoid lateral meniscus have inborn peripheral rim instability? Comparison between intact discoid lateral meniscus and normal lateral meniscus. *Arch Orthop Trauma Surg*. 2018; 138(12): 1725-30.
5. Good CR, Green DW, Griffith MH, Valen AW, Widmann RF, Rodeo SA. Arthroscopic treatment of symptomatic discoid meniscus in children: classification, technique, and results. *Arthroscopy*. 2007; 23(2): 157-63. doi: 10.1016/j.arthro.2006.09.002.
6. Silverstein RS, McKay SD, Coello P, et al. Relationship between age and pathology with treatment of pediatric and adolescent discoid lateral meniscus: a report from the SCORE multicenter database. *Am J Sports Med*. 2023; 51(13): 3493-501. doi: 10.1177/03635465231206173.
7. Smillie IS. The congenital discoid meniscus. *J Bone Joint Surg Br*. 1948; 30B(4): 671-82.
8. Kaplan EB. The embryology of the menisci of the knee joint. *Bull Hosp Joint Dis*. 1955; 16(2): 111-24.
9. Kaplan EB. Discoid lateral meniscus of the knee joint; nature, mechanism, and operative treatment. *J Bone Joint Surg Am*. 1957; 39-A(1): 77-87.
10. Atay OA, Pekmezci M, Doral MN, Sargon MF, Ayvaz M, Johnson DL. Discoid meniscus: an ultrastructural study with transmission electron microscopy. *Am J Sports Med*. 2007; 35(3): 475-8. doi: 10.1177/0363546506294678.
11. Papadopoulos A, Kirkos JM, Kapetanos GA. Histomorphologic study of discoid meniscus. *Arthroscopy*. 2009; 25(3): 262-8. doi: 10.1016/j.arthro.2008.10.006.
12. Choi YH, Seo YJ, Ha JM, Jung KH, Kim J, Song SY. Collagenous ultrastructure of the discoid meniscus: a transmission electron microscopy study. *Am J Sports Med*. 2017; 45(3): 598-603. doi: 10.1177/0363546516674181.
13. Kim JG, Han SW, Lee DH. Diagnosis and treatment of discoid meniscus. *Knee Surg Relat Res*. 2016; 28(4): 255-62. doi: 10.5792/ksrr.16.050.
14. Watanabe M, Takeda S, Ikeuchi H. *Atlas of arthroscopy*. 2nd edition. Tokyo, Japan: Igaku-Shoin Ltd, 1969.
15. Klingele KE, Kocher MS, Hresko MT, Gerbino P, Micheli LJ. Discoid lateral meniscus: prevalence of peripheral rim instability. *J Pediatr Orthop*. 2004; 24(1): 79-82. doi: 10.1097/00004694-200401000-00015.
16. Lee RJ, Nepple JJ, Schmale GA, et al. Reliability of a new arthroscopic discoid lateral meniscus classification system: a multicenter video analysis. *Am J Sports Med*. 2022; 50(5): 1245-53. doi: 10.1177/03635465221076857.
17. Lee YS, Teo SH, Ahn JH, Lee OS, Lee SH, Lee JH. Systematic review of the long-term surgical outcomes of discoid lateral meniscus. *Arthroscopy*. 2017; 33(10): 1884-95. doi: 10.1016/j.arthro.2017.04.006.
18. Ng YH, Tan SHS, Lim AKS, Hui JH. Meniscoplasty leads to good mid-term to long-term outcomes for children and adolescents with discoid lateral meniscus. *Knee Surg Sports Traumatol Arthrosc*. 2021; 29(2): 352-7. doi: 10.1007/s00167-020-05929-2.
19. Rohde MS, Trivedi S, Randhawa S, et al. Pediatric meniscus morphology varies with age: a cadaveric study. Knee Surg Sports Traumatol Arthrosc. 2023; 31(10): 4179-86. doi: 10.1007/s00167-023-07447-3.
20. Gamble JG, Abdalla AB, Meadows MG, et al. Radial width of the lateral meniscus at the popliteal hiatus: relevance to saucerization of discoid lateral menisci. *Am J Sports Med*. 2022; 50(1): 138-41. doi: 10.1177/03635465211056661.
21. Mochizuki T, Tanifuji O, Watanabe S, Sato T, Endo N. The postoperative shorter meniscal width was the risk factor of lateral meniscal extrusion in the middle portion for juvenile and adolescent knees with discoid lateral meniscus. *Knee Surg Sports Traumatol Arthrosc*. 2021; 29(9): 2857-66. doi: 10.1007/s00167-020-06188-x. Epub 2020 Jul 30. Erratum in: *Knee Surg Sports Traumatol Arthrosc*. 2021; 29(9): 2867-8. doi: 10.1007/s00167-020-06227-7.
22. Mochizuki T, Tanifuji O, Sato T, Watanabe S, Endo N. Predictive factors for developing osteochondritis dissecans after surgery for discoid lateral meniscus are younger age and shorter meniscal width. *Knee Surg Sports Traumatol Arthrosc*. 2021; 29(1): 100-8. doi: 10.1007/s00167-019-05750-6.
23. Liu W, Sun X, Liu W, Liu H, Zhai H, Zhang D, Tian F. Finite element study of a partial meniscectomy of a complete discoid lateral meniscus in adults. *Med Eng Phys*. 2022; 107: 103855. doi: 10.1016/j.medengphy.2022.103855.
24. Yokoe T, Ouchi K, Matsumoto T, Tajima T, Chosa E. Effect of the volume of resected discoid lateral meniscus on the contact stress of the tibiofemoral joint: a finite element analysis. *Knee*. 2023; 42: 57-63. doi: 10.1016/j.knee.2023.02.013.
25. Ahn JH, Kang DM, Choi KJ. Risk factors for radiographic progression of osteoarthritis after partial meniscectomy of discoid lateral meniscus tear. *Orthop Traumatol Surg Res*. 2017; 103(8): 1183-8. doi: 10.1016/j.otsr.2017.09.013.
26. Medlar RC, Mandiberg JJ, Lyne ED. Meniscectomies in children. Report of long-term results (mean, 8.3 years) of 26 children. Am J Sports Med. 1980; 8(2): 87-92. doi: 10.1177/036354658000800205.
27. Manzione M, Pizzutillo PD, Peoples AB, Schweizer PA. Meniscectomy in children: a long-term follow-up study. *Am J Sports Med*. 1983; 11(3): 111-5. doi: 10.1177/036354658301100301.
28. Washington ER 3rd, Root L, Liener UC. Discoid lateral meniscus in children. Long-term follow-up after excision. *J Bone Joint Surg Am*. 1995; 77(9): 1357-61. doi: 10.2106/00004623-199509000-00011.
29. Carabajal M, Allende GJ, Masquijo JJ. Mid-term results of arthroscopic remodelling combined with peripheral repair in children with unstable discoid meniscus. *Rev Esp Cir Ortop Traumatol*. 2020; 64(3): 206-12. English, Spanish. doi: 10.1016/j.recot.2019.10.002.
30. Perkins CA, Busch MT, Christino MA, Willimon SC. Saucerization and repair of discoid lateral menisci with peripheral rim instability: intermediate-term outcomes in children and adolescents. *J Pediatr Orthop*. 2021; 41(1): 23-7. doi: 10.1097/BPO.0000000000001695.
31. Logan CA, Tepolt FA, Kocher SD, Feroe AG, Micheli LJ, Kocher MS. Symptomatic discoid meniscus in children and adolescents: a review of 470 cases. *J Pediatr Orthop*. 2021; 41(8): 496-501. doi: 10.1097/BPO.0000000000001907.
32. Haskel JD, Uppstrom TJ, Dare DM, Rodeo SA, Green DW. Decline in clinical scores at long-term follow-up of arthroscopically treated discoid lateral meniscus in children. *Knee Surg Sports Traumatol Arthrosc*. 2018; 26(10): 2906-11. doi: 10.1007/s00167-017-4825-y.
33. Lins LAB, Feroe AG, Yang B, et al. Long-term minimum 15-year follow-up after lateral discoid meniscus rim preservation surgery in

children and adolescents. *J Pediatr Orthop*. 2021; 41(9): e810-e815. doi: 10.1097/BPO.0000000000001903.
34. Bellier G, Dupont JY, Larrain M, Caudron C, Carlioz H. Lateral discoid menisci in children. *Arthroscopy*. 1989; 5(1): 52-6. doi: 10.1016/0749-8063(89)90092-3.
35. Aichroth PM, Patel DV, Marx CL. Congenital discoid lateral meniscus in children. A follow-up study and evolution of management. *J Bone Joint Surg Br*. 1991; 73(6): 932-6. doi: 10.1302/0301-620X.73B6.1955439.
36. Ogüt T, Kesmezacar H, Akgün I, Cansü E. Arthroscopic meniscectomy for discoid lateral meniscus in children and adolescents: 4.5 year follow-up. *J Pediatr Orthop B*. 2003; 12(6): 390-7. doi: 10.1097/01202412-200311000-00007.
37. Atay OA, Doral MN, Leblebicioglu G, Tetik O, Aydingöz U. Management of discoid lateral meniscus tears: observations in 34 knees. *Arthroscopy*. 2003; 19(4): 346-52. doi: 10.1053/jars.2003.50038.
38. Adachi N, Ochi M, Uchio Y, Kuriwaka M, Shinomiya R. Torn discoid lateral meniscus treated using partial central meniscectomy and suture of the peripheral tear. *Arthroscopy*. 2004; 20(5): 536-42. doi: 10.1016/j.arthro.2004.01.028.
39. Wasser L, Knörr J, Accadbled F, Abid A, Sales De Gauzy J. Arthroscopic treatment of discoid meniscus in children: clinical and MRI results. *Orthop Traumatol Surg Res*. 2011; 97(3): 297-303. doi: 10.1016/j.otsr.2010.11.009.
40. Stilli S, Marchesini Reggiani L, Marcheggiani Muccioli GM, Cappella M, Donzelli O. Arthroscopic treatment for symptomatic discoid lateral meniscus during childhood. *Knee Surg Sports Traumatol Arthrosc*. 2011; 19(8): 1337-42. doi: 10.1007/s00167-011-1440-1.
41. Carter CW, Hoellwarth J, Weiss JM. Clinical outcomes as a function of meniscal stability in the discoid meniscus: a preliminary report. *J Pediatr Orthop*. 2012; 32(1): 9-14. doi: 10.1097/BPO.0b013e31823d8338.
42. Ahn JH, Kim KI, Wang JH, Jeon JW, Cho YC, Lee SH. Long-term results of arthroscopic reshaping for symptomatic discoid lateral meniscus in children. *Arthroscopy*. 2015; 31(5): 867-73. doi: 10.1016/j.arthro.2014.12.012.
43. Yoo WJ, Jang WY, Park MS, et al. Arthroscopic treatment for symptomatic discoid meniscus in children: midterm outcomes and prognostic factors. *Arthroscopy*. 2015; 31(12): 2327-34. doi: 10.1016/j.arthro.2015.06.032.
44. Lee CR, Bin SI, Kim JM, Kim NK. Magnetic resonance imaging findings in symptomatic patients after arthroscopic partial meniscectomy for torn discoid lateral meniscus. *Arthroscopy*. 2016; 32(11): 2366-72. doi: 10.1016/j.arthro.2016.04.012.
45. Matsuo T, Kinugasa K, Sakata K, Ohori T, Mae T, Hamada M. Post-operative deformation and extrusion of the discoid lateral meniscus following a partial meniscectomy with repair. *Knee Surg Sports Traumatol Arthrosc*. 2017; 25(2): 390-96. doi: 10.1007/s00167-016-4393-6.
46. Hagino T, Ochiai S, Senga S, et al. Arthroscopic treatment of symptomatic discoid meniscus in children. *Arch Orthop Trauma Surg*. 2017; 137(1): 89-94. doi: 10.1007/s00402-016-2575-9.
47. Ohnishi Y, Nakashima H, Suzuki H, Nakamura E, Sakai A, Uchida S. Arthroscopic treatment for symptomatic lateral discoid meniscus: the effects of different ages, groups and procedures on surgical outcomes. *Knee*. 2018; 25(6): 1083-90. doi: 10.1016/j.knee.2018.06.003.
48. Kinugasa K, Hamada M, Yonetani Y, Matsuo T, Mae T, Nakata K, Horibe S. Discoid lateral meniscal repair without saucerization for adolescents with peripheral longitudinal tear. *Knee*. 2019; 26(3): 803-8. doi: 10.1016/j.knee.2019.03.007.
49. Bauwens PH, Vandergugten S, Fiquet C, Raux S, Cance N, Chotel F. Discoid lateral meniscus instability in children: part II.: repair first to minimise the saucerisation. *Knee Surg Sports Traumatol Arthrosc*. 2023; 31(11): 4816-23. doi: 10.1007/s00167-023-07538-1.
50. Lu X, Fan Y, Jiang B, Qian J, Yang B. Arthroscopic treatment of the symptomatic discoid lateral meniscus improves the knee function in the long-term: a ten-year follow-up study. *Int Orthop*. 2023; 47(10): 2449-55. doi: 10.1007/s00264-023-05941-4.
51. Rublev GA, Natchkebia L, Gaprindashvili V, Mohamed MA, Tamazishvili T, Kartozia I, Zimlitski M. Arthroscopic saucerization of discoid lateral meniscus, with meniscus repair as indicated, results in excellent outcomes in pediatric patients younger than 12 years of age. *Arthrosc Sports Med Rehabil*. 2024; 6(2): 100915. doi: 10.1016/j.asmr.2024.100915.
52. Heyworth BE, Osei DA, Fabricant PD, et al. The shorthand bone age assessment: a simpler alternative to current methods. *J Pediatr Orthop*. 2013; 33(5): 569-74. doi: 10.1097/BPO.0b013e318293e5f2.
53. Furdock RJ, Sun KJ, Ren B, et al. The reliability of the modified fels knee skeletal maturity system. *J Pediatr Orthop*. 2024; 44(2): e192-6. doi: 10.1097/BPO.0000000000002553.
54. Turati M, Boerci L, Piatti M, et al. Meniscal allograft transplants in skeletally immature patients: a systematic review of indications and outcomes. *Healthcare (Basel)*. 2023; 11(9): 1312. doi: 10.3390/healthcare11091312.
55. Vasiliadis AV, Koukoulias N, Katakalos K. Three-dimensional-printed scaffolds for meniscus tissue engineering: opportunity for the future in the orthopaedic world. *J Funct Biomater*. 2021; 12(4): 69. doi: 10.3390/jfb12040069.
56. Li J, Zhang F, Ga X, Gao G, Guo T. Total meniscus replacement with a 3D printing of network hydrogel composite scaffold in a rabbit model. *Knee Surg Sports Traumatol Arthrosc*. 2024; 32(5): 1187-98. doi: 10.1002/ksa.12139.
57. Rönnblad E, Rotzius P, Eriksson K. Autologous semitendinosus tendon graft could function as a meniscal transplant. *Knee Surg Sports Traumatol Arthrosc*. 2022; 30(5): 1520-6. doi: 10.1007/s00167-021-06606-8.

**Conflict of Interest:** the authors declare no conflict of interest.

**Funding:** this work has not received any funding.

**Protection of humans and animals:** the authors declare that no experiments were conducted on humans or animals for this research.

**Data Confidentiality:** the authors declare that they have followed their institution's protocols regarding the publication of patient data.

**Right to privacy and informed consent:** the authors declare that no patient data appear in this article.