Acta Ortopédica Mexicana 2026; 40(3): May.-Jun. 187-191

Clinical case

doi: 10.35366/123289

Brodie's abscess in the ischium of a pediatric patient: a case report

Absceso de Brodie en el isquion de un paciente pediátrico: caso clínico

Gonçalves-Schroder e Souza B,* Sabbagh-Loures-Vieira L,‡ Francisco-Munck-Fontes L,‡ Guimarães-Brum de Castro F,‡ Demolinari-Pires D§

Faculdade de Ciencias Medicas e da Saude de Juiz de Fora, Juiz de Fora – MG, Minas Gerais, Brazil.

ABSTRACT. Osteomyelitis, a bone infection, is rare in the pelvic bones of children, particularly in the ischium, with few documented cases in the literature. *Staphylococcus aureus* is the most common causative agent. Brodie's abscess, a subacute form of osteomyelitis, primarily affects boys and is challenging to diagnose, as it may be mistaken for bone tumors due to its insidious clinical presentation. Brodie's abscess causes bone destruction, bone marrow edema, and complications in soft tissues and joints. Diagnostic methods such as magnetic resonance imaging, which reveals the «penumbra sign», and needle biopsy are essential for diagnosis. Treatment involves prolonged antibiotic therapy and, in some cases, surgical drainage. Malignant tumors, avulsions, and inflammatory conditions, such as ischial osteitis, should be excluded in the differential diagnosis. The objective of this report is to describe a rare case of subacute osteomyelitis in the ischial bone of a pediatric patient, highlighting the imaging, laboratory findings, and clinical manifestations observed.

Keywords: Brodie's abscess, osteomyelitis, child.

RESUMEN. La osteomielitis, una infección ósea, es rara en los huesos pélvicos de los niños, particularmente en el isquion, con pocos casos documentados en la literatura. *Staphylococcus aureus* es el agente causal más común. El absceso de Brodie, una forma subaguda de osteomielitis, afecta principalmente a los varones y es difícil de diagnosticar, ya que puede confundirse con tumores óseos debido a su presentación clínica insidiosa. El absceso de Brodie causa destrucción ósea, edema de la médula ósea y complicaciones en los tejidos blandos y las articulaciones. Métodos diagnósticos como la resonancia magnética, que revela el «signo de penumbra», y la biopsia con aguja son esenciales para el diagnóstico. El tratamiento incluye terapia antibiótica prolongada y, en algunos casos, drenaje quirúrgico. Se deben excluir en el diagnóstico diferencial tumores malignos, avulsiones y condiciones inflamatorias, como la osteítis isquiática. El objetivo de este informe es describir un caso raro de osteomielitis subaguda en el hueso isquiático de un paciente pediátrico, destacando los hallazgos de imágenes, laboratorio y manifestaciones clínicas observadas.

Palabras clave: absceso de Brodie, osteomielitis, niño.

* Physician and professor of medicine at the College of Medical and Health Sciences in Juiz de Fora (SUPREMA) Brazil.
‡ Medical student at the SUPREMA. Brazil.
§ Radiologist at Mater Dei Hospital. Brazil.

Correspondence:
Lucas Sabbagh Loures Vieira
E-mail: lucasabbagh@gmail.com

Received: 03-16-2025. Accepted: 01-09-2026.

How to cite: Gonçalves-Schroder e Souza B, Sabbagh-Loures-Vieira L, Francisco-Munck-Fontes L, Guimarães-Brum de Castro F, Demolinari-Pires D. Brodie's abscess in the ischium of a pediatric patient: a case report. Acta Ortop Mex. 2026; 40(3): 187-191. https://dx.doi.org/10.35366/123289

Abbreviations:
BA = Brodie's Abscess
MRI = Magnetic Resonance Imaging

Introduction

Osteomyelitis of the pelvic bones is uncommon in children and adolescents and extremely rare in the ischium. This condition is important because it can lead to both local and systemic complications, with potential acute and long-term sequelae.[1,2] Specifically, Brodie's Abscess (BA), a rare form of subacute osteomyelitis, predominantly affects male pediatric patients, although isolated cases have been reported in adults.[1,3,4] BA is an atypical manifestation of subacute osteomyelitis, defined as a well-circumscribed intramedullary collection of purulent and necrotic material, encapsulated by granulation tissue and surrounded by sclerotic bone.[2,3,5] Its onset is often insidious, typically presenting with intermittent localized pain in the absence of fever or systemic signs of infection.[3]

Among the most frequent etiologic agents, *Staphylococcus aureus* stands out as the primary cause of BA.[4] Other pathogens have also been reported, including *Pseudomonas*, *Haemophilus influenzae*, *Streptococcus*, and coagulase-negative staphylococci, among others.[2]

Pathologically, it is associated with bone marrow edema, cortical bone destruction, and adjacent soft tissue and joint involvement.[6] While BA typically arises in the metaphysis near the growth plate, it can also develop in the epiphysis or diaphysis of long bones, though diaphyseal involvement is atypical for abscess formation.[2,5,7]

The diagnostic complexity of BA in the pelvic bones is further increased by its anatomical location, which lies close to critical neurovascular structures-particularly the sciatic nerve.[6] The challenging and poorly accessible topography of the region significantly restricts the feasibility of minimally invasive diagnostic procedures, making imaging studies the gold standard for accurate detection, differential diagnosis of other osseous lesions, and effective management.[6,8,9]

Subacute osteomyelitis of the ischium with BA formation is a clinical entity that, to date, has been limited to approximately 10 documented cases in the literature. In this case report, we present a well-documented and illustrative description that highlights not only the rarity of the condition but also the key diagnostic and therapeutic considerations essential for clinical decision-making. In this way, the atypical anatomical site and the subacute infectious process demand a high index of suspicion and a multidisciplinary approach for timely diagnosis and effective intervention.

Case presentation

This is a case of an 11-year and 5-month-old male patient, previously healthy, with a two-week history of right gluteal pain, worsening during ambulation and supine position, along with sporadic episodes of intense pain.

He denied any history of trauma, fever, infections, or accompanying constitutional symptoms. He also denied medication use and comorbidities. He reported starting regular football practice a year ago with a weight loss of 2 kg during this period.

On physical examination, he presented with limping and mild pain during hip rolling, as well as tenderness on palpation of the ischial tuberosity, without edema or inflammatory signs. Hip range of motion was normal, although painful at the extremes of external rotation and extension. Impact tests were negative, as were Drehmann, Lasegue, and Stinchfield tests.

Initial radiographic examinations did not reveal signs of abnormalities, prompting the need for further investigations. Laboratory test results are presented in *Table 1*, corresponding to the dates of June 21, 23, and 29, 2023. The Magnetic Resonance Imaging (MRI) performed on June 21, 2023, showed edema in the ischial bone marrow, raising the possibility of osteitis, bone contusion, or infection *(Figure 1)*.

The patient was managed with active clinical observation, serial radiographic exams, analgesia, anti-inflammatory medication, antibiotic therapy, and rest. However, despite these measures, painful symptoms persisted for another three weeks, prompting a new MRI and laboratory tests.

Clinical analysis results, represented in *Table 1* on July 3, 2023, showed a reduction in laboratory parameters, albeit with values close to or exceeding the upper limit. The MRI, performed on July 18, 2023, revealed an intraosseous lesion with extensive adjacent bone marrow edema and periosteal reaction, as well as a liquid collection in soft tissues suggesting the presence of purulent content *(Figure 2)*.

Based on these findings, surgical treatment was recommended to drain the abscess, curette the bone lesion, and obtain cultures and material for pathological anatomy.

The surgery was conducted under spinal anesthesia, and a posterior-lateral Kocher-Langenbeck incision was performed. During the operation, the presence of a fistulous opening, closely related to the sciatic nerve, confirmed the impossibility of treatment by less invasive means such as interventional radiology. After isolating and protecting the nerve, the intraosseous abscess in the ischium was curetted, and it was confirmed that there was no communication with the joint *(Figure 3)*. The collected material was sent for culture and pathological anatomy, which showed no growth upon cultivation; however, the pathological report confirmed the presence of bone infection and the absence of lesions suggestive of malignancy. In the immediate postoperative period, the patient reported complete relief from painful symptoms, and both postoperative and follow-up radiographs revealed the lytic region of the abscess in the debrided ischium near the greater sciatic notch *(Figure 4)*.

The patient was treated with intravenous antibiotic therapy using vancomycin and meropenem for three weeks, followed by oral antibiotic therapy with clindamycin for

Table 1: Patient laboratory test results.

Parameters	Dates								
	21/06/23	23/06/23	29/06/23	03/07/23	05/01/24	07/01/24	10/01/24	15/01/24	22/01/24
Hemoglobin (g/dl)	13.4	14	13.2	12.1	9.2	8	7.3	7.5	9.3
Leukocytes (/mm^3)	12,490	10,730	11,370	10,470	11,600	18,010	27,880	13,910	8,808
ESR (mm)	84	92	51	37		102	149	102	94
CRP (mg/dl)	–	8.5	10.3	7.4	132	198	277	174	49

Source: Author's own elaboration, 2024.
CRP = C-Reactive Protein. ESR = Erythrocyte Sedimentation Rate.

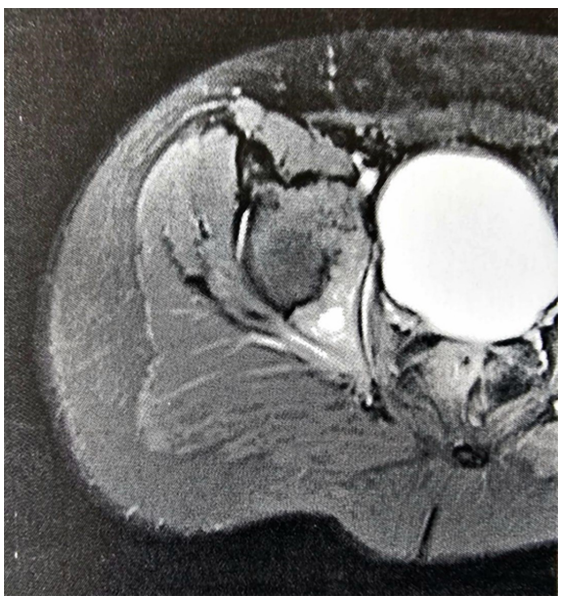

Figure 1: Magnetic resonance imaging in the axial plane, post-contrast, showing a delineated intraosseous lesion with bone marrow edema and periosteal reaction.

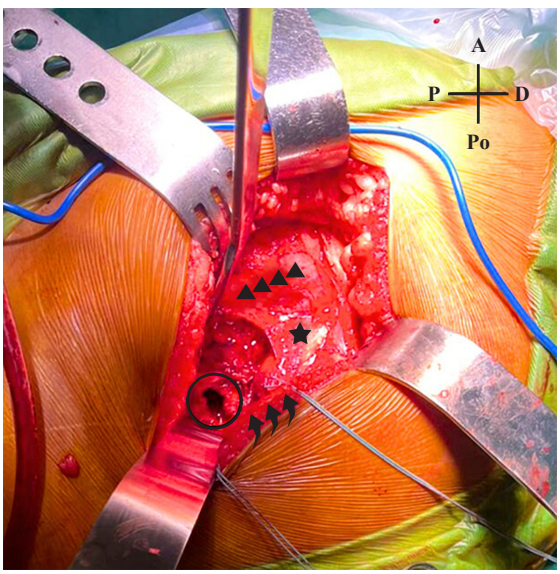

Figure 3: Intraoperative view of the posterior hip approach showing several surgical landmarks: ▲ = trochanteric border. ★ = quadratus femoris muscle. ◯ = abscess opening. ↱ = externally rotated hip muscles retracted posteriorly, protecting the sciatic nerve.

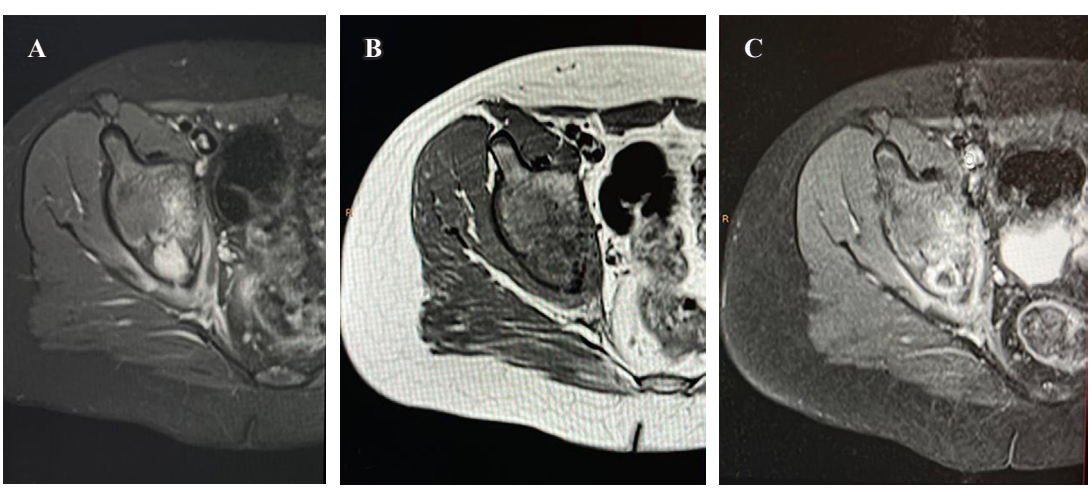

Figure 2: Magnetic resonance imaging in the axial plane. **A)** T2 fat supression sequence (T2FS) showing increased intraosseous lesion. **B)** T1 sequence with the penumbra sign. **C)** Post-contrast with peripheral enhancement of the halo containing purulent center.

an additional six weeks due to the inability to identify the pathogen through cultures.

After one year of follow-up, the patient remained asymptomatic, with no complaints of pain, deformities, or morphological changes on radiographic examination of the hip *(Figure 5)*. Postoperative images showed bone remodeling, as the bone cavity was no longer identifiable. No other abnormalities were observed, such as periosteal reaction, new lytic lesions, or signs of bone deformity. Follow-up laboratory tests showed normal inflammatory parameters, and no complications were recorded.

Discussion

BA can mimic a variety of conditions, including benign and malignant bone tumors such as osteosarcoma and Ewing sarcoma, highlighting the importance of a thorough understanding of this entity for accurate diagnosis.[2,6] Other conditions, such as ischiatic osteitis, stress fractures, juvenile osteochondroses, and bone metastases, are also commonly included in the differential diagnosis.[3,10] A systematic review including 407 patients highlighted that BA is often diagnosed late.[4] This delay is largely due to its insidious and nonspecific presentation, with patients typically reporting only localized pain, while fever is uncommon and inflammatory markers may be inconclusive.[3,4]

Plain radiographs are always the initial recommended tests in the evaluation of painful hips in children and adolescents; however, they do not exclude the possibility of other differential diagnoses, and the use of more sensitive and specific imaging methods such as MRI should be considered.[3,10] The «penumbra sign» in T1-weighted MRI, which presents as a halo surrounding an abscess cavity with a signal higher than the main abscess, can be useful in differentiating subacute osteomyelitis from other bone lesions.[2] However, diagnostic confirmation is only possible through histopathological examination obtained via needle biopsy; in cases like the one presented, where there is risk to noble neurovascular structures like the sciatic nerve, confirmation is made via open surgery.[3,6]

Figure 4: Immediate postoperative anteroposterior pelvic radiograph showing a suction drain within the bone cavity.

Figure 5: Six-month postoperative anteroposterior pelvic radiograph demonstrating complete resolution of the abscess with no signs of periosteal reaction.

In this case report, the cultures were negative, preventing the identification of the etiological agent. This negativity is common in osteomyelitis, occurring in about 24 to 68% of cases,[11] leading to the recommendation of empirical intravenous antibiotic therapy directed at the most common pathogen.[12] In light of this, we opted for a broad-spectrum antibiotic, as the clinical history did not indicate relevant risk factors for any specific germ.

Conservative treatment with isolated antibiotic therapy has been reported in the literature as successful in cases of subacute osteomyelitis, especially if the diagnosis is early.[12,13] However, in the clinical case in question, we chose to complement with invasive treatment since painful symptoms persisted alongside the presence of a purulent collection in the ischial region, this last aspect being considered an indication for surgical treatment.[13] In this process, material for analysis was obtained, facilitating combined drainage of the collection and, eventually, curettage and debridement.

Finally, BA generally has a good prognosis with positive long-term outcomes when treatment is early and adequate. However, it requires prolonged follow-up to ensure satisfactory functional recovery and to identify possible complications that may arise, such as avascular necrosis, limb length discrepancy, pathological fractures, and organ failure.[14]

Conclusion

BA involving the ischium is an exceptionally uncommon manifestation of subacute osteomyelitis, especially in the

pediatric population. The deep pelvic location, coupled with the proximity to vital neurovascular structures such as the sciatic nerve, poses significant diagnostic and therapeutic challenges-particularly due to the limited feasibility of minimally invasive approaches like image-guided biopsy or drainage. This case reinforces the need to include this rare entity in the differential diagnosis of persistent pelvic pain with nonspecific symptoms. Reporting atypical presentations such as this one is essential for enhancing clinical awareness and supporting more accurate and timely intervention in comparable future cases.

References

1. Hamzaoui A, Salem R, Koubaa M, Zrig M, Mnif H, Abid A, et al. *Escherichia coli* osteomyelitis of the ischium in an adult. *Orthop Traumatol Surg Res*. 2009; 95(8): 636-8.
2. Silva CI, Figueroa GMJ, Cañete CI, Hodgson O F, Gündel PA. Absceso de Brodie, una patología de difícil diagnóstico. *Rev Chil Pediatr*. 2020; 91(6): 947-52.
3. Chin J, Naito T, Hon K, Lomiguen C. Challenges in the diagnosis of Brodie's abscess in subacute osteomyelitis. *J Orthop Case Rep*. 2020; 10(3): 1-4.
4. van der Naald N, Smeeing DPJ, Houwert RM, Hietbrink F, Govaert GAM, van der Velde D. Brodie's abscess: a systematic review of reported cases. *J Bone Jt Infect*. 2019; 4(1): 33-9.
5. Salik M, Mir MH, Philip D, Verma S. Brodie's abscess: a diagnostic conundrum. *Cureus*. 2021; 13(7): e16426.
6. Saad A, Kalia S, Le Nail LR, Davies M, James S, Botchu R. Isolated ischial lesions-demographics and imaging features. *Indian J Musculoskelet Radiol*. 2019; 1(1): 14-20.
7. Pulido PG, Hotchen A, Gojanur A, Corbett J, Stohr KK. Brodie's abscesses can stimulate the growth plate in children. *J Bone Jt Infect*. 2019; 4(6): 264-7.
8. Gabbott B, Faria G, Lawson G, Daly K. A Brodie's abscess with soft tissue collection-complicating an already difficult diagnosis. *J Surg Case Rep*. 2018; 2018(1): rjx263.
9. Schlur C, Bachy M, Wajfisz A, Ducou le Pointe H, Josset P, Vialle R. Osteoid osteoma mimicking Brodie's abscess in a 13-year-old girl. *Pediatr Int*. 2013; 55(2): e29-31.
10. Ribeiro SC, Barreto KSS, Alves CBS, Almendra Neto OL, da Nóbrega MV, Braga LRC. Hip pain in childhood. *Radiol Bras*. 2020; 53(1): 63-8.
11. Pääkkönen M, Kallio MJ, Kallio PE, Peltola H. Significance of negative cultures in the treatment of acute hematogenous bone and joint infections in children. *J Pediatric Infect Dis Soc*. 2013; 2(2): 119-25.
12. Chen JA, Lin HC, Wei HM, Hsu YL, Lai HC, Low YY, et al. Clinical characteristics and outcomes of culture-negative versus culture-positive osteomyelitis in children treated at a tertiary hospital in central Taiwan. *J Microbiol Immunol Infect*. 2021; 54(6): 1061-9.
13. Alvares PA, Mimica MJ. Osteoarticular infections in pediatrics. *J Pediatr (Rio J)*. 2020; 96 Suppl 1(Suppl 1): 58-64.
14. Jumabhoy I, Uzoho C, Desai V. An infective cause for the limping child. *BMJ Case Rep*. 2019; 12(9): e228964.

Funding: this research has not received any specific funding from sector agencies.