Acta Ortopédica Mexicana 2026; 40(3): May.-Jun. 164-171

Original article

doi: 10.35366/123286

The impact of preoperative multifidus muscle morphology on surgical outcomes in lumbar degenerative spondylolisthesis: a retrospective cohort study

El impacto de la morfología preoperatoria del músculo multífido en los resultados quirúrgicos de la espondilolistesis degenerativa lumbar: un estudio de cohorte retrospectivo

García-Ramos C,* Pérez-Oliva J,* Carreón-Cerda C,‡ Solorio-Pineda S,* Hernández-Moctezuma D,* Álvarez-Ramírez C,* Alpízar-Aguirre A,* Reyes-Sánchez A*

National Institute of Rehabilitation «Luis Guillermo Ibarra Ibarra». Mexico City, Mexico.

ABSTRACT. Introduction: the multifidus muscle is a key stabilizer of the lumbar spine. While its deterioration has been associated with degenerative spinal conditions, the specific impact of its preoperative morphology on surgical outcomes remains unclear. The objective of this study is to evaluate the relationship between preoperative multifidus muscle morphology (cross-sectional area and fatty degeneration) and clinical-surgical outcomes following lumbar fusion surgery. **Material and methods:** a retrospective cohort study of 99 patients aged 40-65 years with L4-L5 degenerative spondylolisthesis undergoing lumbar fixation and arthrodesis (2022-2024). Preoperative MRIs assessed cross-sectional area multifidus (CSAM) and fatty degeneration. Three spine surgeons performed measurements with substantial interobserver reliability (κ = 0.80). Clinical outcomes (ODI, Roland Morris, SF-36, VAS), surgical variables, and complications were analyzed. **Results:** the cohort (31.31% male, 68.69% female; mean age 59.15 ± 8.78 years) showed significant positive correlations between CSAM and intraoperative blood loss (r = 0.249, p = 0.013) and postoperative complications (r = 0.217, p = 0.031). Fatty degeneration demonstrated no

RESUMEN. Introducción: el músculo multífido es un estabilizador clave de la columna lumbar. Aunque su deterioro se ha asociado con patologías degenerativas, el impacto específico de su morfología preoperatoria en los resultados quirúrgicos permanece incierto. El objetivo de este estudio es evaluar la relación entre la morfología preoperatoria del músculo multífido (área transversal del multífido y la degeneración grasa) y los resultados clínico-quirúrgicos tras la artrodesis lumbar. **Material y métodos:** estudio retrospectivo de cohortes de 99 pacientes de 40-65 años con espondilolistesis degenerativa L4-L5 intervenidos (2022-2024). Se utilizaron resonancias magnéticas preoperatorias para valorar el área transversal del multífido (por sus siglas en inglés CSAM, *cross-sectional area multifidus*) y degeneración grasa del multífidus. Tres cirujanos realizaron las mediciones con confiabilidad interobservadora sustancial (κ = 0.80). Se analizaron resultados clínicos (ODI, Roland Morris, SF-36, EVA), variables quirúrgicas y complicaciones. **Resultados:** la cohorte (31.31% hombres, 68.69% mujeres; edad media 59.15 ± 8.78 años) mostró correlaciones positivas significativas entre CSAM y sangrado intraoperatorio

Level of evidence: III

* Spine Surgery Department, National Institute of Rehabilitation. Mexico City, Mexico.
‡ Clínica Hospital ISSSTE Mérida, Mexico.

Correspondence:
Alejandro Reyes-Sánchez
National Institute of Rehabilitation «Luis Guillermo Ibarra Ibarra», Spine Surgery Division.
Calzada México-Xochimilco No. 289, Col. Arenal de Guadalupe, Tlalpan, CP 14389, Mexico City, México.
E-mail: alereyes@inr.gob.mx

Received: 07-14-2025. Accepted: 01-09-2026.

How to cite: García-Ramos C, Pérez-Oliva J, Carreón-Cerda C, Solorio-Pineda S, Hernández-Moctezuma D, Álvarez-Ramírez C et al. The impact of preoperative multifidus muscle morphology on surgical outcomes in lumbar degenerative spondylolisthesis: a retrospective cohort study. Acta Ortop Mex. 2026; 40(3): 164-171. https://dx.doi.org/10.35366/123286

significant association with complications (p = 0.214) or clinical improvement. All patient groups showed significant clinical improvement at 12 months postoperatively regardless of fatty infiltration severity. **Conclusions:** larger multifidus muscle volume correlates with increased surgical complexity, while fatty degeneration does not predict complications or clinical outcomes. These findings highlight the importance of comprehensive muscle morphology assessment in preoperative planning. A retrospective cohort study was conducted.

Keywords: paraspinal muscles, spinal fusion, spondylolisthesis, pathology, lumbar vertebrae.

(r = 0.249, p = 0.013) y complicaciones postoperatorias (r = 0.217, p = 0.031). La degeneración grasa no mostró asociación significativa con complicaciones (p = 0.214) ni mejoría clínica. Todos los grupos mostraron mejoría clínica significativa a los 12 meses postoperatorios, independientemente de la severidad de la infiltración grasa. **Conclusiones:** un mayor volumen del músculo multífido se correlaciona con mayor complejidad quirúrgica, mientras que la degeneración grasa no predice complicaciones ni resultados clínicos. Estos hallazgos resaltan la importancia de la evaluación integral de la morfología muscular en la planificación preoperatoria. Se realizó un estudio de cohorte retrospectivo.

Palabras clave: músculos paraespinales, fusión espinal, espondilolistesis, patología, vértebras lumbares.

Introduction

Degenerative spondylolisthesis affects 10-15% of patients with chronic low back pain, and surgical intervention is often required when conservative measures fail.[1] The lumbar paraspinal muscles, particularly the multifidus, play a crucial role in maintaining spinal stability, posture, and protecting structural elements.[2,3,4,5] Understanding preoperative predictors of surgical complexity becomes crucial for optimizing outcomes in this specific population.

Age-related degeneration of the lumbar paravertebral muscles follows a predictable pattern, with systematic reviews demonstrating progressive fatty infiltration and muscle atrophy that correlates with advancing age.[2] This degenerative process significantly impacts spinal sagittal alignment, as muscle quantity and quality are critical determinants of spinal biomechanics.[3] The accuracy of MRI signal intensity ratio measurements in evaluating multifidus muscle injury and atrophy has been well-established, providing reliable non-invasive assessment tools for clinical practice.[4]

Changes in paraspinal muscles have been consistently associated with low back pain and spinal degeneration, with CT studies demonstrating clear relationships between muscle degeneration and clinical symptoms.[5] Fat infiltration of paraspinal muscles is particularly associated with both low back pain and disability in community-based adults,[6] highlighting the clinical relevance of muscle quality assessment. Advanced 3D analysis techniques using T2 images have improved our ability to quantify fatty infiltration of paravertebral lumbar muscles,[7] offering more precise evaluation methods.

The correlation between multifidus fatty atrophy and lumbar disc degeneration in low back pain patients has been demonstrated,[8] while the effects of spinal stabilization exercises on muscle cross-sectional areas show the potential for therapeutic intervention.[9] Sedentary lifestyle represents a significant risk factor for low back pain development,[10] emphasizing the modifiable nature of some muscle-related risk factors. CT measurements have consistently shown reduced trunk muscle areas in patients with chronic low back pain,[11] supporting the importance of muscle preservation.

Preoperative paraspinal and psoas major muscle atrophy, along with paraspinal muscle fatty degeneration, have been identified as factors influencing surgical outcomes in lumbar disc disease.[12] Severe lumbar intervertebral disc degeneration associates with Modic changes and fatty infiltration in paraspinal muscles at most lumbar levels,[13] illustrating the interconnected nature of spinal degeneration processes. CT imaging studies confirm significant differences in trunk muscles between chronic low back pain patients and healthy controls,[14] while local denervation atrophy of paraspinal muscles contributes to postoperative failed back syndrome.[15]

Given this comprehensive background, our study aims to precisely evaluate how both morphological characteristics of the multifidus muscle influence intraoperative parameters and clinical outcomes following lumbar fusion surgery for degenerative spondylolisthesis, building upon existing literature while addressing gaps in surgical outcome prediction.

Material and methods

Study design and population

A retrospective cohort study was conducted following STROBE guidelines. The study received approval from the institutional ethics committee (reference #2021-45-SPINE), and informed consent was waived due to the retrospective nature. Sample size calculation was performed a priori using G*Power software, indicating that

97 patients would provide 90% power to detect a moderate correlation (r = 0.30) with $\alpha = 0.05$.

Inclusion criteria comprised:

- Patients aged 40-65 years.
- Single-level L4-L5 degenerative spondylolisthesis (Meyerding grade I-II).
- Primary lumbar fixation and arthrodesis performed between January 2022 and June 2024.
- Complete preoperative MRI studies including axial T2-weighted sequences.
- Minimum 12-month postoperative follow-up.

Exclusion criteria were rigorously applied:

- Previous lumbar spine surgery.
- Traumatic or isthmic spondylolisthesis.
- Active spinal infection or malignancy.
- Inflammatory spondyloarthropathies.
- Neuromuscular disorders affecting paraspinal muscles.
- Incomplete imaging or clinical data.
- Revision surgery cases.

Data collection protocol

Clinical variables

Data abstraction followed a standardized protocol using our institution's electronic medical records. Demographic and clinical variables included:

- Age, sex, body mass index (BMI).
- Comorbidities.
- Smoking status and pack-year history.
- Duration of symptoms prior to surgery.
- Preoperative and 12-month postoperative patient-reported outcomes:
  - Oswestry disability index (ODI) version 2.0.
  - Roland-Morris disability questionnaire.
  - SF-36 Health Survey (physical and mental component summ
  - Visual analog scale (VAS) for lumbar pain (0-10).

Surgical variables

Intraoperative data were extracted from anesthesia records and surgical reports:

- Operative time (skin incision to closure).
- Intraoperative blood loss (quantified by suction canister volume minus irrigation).
- Need for blood transfusion.
- Surgical approach (posterior vs transforaminal lumbar interbody fusion).
- Fusion levels and instrumentation details.

Complication assessment

Postoperative complications were systematically categorized and monitored for 12 months, and those included were: surgical site infection, hardware failure, pseudarthrosis, symptomatic adjacent segment disease, superficial infection, transient neurological deficits, dural tear, reoperations.

MRI acquisition and analysis protocol

Imaging parameters

All patients underwent preoperative lumbar spine MRI using 3.0 Tesla scanners (Philips Achieva) with standardized protocols:

- Axial T2-weighted turbo spin-echo sequences.
- Slice thickness: 3 mm with 0.5 mm gap.
- Field of view: 200 × 200 mm.
- Matrix size: 320 × 256.
- Repetition time/echo time: 3,000-4,000/90-110 ms.

Muscle morphology assessment

Three fellowship-trained spine surgeons (interobserver variability $\kappa = 0.80$) with 10-15 years of experience, blinded to clinical outcomes, independently performed all measurements using DICOM viewer (version 3.3.5). Measurements were conducted at the L4-L5 intervertebral disc level following a standardized protocol:

Cross-sectional area measurements:

- Multifidus muscle boundaries defined:
  - Medial: spinous processes and interspinous ligament.
  - Lateral: plane between multifidus and longissimus muscles.
  - Posterior: thoracolumbar fascia.
  - Anterior: vertebral body and lamina.
- Manual tracing excluded visible fat and fibrous tissue.
- Three consecutive slices centered at the disc level were measured and averaged.
- Vertebral body area (VBA) was measured at the same level for normalization.
- Muscle-to-bone ratio calculated as CSAM/VBA *(Figure 1)*.

Fatty degeneration classification:

Fatty infiltration was graded using a modified four-grade scale adapted from Faur et al., classification *(Figure 2)*:[8]

Grade 1 (mild): < 25% fatty infiltration, normal muscle bulk.
Grade 2 (moderate): 25-50% fatty infiltration, some muscle atrophy.
Grade 3 (severe): 50-75% fatty infiltration, marked muscle atrophy.

Grade 4 (very severe): > 75% fatty infiltration, severe muscle replacement.

For statistical analysis, grades were grouped as «mild degeneration» (grades 1-2) and «severe degeneration» (grades 3-4).

Quality control measures

To ensure measurement consistency:

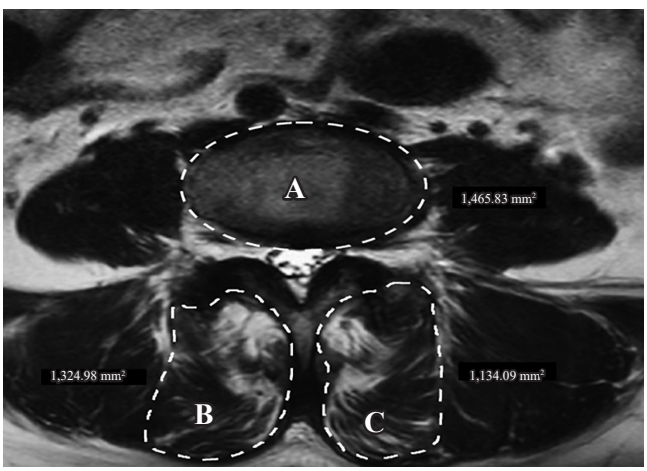

Figure 1: The vertebral body area (VBA) at the level of the L4-L5 intervertebral disc (label A) was analyzed and compared with the cross-sectional area multifidus (CSAM) at the same level (labels B and C). This measurement allowed for the assessment of the relationship between bony morphology and paravertebral muscle mass in the lower lumbar region.

- Initial training session with reference images and standardized measurement protocol.
- Intra-observer reliability was assessed by repeating 20 random measurements after four weeks.
- Regular calibration sessions during the data collection period.
- Consensus meeting for measurements with > 15% interobserver variation.
- All measurements were performed in standardized window settings (window width 400 HU, level 40 HU).

Statistical analysis

Data analysis was performed using SPSS Statistics version 28.0 (IBM Corp., Armonk, NY). Continuous variables were expressed as mean ± standard deviation for normally distributed data or median with interquartile range for non-normal distributions. Categorical variables were reported as frequencies and percentages.

Primary analyses:

- Normality assessment using the Kolmogorov-Smirnov test with Lilliefors correction.
- Interobserver reliability for morphological measurements using intraclass correlation coefficients (ICC) for continuous variables and Cohen's kappa (κ) for categorical variables.
- Correlation analyses using Pearson's correlation for normally distributed continuous variables and Spearman's rank correlation for ordinal or non-normal data.
- Group comparisons using independent t-tests or Mann-Whitney U tests for continuous variables, and chi-square or Fisher's exact tests for categorical variables.

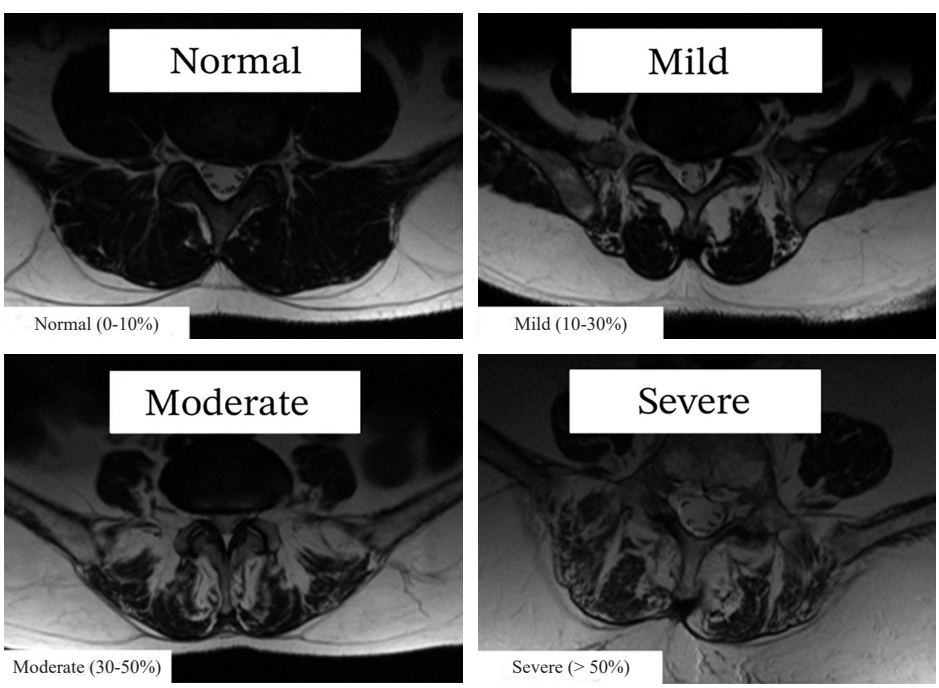

Figure 2:

Axial T2-weighted magnetic resonance images showing the different grades of fatty infiltration in the lumbar multifidus muscle (LMM) according to the classification described by Faur et al.[8]

Secondary analyses:

- Multiple linear regression to adjust for potential confounders (age, sex, BMI, comorbidity index).
- Logistic regression for binary outcome variables (complication occurrence).
- Analysis of covariance (ANCOVA) for group comparisons of clinical improvement.
- Sensitivity analyses excluding outliers (> 3 standard deviations from the mean).

Statistical significance:

A two-tailed p-value < 0.05 was considered statistically significant. For multiple comparisons, the Bonferroni correction was applied to maintain the family-wise error rate. All statistical assumptions were tested, including linearity, homoscedasticity, and multicollinearity. Missing data were handled using multiple imputation with 5 imputed datasets when the missingness was < 5%.

Results

Patient characteristics

From an initial screening of 134 patients, 99 met all inclusion criteria. The cohort comprised 31 men (31.31%) and 68 women (68.69%) with a mean age of 59.15 ± 8.78 years. Mean preoperative clinical scores demonstrated significant disability: ODI 45.43 ± 17.66, Roland-Morris 14.64 ± 5.40, and lumbar VAS 7.15 ± 1.44.

Comorbidities were present in 43.4% of patients, with hypertension (20.8%) and diabetes mellitus (13.2%) being the most common. The mean presence of comorbidity was 1.2 ± 1.1. Spondylolisthesis was grade 1 in 54.7% and grade 2 in 45.3% of cases. Demographic and baseline characteristics are detailed in *Table 1*.

Table 1: Demographic data (N = 99).

Parameters	Mean ± SD	Min-Max
Age (years)	59.15 ± 8.78	43-65
BMI (kg/m^2)	26.15 ± 2.91	19-39
Clinical variables		
ODI (%)	45.43 ± 17.66	12-94
RM (points)	14.64 ± 5.40	3-24
Lumbar VAS (points)	7.15 ± 1.44	4-10
SF-36, PCS (points)	35.91 ± 16.62	16-90
SF-36, MCS (points)	48.25 ± 15.22	20-95
Surgical variables		
Surgical time (min)	187.28 ± 81.62	80-480
Bleending (ml)	437.92 ± 322.18	100-1,600

BMI = body mass index. MCS = mental component summary.
ODI = Oswestry disability index. PCS = physical component summary.
RM = Roland Morris. SD = standard deviation.
VAS = visual analog scale.

Table 2: Degrees of fatty degeneration.

Grade	n (%)
1	6 (6.1)
2	49 (49.5)
3	33 (33.3)
4	11 (11.1)
Total	99 (100.0)

Muscle morphology assessment

All morphological measurements showed substantial interobserver agreement ($\kappa = 0.80$). Intra-observer reliability was excellent (ICC = 0.92, 95%CI 0.88-0.95). Fatty degeneration distribution was: grade 1: 6 patients (6.1%), grade 2: 49 patients (49.5%), grade 3: 33 patients (33.3%), grade 4: 11 patients (11.1%).

The distribution of fatty degeneration grades is presented in *Table 2*.

The mean CSAM was 4,403.3 ± 856.7 mm^2 and mean VBA was 1,281.0 ± 245.3 mm^2, resulting in a muscle-to-bone ratio of approximately 3.44:1. Detailed morphological measurements are presented in *Table 3*.

Surgical outcomes and correlations

A strong positive correlation was observed between operative time and intraoperative blood loss (r = 0.754, p < 0.001). Mean operative time was 185.4 ± 45.2 minutes, and mean blood loss was 450.8 ± 156.7 ml. CSAM showed significant positive correlations with both blood loss (r = 0.249, p = 0.013) and overall complication incidence (r = 0.217, p = 0.031).

Blood loss also correlated with postoperative complications (r = 0.374, p < 0.001). The overall complication rate was 18.2%, with major complications occurring in 8.1% and minor complications in 10.1% of patients. Notably, fatty infiltration showed no significant association with postoperative complications (p = 0.214).

Clinical improvement

All patient groups demonstrated significant improvement in clinical outcomes at 12-month follow-up *(Table 4)*. The mean improvement in ODI was 25.5 ± 8.3 points (p < 0.001), representing a 56.1% improvement from baseline. Roland-Morris improved by 8.2 ± 3.1 points (p < 0.001), and lumbar VAS decreased by 4.3 ± 1.2 points (p < 0.001). SF-36 physical component summary scores improved from 28.4 ± 6.7 to 41.2 ± 8.3 (p < 0.001).

Statistical analysis confirmed no significant correlation between fatty degeneration grade and the magnitude of improvement in ODI (r = 0.08, p = 0.43), Roland-Morris (r = 0.05, p = 0.62), or VAS (r = 0.09, p = 0.38). Subgroup

analysis comparing «mild degeneration» (grades 1-2) versus «severe degeneration» (grades 3-4) showed no significant differences in clinical improvement ($p > 0.05$ for all outcome measures) *(Table 5)*.

Multiple regression analysis adjusting for age, sex, BMI, and comorbidity index confirmed that CSAM remained independently associated with blood loss ($\beta = 0.231$, $p = 0.018$) and complications ($\beta = 0.205$, $p = 0.035$), while fatty degeneration showed no independent associations.

Discussion

This study provides compelling evidence that distinct aspects of multifidus muscle morphology have specific implications for lumbar fusion surgery outcomes. The substantial interobserver reliability ($\kappa = 0.80$) strengthens the validity of our morphological assessments and subsequent conclusions, building upon established MRI measurement accuracy for multifidus muscle evaluation.[4]

The most significant finding was the association between larger multifidus muscle volume and increased surgical complexity. This finding extends previous research demonstrating that paraspinal muscle degeneration correlates with degenerative lumbar spondylolisthesis.[16,17] While Da et al.[16] found quantitative relationships between paraspinal muscle degeneration and spondylolisthesis degree, our study advances this knowledge by demonstrating the surgical implications of muscle volume. Similarly, Liu et al.[17] established associations between paravertebral muscle parameters and single-level degenerative spondylolisthesis, but our work specifically addresses surgical outcomes.

The paradoxical finding that larger muscle volume predicts increased surgical complexity, while fatty degeneration shows no such association, challenges conventional surgical wisdom. This suggests that the mechanical challenges posed by robust muscular anatomy may outweigh the metabolic implications of fatty infiltration in determining surgical outcomes. This distinction becomes particularly relevant when considering that sarcopenia significantly impacts degenerative lumbar spinal stenosis outcomes[18] and associates with low back pain in community studies.[19]

From a technical perspective, larger CSAM likely indicates: 1. greater muscle bulk requiring more extensive retraction and potentially compromising surgical exposure, 2. richer vascularization increasing bleeding risk during dissection, and 3. potentially correlating with higher body mass index, though this requires further investigation. Our findings align with Stanuszek et al.[12] who emphasized preoperative muscle assessment, but refine the approach by distinguishing between volume and quality implications.

Our findings align with the systematic review by Dallaway et al.[2] showing age-related paravertebral muscle degeneration, yet we demonstrate that among surgical candidates, age-related changes may have different implications than previously understood. The relationship between muscle quality and spinal sagittal alignment established by Jun et al.[3] provides context for understanding why muscle morphology matters, though our results suggest its impact differs between conservative and surgical management.

The lack of association between fatty degeneration and surgical outcomes challenges some assumptions derived from community-based studies.[6,20] While Kjaer et al.[20] found MRI-defined fat infiltrations associated with low

Table 3: Volume of the multifidus at L4-L5.

Measurements	Min-Max	Mean ± SD
CSAM L4-L5 right (mm^2)	1,028-3,241	2,166.02 ± 444.981
CSAM L4-L5 left (mm^2)	1,298-3,768	2,237.28 ± 528.808
CSAM total (mm^2)	2,326-7,001	4,403.30 ± 941.972
VBA (mm^2)	877-1,689	1,281.00 ± 188.523
Lumbar musculature (%)	211.26-494.66	344.4986 ± 58.364

CSAM = cross-sectional area multifidus. SD = standard deviation.
VBA = vertebral body area.

Table 4: Pre- and post-operative clinical assessment.

	Related differences			
	Mean ± SD	Error	95%CI LL-UL	p
Lumbar VAS	5.340 ± 2.43	0.33	4.66-6.01	0.005*
SF36 physical	−49.94 ± 18.31	2.51	−54.99 - −44.89	0.005*
SF36 mental	−37.64 ± 17.71	2.43	−42.52 - −32.76	0.005*
RM	11.43 ± 5.33	0.733	9.96-12.90	0.005*
ODI	34.26 ± 21.66	2.97	28.29-40.23	0.005*

CI = confidence interval. LL = lower limit. ODI = Oswestry disability index. RM = Roland Morris. SD = standard deviation. UL = upper limit.
VAS = visual analog scale.
* $p < 0.05$.

Table 5: Testing of related samples.

Degree of fatty degeneration		Related differences			
		Mean ± SD	Error	95% CI LL-UL	Sig. (bilateral)
1	Lumbar VAS	4.375 ± 2.560	0.905	2.235-6.515	0.002
	SF36 physical	−45.000 ± 22.804	8.062	−64.064 - −25.936	0.001
	SF36 mental	−42.375 ± 23.970	8.475	−62.414 - −22.336	0.002
	Roland Morris	8.125 ± 5.303	1.875	3.691-12.559	0.003
	Oswestry	37.750 ± 20.742	7.333	20.410-55.090	0.001
2	Lumbar VAS	4.950 ± 2.544	0.569	3.759-6.141	0.005
	SF36 physical	−50.300 ± 14.291	3.195	−56.988 - −43.612	0.005
	SF36 mental	−39.700 ± 10.438	2.334	−44.585 - −34.815	0.005
	Roland Morris	12.100 ± 5.619	1.256	9.470-14.730	0.005
	Oswestry	29.600 ± 25.052	5.602	17.875-41.325	0.005
3	Lumbar VAS	5.722 ± 2.372	0.559	4.543-6.902	0.005
	SF36 physical	−50.500 ± 20.726	4.885	−60.807 - −40.193	0.005
	SF36 mental	−33.722 ± 22.962	5.412	−45.141 - −22.303	0.005
	Roland Morris	12.056 ± 4.929	1.162	9.605-14.506	0.005
	Oswestry	36.444 ± 20.915	4.930	26.044-46.845	0.005
4	Lumbar VAS	6.571 ± 1.813	0.685	4.895-8.248	0.005
	SF36 physical	−53.143 ± 19.794	7.481	−71.449 - −34.836	0.005
	SF36 mental	−36.429 ± 10.830	4.093	−46.445 - −26.413	0.005
	Roland Morris	11.714 ± 5.282	1.997	6.829-16.600	0.001
	Oswestry	38.000 ± 14.832	5.606	24.282-51.718	0.001

LL = lower limit. SD = standard deviation. UL = upper limit. VAS = visual analog scale.

back pain, and Teichtahl et al.[6] demonstrated relationships with disability in community adults, our surgical population appears to respond differently to intervention. This may reflect the fundamental difference between mechanical decompression/fusion versus conservative management for pain originating from different sources.

Notably, all patient groups experienced significant clinical improvement regardless of preoperative muscle morphology. This finding is particularly encouraging in the context of studies showing severe degeneration associations with poor outcomes.[13,21,22] Kim et al.[21] identified paraspinal muscle problems as risk factors for adjacent segment degeneration, but our results suggest this may not affect short-term surgical success. The potential for postoperative denervation atrophy identified by Sihvonen et al.[15] underscores the importance of surgical technique in preserving muscle function.

Clinical implications

Based on our findings, we propose the following clinical algorithm for preoperative assessment:

1. Routine CSAM measurement on preoperative MRI for all patients undergoing lumbar fusion.
2. Stratification of surgical complexity based on CSAM values:
   a. CSAM > 5,000 mm^2: anticipate increased bleeding risk and plan accordingly.
   b. CSAM 4,000-5,000 mm^2: standard surgical planning.
   c. CSAM < 4,000 mm^2: consider potential for easier dissection but assess bone quality.
3. Patient counseling emphasizing that fatty degeneration on MRI does not predict surgical outcomes.
4. Resource allocation optimization based on anticipated surgical complexity.

Limitations and future directions

This study has several limitations that should be acknowledged. Its retrospective design introduces inherent selection biases, though we employed rigorous inclusion criteria and statistical adjustments to mitigate these effects. The single-center nature may limit generalizability, though our cohort characteristics align with typical degenerative spondylolisthesis populations. While our visual grading scale showed excellent reliability, future studies would benefit from quantitative fat fraction measurements using chemical-shift imaging as employed by Hoppe et al.[7]

Additionally, we did not account for all potential confounders, such as specific surgical techniques or surgeon experience, though all procedures were performed by fellowship-trained spine surgeons using standardized approaches. The 12-month follow-up period provides robust short-to-medium term outcomes, but longer-term assessment is needed to evaluate the sustainability of clinical improvements.

Future research should focus on:

- Multicenter validation of our findings across diverse populations.
- Development of automated CSAM measurement tools for clinical implementation.
- Investigation of whether preoperative rehabilitation can modify surgical risk factors.
- Long-term assessment of muscle morphology changes following surgery.
- Exploration of genetic and metabolic factors influencing muscle degeneration patterns.

Conclusions

In patients undergoing L4-L5 fusion for degenerative spondylolisthesis, multifidus muscle volume correlates with surgical complexity parameters, including blood loss and complication rates. In contrast, fatty degeneration does not predict surgical outcomes or clinical improvement. These findings highlight the importance of comprehensive muscle morphology assessment in preoperative planning while challenging conventional assumptions about the prognostic significance of fatty infiltration.

From a clinical perspective, this distinction is crucial: surgeons can now use CSAM measurements to anticipate technical challenges while reassuring patients that fatty changes on MRI do not necessarily portend poorer surgical outcomes. The integration of muscle morphology assessment into routine preoperative evaluation represents a practical advancement in personalized surgical planning for lumbar degenerative disorders.

References

1. García-Ramos CL, Valenzuela-González J, Baeza-Álvarez VB, Rosales-Olivarez LM, Alpizar-Aguirre A, Reyes-Sánchez A. Degenerative spondylolisthesis I: general principles. *Acta Ortop Mex*. 2020; 34(5): 324-8.
2. Dallaway A, Kite C, Griffen C, Duncan M, Tallis J, Renshaw D, et al. Age-related degeneration of the lumbar paravertebral muscles: systematic review and three-level meta-regression. *Exp Gerontol*. 2020; 133: 110856.
3. Jun HS, Kim JH, Ahn JH, Chang IB, Song JH, Kim TH, et al. The effect of lumbar spinal muscle on spinal sagittal alignment: evaluating muscle quantity and quality. *Neurosurgery*. 2016; 79(6): 847-55.
4. Zhi-Jun H, Wen-Bin X, Shuai C, Zhi-Jie Z, Feng-Dong Z, Xiao-Jing Y, et al. Accuracy of magnetic resonance imaging signal intensity ratio measurements in the evaluation of multifidus muscle injury and atrophy relative to that of histological examinations. *Spine (Phila Pa 1976)*. 2014; 39(10): E623-9.
5. Kalichman L, Hodges P, Li L, Guermazi A, Hunter DJ. Changes in paraspinal muscles and their association with low back pain and spinal degeneration: CT study. *Eur Spine J*. 2010; 19(7): 1136-44.
6. Teichtahl AJ, Urquhart DM, Wang Y, Wluka AE, Wijethilake P, O'Sullivan R, et al. Fat infiltration of paraspinal muscles is associated with low back pain, disability, and structural abnormalities in community-based adults. *Spine J*. 2015; 15(7): 1593-601.
7. Hoppe S, Maurer D, Valenzuela W, Benneker LM, Bigdon SF, Hackel S, et al. 3D analysis of fatty infiltration of the paravertebral lumbar muscles using T2 images-a new approach. *Eur Spine J*. 2021; 30(9): 2570-6.
8. Faur C, Patrascu JM, Haragus H, Anglitoiu B. Correlation between multifidus fatty atrophy and lumbar disc degeneration in low back pain. *BMC Musculoskelet Disord*. 2019; 20(1): 414.
9. Kim S, Kim H, Chung J. Effects of spinal stabilization exercise on the cross-sectional areas of the lumbar multifidus and psoas major muscles, pain intensity, and lumbar muscle strength of patients with degenerative disc disease. *J Phys Ther Sci*. 2014; 26(4): 579-82.
10. Chen SM, Liu MF, Cook J, Bass S, Lo SK. Sedentary lifestyle as a risk factor for low back pain: a systematic review. *Int Arch Occup Environ Health*. 2009; 82(7): 797-806.
11. Kamaz M, Kiresi D, Oguz H, Emlik D, Levendoglu F. CT measurement of trunk muscle areas in patients with chronic low back pain. *Diagn Interv Radiol*. 2007; 13(3): 144-8.
12. Stanuszek A, Jedrzejek A, Gancarczyk-Urlik E, Kolodziej I, Pisarska-Adamczyk M, Milczarek O, et al. Preoperative paraspinal and psoas major muscle atrophy and paraspinal muscle fatty degeneration as factors influencing the results of surgical treatment of lumbar disc disease. *Arch Orthop Trauma Surg*. 2022; 142(7): 1375-84.
13. Ozcan-Eksi EE, Eksi M, Akcal MA. Severe lumbar intervertebral disc degeneration is associated with modic changes and fatty infiltration in the paraspinal muscles at all lumbar levels, except for L1-L2: a cross-sectional analysis of 50 symptomatic women and 50 age-matched symptomatic men. *World Neurosurg*. 2019; 122: e1069-e77.
14. Danneels LA, Vanderstraeten GG, Cambier DC, Witvrouw EE, De Cuyper HJ. CT imaging of trunk muscles in chronic low back pain patients and healthy control subjects. *Eur Spine J*. 2000; 9(4): 266-72.
15. Sihvonen T, Herno A, Paljarvi L, Airaksinen O, Partanen J, Tapaninaho A. Local denervation atrophy of paraspinal muscles in postoperative failed back syndrome. *Spine (Phila Pa 1976)*. 1993; 18(5): 575-81.
16. Da W, Jian Q, Evan J, Chan AK, McCormick PC, Mandigo CE, et al. Quantitative analysis of relationship between paraspinal muscle degeneration and degree of degenerative lumbar spondylolisthesis. *Spine (Phila Pa 1976)*. 2025; 50(19): 1327-35.
17. Liu S, Shi Q, Da WW, Xue CC, Chen L, Li YN, et al. Association between paraspinal muscle parameters and single-segment degenerative lumbar spondylolisthesis: retrospective, cross-sectional cohort study. *Spine (Phila Pa 1976)*. 2025; 50(12): 841-8.
18. Park S, Kim HJ, Ko BG, Chung JW, Kim SH, Park SH, et al. The prevalence and impact of sarcopenia on degenerative lumbar spinal stenosis. *Bone Joint J*. 2016; 98-b(8): 1093-8.
19. Tanishima S, Hagino H, Matsumoto H, Tanimura C, Nagashima H. Association between sarcopenia and low back pain in local residents prospective cohort study from the GAINA study. *BMC Musculoskelet Disord*. 2017; 18(1): 452.
20. Kjaer P, Bendix T, Sorensen JS, Korsholm L, Leboeuf-Yde C. Are MRI-defined fat infiltrations in the multifidus muscles associated with low back pain? *BMC Med*. 2007; 5: 2.
21. Kim JY, Ryu DS, Paik HK, Ahn SS, Kang MS, Kim KH, et al. Paraspinal muscle, facet joint, and disc problems: risk factors for adjacent segment degeneration after lumbar fusion. *Spine J*. 2016; 16(7): 867-75.
22. White AA 3rd, Gordon SL. Synopsis: workshop on idiopathic low-back pain. *Spine (Phila Pa 1976)*. 1982; 7(2): 141-9.

Conflict of interests: the authors declare that they have no conflicts of interest to disclose.

Ethical considerations: No funding was received for the development of this study. No data has been manipulated. All participants provided informed consent before their participation.