

# Arthroplasty as a treatment for acute and quiescent septic arthritis in native hips

*Artroplastía como tratamiento para la artritis séptica aguda y latente en caderas nativas*

Bochatey E,\* del Sel H,† Tillet F,§ Lopreite F¶

British Hospital of Buenos Aires, Argentina.

**ABSTRACT. Introduction:** The most feared complication in hip arthroplasty after septic arthritis is septic failure. It is considered that the two-stage treatment is the accepted treatment for acute septic hip arthritis. The objective in this work is to establish a therapeutic guideline for septic arthritis in native hips, proposing a two-stage treatment for acute, and a one-stage treatment for quiescent. **Material and methods:** Observational, descriptive, retrospective study. We analyzed all patients who underwent total primary hip replacement between June 1997 and June 2016. We selected those patients who had a diagnosis of septic arthritis of the hip prior to surgery (group 1: acute septic arthritis; group 2: quiescent septic arthritis). **Results:** Eight hips in group 1 with a follow-up of one to six years. Each patient fulfilled the antibiotic treatment between the placement of the spacer and the definitive prosthetic replacement, and, in all the cases, the remission of the infection was verified. On the other hand, 12 hips in group 2, the time between the treated infection and the prosthetic replacement varied between five and 46 years. The femoral heads sent to culture were in all cases negative. **Conclusions:** In the last 20 years, we have obtained satisfactory results, both in the treatment of acute septic arthritis and in its sequelae, interpreting them as pathologies of the same origin but with a different treatment. Both treatments are adequate, as long as the therapeutic protocol established for each of the groups is respected.

**Keywords:** Arthroplasty, septic arthritis, native hip.

**RESUMEN. Introducción:** La complicación más temida en la artroplastía de cadera después de la artritis séptica (activa o sus secuelas) es el fracaso séptico. El tratamiento en dos etapas, una vez resuelto el proceso infeccioso, es el tratamiento aceptado para la etapa aguda. El objetivo de este trabajo es establecer una pauta terapéutica para la artritis séptica en las caderas nativas, proponiendo un tratamiento en dos etapas para agudos, y un tratamiento de una etapa para las secuelas. **Materiales y métodos:** Realizamos un estudio observacional, descriptivo y retrospectivo. Analizamos a todos los pacientes que se sometieron a un reemplazo primario total de cadera en nuestra institución entre Junio de 1997 y Junio de 2016 con un diagnóstico de artritis séptica de la cadera antes de la cirugía (grupo 1: artritis séptica aguda; grupo 2: secuelas de artritis séptica). **Resultados:** Grupo 1: ocho caderas, con un diagnóstico agudo de artritis séptica y seguimiento de uno a seis años. Se cumplió con el tratamiento antibiótico entre la colocación del espaciador y el reemplazo protésico definitivo, y, en todos los casos, se verificó la remisión de la infección. Grupo 2: 12 caderas. El tiempo entre la infección tratada y el reemplazo de prótesis varió entre cinco y 46 años. Las cabezas femorales enviadas para cultivo eran en todos los casos negativas. **Conclusiones:** En los últimos 20 años, hemos obtenido resultados satisfactorios, tanto en el tratamiento de la artritis séptica aguda como en sus secuelas, interpretándolas como patologías del mismo origen pero con un tratamiento diferente. Ambos tratamientos son adecuados, siempre y cuando se respete el protocolo terapéutico establecido para cada uno de los grupos.

**Palabras clave:** Artroplastía, artritis séptica, cadera nativa.

## Level of evidence: IV

\* Cirujano especializado en cirugía de cadera y rodilla, Grupo GRECARO.

‡ Jefe de Servicio de Ortopedia y Traumatología del Hospital Británico de Bs As.

§ Fellow de artroplastía de cadera y rodilla, Hospital Británico de Bs As.

¶ Staff del Hospital Británico de Bs As. Cirujano especializado en cirugía reconstructiva de cadera y rodilla Grupo GRECARO.

## Correspondence:

Dr. Eduardo Bochatey  
Cervino 4417, 6toB, Capital Federal, C.P. C1425AHB. Buenos Aires, Argentina.

Received: 10-09-2020. Accepted: 21-02-2021.

**How to cite:** Bochatey E, del Sel H, Tillet F, Lopreite F. Arthroplasty as a treatment for acute and quiescent septic arthritis in native hips. Acta Ortop Mex. 2021; 35(1): 11-16. <https://dx.doi.org/10.35366/100924>



## Introduction

A patient who is dealing with a septic hip arthritis can be initially treated with arthroscopy or open debridement and antibiotics, but the risk of failure increases quickly in the first days after the appearance of the symptoms.<sup>1</sup> In those cases where the symptomatic period is prolonged and radiologic evidence of articular destruction is present, a more radical surgery is needed. Articular resection helps to eradicate infection, but it is associated with postoperative morbidities, like limbs length discrepancy, use of walking aids, and use of painkillers.<sup>2</sup> Historically, the deep prosthetics infection was treated only with resection arthroplasty.<sup>3</sup> Since the appearance of the antibiotic loaded spacers, that constitute an adjuvant treatment in the deep infection allowing the diffusion into the tissues, satisfactory results in the resolution of articular prosthetics infections were obtained, keeping a sufficient articular function in between the resection surgery and the reimplantation, with an adequate tension of the soft tissues, allowing the weight loading and facilitating the subsequent revision and articular reconstruction.<sup>4,5,6</sup>

The most feared complication in hip arthroplasty after a septic arthritis (active or quiescent) is the septic failure. The treatment in two times, using spacers and replacing them with a definitive prosthesis in a second time, once the infectious process is resolved, is considered to be the accepted treatment for acute septic arthritis of the hip. However, it is possible to define a treatment in one time for the sequelae of quiescent septic arthritis, taking as parameters of infection resolution the following conditions: the normalization of laboratory values (ESR and CRP), the clinical status, and the time elapsed between the resolution of the infection and the moment of the joint replacement. In these cases, the type of germ responsible for the primary infection has no relevance, as long as the times of treatment and quiescence have been respected as described by Kim et al.<sup>7</sup>

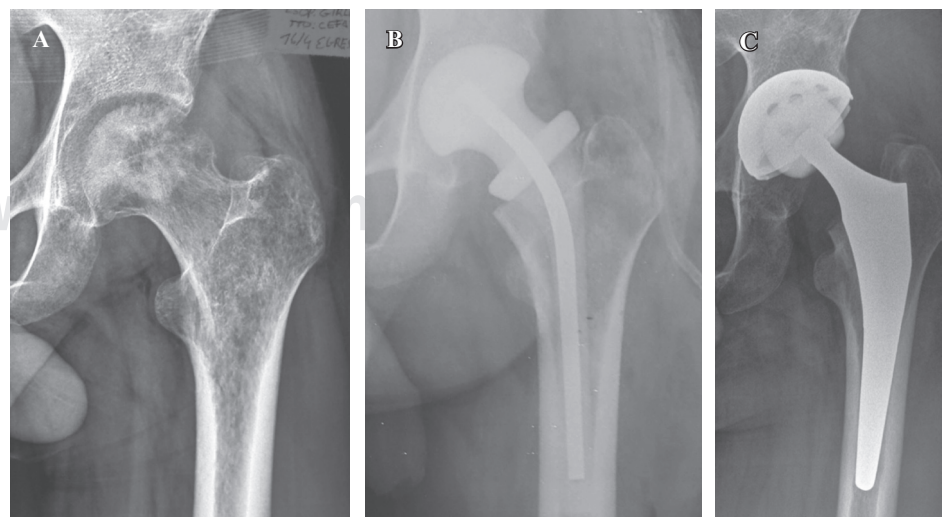
The objective that we set ourselves in this work is to establish, based on the cases treated in our Hospital, a therapeutic guideline for septic arthritis on native hips, proposing a treatment in two stages for acute septic arthritis, and in one stage for the quiescent ones.

## Material and methods

We define the acute septic arthritis as those that present clinical (spontaneous pain that increases with hip mobility, load intolerance, fever, phlogosis and swelling) and laboratory (leukocyte count, ESR and CRP) parameters altered. In addition, radiological evidence of coxo-femoral joint condition must be found, which compromises the femoral head, presenting osteolysis areas and bone loss (*Figure 1*). Finally, positive samples for a germ in the joint puncture should be obtained.

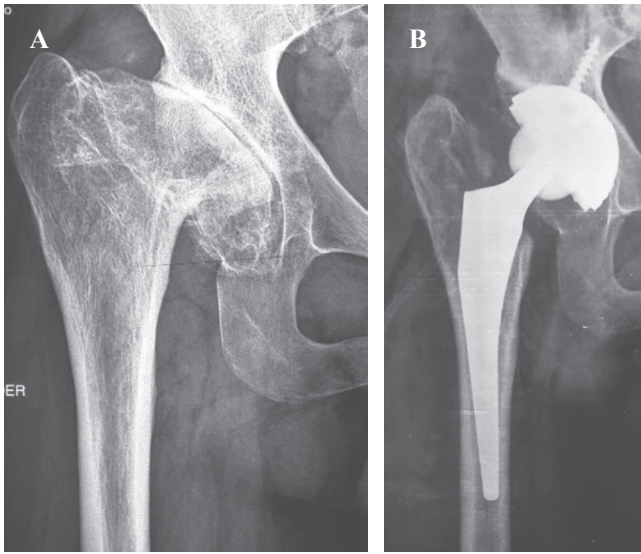
The definition of quiescent septic arthritis is reserved for those patients for whom there is a history of acute septic arthritis, who have completed an accurate antibiotic treatment, after which it is possible to demonstrate normalization of laboratory values and absence of clinical signs that suggest ongoing infection. These patients present clinical and/or radiological signs of articular alteration (*Figure 2*) that require treatment with a hip replacement.

We conducted an observational, descriptive, retrospective study, in which we analyzed all patients who have been operated from primary total hip replacement in our hospital between June 1997 and June 2016. We selected those patients who have had a diagnosis of septic hip arthritis prior to surgery. We divided them into the two previously defined groups (group 1: acute septic arthritis; group 2: quiescent septic arthritis). We excluded from the study those patients under the age of 15, those who have a follow-up of less than one year, and those who have had a previous prosthesis or osteosynthesis material in the affected joint or adjoining to it.



**Figure 1:**

**A)** Acute septic hip arthritis with lytic changes in the femoral head. **B)** First surgical stage. Cement spacer placement with ATB. **C)** Final implant placement.



**Figure 2:** **A)** Septic sequel of childhood septic arthritis in a 37-year-old patient. (Quiescent). **B)** One stage treatment of the sequel of septic arthritis with total arthroplasty.

In the period 1997-2016, 6263 primary hips were operated. The population studied includes 18 patients with 20 hips (2 bilateral), who are over 15 years old, with diagnosis of septic arthritis of native hip, either acute or quiescent, treated with total hip arthroplasty, with a follow-up greater than one year. The data of the clinical history were analyzed, transferring the Harris Hip Score, the treatments made and the background of infection into an Excel board (*Tables 1 and 2*).

Patients (group 1) with evolving septic arthritis (eight hips in six patients) were evaluated separately, to whose hip a joint puncture was performed in order to diagnose and isolate the germ. Subsequently, they were treated in two stages. Initially, the surgical procedure was carried out with synovectomy, resection of the femoral head, milling of the acetabulum with removal of the articular cartilage, and five samples for culture and antibiogram were obtained. An antibiotic (ATB) loaded spacer was placed, generally with Gentamicin and, in case of adding cement, this was mixed with Vancomycin (1 to 3 grams). Subsequently, we continued with an intravenous antibiotic treatment, and then orally complying it with a minimum time of 6 weeks, which was established by our Hospital Infectology Service.

In a second time, once the laboratory values (ESR and CRP) were normalized, taking two values without ATB treatment with a difference of two weeks between them. Once the remission of the infection was determined, the final prosthesis was placed. The type of prosthesis to be used (uncemented, hybrid or cemented) was selected according to the age, functional demand, and bone quality. In cases of hybrid or cemented implants, ATB added to cement was used as infection prophylaxis (no more than 1 g per dose of cement), but not as a treatment for the infection since

the infection was considered resolved before performing the joint replacement procedure (*Figure 1 A to C*).

On the other hand, group 2 includes patients with septic arthritis considered in remission of infection (12 hips in 11 patients), which may be a sequela which may have been acquired in childhood, or which may have been acquired in adult septic arthritis who were resolved with antibiotic treatment at the time of programming the surgical treatment. These patients were free of infections for at least two years since the end of the treatment, and had normal laboratory values, with negativity in the ESR and CRP values, and underwent favorable clinical evolution. In them, arthroplasty in one time was performed, using the usual antibiotic prophylaxis scheme (cefazolin 1-2 g ev in anesthetic induction and during the first 24 hours after surgery) for the infection prophylaxis. All femoral heads were sent to culture. No previous joint puncture was performed in this group of patients, since, as described by Bauer et al., it would not be useful in detecting persistent infections of low virulence in quiescent septic arthritis, which explains the high number of false negatives reported by the authors (*Figure 2 A and B*).

In our protocol, we do not consider the use of postoperative antibiotic schemes different from the usual one, because we interpret the alteration of these hips as sequelae of infectious processes already resolved, as reported by Kim et al.<sup>11</sup> the final result was evaluated in terms of success. In the case of acute septic arthritis, a successful treatment would result in the eradication of the infection (normalization of ESR and CRP), and, in the case of quiescent septic arthritis, the nonrecurrence of the infection. The pre and post-operative functional results were analyzed using the Harris Hip Score.

**Statistic analysis:** quantitative variables were described by means and standard deviation, and categorical variables by percentage. The differences in the quantitative variables between the test groups were compared with the differences between proportions with the  $\chi^2$  test. Consider statistically significant differences at probabilities less than 0.05. Statistical analysis was performed with STATA version 13.0 software.

## Results

Group 1 (acute septic arthritis) includes eight hips of seven patients (one bilateral), three women and four men with an average age of 49.25 years old (21 to 74 years old) at the time of diagnosis, and a follow-up of one to six years (average 2.25 years). The isolated germs were *Staphylococcus aureus* in four cases (1 resistant to methicillin), *Streptococcus pneumoniae* in three cases, and *Bacteroides spp* in one case (*Table 3*). All patients underwent an antibiotic treatment of six to 12 weeks (average of nine weeks), between the placement of the spacer and the final prosthetic replacement, and, in all cases, the remission of the infection was verified by normalizing the ESR and the C-reactive protein values. In all cases, the antibiotic treatment was finished 30 days before

arthroplasty. The final result in all cases was satisfactory, with notable improvement in functionality and absence of pain, improving from a HHS of 22 points at the beginning of the disease, to a HHS of 93 points, on average, at the end. This result showed to be statistically significant, in favor of group 1 ( $p$  0.001). No postoperative complications or exacerbation of the infectious process were observed until the present date.

On the other hand, group 2 (quiescent septic arthritis) includes 12 hips of 11 patients (one bilateral), six women and five men, with an average age of 49.20 years old (16 to 81 years old) at the time of surgery. The time elapsed between the treated infection and the prosthetic replacement varied between five and 46 years (average 18.83 years). Femoral heads sent to culture were in all cases negative (Table 3). The functional results obtained from the Harris Hip Score in this group improved from an average initial value of 37 points, to an average end of 88 points. Some patients remained with certain limitations in their mobility, as a consequence of the previous stiffness product of so many years of evolution that generated soft tissue retraction. However, they all evolved with a significant functional improvement of the treated joint.

The postoperative follow-up of the patients of both groups was no different from the usual one for all patients with total primary hip arthroplasty in our hospital. The postoperative controls were carried out, first in the third week, then in the sixth week, and then in the third and sixth months; finally, since there, an annual control was to be carried out. No follow-up, nor postoperative control laboratory studies, was undertaken by the infectology department, because these were considered patients with infectious disease resolution and with their respective infectious discharge prior to joint replacement surgery.

## Discussion

Primary septic arthritis of the hip in adults is a rare but potentially devastating disease.<sup>2</sup> When performing this work, it became clear the importance of differentiating and defining acute and quiescent septic arthritis, thus treating them as individual pathologies, with their particular preoperative evaluation, treatment and follow-up.

In acute septic arthritis, the symptomatology is that of an active infection and the treatment goes in that direction,

**Table 1: Corresponding to group 1 (acute septic arthritis group). The type and time of treatment of the patients is described.**

Patient	Gender	Birthdate	Isolated germ	Spacer implantation date	Antibiotic period between surgeries (weeks)	Arthroplasty date
FJ	Male	07/31/39	<i>S. pneumoniae</i>	08/16/11	9	12/06/11
SG	Female	11/22/41	<i>S. pneumoniae</i>	08/05/15	8	10/15/15
CM	Female	01/01/75	<i>Bacteroides spp.</i>	03/31/15	12	07/07/15
PC	Male	04/01/76	<i>Meticiline-sensible S. aureus</i>	02/17/16	8	05/23/16
GM	Male	05/10/94	<i>Meticiline-sensible S. aureus</i>	08/06/15	11	12/11/15
GM	Male	05/10/94	<i>Meticiline-sensible S. aureus</i>	08/06/15	11	12/11/15
CA	Male	01/11/57	<i>Meticiline-sensible S. aureus</i>	06/14/16	6	09/15/16
DM	Female	05/21/48	<i>S. pneumoniae</i>	03/11/15	8	06/04/15

**Table 2: Corresponding to group 2 (quiescent septic arthritis group). The time elapsed between the age of infection and the joint replacement is described.**

Patient	Gender	Birthdate	Age of infection (years)	Quiescent period (years)	Arthroplasty date
LA	Male	02/04/44	15	38	07/29/97
SA	Female	10/12/55	40	5	09/18/01
SM	Male	03/12/47	12	46	06/01/05
PS	Male	10/25/59	11	37	03/18/08
FP	Male	10/05/76	13	19	02/17/09
PC	Female	07/20/29	48	33	08/09/10
DE	Female	12/04/96	Neonatal	16	06/26/13
DE	Female	12/04/96	Neonatal	16	06/26/13
CF	Male	11/27/79	8	27	05/15/15
PS	Female	02/04/74	10	30	10/06/14
SE	Female	01/11/84	Neonatal	31	07/26/16

**Table 3: Socio-demographic and clinical characteristics of the patients, and functional results.**

	Acute septic arthritis	Quiescent septic arthritis	p
Gender, N (%)			
Female	3 (37.5)	6 (54.55)	0.47
Male	4 (62.5)	5 (45.45)	
Age (years)	49.25 (21-74)	49.20 (16-81)	–
Follow up (years)	2.25 ± 1.03	3.09 ± 2.02	0.25
Time between infection/THA (years)	–	18.83 (5-46)	–
Culture isolation		No isolation	–
<i>Staphylococcus</i>	4		
<i>Streptococcus</i>	3		
<i>Bacteroides</i> spp	1		
Harris hip score			
Pre-operation	22 ± 3.58	37 ± 5.42	0.001
Postoperation	93 ± 2.26	88 ± 1.94	0.001

with surgical cleaning and antibiotics. As for quiescent arthritis, the treatment is that of the sequel in a joint infection with its destruction. Although the high cure rate allowed by antibiotic cement spacers and their greater efficacy has been demonstrated for years, compared to that of previous procedures (such as antibiotic cement beads), in preserving joint function and facilitating the revision of that joint for the treatment of prosthetic infection, a protocolized treatment which differentiates acute septic arthritis from quiescent septic arthritis in native hips is not yet described.

Whatever the bacteria involved (pyogenic or mycobacteria), the role of arthroplasty in these pathologies remains clear. The risk of complications, and especially of failure, due to infection (due to preoperative contamination in evolutionary septic arthritis, or due to exacerbation in quiescent ones) is difficult to determine,<sup>8</sup> despite of not having, in our results, patients with postoperative infection or recurrence.

Referring specifically to acute septic arthritis, some authors, such as Jupiter et al., suggest in their work that arthroplasty can be performed in one time, either for acute or quiescent septic arthritis, obtaining results comparable to those obtained in a two-time treatment.<sup>9</sup>

Anagnostakos et al. describe a high rate (87%) of control of acute septic arthritis with two-stage treatment, but also highlight the high mortality rate between the first and second stage (8.8%).<sup>2</sup> Bauer et al.<sup>3</sup> resolved an 85% of cases by applying two-stage arthroplasty for acute septic arthritis of 13 hips, taking into account that these authors evaluated hips and knees equally.

Our choice of a two-stage treatment for acute septic arthritis was to perform initial infection control by treating the condition with an antibiotic loaded spacer. The previous puncture of the joint in these cases allowed to identify the

germ involved and use in the cement the corresponding antibiotic, according to the sensitivity that it presented. Likewise, we consider as the treatment of choice for these cases: the surgical cleaning with removal of the femoral head, and the treatment with ATB until the normalization of the patient's laboratory, and then proceed to the final implant. This allows greater predictability in the results and practically ensures the placement of a prosthesis in an infection free joint.

In relation to the hips with history of infection that we call quiescent, the treatment consists in solving the sequelae of a joint that is usually severely damaged. There are some guidelines that must be taken into account. On the one hand, it is important to have a normal laboratory with regard to infection (normal ESR and CRP). Also significant is the time that the infection has been in remission.<sup>10,11</sup> According to Kim et al.,<sup>7</sup> the longer the symptom-free interval between the initial infection treated and the arthroplasty, the higher the success rate and the lower the risk of reinfection.

Another point to highlight is the preoperative biopsy that, in the case of active infection in acute septic arthritis, is mandatory to diagnose and identify the pathogen involved in it. However, as described by Bauer et al. in their work, where they obtained seven false negatives in 23 patients, it is not a sensitive practice to detect persistent infections of low virulence in quiescent septic arthritis.<sup>3</sup> In our experience, prior joint puncture does not seem to be a practice of strict necessity. In the group of patients with sequelae of septic arthritis, puncture was not performed routinely, and the little use of this procedure was reflected in the fact that femoral head cultures were all negative. Similarly, the functional recovery of patients with acute septic arthritis was different compared to quiescent. The patients treated with the acute condition presented a better functional recovery and this is mainly due to the fact that patients with septic arthritis sequelae have an interval of years between the treated infection and the prosthetic implant and may even have previous surgeries,<sup>12</sup> with retraction of tissues, anatomical alterations of the joint and muscular atrophy. We believe that one stage joint replacement in quiescent arthritis is the method of choice. Bauer et al. obtained a 100% resolution through one stage arthroplasty for the nine quiescent hips.<sup>3</sup> In our hands, the result was highly satisfactory with this procedure, also obtaining 100% good results.

The same authors propose to associate postoperative antibiotic therapy in cases of quiescent septic arthritis, until the results of the cultures are obtained.<sup>3</sup> In our therapeutic protocol, we do not include any antibiotic scheme beyond that used for the prophylaxis of infection that is carried out for arthritic hips with Cefazolin. All femoral heads were sent to culture, which yielded all negative results. The use of such femoral heads as a source of bone graft is not recommended.<sup>11</sup>

The main weakness this work presents is the limited number of patients evaluated, which coincides with the numbers published in other works and in that it is retrospective. Despite this, the work presents considerable strengths: in all cases, the same protocol was applied; the cases are consecutive, all corresponding to the same joint, not comparing hips and knees; and its original character considering it is a national publication. This work may be considered as an important starting point in the study of two pathologies that, even though they can be mistakenly interpreted as one, they must be considered, evaluated and treated differently.

## Conclusions

In our experience of the last 20 years, we have obtained satisfactory results, that is why we believe it is possible to establish a therapeutic protocol for primary septic hip arthritis. In two stages for active infections, with the placement of antibiotic loaded spacer in a first stage, followed by a period of not less than six weeks of antibiotic treatment, and, once the values of ESR and CRP have been normalized, the placement of the definitive hip prosthesis.

The treatment in one stage for quiescent infections with at least two years between the remission of the infection and the placement of the implant, is the one of choice, verified by already negative values of ESR and CRP, with the placement of the definitive hip prosthesis.

## References

1. Romano CL, Romano D, Meani E, Logoluso N, Drago L. Two-stages revision surgery with preformed spacers and cementless implants for septic hip arthritis: a prospective, non-randomized cohort study. *BMC Infect Dis.* 2011; 11: 129.
2. Anagnostakos K, Duchow L, Koch K. Two-stages protocol and spacer implantation in the treatment of destructive septic arthritis of the hip joint. *Arch Orthop Trauma Surg.* 2016; 136 (7): 899-906.
3. Bauer T, Lacoste S, Lhotellier L, Mamoudy P, Lortat-Jacoba A, Hardya P. Arthroplasty following a septic arthritis history: a 53 cases series. *Orthop Traumatol Surg Res.* 2010; 96: 840-3.
4. Romano CL, Romano D, Albisetti A, Meani E. Preformed antibiotic-loaded cement spacers for two-stage revision of infected total hip arthroplasty. Long-term results. *Hip Int.* 2012; 22 (Suppl 8): S46-53.
5. Romano CL, Romano D, Logoluso N, Meani E. Long-stem versus short-stem preformed antibiotic-loaded cement spacers for two-stage revision of infected total hip arthroplasty. *Hip Int.* 2010; 20 (1): 26-33.
6. Vielgut I, Sadoghi P, Wolf M, Holzer L, Leithner A, Schwantzer G, et al. Two-stage revision of prosthetic hip joint infections using antibiotic-loaded cement spacers: when is the best time to perform the second stage? *Int Orthop.* 2015; 39 (9): 1731-6.
7. Kim YH, Oh SH, Kim JS. Total hip arthroplasty in adult patients who had childhood infection of the hip. *J Bone Joint Surg Am.* 2003; 85 (2): 198-204.
8. Chen CE, Wang JW, Juhn RJ. Total hip arthroplasty for primary septic arthritis of the hip in adults. *Int Orthop.* 2008; 32: 573-80.
9. Jupiter JB, Karchmer AW, Lowell JD, Harris WH. Total hip arthroplasty in the treatment of adult hips with current or quiescent sepsis. *J Bone Joint Surg Am.* 1981; 63 (2): 194-200.
10. Hardinge K, Cleary J, Charnley J. Low-friction arthroplasty for healed septic and tuberculous arthritis. *J Bone Joint Surg Br.* 1979; 61-B (2): 144-7.
11. Lopreite F, Garabano G, Mana Pastrian D, del Sel H. Artroplastia de cadera en un paciente con secuela de tuberculosis. *Rev Asoc Argent Ortop Traumatol.* 1974, pp. 145-7.
12. Jagadishwer Rao K, Prasad D, Jain K. Management of sequelae of septic arthritis of hip. *Indian J Orthop.* 2007; 41 (4): 404-6.