

A management algorithm for vertebral destruction syndrome by multiple myeloma and metastatic spinal cord compression

Algoritmo de manejo para el síndrome de destrucción vertebral por mieloma múltiple y compresión metastásica de la médula espinal

Mireles-Cano JN,* Escoto-Venegas E,* García-González OG,* Miranda-González A,* González-Ramírez J,* Hernández-Sepúlveda E,* Martínez-Pérez R*

Hospital Regional de Alta Especialidad del Bajío, Universidad de Guanajuato.

ABSTRACT. Introduction: Multiple myeloma represents 1% of all cancers and 10% of hematological cancers. Up to 80-90% of cases will have skeletal involvement and the spine is the most frequently involved site. Any intervention must be aimed to improve the patient's functional prognosis and will impact their quality of life. **Objective:** To describe the clinical presentation of vertebral destruction syndrome due to multiple myeloma and to present the management algorithm used for the study and decision-making in treatment. **Material and methods:** *Study design:* Retrospective cross-sectional. A search was made in the hospital's clinical file in search of patients with a histological diagnosis of multiple myeloma attended by the Spinal Surgery Service. Clinical characteristics of the initial presentation were obtained such as: presence of pain, ASIA scale and it was categorized according to the Durie-Salmon classification at diagnosis; the levels involved and type of surgery were described. **Results:** The study included ten patients with an average age of 61.4 years, 70% were male subjects. All patients were approach according to the modified protocol for vertebral destruction syndrome and fluoroscopy-guided percutaneous biopsy. Most had pain at diagnosis, after neurologic examination only 30% were classified as ASIA A. Most of the patients were staged III according to Durie Salomon. The most frequently vertebral segment involved was thoracic. In only one patient more than two vertebrae were involved. After diagnosis of multiple myeloma, nine patients were managed according to

RESUMEN. Introducción: El mieloma múltiple representa 1% de todos los tipos de cáncer y 10% de los cánceres hematológicos. Hasta en 80-90% de los casos se involucrará el sistema esquelético, siendo la columna el sitio más frecuentemente afectado. Cualquier intervención planeada deberá ser dirigida a mejorar el pronóstico funcional del paciente e impactará en su calidad de vida. **Objetivo:** Describir la presentación clínica del síndrome de destrucción vertebral por mieloma múltiple y presentar el algoritmo de manejo empleado para el estudio y la toma de decisiones en el tratamiento. **Material y métodos:** *Diseño de estudio:* Retrospectivo, transversal. Se realizó una búsqueda en el archivo clínico del hospital en búsqueda de pacientes con diagnóstico histológico de mieloma múltiple atendidos por el Servicio de Cirugía de Columna. Se obtuvieron características clínicas de la presentación inicial como: presencia de dolor, escala de ASIA y se categorizó de acuerdo con la clasificación de Durie-Salmon al diagnóstico; se describen los niveles involucrados y tipo de cirugía. **Resultados:** El estudio incluyó 10 pacientes con una edad promedio de 61.4 años, 70% de los cuales fueron varones. Todos los pacientes se abordaron de acuerdo al protocolo de síndrome de destrucción vertebral y con biopsia percutánea guiada por fluoroscopia. La mayoría de los pacientes tenían dolor al diagnóstico, tras la exploración neurológica sólo el 30% fueron clasificados como ASIA A. La mayoría de los pacientes se estadificaron como III de acuerdo con Durie-Salmon. El segmento vertebral más comúnmente afectado

Level of evidence: IV

www.medigraphic.org.mx

* Spine Surgery. Neurosurgery Department. Hospital Regional de Alta Especialidad del Bajío, Universidad de Guanajuato. León, Gto., México.

Correspondence:

Dr. José Nicolás Mireles-Cano

ORCID ID: <https://orcid.org/0000-0001-8352-9732>.

Apolo XI, 418, int. 316, Col. Futurama Monterrey, ZIP Code: 37180, León, Guanajuato, México.

E-mail: fellowhraeb@gmail.com

How to cite: Mireles-Cano JN, Escoto-Venegas E, García-González OG, Miranda-González A, González-Ramírez J, Hernández-Sepúlveda E et al. A management algorithm for vertebral destruction syndrome by multiple myeloma and metastatic spinal cord compression. Acta Ortop Mex. 2020; 34(5): 293-297. <https://dx.doi.org/10.35366/97991>



a NOMS framework. In the majority they were treated with fusion by posterior approach, six of them were augmented with vertebroplasty. Only one patient of the total, was treated with vertebroplasty alone. **Conclusions:** The use of systematized management algorithms will allow better decisions to be made in conjunction with a multidisciplinary group for the care of multiple myeloma with vertebral involvement.

Keywords: Multiple myeloma, metastatic spinal cord compression, vertebral destruction syndrome.

fue el torácico. En sólo un paciente se involucraba más de dos vértebras. Tras el diagnóstico de mieloma múltiple, nueve pacientes fueron manejados de acuerdo con el marco de trabajo NOMS. La mayoría fueron tratados con fusión por un abordaje posterior, seis de ellos con aumentación con vertebroplastia. Sólo un paciente del total, fue tratado sólo con vertebroplastia. **Conclusiones:** El empleo de algoritmos de tratamiento sistematizado permitirá la toma de mejores decisiones en conjunto con un grupo multidisciplinario para el tratamiento de mieloma múltiple con afección vertebral.

Palabras clave: Mieloma múltiple, compresión metastásica de la médula espinal, síndrome de destrucción vertebral.

Introduction

Multiple myeloma could be considered as the malignant counterpart of plasma cells in which there is cell proliferation with multiple organic involvement, with particular affinity for bone and bone marrow.¹ It represents 1% of all cancers and 10% of hematological cancers, which is why it ranks second in this group. The average age of diagnosis is 65 years. There is a predominance in males and the incidence is double in African-American patients compared to Caucasians. The most recent update of the criteria of the International Myeloma Working Group (IMWG) postulates that the diagnosis requires three of the following components: > 10% of monoclonal plasma cells in bone marrow and/or a biopsy with evidence of plasmacytoma; serum and/or urinary monoclonal protein and have at least one of the «CRAB» criteria: calcium elevation, renal failure, anemia or lytic bone lesions greater than 5 mm.² Up to 80-90% of cases will have skeletal involvement.³ The spine is the most frequently involved site, affecting up to 60% of patients at presentation and up to 15-30% of patients developing new lesions in late stages. For this association, the spine specialist must have a clear understanding of this entity and include it in differential diagnoses during the systematic approach of the patient

with vertebral destruction syndrome, since early recognition and timely multidisciplinary intervention will improve the patient’s functional prognosis and will impact your quality of life. The purpose of this study is to describe the clinical characteristics at the presentation of patients with histological diagnosis of multiple myeloma, as well as to detail the diagnostic and treatment algorithm used, from the moment of presentation to the decision of a definitive treatment.

Material and methods

A retrospective, descriptive and cross-sectional design study was carried out in the period from March 2012 to February 2017 with the authorization of the hospital’s research and ethics committee under code CEI-29-16. A review was made of the electronic files of patients with a diagnosis of vertebral destruction syndrome who were referred to the Spine Surgery Service of a third-level care center, including only those patients with a histological diagnosis of multiple myeloma. In addition to demographic data, clinical information was sought: presence of pain, ASIA scale and categorized according to the Durie-Salmon classification at diagnosis; levels involved and type of surgery.

Multiple myeloma and vertebral destruction syndrome case series			
Durie-Salmon staging system			
I $0.6 \times 10^{12}/m^2$	II Intermediate volume	III $1.2 \times 10^{12}/m^2$	A
Fulfill all the following: <ul style="list-style-type: none"> • Hemoglobin > 10 g/dl • Serum calcium < 12 mg/dl • No skeletal lesions or solitary plasmacytoma • IgG < 5 g/dl or • IgA < 3 g/dl or • Monoclonal urinary protein < 4 g/24 hours 	<ul style="list-style-type: none"> • No criteria for I or III stage 	Any of the following: <ul style="list-style-type: none"> • Hemoglobin < 8.5 g/dl • Serum calcium > 12 mg/dl • Multiple osteolytic lesions, fractures • IgG > 7 g/dl or • IgA > 5 g/dl or • Monoclonal urinary protein > 12 g/24 hours 	Serum creatinine: < 2 mg/dl B Serum creatinine: > 2 mg/dl

Figure 1:

Durie-Salmon clinical staging system. Clinical criteria to estimate the spread of neoplastic cells in multiple myeloma. Modified from: Durie BG, et al.⁵

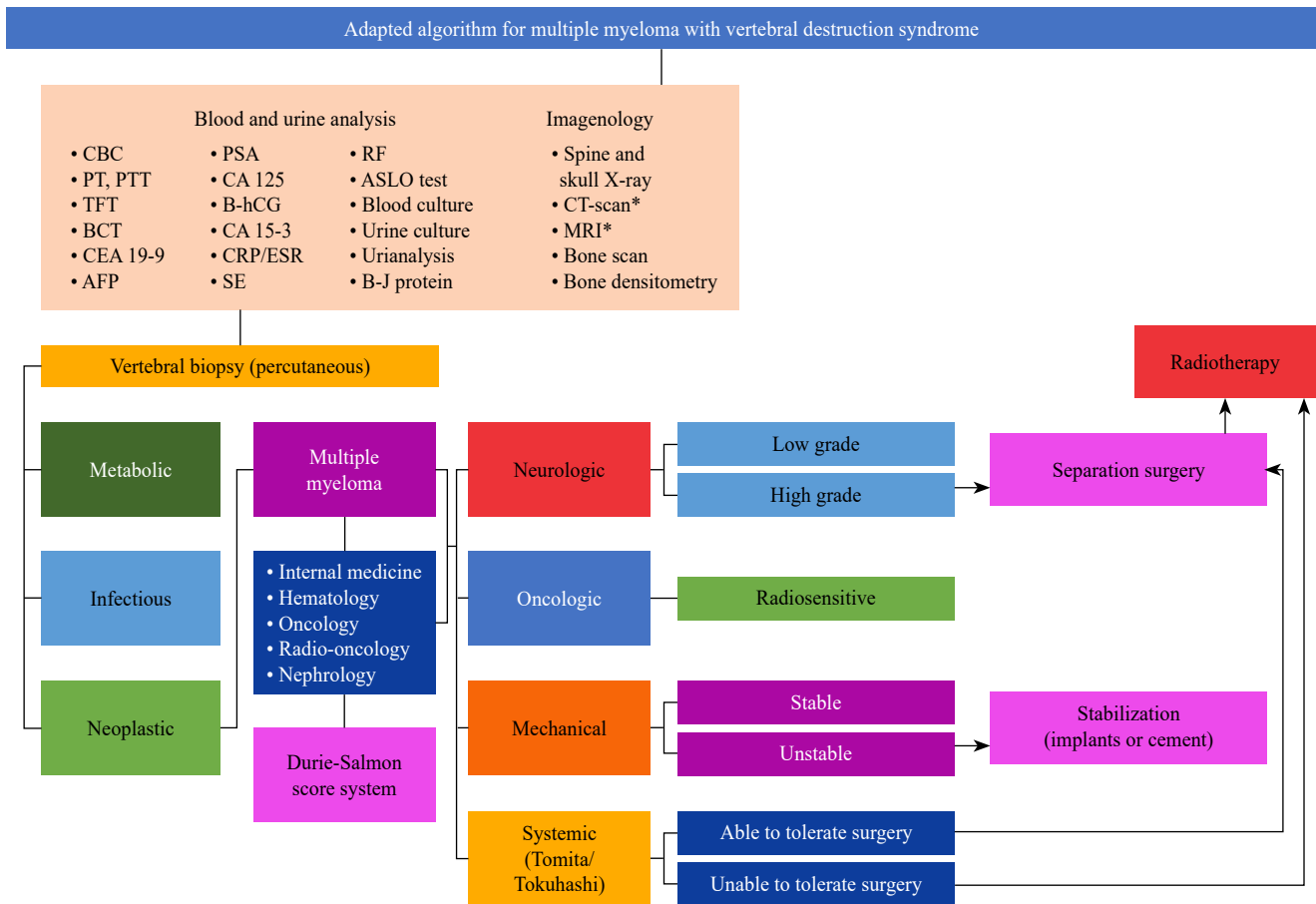


Figure 2: Proposal of management algorithm used.

BH = complete blood count; TP = prothrombin time; TTP = thromboplastin time; PFT = thyroid function tests; QC 6 = clinical blood chemistry of 6 elements; AFP = alpha-fetoprotein; APE = prostate specific antigen; B-hCG = fraction B human chorionic gonadotrophin; PCR/ESR = C reactive protein and erythrocyte sedimentation rate; SE = serum electrolytes; RF = rheumatoid factor; EGO = general urine test; B-J = Bence-Jones protein; CAT = computerized axial tomography; MRI = magnetic resonance imaging. * Simple and contrasted.

Diagnostic algorithm

All patients attended by the hospital’s spinal service for vertebral destruction syndrome require completing the protocol described by Alpizar-Aguirre et al. and modified by our institution, which includes a series of serum and urine tests; Conventional radiographs, magnetic resonance imaging, computed axial tomography and bone scan. After an analysis of these elements, a biopsy of the spinal tissue involved is performed.⁴ This allows us to increase the sensitivity of our diagnostic approach by differentiating between the three etiologies of vertebral destruction: infectious, metabolic, and neoplastic. After having a histological diagnosis, the patient is sent to the internal medicine, hematology, oncology and radio-oncology service to provide medical treatment, prognosis and multidisciplinary follow-up. In the case of patients with multiple myeloma, the staging described by Durie-Salmon⁵ (Figure 1) is used and additionally it refers to the nephrology department. After this comprehensive assessment, the joint decision is made in accordance with the NOMS reference framework (Neurologic, Oncologic, Mechanical,

and Systemic),⁶ the most appropriate definitive surgical treatment with the least possible morbidity. This allows the management of the increasingly frequent population with spinal cord compression due to malignancy (CMEM) to be standardized. The algorithm used is presented (Figure 2).

Results

Ten patients with histological diagnosis of vertebral multiple myeloma were included in the study period obtained by the spine surgery service, with an average age of 61.4 years (49 to 83). 30% women and 70% men. All the patients were approached with the modified protocol of the vertebral destruction syndrome described and subsequently underwent percutaneous biopsy. All presented axial pain at some point in the evolution. At diagnosis 60% had an incomplete spinal cord injury classified as ASIA D, 30% were in ASIA A and only in one patient was there integrity with ASIA E. The patients were categorized according to the Durie-Salomon stages for multiple myeloma, half of the patients were in stage III, 40% in stage II and only one patient was classified as I. Anemia was diagnosed in 60% of the patients, of these four patients with

hemoglobin levels below 7.5 g/dl. One patient was diagnosed with kidney failure. Two patients had hypercalcemia.

Of the total number of patients, there were 17 vertebrae involved. The most frequently affected segment was the thoracic with 59% (n = 10) of the total vertebrae. Followed by the lumbar with six vertebrae and the sacrum with a vertebra involved at this level.

The distribution of levels affected by patient was variable, half of the patients presented with only one vertebral level involved. 4 patients 2 levels and only one patient with 4 levels involved.

After multiple myeloma diagnosis by fluoroscopy-guided percutaneous biopsy in all the patients, they were sent to the oncology service where they received hematological medical treatment and subsequently underwent a surgical procedure according to the NOMS reference framework in 9 of them. Fusion with posterior instrumentation was performed in 8 patients; in 6 of them, vertebroplasty was additionally performed. Only in one patient was vertebroplasty used as the only form of definitive treatment. The summary of the series is presented in (Table 1).

Discussion

The association of multiple myeloma with vertebral lesions is classically described in the literature. In a series of 1027 patients, Kyle et al reported that radiographic bone abnormalities were found at some point in the disease in 84% of the patients, such as lytic lesions, pathological fractures, vertebral compression fractures and osteopenia.⁷ Most of these injuries affect the vertebral body, but they can be found in posterior bony elements: facets, pedicles, transverse and

spinous processes. Weakness results in asymmetric vertebral wedging with potential compromise of spinal stability and neurological function,⁸ since multiple myeloma has been reported to be one of the most frequent causes of CMEM, being responsible for up to 11.1% of hospitalizations for this complication in the United States, only two places behind lung cancer (24.9%) and prostate cancer (16.2%).⁹

In the presented series, all patients obtained a first-time diagnosis and began their study by a spinal surgery service at a third-level center. Most had some degree of spinal compression at the time of initial assessment. It is not uncommon for the initial presentation of this neoplasm to include spinal compression. In the Benson et al series, 66% of patients with multiple myeloma presented with paraplegia, which in most were preceded by axial pain, sensory deficit, or progressive paraparesis.¹⁰ For the spinal surgeon treating a patient with vertebral destruction, it is advisable to have systematized management methods. The spectrum of differential diagnoses is very broad and includes, in addition to primary and metastatic neoplasms, simulatory processes such as infections and injuries due to metabolic diseases. Standardized diagnostic approaches that cover the different causes, such as the previously used modification, will allow identifying the disease that is being faced and consequently making better decisions.

Once a primary or metastatic tumor has been identified, the degree of compression and the presence of instability should be considered and evaluated. A reproducible method for the latter is the Spinal Instability in Neoplastic Disease (SINS) classification system that defines whether the patient requires stabilization,¹¹ either with fusion or with vertebral augmentation. If you are a suitable candidate

Table 1: Case series characteristics.

Multiple myeloma and vertebral destruction syndrome case series									
Age	Gender	Axial pain at diagnosis	ASIA	Durie-Salmon	Serum hemoglobyn (g/dl)	Serum creatinine (mg/dl)	Serum calcium (mg/dl)	Affected level	Surgery
76	F	Y	D	3 A	7.0	0.4	9.6	T12	Fusion
31	M	N	E	1 A	15.9	1.0	8.3	C2	Vertebroplasty-fusion
54	M	Y	D	2 A	14.0	0.8	8.0	L3	Fusion
54	M	Y	D	2 A	13.9	1.0	9.0	T2, S1	Biopsy
53	F	Y	A	2 A	12.2	0.4	8.0	T9, T10	Vertebroplasty + fusion
49	M	Y	A	2 A	15.1	0.6	9.8	T4, T5	Fusion
67	F	Y	E	3 A	6.3	1.2	9.4	L1	Vertebroplasty + fusion
64	F	Y	D	3 A	7.4	1.9	10.6	L1	Vertebroplasty + fusion
60	M	Y	E	3 A	10.0	0.8	8.0	T3, T5, T7	Vertebroplasty + fusion
56	M	Y	D	3 B	7.9	2.1	14.0	L3, L4	Vertebroplasty

M = male, F = female; Y = yes, N = no.

or not, will depend on your general condition. There are objective evaluations for this purpose in the literature, such as the Tomita¹² and Tokuhashi¹³ scores that help to make an individualized decision, based on evidence and in conjunction with a multidisciplinary medical-surgical team, the patient and their family members. Although implant fusion surgeries still play a role as stabilizing procedures, their large approaches lead to greater morbidity and complications in immunologically and nutritionally disadvantaged patients, which has allowed exploring less invasive alternatives. With the development and refinement of minimal invasive spine surgery (MISS) techniques, its field of application is expanding and CMEM is no exception. Kyphoplasty, percutaneous vertebroplasty alone, and their combination with radiofrequency ablation have been shown to reduce pain, improve mobility, and provide stability to vertebral bodies affected by multiple myeloma.¹⁴ These methods of vertebral augmentation have proven to be true stabilization methods for the anterior and medial spines, and have shown encouraging results in pain control in combination with radiofrequency.¹⁵

Although a review of hematological medical management is beyond the objectives of this work, the role of radiotherapy should be highlighted, since multiple myeloma is classically considered a radiosensitive tumor. The use of radiosurgery has shown to improve pain in up to 41% of patients in a period of 1.6 months, however, close radiological follow-up by the spinal specialist is necessary since its association with instability complications with a cumulative incidence for radiographic failure at 6 and 12 months, of 6% and 9% respectively; and a cumulative risk of vertebral fracture of 18% at 6 and 12 months.¹⁶ In general, the use of radiation therapy should be limited as much as possible to avoid worsening the already diminished bone marrow production. Patients who benefit from radiosurgery are those with soft tissue tumors or plasmacytomas who have not responded to systemic therapy, patients who cannot receive systemic therapy, refractory to treatment, as a palliative measure in patients with poor functional states, severe pain associated with effect of tumor mass or in the case of patients who will undergo procedures of vertebral augmentation with cement in which a decrease in tumor volume is required. With the development of better non-invasive techniques and pharmacological measures, the quality and expectation of patients has had a positive impact.

The chapter on vertebral metastasis disease has seen a dizzying and contrasting evolution over more than 40 years, with different controversial works that have resulted in algorithms or frames of reference that seek to facilitate decision-making.¹⁷ A review of these simplified methods and a deep understanding of current oncological concepts applied to the surgical field should not be neglected.

Conclusions

The participation of the spine surgeon in the medical and surgical management of patients with multiple myeloma is very active in different stages of the disease:

from the presentation, at the final diagnosis, in the care of complications throughout the natural evolution of the disease or inherent in therapeutic methods. The use of systematized management algorithms will allow better decisions to be made in conjunction with a multidisciplinary group for the care of multiple myeloma with vertebral involvement.

References

- Röllig C, Knop S, Bornhäuser M. Multiple myeloma. *Lancet*. 2015; 385(9983): 2197-208.
- Rajkumar SV, Dimopoulos MA, Palumbo A, Blade J, Merlini G, Mateos MV, et al. International Myeloma Working Group updated criteria for the diagnosis of multiple myeloma. *Lancet Oncol*. 2014; 15(12): e538-48.
- Lasocki A, Gaillard F, Harrison SJ. Multiple myeloma of the spine. *Neuroradiol J*. 2017; 30(3): 259-68.
- Alpizar-Aguirre A, Elías-Escobedo A, Rosales-Olivares LM, Miramontes-Martínez V, Reyes-Sánchez A. Vertebral destruction syndrome. Diagnostic evaluation systems. *Cir Cir*. 2008; 76(3): 205-11.
- Durie BG, Salmon SE. A clinical staging system for multiple myeloma. Correlation of measured myeloma cell mass with presenting clinical features, response to treatment, and survival. *Cancer*. 1975; 36(3): 842-54.
- Laufer I, Rubin DG, Lis E, Cox BW, Stubblefield MD, Yamada Y, et al. The NOMS framework: approach to the treatment of spinal metastatic tumors. *Oncologist*. 2013; 18(6): 744-51.
- Kyle RA, Gertz MA, Witzig TE, Lust JA, Lacy MQ, Dispenzieri A, et al. Review of 1027 patients with newly diagnosed multiple myeloma. *Mayo Clin Proc*. 2003; 78(1): 21-33.
- Molloy S, Lai M, Pratt G, Ramasamy K, Wilson D, Quraishi N, et al. Optimizing the management of patients with spinal myeloma disease. *Br J Haematol*. 2015; 171(3): 332-43.
- Mak KS, Lee LK, Mak RH, Wang S, Pile-Spellman J, Abrahm JL, et al. Incidence and treatment patterns in hospitalizations for malignant spinal cord compression in the United States, 1998-2006. *Int J Radiat Oncol Biol Phys*. 2011; 80(3): 824-31.
- Benson WJ, Scarffe JH, Todd ID, Palmer M, Crowther D. Spinal-cord compression in myeloma. *Br Med J*. 1979; 1(6177): 1541-4.
- Fisher CG, DiPaola CP, Ryken TC, Bilsky MH, Shaffrey CI, Berven SH, et al. A novel classification system for spinal instability in neoplastic disease: an evidence-based approach and expert consensus from the Spine Oncology Study Group. *Spine (Phila Pa 1976)*. 2010; 35(22): E1221-9.
- Tomita K, Kawahara N, Kobayashi T, Yoshida A, Murakami H, Akamaru T. Surgical strategy for spinal metastases. *Spine (Phila Pa 1976)*. 2001; 26(3): 298-306.
- Tokuhashi Y, Matsuzaki H, Oda H, Oshima M, Ryu J. A revised scoring system for preoperative evaluation of metastatic spine tumor prognosis. *Spine (Phila Pa 1976)*. 2005; 30(19): 2186-91.
- Patel MS, Ghasem A, Greif DN, Huntley SR, Conway SA, Al Maaieh M. Evaluating treatment strategies for spinal lesions in multiple myeloma: a review of the literature. *Int J Spine Surg*. 2018; 12(5): 571-81.
- Kyriakou C, Molloy S, Vrionis F, Alberico R, Bastian L, Zonder JA, et al. The role of cement augmentation with percutaneous vertebroplasty and balloon kyphoplasty for the treatment of vertebral compression fractures in multiple myeloma: a consensus statement from the International Myeloma Working Group (IMWG). *Blood Cancer J*. 2019; 9(3): 27.
- Miller JA, Balagamwala EH, Chao ST, Emch T, Suh JH, Djemil T, et al. Spine stereotactic radiosurgery for the treatment of multiple myeloma. *J Neurosurg Spine*. 2017; 26(3): 282-90.
- Marco RA, Brindise J, Dong D. MOSS: A patient-centered approach. In: Marco RA (Ed.). *Metastatic spine disease*. Cham, Switzerland: Springer International Publishing; 2018. pp. 1-20.

Conflict of interest: No conflict of interest is declared.