

## Comparative study between Plate-Graff, Plate-Cage and PEEK cage in cervical spine fusion

Reyes-Sánchez AA,\* Estrada-Gómez JA,\*\* Zarate-Kalfopulus B,\*\* García C,\*\* Alpizar-Aguirre A,\*  
Rosales-Olivares LM\*\*\*

National Institute of Rehabilitation Luis Guillermo Ibarra Ibarra (Mexico)

**ABSTRACT. Objective:** To compare results of Plate-Graff, Plate-Cage and PEEK cage in patients with cervical stenosis. **Material and methods:** Prospective, with before and after intervention and comparative study. From January 2005 to October 2011 we included 37 patients (male: 48.6%, female: 51.4%) post-surgery by anterior approach; 3 groups via: Group I, arthrodesis with Plate-Graff n = 12 (M 41.7%, F 58.3%) with 22 levels, group II, Plate-Cage n = 11 (M 63.6% 36.4% F) 19 levels, group III, PEEK cage, n = 14 (M 0% F 50%) with 25 levels. Functional assessment pre- and postoperative with neck disability index (NDI) and visual analogue scale for pain (VAS). The radiological assessment with X-rays only. Descriptive statistics were obtained. Wilcoxon method use according to data distribution, non parametric tests of ranges with sign of Kruskal-Wallis for comparison between more than two groups, and significance level with  $p < 0.05$ . We used the statistical package SPSS version 15. **Results:** The majority of patients was found between the sixth and eighth decade of life. At one year of follow up the NDI and pain with VAS shown improvement with statistical difference in three groups ( $p = 0.001$ ). However, the radiographic measurements per year of follow-up

**RESUMEN. Objetivo:** Comparar resultados de placa-injerto, caja-placa y caja-PEEK, en pacientes con conducto cervical estrecho. **Material y métodos:** Estudio prospectivo, en panel antes y después, de intervención y comparativo. De Enero de 2005 a Octubre de 2011, muestra de 37 pacientes (masculino: 48.6%, femenino: 51.4%) postoperados por vía anterior; formando tres grupos: grupo I, artrodesis con placa-injerto n = 12 (M 41.7%, F 58.3%) con 22 niveles; grupo II, caja-placa n = 11 (M 63.6%, F 36.4%) con 19 niveles; grupo III, caja-PEEK, n = 14 (M 50%, F 50%) con 25 niveles. La evaluación funcional pre- y postoperatoria mediante la escala de discapacidad cervical y escala visual análoga de dolor. La evaluación radiológica con radiografías de columna cervical. Se obtuvo estadística descriptiva. De acuerdo con la distribución de los datos se usaron pruebas no paramétricas de rangos con signo de Wilcoxon, y Kruskal-Wallis para comparación entre más de dos grupos. Con nivel de significancia de  $p < 0.05$ . Se utilizó el paquete estadístico SPSS versión 15. **Resultados:** La mayoría de los pacientes se encontró entre la sexta y octava década de la vida. Al año de postoperados el índice de discapacidad cervical y mejoría del dolor con EVA mostraron mejoría con diferencia estadística en los tres grupos ( $p =$

### Level of evidence: IV

\* Head of Special Surgery Division.

\*\* Spine Surgery Service.

\*\*\* Head of Spine Surgery Service.

National Institute of Rehabilitation (Mexico).

Corresponding author:

Alejandro Reyes-Sánchez

Camino a Santa Teresa Núm. 1055-684, Col. Héroes de Padierna, CP 10700, Ciudad de México, México.

Tel: 59991000, ext. 12209 y 12206

E-mail: alereyes@inr.gob.mx

Este artículo puede ser consultado en versión completa en <http://www.medigraphic.com/actaortopedica>

showed a significant improvement of segmental lordosis ( $p = 0.02$ ) only in patients with Plate-Graft. **Conclusions:** Using the graft offers best clinical and radiographic results compared with the Plate Cage and box peek to one year of follow-up.

**Key words:** Cervical arthrodesis, cervical osteosynthesis, spinal surgery.

0.001). Sin embargo, las mediciones radiográficas al año de seguimiento mostraron una mejoría significativa de la lordosis segmentaria ( $p = 0.02$ ) sólo en pacientes operados con placa-injerto. **Conclusiones:** El uso de la placa-injerto ofrece mejores resultados clínicos y radiográficos en comparación con la caja-placa y caja-PEEK, al año de seguimiento.

**Palabras clave:** Artrodesis cervical, osteosíntesis cervical, cirugía de columna.

## Introduction

The degenerative cervical disease is a chronic and progressive process associated with a bone forming reaction of osteophyte and joint deformation, which can produce stenosis of the cervical canal and possible compression of neural elements. The severity of these changes are variable, however represents the most common cause of dysfunction in spinal cord above the 55 years old.<sup>1</sup> Root compression produces pain and inflammation causing mechanical distortion, motor weakness and sensory deficit; in addition, joint compression of blood vessels increases the permeability and produces a chronic swelling of the root that generates increased symptoms of the myotome<sup>2</sup> or the root dermatome.<sup>2,3,4,5</sup> Spasticity is the axis about which develops muscle dysfunction responsible for the alteration of the gait, which is present in 80% of patients that less than half with a motor deficit in proximal muscles of pelvic extremities.<sup>6</sup> Motor and sensory changes are specific to the cord level and are proportionate to the damage.<sup>2,4,5,7,8,9,10</sup> Neck pain has a prevalence of 66% to throughout life and disability in 5% of cases. In spite of being a common problem the nonspecific symptoms and the determination of its origin is difficult, as you can have a muscle or discogenic etiology.<sup>2,11,12</sup>

The controversy about the surgical approach of cervical myelopathy still not been resolved and some authors prefer anterior approaches while others decide to posterior approach.<sup>13,14,15,16,17,18,19,20,21,22,23,24,25,26</sup> The objective in the surgical treatment is functional balance immediately through decompression and fixation to carry the bone fusion which will have highest rate of consolidation if it is associated to a system of osteosynthesis, simple as possible to minimize the chances of complications and design an implant that ensures their integrity throughout the time.<sup>27,28,29,30,31</sup> While the autologous iliac crest graft fosters rapid melting, this procedure requires a second surgery and has complications such as pain at donor site, femorocutaneous nerve injury, bruising, pseudoarthrosis, dislocation of grafting among others collapse;<sup>32,33,34,35</sup> as result it has increased the usefulness of the allograft, however, this increases the risk of infection transmission.<sup>36,37,38,39,40</sup>

Previous cervical plate associated with graft of iliac crest increases the relative height of the disk 15.3 preoperative to 19.8% from 6-9 month postoperative with angle, such increase in the segment contributed to 2.6° of lordosis and reaching a bone fusion in dynamic studies on 100% of the cases.<sup>27,41,42,43</sup>

In the same way that three-cortical together with the anterior plate improves clinical outcomes and X-ray, an anterior cage and plate in association increases results by adding the advantages of both systems, however demonstrated that the Plate-Cage increases the surgical time but not the complications.<sup>44</sup> when the cage interacts with the plate completely prevents migration, so that subsequent disc decompression may be as radical as it require.<sup>45</sup> The cage can be filled with the osteogenic material or osteoconductor material as determined, decreasing symptoms in the donador site.<sup>45,46,47,48,49,50,51,52</sup>

Between various biomaterials, the cage of polyether ether ketona (PEEK), are biocompatible, radiolucent and have an elasticity modulus similar to bone. Therefore, PEEK seems a biomaterial for previous decompression and fusion with cage.<sup>53,54</sup> Therefore the goal of the cervical fusion before decompression with Graft-Plate, Plate-Gage or PEEK cage aims to restore and maintain the stability of the segment; the intersomatic space, the opening of holes in conjunction; the alignment lordosis segment; promote the reabsorption of the ligamentum; remove the dynamic factor for myelopathy.

However, since there is not any guide with respect to which is the best treatment for this objective and that today has not reported a similar study to make the comparison of these three types of technique. For this reason, in this study the general objective was to compare the outcomes of the systems of anterior cervical plate and graft, Plate-Cage, PEEK cage in patients undergoing surgery with the diagnosis of cervical stenosis.

## Material and methods

Prospective, panel study before and after intervention and comparative, including 37 patients with diagnosis of cervical stenosis treated by anterior approach with

discectomy and using three different material which gave different groups: group I Plate-Graff, group II Plate-Cage and group III PEEK cage. In all of them bone graft was autologous and tooked of the iliac crest. Preoperative and one year follow-up evaluation was based on visual analogue scale (VAS) for neck pain and upper limbs functional assessment and clinical evolution through neck disability index (DIS) and determine if existed or not adverse events and complications inherent in each of the systems used in each group. Studies included: simple and dynamic X-rays of cervical spine, imagine of magnetic resonance (IMR). In evaluating alignment of the segment, disc height and final placement of the implant.

### Surgical technique

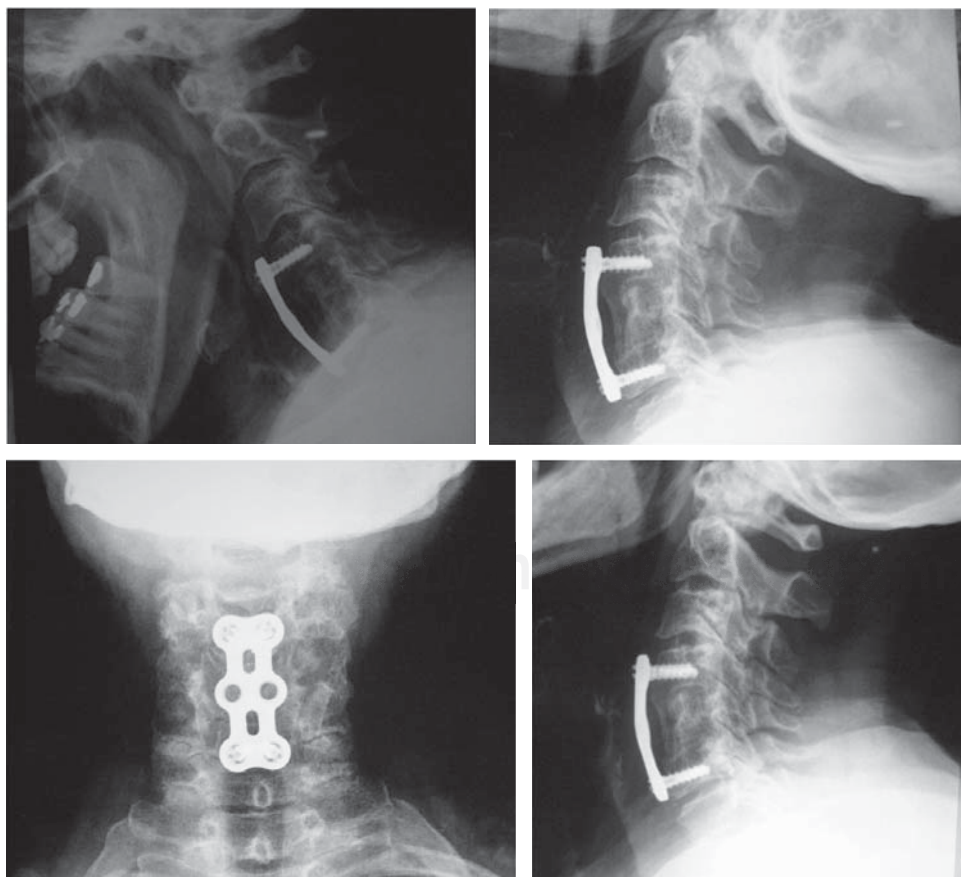
Surgery performed in all cases according to the technique developed by Smith-Robinson.<sup>23</sup> Under external cervical traction and through an incision horizontally on the neck, medial rejection of organ and lateral vasculo-nervous package, exposure of the levels affected by verification with intensifier images; placing of Cloward's separators; exhibition of the roots affected; distraction of intervertebral spaces with Caspar instrumental and total discectomy was performed, then the measurement of the depth of the space for the selection of the size of the implant and through distraction is to place the graft or PEEK cage if appropriate

placement of the plate under fluoroscopy. Finally, the stability of the implant was checked, rinsing with saline solution and let a drainage, which we withdrew 24 hours post-op, after wound closure we place a Philadelphia cervical collar.

Non-parametric tests for ranges with Wilcoxon, sign for Kruskal Wallis and related data for comparison between more than two groups were applied according to the distribution of data. All the tests used a 0.05 significance level. We used the statistical package SPSS version.<sup>15</sup>

### Results

37 patients within the study, 18 men and 19 women were included. The youngest patient was 34 years old and older age 84 years, with an average 61.8 years. Three groups: group I, n = 12 (m: 7, F: 5) with a total of 22 levels made fusion with Plate-Graff, group II, n = 11 (m: 4, F: 7) with a total of 19 levels register it Plate-Cage (*Figure 1*), group III, n = 14 (F: 7, m: 7) with 25 levels using PEEK cage. Clinical assessment of pain measured with visual analog scale and functionality through the neck disability index showed improvement in the postoperative period and one year of follow-up in three groups (*Table 1*). However, the PEEK-cage group had better results for pain ( $p = 0.001$ ). On the other hand, global lordosis, quantified by Cobb method, showed no difference in evaluation before and after surgery,



**Figure 1:**

One years FU, Plate Graff, without any conflict in lordosis and adjacent levels.

Table 1: Results in the three different groups.				
	Plate-Graff	Plate-Cage	PEEK Cage	1 year
Male	7 (41.7%)	4 (63.6%)	7 (50%)	
Female	5 (58.3%)	7 (36.4%)	7 (50%)	
Age	34-79 (61)	39-80 (62)	42-84 (62)	
Operated levels				
1 Level	4	3	3	
2 Levels	6	8	11	
3 Levels	2	-	-	
Visual analogue scale				
Preoperative	8-9 (8)	8-9 (8)	5-8 (7)	
1 year follow up	2-7 (4.5)	2-8 (5)	2-5 (2)	
	p = 0.002*	p = 0.003*	p = 0.001*	p = 0.000+
Neck discapacity index				
Preoperative	21-40 (28)	10-41 (22)	34-50 (48)	
1 year follow up	9-26 (20)	10-18 (16)	8-34 (14)	
	p = 0.003*	p = 0.006*	p = 0.001*	p = 0.000+
Global lordosis				
Preoperative	0 a 42 (25°)	14 a 30 (24°)	-16 a 40 (13°)	
1 year follow up	18 a 40 (23°)	0 a 32 (20°)	-8 a 28 (10°)	
	p = 0.755	p = 0.474	p = 0.085	p = 0.000+
Segmentary lordosis				
Preoperative	-8 a 16 (25°)	0 a 16 (10°)	-16 a 40 (11.3°)	
1 year follow up	4 a 16 (23°)	0 a 12 (8°)	-8 a 16 (5.8°)	
	p = 0.007*	p = 0.516	p = 0.414	p = 0.449+
Disc space height				
Preoperative	30-67 (10)	32-66 (52)	5-90 (52)	
1 Year follow up	37-70 (70)	30-72 (58)	28-96 (52)	
	p = 0.154	p = 0.018*	p = 0.624	p = 0.556+
Subsidence				
With	8.3%	9.09%	21%	
With out	91.7%	90.9%	79%	
Surgical time	90-240 (132)	60-400 (170)	90-180 (120)	p = 0.665+
Bloodless	50-250 (100)	90-230 (150)	30-250 (200)	p = 0.663+

\* Wilcoxon signed ranks test. + Kruskal-Wallis test. () Medium value.

however, to compare treatment, we note that the Plate-Cage and Graff-Plate maintain regional lordosis, unlike patients with PEEK-cage presented kyphosis (5/14) (p = 0.00), recover the loss of lordosis or correct is important due to the kyphosis increases and accelerates degenerative changes over time, particularly in the adjacent levels higher and lower than arthrodesis. Kyphosis evaluation results are presented in the (Figure 2). Segmental among Plate-Graff lordosis introduced difference between the preoperative and in the monitoring year (p = 0.007), however when comparing the treatment not be note significant changes. The height of the intradiscal space kept only follow-up year in Plate-Cage group (p = 0.018). To assess the sinking with three types of treatment are found no difference with statistical significance that we found the following results: Plate-Graff (12 patients) group note sinking in one patient. Plate-Cage (11 patients) group present collapse in one patient. And PEEK-cage (14 patients) Group presented sinking in three patients. The relationship to the surgical and bleeding time there was no difference between procedures.

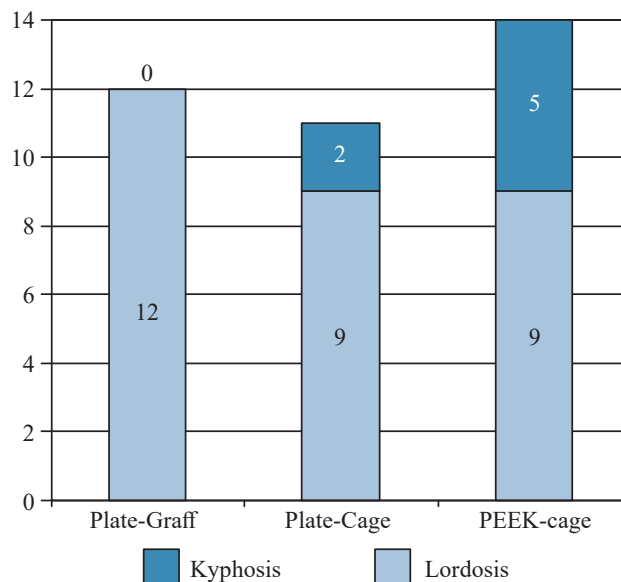


Figure 2: Relation lordosis-kyphosis in the three groups.

### Discussion

This study, although few patients is comparable in epidemiological, clinical and radiological features throughout the literature, and corresponds to the classical image described in all review articles published on these same topic.<sup>14,15,16</sup> The patient is a male of 50-70 years, who show clinical about a year and a half of evolution compatible with a previous moderate intensity, myelopathy syndrome is important to mention that 25% of cases, specialized consultation differs more than two years, reflecting the difficulty in making a correct diagnosis of a disease affecting elderly patients, mainly manifested as an gait alteration and can therefore be interpreted as the old man physiological gait.<sup>55</sup> Surgery should be used in those patients who do not improve or those that develop with progressive neurological deficit. Cervical discectomy through previous approach has been a successful surgical treatment of degenerative disease of the cervical spine since the 1950s.<sup>23,24,25</sup> The use of autologous bone graft has been regarded as the standard method to achieve a stable fusion: however, in the literature have been collected complications such as donor site morbidity or collapse, extrusion or failure of the fixation of the graft. The techniques used until few years ago, involve surgical operations complex and protracted, presenting a high incidence of complications. Despite its usefulness, there is controversy regarding the grafts to be used for fusion and the need for additional plates to improve stability; likewise, there is no consensus about the validity of the results.<sup>7,9</sup> This has led to develop different surgical techniques and implants to solve these problems.

To compare the results of the study showed that three groups patients had improvement in their clinical evolution to assessed through the cervical disability scale and similar visual scale of pain regarding cervical region. The literature

mentioned long-term decompression results via previous treating cervical canal close with myelopathy is variable, with figures of improvement at 50% of patients in some publications while in others the good results exceed 90% of the cases.<sup>15</sup> Also note that with the Plate-Cage system is required longer surgical, even that not are not statistically proved. With regard to alignment of cervical lordosis global to make comparison with three types of treatment, Plate-Graff systems, Cage-Plate, presented best radiographic results but they had no statistical significance. And on segmental lordosis this remained with the system of Plate-Graff the results if they have different statistical. Regarding the height of the interdiscal space, it remained with system Plate-Cage unlike the other two treatments. It may be that once establishes the intradiscal space with the cage and stays with the plate, you get greater stability.

In the presentation of segmental kyphosis note the group of patients treated with Plate-Graff, no patient system presented kyphosis, on the other hand patients treated with system PEEK cage, observed 5 of 14 patients submitted this type of deformity. So, in Martin's study<sup>26</sup> with a follow up to three years, treated 53 patients with cervical discectomy and arthrodesis by anterior approach, noting that five patients (9.4%) developed postsurgical kyphosis. Which presents similarity with our study, in patients treated with PEEK cage. In the studies carried out by Kyunog-Jin Song et al.<sup>56</sup> Attended previous cervical discectomy with PEEK-cage in 38 patients and compare the results of the patients who made cervical discectomy with Plate-Cage, noting that the patients of the group PEEK-cage 16/38 (42.1%) presented segmental kyphosis instead group patients Plate-Cage 4/40 (10%) presented this deformity. With regards the sinking patients of the group PEEK-Cage 19/59 (32.3%) were sinking and Plate-Cage 6/62 patients (9.7%) presented sinking. These results show similarity to the results in our study. In which note segmental kyphosis presenting 5/14 patients treated with safe PEEK and patients treated with Plate-Cage 2/11.

The ideal implant must comply with the objectives of treatment for degenerative disease of the cervical column as they are: simple surgical procedures, reduction of costs, surgical time and hospital stay minimum instrumentation to allow stabilization immediate and secure the cervical column with early mobilization of the patient and minimal postoperative discomfort and effectively restore the Biomechanics of cervical spine. Based on the results obtained in this study, concluded that the three implants studied: Plate-Graff, Plate-Cage and PEEK-cage comply partially to monitoring year with ideal treatment goals. This study generates the need for a long-term follow-up, to evaluate the biomechanical behavior of implants through time as well as comparison with implant of new generation. This pathology in their complexity requires multiple tools for its approach and treatment. Of previous cervical discectomy and fusion using Plate-Graff surgery. As a combination of biomechanical stability and a biological

mechanism of fusion of the cervical spine, it is one of these options or tools which allows dealing with the patient and improve their clinical status, either partially or totally, avoiding a functional, neurological deterioration and the quality of life.

## Conclusions

Our study notes clinical with three types of treatment improved outcomes; we observed kyphosis and sinking of the implants which had no adverse effects on these clinical outcomes. Radiographic evaluation showed improvement with the use of systems Plate-Graff and Plate-Cage. The results of our study are good and encouraging, at one year follow up to continue to apply this technique, although it requires a learning curve.

## References

1. al-Mefty O, Harkey HL, Marawi I, Haines DE, Peeler DF, Wilner HI, et al. Experimental chronic compressive cervical myelopathy. *J Neurosurg.* 1993; 79(4): 550-61.
2. Rao R. Neck pain, cervical radiculopathy, and cervical myelopathy: pathophysiology, natural history, and clinical evaluation. *J Bone Joint Surg Am.* 2002; 84-A(10): 1872-81.
3. Rhee JM, Yoon T, Riew KD. Cervical radiculopathy. *J Am Acad Orthop Surg.* 2007; 15(8): 486-94.
4. Salvi FJ, Jones JC, Weigert BJ. The assessment of cervical myelopathy. *Spine J.* 2006; 6(6 Suppl): 182S-9.
5. Baptiste DC, Fehlings MG. Pathophysiology of cervical myelopathy. *Spine J.* 2006; 6(6 Suppl): 190S-7.
6. Chiles BW 3rd, Leonard MA, Choudhri HF, Cooper PR. Cervical spondylotic myelopathy: patterns of neurological deficit and recovery after anterior cervical decompression. *Neurosurgery.* 1999; 44(4): 762-9; discussion 769-70.
7. Rao RD, Gourab K, David KS. Operative treatment of cervical spondylotic myelopathy. *J Bone Joint Surg Am.* 2006; 88(7): 1619-40.
8. Matz PG. Does nonoperative management play a role in the treatment of cervical spondylotic myelopathy? *Spine J.* 2006; 6(6 Suppl): 175S-81.
9. Komotar RJ, Mocco J, Kaiser MG. Surgical management of cervical myelopathy: indications and techniques for laminectomy and fusion. *Spine J.* 2006; 6(6 Suppl): 252S-67.
10. Edwards CC 2nd, Riew KD, Anderson PA, Hilibrand AS, Vaccaro AF. Cervical myelopathy. current diagnostic and treatment strategies. *Spine J.* 2003; 3(1): 68-81.
11. Côté P, Cassidy JD, Carroll L. The Saskatchewan Health and Back Pain Survey. The prevalence of neck pain and related disability in Saskatchewan adults. *Spine (Phila Pa 1976).* 1998; 23(15): 1689-98.
12. Lawrence JS. Disc degeneration. Its frequency and relationship to symptoms. *Ann Rheum Dis.* 1969; 28(2): 121-38.
13. Baba H, Maezawa Y, Imura S, Kawahara N, Tomita K. Spinal cord evoked potential monitoring for cervical and thoracic compressive myelopathy. *Paraplegia.* 1996; 34(2): 100-6.
14. Bohlmann HH. Cervical spondylosis and myelopathy. *Instr Course Lect.* 1995; 44: 81-97.
15. Clavel-Escribano M, Clavel-Laria P. Tratamiento quirúrgico de la mielopatía cervical espondiloartrósica. *Neurocirugía.* 1996; 7(1): 4-10.
16. Law MD Jr, Bernhardt M, White AA 3rd. Evaluation and management of cervical spondylotic myelopathy. *Instr Course Lect.* 1995; 44: 99-110.
17. Saunders RL. Anterior reconstructive procedures in cervical spondylotic myelopathy. *Clin Neurosurg.* 1991; 37: 682-721.
18. Greene DL, Crawford NR, Chamberlain RH, Park SC, Crandall D. Biomechanical comparison of cervical interbody cage versus structural bone graft. *Spine J.* 2003; 3(4): 262-9.

19. Bailey RW, Badgley CE. Stabilization of the cervical spine by anterior fusion. *J Bone Joint Surg Am.* 1960; 42-A: 565-94.
20. Demircan MN, Kutlay AM, Colak A, Kaya S, Tekin T, Kibici K, et al. Multilevel cervical fusion without plates, screws or autogenous iliac crest bone graft. *J Clin Neurosci.* 2007; 14(8): 723-8.
21. Castro FP Jr, Holt RT, Majd M, Whitecloud TS 3rd. A cost analysis of two anterior cervical fusion procedures. *J Spinal Disord.* 2000; 13(6): 511-4.
22. Sampath P, Bendebba M, Davis JD, Ducker TB. Outcome of patients treated for cervical myelopathy. A prospective, multicenter study with independent clinical review. *Spine (Phila Pa 1976).* 2000; 25(6): 670-6.
23. Smith GW, Robinson RA. The treatment of certain cervical-spine disorders by anterior removal of the intervertebral disc and interbody fusion. *J Bone Joint Surg Am.* 1958; 40-A(3): 607-24.
24. Cloward RB. The anterior approach for removal of ruptured cervical disks. *J Neurosurg.* 1958; 15(6): 602-17.
25. Martín R, Carda JR, Pinto JI, Sanz F, Montaña F, Paternina B, et al. Discectomía cervical y artrodesis intersomática mediante técnica de Cloward: Análisis retrospectivo de las complicaciones y los resultados radiológicos en 167 casos. *Neurocirugía.* 2002; 13: 265-84.
26. De la Torre M, Martínez-Quiñones JV, Escobar R, Rodríguez D. Artrodesis cervical anterior con espaciadores intersomáticos. *Neurocirugía.* 2001; 12(3): 210.
27. González-Darder JM, Pesudo-Martínez JV, Feliu-Tatay R. Fusión cervical postdiscectomía. Estudio clínico-radiológico comparando el injerto óseo de cresta iliaca, placa cervical anterior con injerto óseo y placa-caja GD. *Neurocirugía.* 2001; 12(2): 143-51.
28. González-Darder JM, Atienza CM, Molla F. Placa-Caja para fijación cervical por vía anterior. Estudio biomecánico. *Neurocirugía.* 2000; 12(2): 152-7.
29. Thorell W, Cooper J, Hellbusch L, Leibrock L. The long-term clinical outcome of patients undergoing anterior cervical discectomy with and without intervertebral bone graft placement. *Neurosurgery.* 1998; 43(2): 268-73; discussion 273-4.
30. Zdeblick TA, Ducker TB. The use of freeze-dried allograft bone for anterior cervical fusions. *Spine (Phila Pa 1976).* 1991; 16(7): 726-9.
31. Arnold P, Boswell S, McMahon J. Threaded interbody fusion cage for adjacent segment degenerative disease after previous anterior cervical fusion. *Surg Neurol.* 2008; 70(4): 390-7.
32. Cauthen JC, Kinard RE, Vogler JB, Jackson DE, DePaz OB, Hunter OL, et al. Outcome analysis of noninstrumented anterior cervical discectomy and interbody fusion in 348 patients. *Spine (Phila Pa 1976).* 1998; 23(2): 188-92.
33. Hacker RJ, Cauthen JC, Gilbert TJ, Griffith SL. A prospective randomized multicenter clinical evaluation of an anterior cervical fusion cage. *Spine (Phila Pa 1976).* 2000; 25(20): 2646-54; discussion 2655.
34. Sawin PD, Traynelis VC, Menezes AH. A comparative analysis of fusion rates and donor-site morbidity for autogeneic rib and iliac crest bone grafts in posterior cervical fusions. *J Neurosurg.* 1998; 88(2): 255-65.
35. Chuang HC, Cho DY, Chang CS, Lee WY, Jung-Chung C, Lee HC, et al. Efficacy and safety of the use of titanium mesh cages and anterior cervical plates for interbody fusion after anterior cervical corpectomy. *Surg Neurol.* 2006; 65(5): 464-71; discussion 471.
36. Ryu SI, Mitchell M, Kim DH. A prospective randomized study comparing a cervical carbon fiber cage to the Smith-Robinson technique with allograft and plating: up to 24 months follow-up. *Eur Spine J.* 2006; 15(2): 157-64.
37. Fernyhough JC, White JI, LaRocca H. Fusion rates in multilevel cervical spondylosis comparing allograft fibula with autograft fibula in 126 patients. *Spine (Phila Pa 1976).* 1991; 16(10 Suppl): S561-4.
38. Floyd T, Ohnmeiss D. A meta-analysis of autograft versus allograft in anterior cervical fusion. *Eur Spine J.* 2000; 9(5): 398-403.
39. Majd ME, Vadhva M, Holt RT. Anterior cervical reconstruction using titanium cages with anterior plating. *Spine (Phila Pa 1976).* 1999; 24(15): 1604-10.
40. Hwang SL, Lee KS, Su YF, Kuo TH, Lieu AS, Lin CL, et al. Anterior corpectomy with iliac bone fusion or discectomy with interbody titanium cage fusion for multilevel cervical degenerated disc disease. *J Spinal Disord Tech.* 2007; 20(8): 565-70.
41. Kwon BK, Vaccaro AR, Grauer JN, Beiner JM. The use of rigid internal fixation in the surgical management of cervical spondylosis. *Neurosurgery.* 2007; 60(1 Suppl 1): S118-29.
42. Geer CP, Papadopoulos SM. The argument for single-level anterior cervical discectomy and fusion with anterior plate fixation. *Clin Neurosurg.* 1999; 45: 25-9; discussion 21.
43. Schulte K, Clark CR, Goel VK. Kinematics of the cervical spine following discectomy and stabilization. *Spine (Phila Pa 1976).* 1989; 14(10): 1116-21.
44. Katsura A, Hukuda S, Saruhashi Y, Mori K. Kyphotic malalignment after anterior cervical fusion is one of the factors promoting the degenerative process in adjacent intervertebral levels. *Eur Spine J.* 2001; 10(4): 320-4.
45. Samandouras G, Shafafy M, Hamlyn PJ. A new anterior cervical instrumentation system combining an intradiscal cage with an integrated plate: an early technical report. *Spine (Phila Pa 1976).* 2001; 26(10): 1188-92.
46. Matgé G. Cervical cage fusion with 5 different implants: 250 cases. *Acta Neurochir (Wien).* 2002; 144(6): 539-49; discussion 550.
47. Zdeblick TA, Phillips FM. Interbody cage devices. *Spine (Phila Pa 1976).* 2003; 28(15 Suppl): S2-7.
48. Türeyen K. Disc height loss after anterior cervical microdiscectomy with titanium intervertebral cage fusion. *Acta Neurochir (Wien).* 2003; 145(7): 565-9; discussion 569-70.
49. Buttermann GR. Prospective nonrandomized comparison of an allograft with bone morphogenic protein versus an iliac-crest autograft in anterior cervical discectomy and fusion. *Spine J.* 2008; 8(3): 426-35.
50. Malloy KM, Hilibrand AS. Autograft versus allograft in degenerative cervical disease. *Clin Orthop Relat Res.* 2002; (394): 27-38.
51. Samartzis D, Shen FH, Matthews DK, Yoon ST, Goldberg EJ, An HS. Comparison of allograft to autograft in multilevel anterior cervical discectomy and fusion with rigid plate fixation. *Spine J.* 2003; 3(6): 451-9.
52. Robinson RA, Smith GW. Anterolateral cervical disc removal and interbody fusion for cervical disc syndrome. *Bull Johns Hopkins Hosp.* 1955; 96: 223-55.
53. Black J, Hastings GW. *Handbook of biomaterials properties.* London, UK: Chapman and Hall; 1998.
54. Ramakrishna S, Mayer J, Wintermatel E, Leong KW. Biomedical application for polymer composite materials; a review. *Compos Sci Technol.* 2001; 61: 1189-224.
55. Martín R, Carda JR, Montaña F, Pinto JI, Sanz F, Paternina B, et al. Mielopatía cervical: análisis retrospectivo de los resultados quirúrgicos de 54 pacientes tratados mediante discectomía y fusión intersomática por vía anterior. *Neurocirugía.* 2005; 16(3): 235-55.
56. Song KJ, Taghavi CE, Lee KB, Song JH, Eun JP. The efficacy of plate construct augmentation versus cage alone in anterior cervical fusion. *Spine (Phila Pa 1976).* 2009; 34(26): 2886-92.