Archivos de Cardiología de México

PERMANYER

Check for updates

SCIENTIFIC LETTER

Transcatheter resolution of mechanical aortic valve dysfunction in a pediatric patient

Resolución transcatéter de disfunción de una válvula aórtica mecánica en un paciente pediátrico

José L. Colín-Ortiz[1], Jorge A. Silva-Estrada[1], Paola S. García-Vargas[1], and Yigal Pina-Reyna[2]*

[1]Department of Pediatric Cardiology, Instituto Nacional de Pediatría; [2]Department of Interventional Cardiology, Instituto Nacional de Cardiología Ignacio Chávez. Mexico City, Mexico

Case presentation

Male 13-year-old with a history of ductus arteriosus closure in another hospital through lateral thoracotomy in the 1st year of live. 12 years after; he was referred to our center by several months with progressive dyspnea, orthopnea, and 1-time syncope. His weight fell below the 3rd percentile and a physical examination revealed crackling rales in both lungs, hyperdynamic left ventricle impulse, ejective II/VI aortic systolic murmur, and III/VI aortic diastolic murmur with a gallop rhythm and water hammer pulse. Chest X-ray, electrocardiogram (ECG), transthoracic echocardiogram, contrast-enhanced cardiac computed tomography, and cardiac magnetic resonance were requested. We found an aneurysmal dilation of the aortic root and ascending aorta (Fig. 1A) with severe aortic regurgitation, small ductus, and severe left ventricle systolic dysfunction with ejection fraction of 33%. Bentall surgery was performed with polytetrafluoroethylene (PTFE) conduit carrying a 25 mm St. Jude mechanical valve and 8 mm dacron grafts for coronary reimplant, a fibrin bio-sealant was sprayed in the suture points of the valved conduit (Tysseel® Baxter International Inc. Deerfield, Illinois U.S.). Cardiopulmonary bypass time was 7 h and aortic cross-clamp time was 4 h. Patient received 7 days of veno-arterial extracorporeal membrane oxygenation (ECMO) with 95 mL/kg flow, 2 L/min sweep flow, FiO_2 80%, negative pressure of 90 mmHg, and a 100-mmHg transmembrane gradient. Due to sudden economic restraints, ECMO had to be withdrawn, myocardial ischemia with ST-segment depressions was documented immediately after. The metallic second heart sound was significantly decreased. Days after; a pneumothorax led to cardiac arrest which required 18 min of cardiopulmonary resuscitation (CPR). After stabilization, urgent coronary angiography was performed. Clinical suspicion was that coronary grafts would have significant stenoses. A peak-to-peak gradient of 50 mmHg was recorded during left ventricle to ascending aorta pullback tracing (Fig. 1B). During a second (with end hole) catheter withdrawal attempt, the patient had ventricular fibrillation and required 4-min CPR and defibrillation in two occasions. After normalization to sinus rhythm, angiography revealed the absence of single-disc opening with low anterograde flow (Fig. 1C). Both coronary implants were patent, with < 30% stenosis. We were able to restore the normal functioning of the mechanical valve with a pigtail catheter; in the 1st time an attempt was made with a

***Correspondence:**
José L. Colín-Ortiz
E-mail: colin_jldgo@yahoo.com.mx

Date of reception: 19-07-2024
Date of acceptance: 30-01-2025
DOI: 10.24875/ACM.24000136

Available online: 12-03-2025
Arch Cardiol Mex. 2025;95(3):381-384
www.archivoscardiologia.com

1405-9940 / © 2025 Instituto Nacional de Cardiología Ignacio Chávez. Published by Permanyer. This is an open access article under the CC BY-NC-ND license (http://creativecommons.org/licenses/by-nc-nd/4.0/).

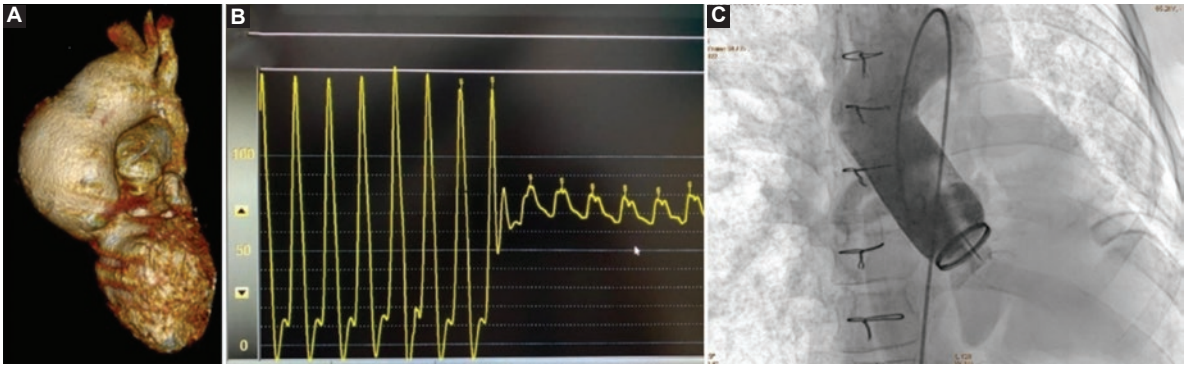

Figure 1: **A**: cardiac computed tomography 3D volume-rendering reconstruction shows aneurysmal dilatation of aortic root and ascending aorta. **B**: pullback tracing from left ventricle to aorta. **C**: valved conduit angiography shows a lack of opening of one disc in systole.

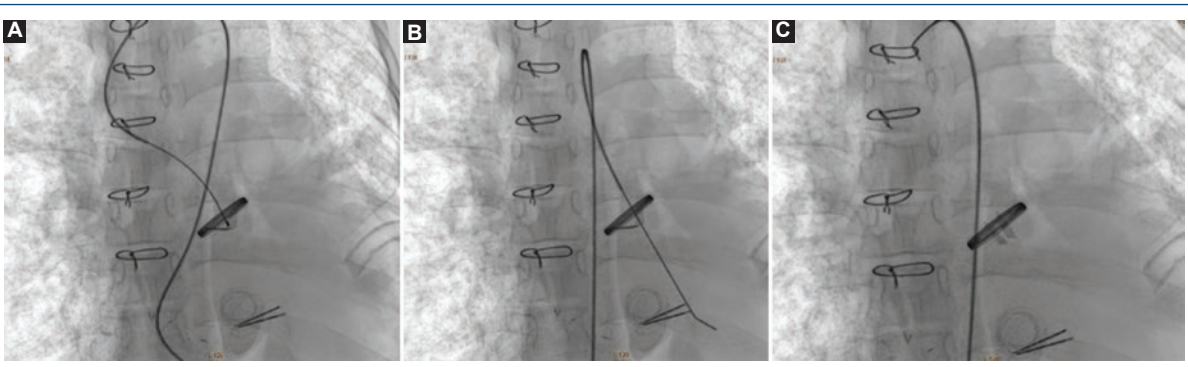

Figure 2: **A**: pigtail catheter with stiff proximal shaft of a 0.035″ guide wire on dysfunctional disc. **B**: stiff proximal shaft guide-wire crossing the mechanical valve. **C**: immediate mobilization of dysfunctional disc right after guide-wire withdrawal.

multipurpose 6 Fr catheter placed over the dysfunctional disc and using the stiff proximal shaft of a PTFE-coated guide wire, but it was unsuccessful. Mobility of the dysfunctional disc was successfully achieved with a 6 Fr pigtail catheter and the same PTFE-coated guidewire; however, the stiff proximal shaft was modified with a 45° angulation allowing forceful compression on the disc until full mobility was restored (Fig. 2). An initial heparin dose of 110 UI/kg was infused to continue with a continuous infusion of 20 UI/kg/h. Transesophageal echocardiogram showed an absence of aortic regurgitation. Fluoroscopy demonstrated normal opening and closure of both mechanical discs (Fig. 2C). After catheterization the patient showed slight hemodynamical improvement, allowing a decrease of inotropes. In the next 72 h, the patient had several episodes of ventricular tachycardia and had a cardiac arrest due to ventricular fibrillation without response to CPR. The postmortem study was not performed.

The first mechanical valve replacement in a human was performed in 1947 with a cage-ball prosthesis developed by Charles Hufnagel. Afterward, in 1951 Hufnagel and Campbell separately developed similar models and in 1952 the former placed a caged-ball mechanical valve in the descending aorta in a patient with severe aortic regurgitation. This surgery was performed before the introduction of cardiopulmonary bypass and paved the way for upcoming era of heart valve replacement. Based on Hufnagel and Campbell's work, Harken in 1960 placed an aortic mechanical valve in a subcoronary position and marked the beginning of valve replacement under cardiopulmonary bypass. Later on, that year, Starr-Edwards mechanical valve was utilized for mitral valve replacement. After,

the 1960's the ball occlude device was replaced with a lenticular disc which kept the lateral flow principle[1,2].

Finally, single-disc and double-disc mechanical valves were introduced. The latter showed good outcomes and ushered in a modern era of surgical valve replacement with growing experience in heart centers all over the world, albeit not without setbacks. Diverse complications in the short and long term have been reported with these new mechanical valves such as thrombosis, embolism, endocarditis, paravalvular leak, hemolysis, valve malposition, and dysfunction either due to lack of closure or opening.

Lack of opening of a mechanical valve is very rare, most cases being reported in mitral valves due to thrombus and/or pannus, additionally, mechanical valve dysfunction has been reported in which immobilization of a disc is due to surgical bio-sealant used during cardiac surgery[3,4].

Only two reports in children have been published; the first one in a 13-month-old girl who had thrombosis in a mitral mechanical valve, in this patient left heart catheterization through transseptal puncture was performed and disc mobility was restored with a 5 Fr 4.0 curve JR guide catheter reinforced with a tip-deflecting wire[5], the second is a case series describing five patients who received thrombolysis with good outcomes[6].

Hariram[7] described five adult patients with obstructed mitral mechanical valves and successful transcatheter manipulation (6 Fr right Judkins) without complications after failed thrombolysis. No additional procedure was required in any of these patients other than heparin infusion and optimal international normalized ratio target.

Bentall surgery for replacement of ascending aorta was introduced in 1968, ever since, it has suffered various modifications to decrease complications; however, its morbidity and mortality remain significant in high-risk cases[8].

The aim of this manuscript is sharing the case of a pediatric patient in whom the one of discs of the mechanical valve was immobile more probability by the used the bio-sealant during cardiac surgery, and it was possible its resolution by transcatheter route.

In pediatric patients, surgical valvuloplasty or biological prostheses are usually preferred over mechanical valves for surgical treatment of valve disease. In the aortic valve; Ross surgery is an option for valve replacement. However, with ascending aorta aneurysm, Bentall surgery is the first-line treatment, oftentimes with a valved conduit. This case shows a rare early complication of a mechanical valve presumably secondary to bio-sealant use. We conducted a literature research and found only two reports of the absence of opening of mechanical valves in children, both in mitral position[5,6].

An important clinic sign of mechanical valve dysfunction is a decrease in the intensity of the closure sound of the mechanical valve. Whenever this sign is encountered, imaging studies must verify the normal functioning of the valve. Echocardiography is first-line investigation, but; it has a poor acoustic window, even for transesophageal views might hinder adequate visualization. Cardiac computed tomography with retrospective ECG-gated acquisitions is an excellent modality for visualization of a mechanical valve with high spatial resolution. In our case, cardiac catheterization was performed due to hemodynamic instability and suspicion of coronary stenosis. It is important to seek for best view; where both discs can be visualized separately without overlapping images.

Theoretical complications after advancing a catheter across a mechanical valve are regurgitation or obstruction due to disc immobilization or entrapment with the guidewire/catheter between a disc and the valve ring. In the last 20 years, several techniques to perform left ventricle to ascending aorta pullback tracing in patients with mechanical valve have shown minimal risks without mechanical valve complications after crossing of the discs[9,10]. During both selective coronary angiography and endovascular paravalvular leak treatment, catheters may inadvertently contact mechanical discs without causing any complications. In conclusion, catheter crossing and even inadvertent manipulation of mechanical valves entail a minimum risk of mechanical valve dysfunction or catheter entrapment.

In our patient with a St. Jude 25 mm valved conduit after Bentall surgery, mechanical valve dysfunction due to the absence of one disc opening led up to myocardial ischemia. Mechanical valve obstruction compromised stroke volume, systemic arterial pressure, and coronary perfusion. This hemodynamic derangement in the setting of systolic and diastolic left ventricle dysfunction predicted a poor prognosis.

After confirmation of mechanical valve disc immobilization, the cardiovascular team must choose among pharmacological, interventional, and surgical approaches. Thrombolysis can be attempted depending of coagulation profile and bleeding risks. Another option is surgical reintervention, which in our patient was a high-mortality approach. Hybrid procedures have been reported as well with good outcomes in adults[11]. In our case, attempting to restore mobility with catheter manipulation proved a safe and effective approach.

Adequate anticoagulation is of utmost importance to avoid thrombosis/embolism and disc immobilization after mechanical valve implantation. This might have

been the cause of mechanical valve dysfunction in our patient, in whom, due to bleeding risks, heparin dose was infra-therapeutic and eventually suspended. Pannus is another potential factor for disc immobilization, but; it takes a longer time and should not be a cause in acute or sub-acute scenarios. In the third place, the bio-sealant used during Bentall procedure as a potential reason for mechanical valve dysfunction is plausible. We are not sure at what point after surgery valve dysfunction ensued. Restoration of disc mobility after several guide-wire attempts makes us think that dysfunction had been established for several days, ECMO utilization as a bridge for ventricular function restoration might have concealed the disc dysfunction. The possibility that the catheter itself had been the cause of dysfunction is unlikely, since, no catheter/guide wire entrapment was reported. Cause of dysfunction valve in our case was more likely a combination of two factors: first; bio-sealant use and then; insufficient heparin.

Whenever, if there is a decrease in the metallic component of any of the heart sounds, alongside hemodynamic compromise in patients with mechanical valves it is imperative to confirm adequate discs mobility, regardless of echocardiogram findings. In the event of immobility of one of valve discs, thrombolysis is the first-line therapy. Percutaneous manipulation of the mechanical valve is a safe and effective second-line therapy. Surgical exploration is the last option and must be deferred as it entails higher mortality.

Funding

This research has not received any specific grant from agencies in the public, commercial, or for-profit sectors.

Conflicts of interest

The authors declare no conflicts of interest.

Ethical considerations

Protection of humans and animals. The authors declare that no experiments involving humans or animals were conducted for this research.

Confidentiality, informed consent, and ethical approval. The authors have followed their institution's confidentiality protocols, obtained informed consent from patients, and received approval from the Ethics Committee. The SAGER guidelines were followed according to the nature of the study.

Declaration on the use of artificial intelligence. The authors declare that no generative artificial intelligence was used in the writing of this manuscript.

References

1. Azpitarte J, Alonso AM, García Gallego F, González Santos JM, Paré C, Tello A. Guías de práctica clínica de la sociedad española de cardiología en valvulopatías guidelines of the spanish society of cardiology on valve heart disease. Rev Esp Cardiol. 2000;53:1209-78.
2. Harken DE, Soroff HS, Taylor WJ, Lefemine AA, Gupta SK, Lunzer S. Partial and complete prostheses in aortic insufficiency. J Thorac Cardiovasc Surg. 1960;40:744-62.
3. Gabrijelcic T. Blockage of a mechanical aortic valve leaflet with bioglue: a case report. Heart Surg Forum. 2012;15:E310-2.
4. Smeltz AM, Caranasos TG, Teeter EG. BioGlue-associated loss of aortic valve leaflet motility sonographically masked by both newly replaced mechanical aortic and mitral valves. Semin Cardiothorac Vasc Anesth. 2018;22:91-4.
5. Arar Y, Hong J, Veeram Reddy S. Transcatheter mechanical manipulation of obstructed prosthetic mitral valve in an infant. Cardiol Young. 2020;30:1747-9.
6. Mashali MH, Ahmad Z, Omar Galal M, Al-Kouatli A. Effectiveness of alteplase infusion for the management of prosthetic mitral valve thrombosis in paediatric age group and proposed algorithm. Cardiol Young. 2022;33:747-53.
7. Hariram V. Percutaneous management of prosthetic valve thrombosis. Indian Heart J. 2014;66:427-9.
8. Mookhoek A, Korteland NM, Arabkhani B, Di Centa I, Lansac E, Bekkers JA, et al. Bentall procedure: a systematic review and meta-analysis. Ann Thorac Surg. 2016;101:1684-9.
9. Owan TE, Reddy BT, Michaels AD. Retrograde left-ventricular hemodynamic assessment of mechanical aortic and mitral valve gradients using a high-fidelity pressure wire: a case series. Catheter Cardiovasc Interv. 2010;76:621-5.
10. Moharram MA, Yong AS, Khoury V, Lowe HC. Arriving safely and avoiding a puncture: use of a Radi PressureWire to cross an ATS prosthetic aortic valve for direct measurement of left ventricular pressure. Tex Heart Inst J. 2011;38:50-1.
11. Koehle M, Strote JA, Guadagnoli M, Oldemeyer JB. A novel mechanical mitral valve replacement using Sapien XT. Catheter Cardiovasc Interv. 2018;92:983-7.