Archivos de Cardiología de México

PERMANYER

Check for updates

SCIENTIFIC LETTER

Hepatocellular carcinoma with inferior vena cava tumor thrombus extending into cardiac chambers: case report

Carcinoma hepatocelular con extensión cardíaca de trombo tumoral de vena cava inferior: reporte de caso

*Rafael Pedraza-Jiménez[1], Roberto Anjed Velazco-Llinas[1], Valeria Sandoval-Martínez[2], and José M. Alanís-Naranjo[3]**

[1]Department of Cardiology, Hospital Universitario Dr. José Eleuterio González, Monterrey, N.L.; [2]Department of Cardiovascular Imaging, Hospital General Dr. Miguel Silva, Morelia, Mich.; [3]Department of Cardiology, Hospital Regional 1° de Octubre, ISSSTE, Mexico City. Mexico

Case presentation

On a global basis, liver cancer is the third leading cause of cancer-related death, of which 75-85% are hepatocellular carcinomas (HCCs).[1] HCC frequently forms a tumor thrombus (TT) within the portal vein, while a direct invasion of the hepatic vein with TT extending into the heart chambers through the inferior vena cava (IVC) is uncommon.[2,3]

We presented a 40-year-old patient admitted with Budd-Chiari syndrome (BCS), who was diagnosed with HCC and had an IVC TT that extended into the heart chambers.

A 40-year-old man presented to the emergency department complaining of abdominal pain for one week. The patient manifested progressive jaundice, bilateral leg edema, ascites, increased abdominal circumference, nausea, and vomiting two months prior, as well as reported excessive alcohol consumption since the age of 17 (a mean of 30 drinks per week).

On admission, he had jaundice, gynecomastia, a distended abdomen with a positive fluid shift, collateral circulation on the anterior abdomen, bilateral pitting edema of the lower extremities, in addition to normal blood pressure (110/85 mmHg), normal heart rate (90 beats per minute), and no heart murmurs.

The laboratory blood tests revealed that hepatitis B and C serology were negative, but high alpha-fetoprotein (AFP) level with abnormal liver function tests were present (Table 1). Ascites analysis showed protein of 2.2 g/dl, albumin of 0.5 g/dl, a white blood cell count of 50 cells/mm3, and negative cultures with a serum-ascites albumin gradient of 2.2 g/dl.

Multiphase chest abdomen-pelvis computed tomography (CT) scan revealed a liver with lobulated edges and an irregular mass measuring 14 x 13.6 x 9.9 cm with lobulated margins. A contrast application showed enhancement in the peripheral area in the arterial and venous phases, followed by washout in the equilibrium phase, indicating HCC (Fig. 1). The mass extended towards the IVC and ascended to the right atrium (Fig. 2); pulmonary embolism was ruled out. The patient was admitted to the gastroenterology department ward for further evaluation, with a diagnosis of secondary BCS due to advanced HCC.

Transthoracic echocardiography (TTE) revealed a left ventricular ejection fraction of 53%, normal right ventricular systolic function, and no valvulopathies. A fixed mass was found in the right atrium coming from the IVC with a wide base of implantation and irregular

***Correspondence:**
José M. Alanís-Naranjo
E-mail: martin.alanis.n@gmail.com

Date of reception: 11-06-2024
Date of acceptance: 17-12-2024
DOI: 10.24875/ACM.24000116

Available online: 20-02-2025
Arch Cardiol Mex. 2025;91(3):371-375
www.archivoscardiologia.com

1405-9940 / © 2024 Instituto Nacional de Cardiología Ignacio Chávez. Published by Permanyer. This is an open access article under the CC BY-NC-ND license (http://creativecommons.org/licenses/by-nc-nd/4.0/).

Table 1. Initial blood tests

	Value	Reference range
Leukocytes, mm^3	9,450	4,000-11,000
Platelets, mm^3	44,500	142,000-424,000
Hemoglobin, g/dl	14.8	12-18
Bilirubin, mg/dl	26.6	0.2-1.0
Direct bilirubin, mg/dl	15.4	0-0.2
Indirect bilirubin, mg/dl	11.2	0.2-0.8
Serum total protein, g/dl	7.5	6.1-7.9
Serum albumin, g/dl	2.7	3.2-5.5
Creatinine, mg/dl	1.7	0.6-1.4
AST, UI/L	321	10-42
ALT, UI/L	102	10-42
Alkaline phosphatase, UI/L	434	38-125
Lactate dehydrogenase, UI/L	877	91-180
Alpha-fetoprotein, ng/ml	> 2000	5-10 ng/ml
PT, sec	32.6	11-12.5
aPPT, sec	44.2	30-40
INR	2.9	0.8-1.1
HBV (ELISA)	Negative	Negative
HCV (ELISA)	Negative	Negative
HIV (ELISA)	Negative	Negative

AST: aspartate transaminase; ALT: alanine transaminase; HBV: hepatitis B virus; HCV: hepatitis C virus; HIV: human immunodeficiency virus; ELISA: enzyme-linked immunosorbent assay; PT: prothrombin time; INR: international normalized ratio; aPPT: activated partial thromboplastin time.

edges, which invaded the interatrial septum and subtly protruded into the left atrium (Fig. 3).

The patient declined any invasive or surgical procedures and was referred to the oncology department for antineoplastic treatment for advanced and unresectable HCC. Medical treatment included sorafenib 400 mg BID, apixaban 5 mg BID, Furosemide 40 mg OD, and Spironolactone 50 mg BID.

In light of the advanced cancer stage, the patient was discharged and continued medical therapy with partial improvement in symptoms. The patient passed away three months later.

Discussion

According to the American Association for the Study of Liver Diseases (AASLD) guidelines[4], the CT image features of the hepatic lesion and a markedly elevated AFP level in a patient with a history of excessive alcohol consumption supported the diagnosis of HCC in this case.

Early HCC is often asymptomatic and challenging to diagnose outside of targeted surveillance programs.[5] The main routes of HCC's spread through the heart are continuous hematogenous spread along the IVC and direct spread from various surrounding structures.[6]

Cancer-related intracardiac metastases are a rare manifestation of HCC.[6] The incidence rate of HCC invading the IVC and then causing a TT to extend into the right atrium is usually 1 to 4%, according to the literature.[2] Little is known about the clinical features and effective treatments once HCC has invaded the right atrium.[3,7]

A wide range of clinical manifestations exist for HCC with right atrial extension, mainly determined by the tumor size. Most patients remain asymptomatic (39.5%) at diagnosis, and 37.5.% exhibit bilateral lower extremity edema; 31.3% suffer exertional dyspnea. Syncope, abdominal venous distension, ascites, chest pain, cough, and hemoptysis are other clinical manifestations.[2,7]

BCS can be triggered rapidly by caval and atrial tumor extension of HCC. BCS is caused by obstruction of the hepatic vein or the IVC and can be caused by either compression or invasion by malignant tumors. Secondary BCS is found in less than 1% of HCC cases.[2]

Numerous cardiopulmonary complications can result from this condition, including pulmonary embolism, shock, heart failure, lethal arrhythmias, as well as systemic metastases. Heart failure and sudden cardiac death are the most common causes of death, reported in 25% of patients.[2,7]

Echocardiography should be performed as a first diagnostic test to evaluate IVC TT with cardiac extension, just as with other cardiac masses.[2,8,9] A TTE provides information about the size, shape, echogenicity, mobility, location, and hemodynamic effects of the cardiac mass.[2,9] Distinguishing between benign and malignant tumors may be difficult when the image quality is suboptimal, or the echoes are complex.[9]

Contrast echocardiography (CE) has emerged as a promising technology for distinguishing between malignant and benign tumors with comparable accuracy to pathological analysis. Furthermore, ultrasound-enhancing agents can assess the blood supply within a cardiac mass. The difference in perfusion between cardiac masses may help

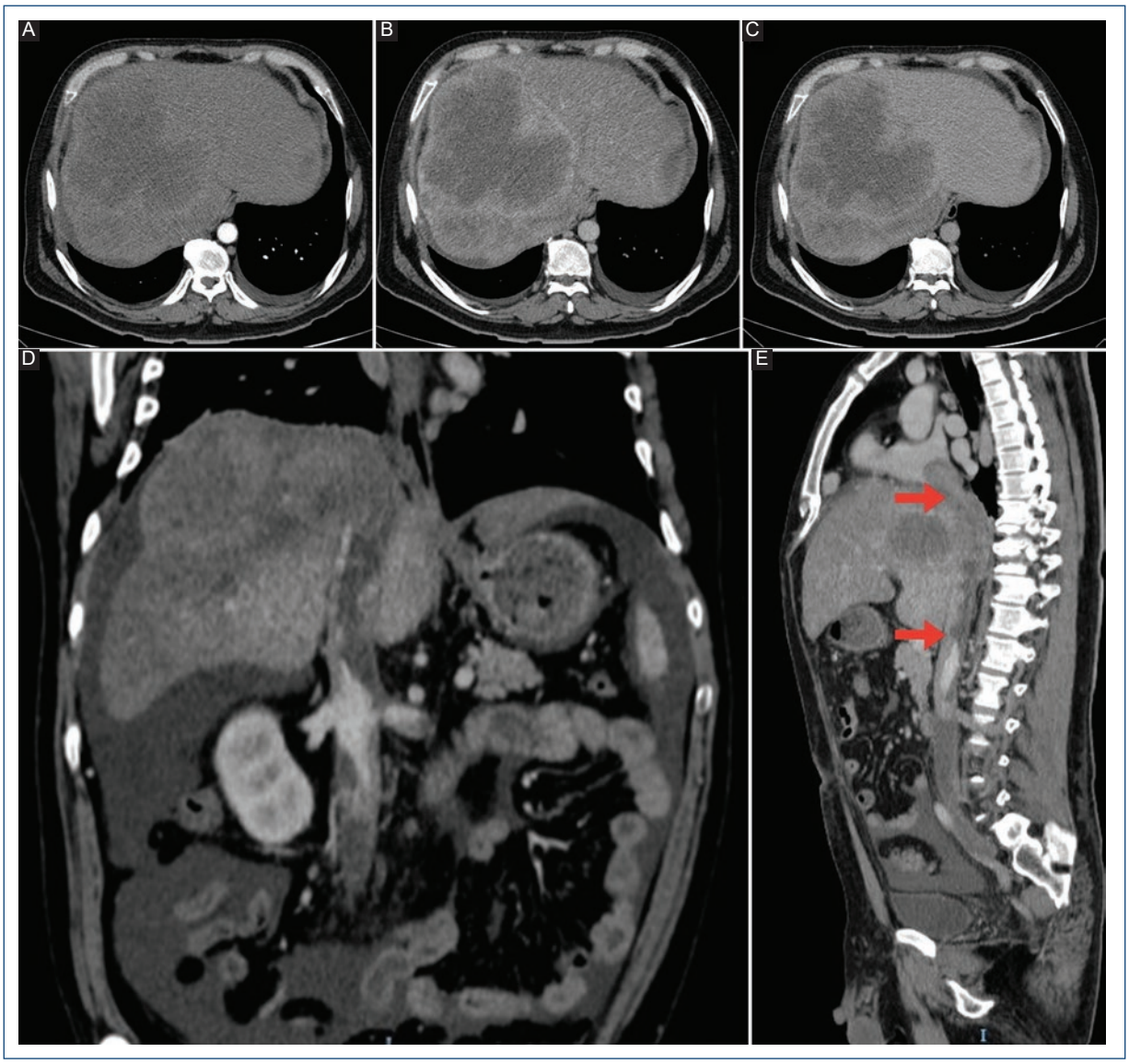

Figure 1. Multiphase CT scan showing the liver mass suggesting hepatocellular carcinoma: **A**: arterial phase, **B**: portal venous phase, **C**: equilibrium phase. Liver mass extension towards the inferior vena cava and ascending to the right atrium: **D**: coronal plane, **E**: sagittal plane (red arrow).

distinguish between vascular and nonvascular tumors or thrombi. A malignant tumor demonstrates greater enhancement than the adjacent myocardium as a result of abnormal neovascularization, whereas benign tumors exhibit a sparse blood supply.[8,9]

In addition to real-time 3-dimensional echocardiography, transesophageal echocardiogram (TEE) provides additional value in assessing the intracardiac mass.[8] TEE can accurately define the cranial extent of TT, and its diagnostic utility increases with the level of TT extension. During surgical treatment, TEE is an essential tool for selecting and modifying the surgical technique, performing and monitoring the procedure, increasing patient safety, and ruling out residual TT.[10,11] In addition, it provides early detection of adverse events such as heart failure or TT embolism.[10]

Cardiac CT can detect a TT of HCC, but contrast enhancement is necessary, and this procedure involves radiation and risks associated with contrast agents.[2] In cases where CT findings of IVC TT are equivocal, cardiac magnetic resonance (CMR) may be helpful due to its superior soft tissue characterization.[9,11]

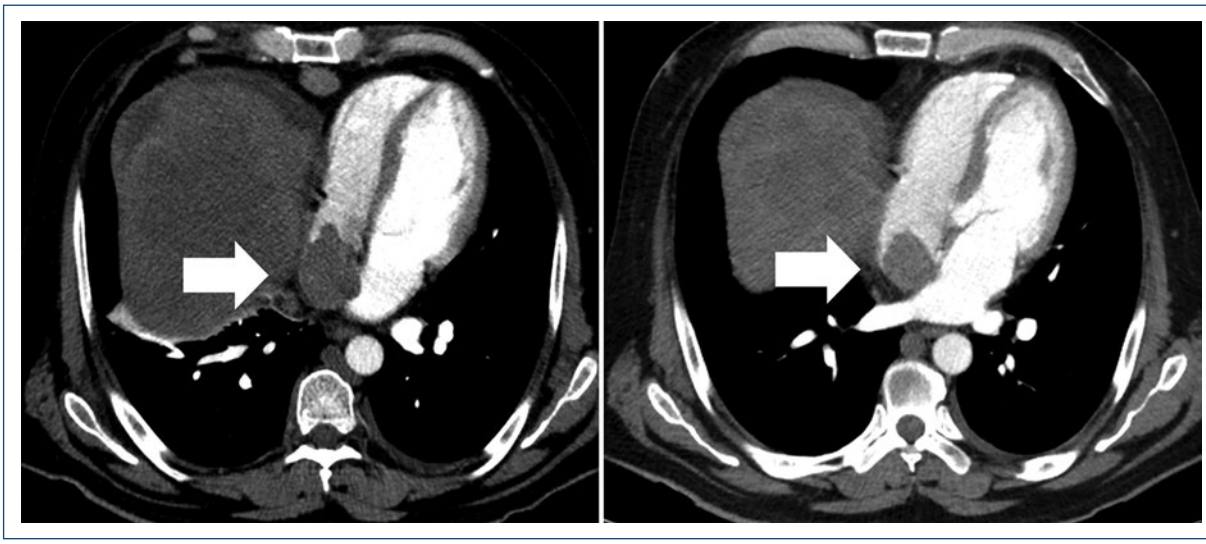

Figure 2. CT showing a mass in the right atrium coming from the inferior vena cava, which invades the interatrial septum (white arrow).

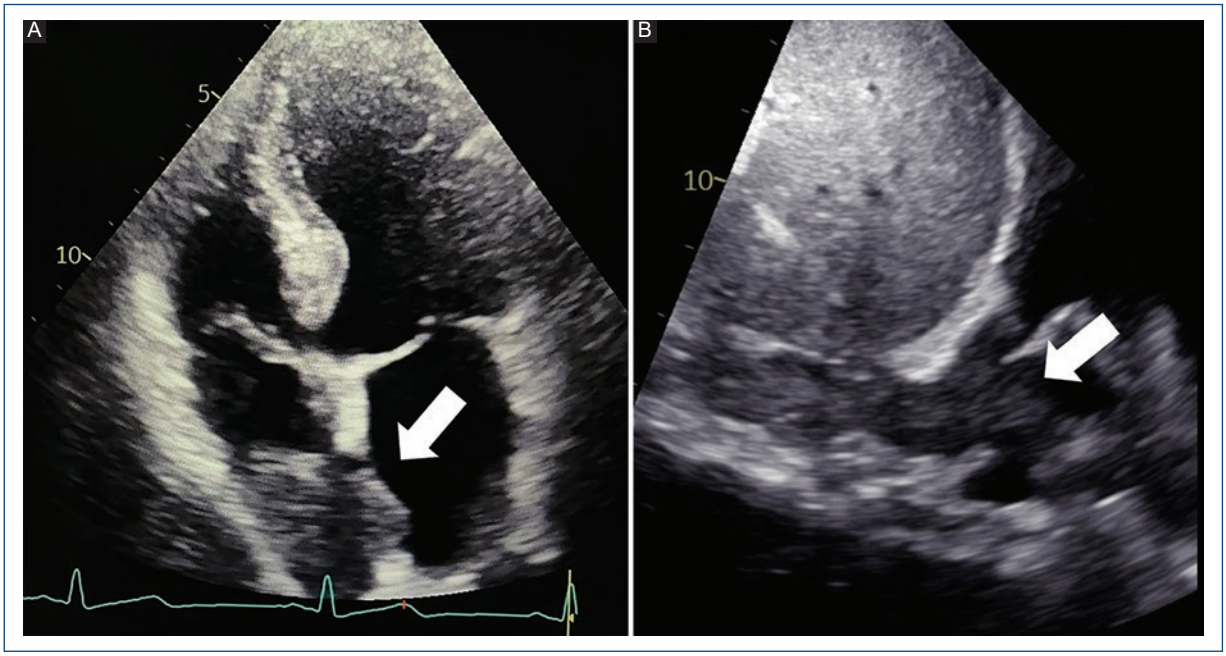

Figure 3. Transthoracic echocardiogram showing a fixed mass in the right atrium coming from the inferior vena cava, which invades the interatrial septum and protrudes into the left atrium (white arrow). **A**: apical four-chamber view, **B**: subcostal inferior vena cava view.

On CMR, TT exhibits low signal intensity on T1-weighted imaging and high signal intensity on T2-weighted imaging in the same manner as other secondary cardiac tumors.[8,12] A TT will show heterogeneous enhancement after intravenous gadolinium administration, distinguishing it from a non-TT (which will not capture) since both can coexist.[12]

Generally, patients with HCC that extends into the right atrium are poor surgical candidates due to the complex surgical procedure involved in removing the tumor from the IVC and right atrium.[7]

Symptomatic management of HCC-related thrombus formation and its extension to the right atrium results in a median survival of five months, while cases

untreated or undiagnosed have a survival of three days to two months.[6,7] Non-surgical approaches, such as the transarterial chemoembolization procedure, chemotherapy, and radiotherapies, have been attempted to palliate and improve quality of life, reporting a median survival rate of 4.2-10 months.[3,6] The overall survival of patients undergoing surgery is 12 to 19 months.[3]

Conclusion

Cardiac extension of IVC TT due to HCC is a rare presentation of the disease with a poor prognosis. Although multiple therapies have been discussed, none have been extensively investigated, given the condition's rarity. The use of multimodal imaging provides more information, thereby facilitating a correct diagnosis and prompt treatment.

Funding

This research has not received any specific grant from agencies in the public, commercial, or for-profit sectors.

Conflicts of interest

The authors declare no conflicts of interest.

Ethical considerations

Protection of humans and animals. The authors declare that no experiments involving humans or animals were conducted for this research.

Confidentiality, informed consent, and ethical approval. The authors have followed their institution's confidentiality protocols, obtained informed consent from patients, and received approval from the Ethics Committee. The SAGER guidelines were followed according to the nature of the study.

Declaration on the use of artificial intelligence. The authors declare that no generative artificial intelligence was used in the writing of this manuscript.

References

1. Bray F, Laversanne M, Sung H, Ferlay J, Siegel RL, Soerjomataram I, et al. Global cancer statistics 2022: GLOBOCAN estimates of incidence and mortality worldwide for 36 cancers in 185 countries. CA Cancer J Clin. 2024 May-Jun;74(3):229-263.
2. Chen M, Huang X, Yang Q. Hepatocellular carcinoma with inferior vena cava and right atrial tumor thrombus: A case report. Echocardiography. 2019 Nov;36(11):2110-2113.
3. Qiu W, Wang C, Zhang R, Wei F, Shi X, Sun X, et al. Surgical treatment of a rare case of hepatocellular carcinoma with right atrial metastasis: A case report. Medicine (Baltimore). 2020 Aug 7;99(32):e21630.
4. Singal AG, Llovet JM, Yarchoan M, Mehta N, Heimbach JK, Dawson La, et al. AASLD Practice Guidance on prevention, diagnosis, and treatment of hepatocellular carcinoma. Hepatology. 2023 Dec 1;78(6):1922-1965.
5. Chaudhry H, Sohal A, Iqbal H, Chaudhary U, Roytman M. Unusual sites of hepatocellular carcinoma metastasis: Case report. SAGE Open Med Case Rep. 2023 Nov 14;11:2050313X231211709.
6. Amin S, Shahab A, Qazi AR, Yunus H, Saeed L, Khan AA, et al. A Rare Incidence of Hepatocellular Carcinoma With Tumor Thrombus Extending to the Right Heart. Cureus. 2023 Aug 23;15(8):e43965.
7. Haq MS, Fatima T, Caplan J. Hepatocellular Carcinoma With Cardiac Metastasis Presenting as Presyncope. Cureus. 2022 May 11;14(5):e24926.
8. Tyebally S, Chen D, Bhattacharyya S, Mughrabi A, Hussain Z, Manisty C, et al. Cardiac Tumors: JACC CardioOncology State-of-the-Art Review. JACC CardioOncol. 2020 Jun 16;2(2):293-311
9. Wang Q, Wang B, Zhang X, Zhong X, Chang S, Yang J, et al. The usefulness of contrast echocardiography in the evaluation of cardiac masses: a multicenter study. BMC Cardiovasc Disord. 2024 Jan 13;24(1):43.
10. Łukasz Trzciniecki M, Bursiewicz W, Trzciniecka M, Mączka K, Legieć M, Sobieraj J, et al. The Role of Intraoperative Transesophageal Echocardiography in the Management of Renal Cell Carcinoma with Atrial Thrombus - Case Report. J Ultrason. 2023 Feb 28;23(92):28-31.
11. Calderone CE, Tuck BC, Gray SH, Porter KK, Rais-Bahrami S. The role of transesophageal echocardiography in the management of renal cell carcinoma with venous tumor thrombus. Echocardiography. 2018 Dec;35(12):2047-2055.
12. Cely Cely A, López-Guarch CJ, Alonso Charterina S. Masas cardiacas: multimodalidad-resonancia magnética cardiaca. Rev Colomb Cardiol. 2019;26:111-22.