Archivos de Cardiología de México

Permanyer

Check for updates

SCIENTIFIC LETTER

Ductal spasm versus angiographic variations during patent ductus arteriosus transcatheter closure: case report. Nightmare in ductus arteriosus closure

Espasmo ductal versus variaciones angiográficas durante el cierre transcatéter de conducto arterioso persistente: reporte de caso. Pesadilla en el cierre del ducto arterioso

Roberto Mijangos-Vázquez[1] and Andrea Castillo-González[2]*

[1]Department of Pediatric Interventional Cardiology, Hospital de Especialidades Pediátricas, Universidad Autónoma de Chiapas, Tuxtla Gutiérrez, Chis.; [2]Department of Pediatric Interventional Cardiology, Instituto Nacional de Cardiología Ignacio Chávez, Mexico City, Mexico

Case presentation

In full-term children, the reported incidence of patent ductus arteriosus (PDA) is approximately 1 per 2000 live births, accounting for 5-10% of all congenital heart diseases[1]. Percutaneous closure of the PDA was first describe in 1967[2]. To date, advances in the fabrication of different devices and delivery systems have transformed this procedure.

Krichenko et al.[3] described a useful angiographical classification for guidance of transcatheter PDA closure. An interesting feature in young children is the reactivity of the duct to mechanical manipulations, which occur up to age 16 months. Ductal spasm may also occur during the process of closing a ductus and may result in inaccuracy in ductal measurement. This error may lead to undersized device occlusion, with subsequent device embolization.

Most ductal occlusions are completed without significant complications, but ductal spasm before or during the procedure remains a significant problem when encountered. This phenomenon was highlighted by Batlivala et al.[4] in a series of 331 occlusions and De Decker et al.[5] in a series of 267 ductal occlusions.

We report the case of a 1 year old male with history of symptoms of volume overload, left-sided heart failure, failure to thrive and recurrent chest infection. He had echocardiographic diagnostic of a big PDA with normal pulmonary artery pressure and normal left ventricular function.

The patient was presented in cardiac medical conference and we decided to perform PDA transcatheter closure. Previous to catheterization, the patient received prophylactic antibiotic therapy. The procedure was performed under fluoroscopic guidance and general anesthesia. Vascular access was completion with 4 Fr in the femoral artery and 5 Fr in the femoral vein. The size and shape of PDA was assessed on aortic angiography in lateral and right oblique projections. Initially, by angiography, the PDA morphology was classified as type A (Fig. 1A) in accordance with the classification stablished by Krichenko et al.[3].

Our first choice was a device 1–2 mm larger than narrowest diameter of the pulmonary end of the PDA so we chose an Amplatzer™ Duct Occluder I (ADO I,

***Correspondence:**
Roberto Mijangos-Vázquez
E-mail: dr.rmijangos@gmail.com

Date of reception: 21-05-2024
Date of acceptance: 17-12-2024
DOI: 10.24875/ACM.24000104

Available online: 19-02-2025
Arch Cardiol Mex. 2025;95(3):367-370
www.archivoscardiologia.com

1405-9940 / © 2024 Instituto Nacional de Cardiología Ignacio Chávez. Published by Permanyer. This is an open access article under the CC BY-NC-ND license (http://creativecommons.org/licenses/by-nc-nd/4.0/).

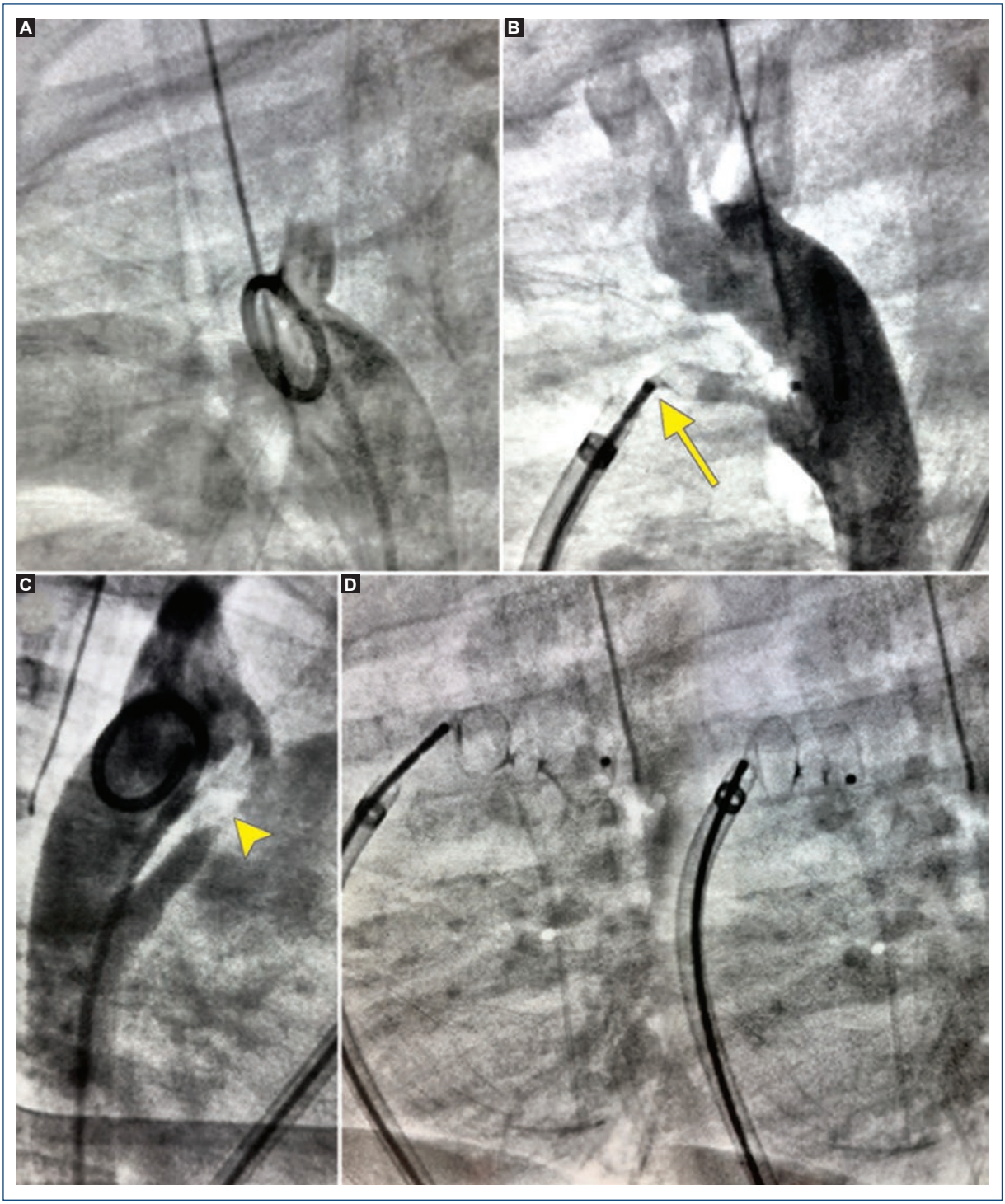

Figure 1. A: aortography in lateral view observing a type A ductus arteriosus (Krichenko [5] classification). **B**: aortography in lateral view. The device is completely delivered with a very important waist throughout the entire device (arrow). **C:** aortography in right anterior oblique. Type E ductus arteriosus with an important pulmonary end stenosis (arrowhead). **D:** amplatzer TM duct occluder II (ADO II) slipped out into the pulmonary trunk.

Abbott Cardiovascular) 8/6mm, this was implanted via a venous approach. However, once the device was in place, we noticed that the device took a completely different shape than was expected for the initial morphology of the ductus, the device had a very narrow waist (Fig. 1B), so the device was recaptured.

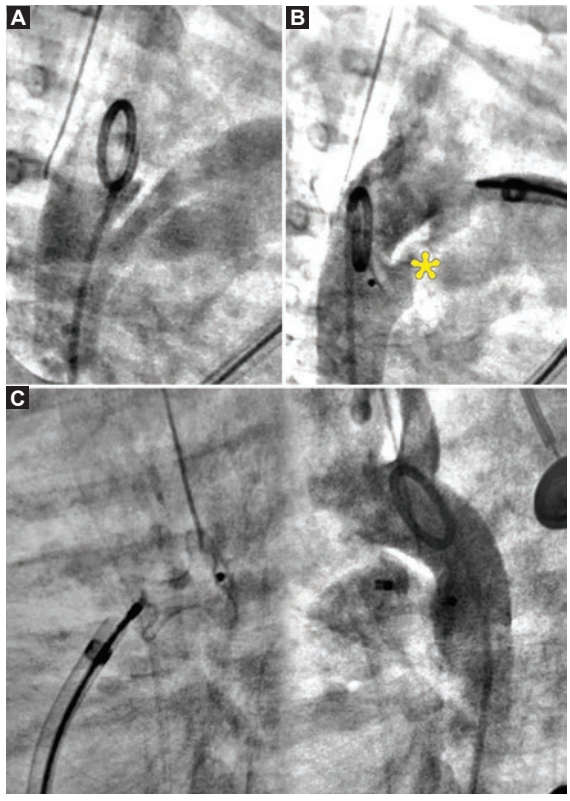

Figure 2. A: aortography in right anterior oblique. Type C ductus arteriosus. **B:** amplatzer TM device without covering the entire length of the ductus (asterisk). **C:** device released with good conformation and adequate position.

After that first device delivery, we performed a second angiography in right anterior oblique view and in that moment the ductus adopted a different morphology, it was classified as type E with a very important narrowness in the pulmonary end (Fig. 1C). In that moment, we concluded that a ductal spasm had occurred, so we changed the plan and selected a double-disc device to use, an Amplatzer™ Duct Occluder II (ADO II, Abbott Cardiovascular) 6/6mm. With venous approach, we initiated to deliver the proximal disc of the device; however, the device slipped out easily into the pulmonary trunk (Fig. 1D). This was actually something unexpected since the previous angiography confirmed a very important narrowing at the pulmonary end, so we were sure that the device would be completely anchored in this area of the duct.

After retrieving the second device, we performed a third angiography in right anterior oblique view and in that moment the ducts arteriosus adopted a different morphology, a very large ductus with no narrowing, it was classified as type C or possibly a fetal type duct (Fig. 2A). At that moment, we thought that the ductal spasm has recovered so we decided to try to use the latest device again, the ADO II; however, the length of the device did not cover the entire length of the PDA (Fig. 2B).

Finally, we chose a first-generation Amplatzer™ device (ADO I) but of a larger size (10/8mm).When the device was fully released we noticed that its final conformation was quite good, with the presence of an adequate waist. We performed a final angiography in lateral view and we observed adequate position of the device without residual shunts, so we decided to release it (Fig. 2C).

The patient showed improvement after the intervention and was discharged one day after the procedure. One month after the intervention, the patient showed improvement in his functional class with excellent clinical outcome. The Amplatzer™ device is seen in excellent shape with no residual shunts on echocardiogram.

In a study published in India, the authors aimed to report the safety and efficacy of the ADO II device in children younger than 3 years with a tubular or elongated PDA[6]. In our patient, after the second angiography was performed, the PDA was elongated and with a stenosis at the pulmonary end, so we decided to use an ADO II device. However, the result was not as favorable as we thought because the device was easily slipped out to the pulmonary trunk.

Recent reports have evaluated the Amplatzer™ Vascular Plug II (AVP II, Abbott Cardiovascular) in different anatomical variants, with encouraging results[7]. In the case that we present, we didn't use this type of device because the length of the ductus was larger than the length of the device.

Catheter closure of the PDA is among the safest interventional cardiac procedure, but rarely, the patent ductus has been found to close intermittently, because of the PDA spasm during the transcatheter closure. Discussion exist about the relative influences of various factors to the onset and maintenance of ductal spasm. In our case, after the different variations that we observed during the angiographies, we are really not sure about the behavior of the PDA. We hypothetically believe that maybe direct physical stimulation of the ductus by passing the exchange guidewire, the delivery system or after the use of the first ADO I device caused the ductal spasm. Nevertheless, even without manipulation, there have been reports of spontaneous spasm of the PDA that led to improper selection of device.

Beyond that, according to the literature, there are a number of factors contributing to the ductal spasm[8].

However, the spasm is not a common complication during transcatheter PDA closure. Even big studies have been informed about their complications and the duct spasms is not one the commonest. Galeczka et al.[9] published a study of 1036 patients and reported 73 periprocedural complications (7%). A higher complication rate was reported by El-Said et al.[10] reaching up to 9%. None of these great publications reported spasm or other morphology variations as a complication during their procedures. In contrast, what happened in our case is something extremely interesting and represented a great problem in choosing the device that should be used and without a doubt, most importantly, it could have represented a very high risk and a serious complication for the patient.

Spasm of the patent ductus arteriosus can occur during transcatheter closure and may be an unrecognized cause of procedural failure. Besides, the variations in morphology that may occur during percutaneous closure of the ductus arteriosus must be considered a very true complication.

The awareness that these variations exist is important before attempting catheter occlusion and may improve results with more widespread clinical application.

Funding

This research has not received any specific grant from agencies in the public, commercial, or for-profit sectors.

Conflicts of interest

The authors declare no conflicts of interest.

Ethical considerations

Protection of humans and animals. The authors declare that no experiments involving humans or animals were conducted for this research.

Confidentiality, informed consent, and ethical approval. The study does not involve patient personal data nor requires ethical approval. The SAGER guidelines do not apply.

Declaration on the use of artificial intelligence. The authors declare that no generative artificial intelligence was used in the writing of this manuscript.

References

1. Mitchell SC, Korones SB, Berendes HW. Congenital heart disease in 56,109 births. Incidence and natural history. Circulation 1971;43:323-32.
2. Porstmann W, Wierny L, Warnke H. Closure of the persistent ductus arteriosus without thoracotomy. Ger Med Mm 1967;12:259-261.
3. Krichenko A, Benson LN, Burrows P, Möes CA, McLaughlin P, Freedom RM, et al. Angiographic classification of the isolated, persistently patent ductus arteriosus and implications for percutaneous catheter occlusion. Am J Cardiol 1989;63(12):877–80.
4. Batlivala SP, Glatz AC, Gillespie MJ, Dori Y, Rome JJ. Ductal spasm during performance of transcatheter ductal occlusion. Catheter Cardiovasc Interv 2013, http://dx.doi.org/10.1002/ccd.25120 [Epub ahead of print.
5. De Decker R, Comitis G, Thomas J, Van Der Merwe E, Lawrenson J. A novel approach to ductal spasm during percutaneous device occlusion o patent ductus arteriosus. Cardiology in the Young (2016);26:1352-1358.
6. Kumar SM, Subramanian V, Bijulal S, Krishnamoorthy KM, Sivasankaran S, Tharakan JA. Percutaneous closure of a moderate to large tubular or elongated patent ductus arteriosus in children younger than 3 years: Is the ADO II appropriate?. Pediatr Cardiol 2013;34(7):1661-7.
7. Liddy S, Oslizlok P, Walsh KP. Comparison of the results of transcatheter closure of patent ductus arteriosus with newer amplatzer devices. Catheter Cardiovasc Interv 2013;82:253-9.
8. MacDonald ST, Bhindi R, Ormerod O, Wilson N. Ductus arteriosus spasm. JACC Cardiovasc Interv 2009;2(1):73.
9. Galeczka M, Szkutnik M, Bialkowski J, Litwin L, Smerdzinski S, Knop M, et al. Transcatheter patent ductus arteriosus closure: what have we learned after over 25 years? A single-center experience with 1036 patients. Kardiologia Polska 2021;79(3):287-293.
10. El-Said HG, Bratincsak A, Foerster SR, Murphy JJ, Vincent J, Holzer R et al. Safety of percutaneous patent ductus arteriosus closure: an unselected multicenter population experience. J Am Heart Assoc 2013;2(6):e000424.