

Traumatic coronary dissection: A heart attack game

Dissección coronaria traumática: un partido de infarto

Pilar Alcantud-Lozano¹, Juan J. Portero-Portaz^{2*}, Vicente Ferrer-Bleda², Sara Díaz-Lancha²,
Juan G. Córdoba-Soriano², and Jesús M. Jiménez-Mazuecos²

¹Department of Emergency, Hospital Hellín, Hellín; ²Department of Cardiology, Complejo Hospitalario Universitario de Albacete, Albacete, Spain

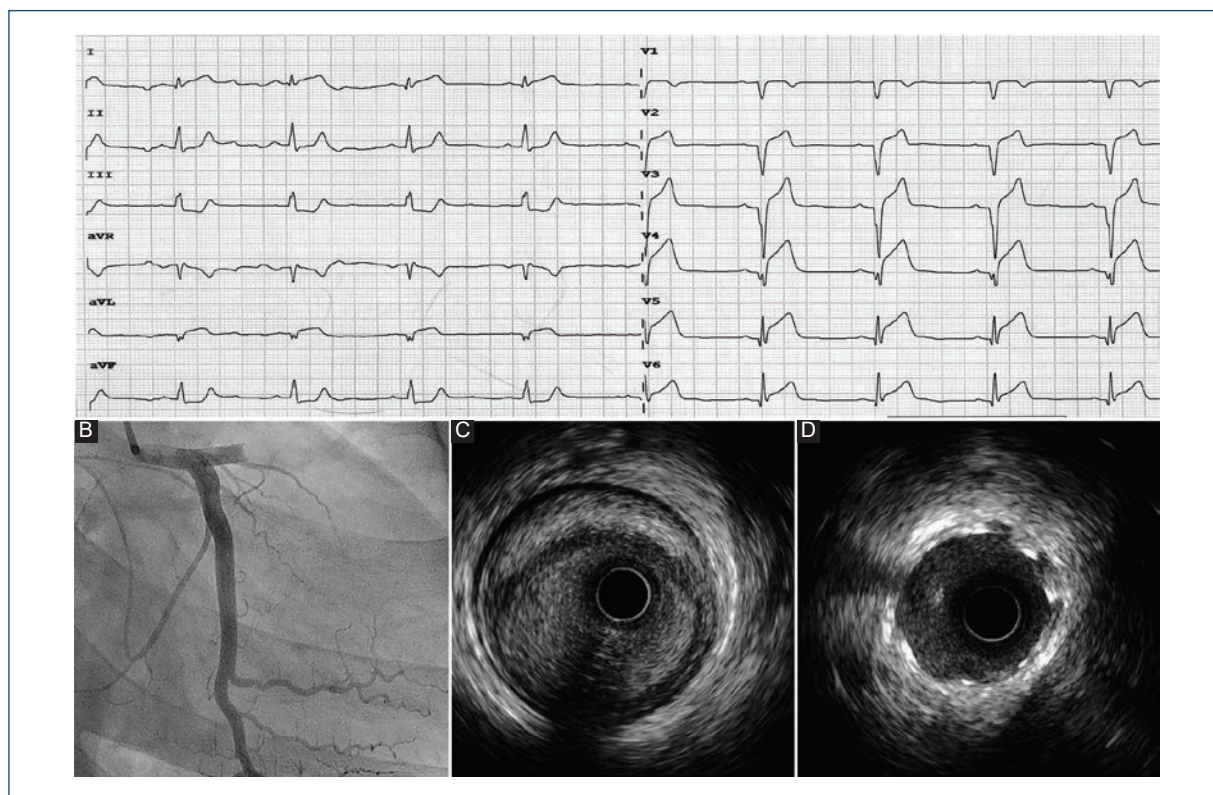


Figure 1. **A:** Electrocardiographic registry of ST-segment elevation myocardial infarction of anterolateral localization. **B:** Left coronary artery angiography (right anterior oblique + 20°, caudal + 20°) with anterior descending (AD) proximal acute occlusion. **C:** Pre-angioplasty intravascular ultrasound (IVUS) on AD with image of occlusive coronary artery dissection and intramural hematoma (meniscus-like or semilunar image). **D:** Post-angioplasty IVUS with covered stent implant; correct apposition and expansion are observed (hyper-refringent struts).

Correspondence:

*Juan J. Portero-Portaz

E-mail: Juanjose.porteroportaz@gmail.com

2604-7063 / © 2020 Instituto Nacional de Cardiología Ignacio Chávez. Published by Permanyer. This is an open access article under the CC BY-NC-ND license (<http://creativecommons.org/licenses/by-nc-nd/4.0/>).

Date of reception: 30-08-2019

Date of acceptance: 10-01-2020

DOI: 10.24875/ACME.M20000115

Available online: 04-09-2020

Arch Cardiol Mex (Eng). 2020;90(2):205-206

www.archivoscardiologia.com

Thirty-four-year-old man without cardiovascular risk factors who was a semi-professional rugby player. He referred chest pain after thoracic trauma (TT) during a match; he presented with poor general condition, bruising, and sternocostal tenderness. In view of the poor evolution, electrocardiogram (ECG) was performed under analgesia (Fig. 1A); by virtue of the findings, urgent coronary angiography was requested, which revealed an anterior descending (AD) artery occlusive dissection (Fig. 1B), with intramural hematoma image on intravascular ultrasound (IVUS; Fig. 1C); the patient was treated with drug-eluting stents implantation (Fig. 1D).

High-energy closed TTs, including those observed in contact sports¹, can cause serious injuries to internal organs. Although uncommon, traumatic coronary artery dissection is difficult to diagnose when clinical presentation, epidemiology, and patient characteristics do not reveal a coronary syndrome. The pathophysiology is largely unknown but, like other large vessels, traction-distraction forces appear to be the cause. There are no clear predisposing factors; according to some authors, collagen alterations, and non-significant atherosclerosis can modify the arterial structure and make it vulnerable.

Percutaneous revascularization is the strategy of choice in cases of occlusion or severe stenosis. In general, thrombolysis is not considered due to the differences in etiopathogenesis. Cases of conservative treatment have been described with good results in non-obstructive injuries, including surgical revascularization. Intracoronary imaging, although controversial, completes the diagnosis, and helps select treatment².

Although there are centers with established protocols, it is safe to say that in every high-energy TT, or

in those that are lighter but with incoercible pain or clinical involvement discordant with examination, necrosis markers' serialized analysis, and ECG are mandatory.

Funding

This work has not required any funding for its preparation.

Conflicts of interest

There are no conflicts of interest involving the authors.

Ethical disclosures

Protection of people and animals. The authors declare that no experiments were performed on humans or animals for this investigation.

Confidentiality of data. The authors declare that they have followed the protocols of their work center on the publication of patient data.

Right to privacy and informed consent. The authors have obtained informed consent from the patients or subjects referred to in the article. This document is in the possession of the corresponding author.

References

1. Hazeleger R, van der Wieken R, Slagboom T, Landsaat P. Coronary dissection and occlusion due to sports injury. *Circulation*. 2001; 103(8):1174-1175.
2. Moreno R, Pérez del Todo J, Nieto M, Alba F, Alfonso F, García-Rubira JC, et al. Primary stenting in acute myocardial infarction secondary to right coronary artery dissection following blunt chest trauma. Usefulness of intracoronary ultrasound. *Int J Cardiol*. 2005;103(2):209-211.