



SPECIAL ARTICLE

Catheter cryoablation of atrio-ventricular nodal reentrant tachycardia. A clinical review

Walid Amara,¹ Antonio De Sisti,² Laura Romero,³ Joelci Tonet³

¹ Cardiology Department, le Raincy-Montfermeil Hospital, Montfermeil, France.

² Cardiology Department, Poissy-St Germain-en-Laye Hospital, Poissy, France.

³ Cardiology Institute, Rhythmology Unit, Pitié-Salpêtrière Hospital, Paris, France.

Received on March 19, 2010; accepted on September 19, 2010.

KEY WORDS

AVNRT; Cryoablation;
AV-block; France.

Abstract

Cryoablation is a new method in interventional cardiac electrophysiology for percutaneous catheter ablation of cardiac arrhythmias. Cryothermal mapping enables the functional assessment of a particular site before permanent ablation. In this way, the targeted tissue may be confirmed as safe for ablation. This is useful in high-risk ablation, for example, next to the His bundle or the compact AV node. In the last decade, several studies have been addressed to AV-nodal reentry tachycardia (AVNRT) cryoablation. Current experiences indicate that cryoablation for AV-nodal reentry tachycardia is effective and safe. However, its wide use seems to be somewhat limited by a slightly lower efficacy when compared to radiofrequency. Further studies evaluating long-term success of cryothermal ablation versus radiofrequency are warranted. However, for high-risk ablations, cryoenergy is very helpful and should be systematically used. This article is a review of acute and long-term effects of cryoablation in patients suffering of AV-nodal reentry tachycardia episodes.

PALABRAS CLAVE

TRNAV; Crioablación;
Bloqueo AV; Francia.

Crioablación con catéter de la taquicardia por reentrada intranodal. Una revisión clínica

Resumen

La crioablación es un nuevo método en la electrofisiología cardiaca intervencionista para la ablación percutánea de las arritmias cardiacas. El mapeo criotérmico permite la evaluación funcional de un sitio en particular antes de la ablación permanente; de esta manera, el tejido blanco puede confirmarse como seguro para el procedimiento. Esto es útil en la ablación de alto riesgo, por ejemplo, cerca del haz de His o del nodo AV compacto. En la última década, varios estudios se han orientado a la crioablación para la taquicardia de reentrada del nodo AV (TRNAV). Las experiencias actuales indican que la crioablación de la taquicardia de reentrada del nodo AV es efectiva y segura. Sin embargo, la apertura para ampliar su uso está parcialmente limitada por su eficacia ligeramente menor al compararla con el empleo de la radiofrecuencia. Se justifican ensayos clínicos futuros con objeto de evaluar el éxito a largo plazo de la ablación criotérmica en comparación con la radiofrecuencia. Para las ablaciones de alto riesgo, la crioenergía es muy útil y debería ser usada sistemáticamente. Este artículo consiste en una revisión sobre los efectos inmediatos y a largo plazo de la crioablación en pacientes que presentan episodios de taquicardia por reentrada del nodo AV.

Correspondence author: Joelci Tonet, Hôpital de La Pitié-Salpêtrière, Institut de Cardiologie, Unité de Rythmologie, 47-83. Boulevard de l'Hôpital, 75651 Paris, France. Fax: 33142163057. E-mail: joelci.tonet@psl.aphp.fr

Introduction

Atrioventricular nodal reentrant tachycardia AV-nodal reentry tachycardia (AVNRT) is one of the most frequent supraventricular tachycardia targeted for endocardial catheter ablation. Although radiofrequency (RF) ablation remains the standard for the treatment of AVNRT worldwide, according to published data a small risk of irreversible complete atrioventricular (AV) block remains.¹⁻³ Particularly in young individuals, physicians and patients may be hesitant to perform RF catheter ablation because of the risk of inadvertent AV block, necessitating implantation of a permanent pacemaker (PM). Cryoablation is a new method in cardiac electrophysiology for percutaneous catheter ablation of cardiac arrhythmias. Cryoablation is an alternative to RF therapy for the treatment of AVNRT without any reported case of permanent AV block.⁴ The safety profile of cryoablation is also related to the reversibility of the cryothermal effect during cryomapping at -30°C , which allows for the functional assessment of a particular site before permanent cryoablation at -80°C . In this way, the targeted tissue may be confirmed as safe for ablation. This can be useful in high-risk ablations, for example, next to the His bundle or the compact AV node. In the last decade, several studies have been addressed to AVNRT cryoablation. This article is a review of acute and long-term effects of cryoablation in patients suffering of AVNRT episodes.

Principles of cryoablation

Cryocatheter ablation is performed by using a cryoablation system (CryoCath, Inc.) that consists of a control console and a 7F steerable catheter with a 4- or 6-mm-tip electrode and uses N_2O as the refrigerant fluid. The console delivers the refrigerant fluid to the tip of the cryocatheter through a hollow injection tube. The refrigerant fluid undergoes a phase change (from liquid to gas) at the

tip of the cryocatheter, resulting in cooling of the adjacent myocardial tissue. The gas is then removed through a second coaxial tube under vacuum.

The protocol of cryoablation procedure includes a preliminary cryomapping and a subsequent cryo-application after successful and uncomplicated cryomapping.⁵ Cryomapping is carried out first at a cryocatheter tip temperature of -30 to -40°C for a maximal duration of 60 s to test the electrophysiological effects on the target site by using programmed stimulation, which reproducibly demonstrated dual nodal physiology or induced AVNRT (Figure 1). In case of ineffective results or AV-block, cryomapping is stopped and then repeated at new target sites. Cryoablation, which creates a permanent lesion by cooling the tip temperature to -80°C generally for 4 minutes duration, is initiated immediately following successful cryomapping, defined as block of the slow pathway conduction or the non-inducibility of AVNRT. Programmed stimulation is repeated all the time during cryoablation to confirm the effectiveness of the ablation. If AVNRT is still inducible or AV-block occurs, cryoablation is stopped and cryomapping is repeated at a new target site. It is important to mention that, in contrast with radiofrequency catheter ablation of AVNRT, cryotherapy did not include ectopic rhythms.⁵

Advantages of cryoablation

Contrarily to RF, during cryomapping and cryoablation the cryocatheter tip adheres to the myocardial tissue because of ice formation. In comparison to RF, cryoablation induces less endothelium and connective tissue damages, limiting thrombi generation, as well as the risk of cardiac perforation and tamponade.^{5,6} The adjacent structures like artery or vein vessels or the esophagus are preserved by the cryotechnique (Figure 2). Contrarily to RF, cryoablation is painless, which reduces the need of anesthesia and sedation (Table 1).

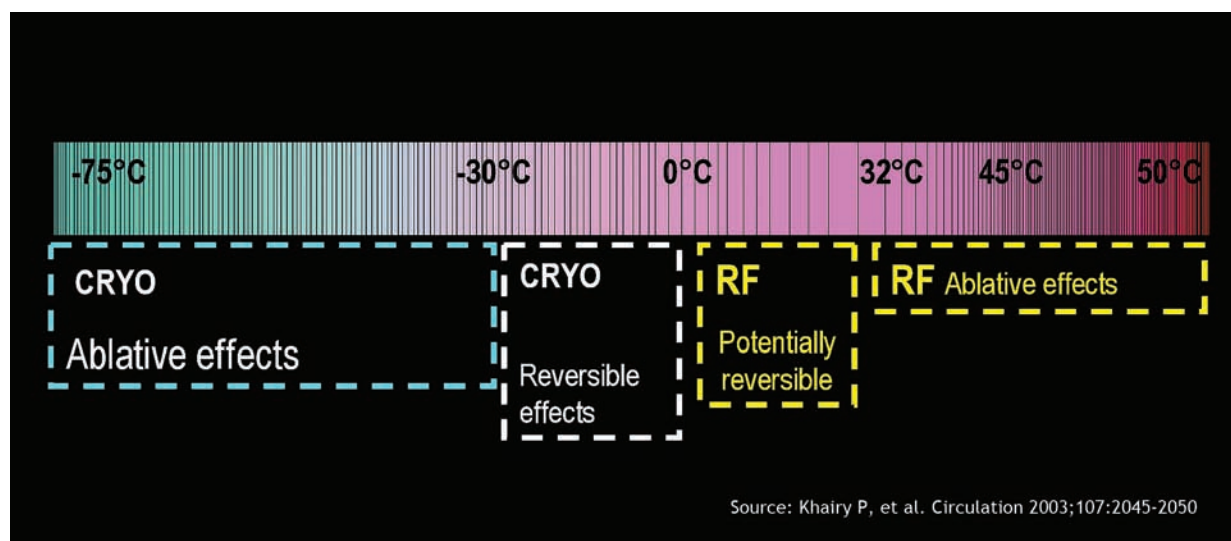


Figure 1. RF: radiofrequency; CRYO: cryoenergy.

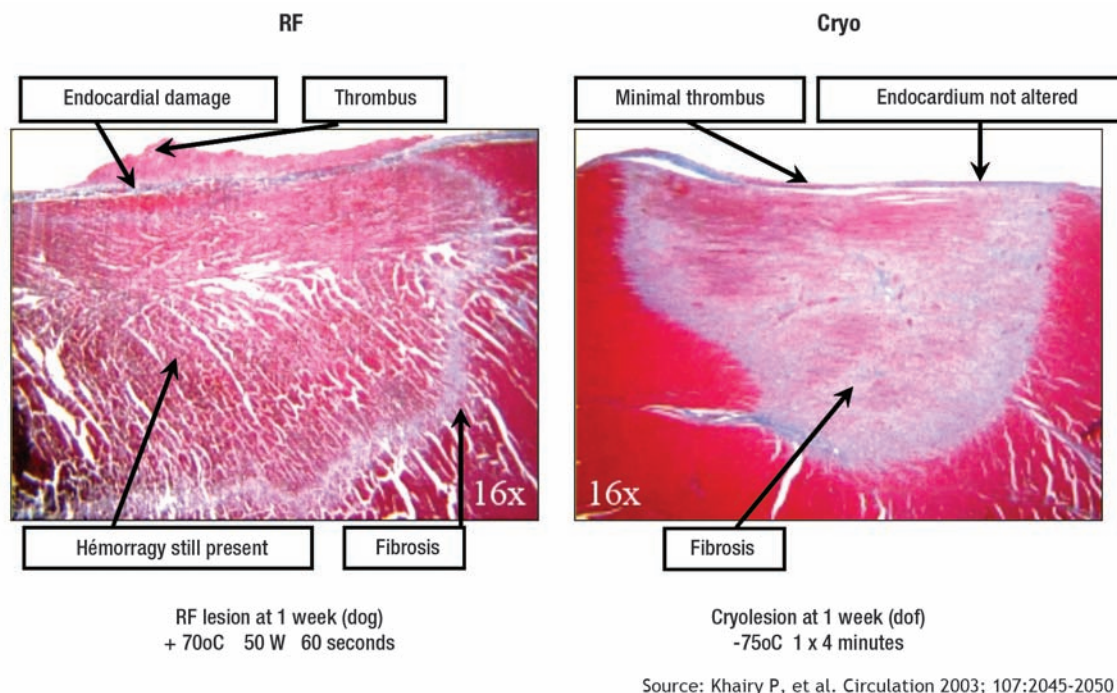


Figure 2. RF: radiofrequency; CRYO: cryoenergy

Clinical results of cryoablation for AVNRT

Cryoablation for AVNRT has been the object of numerous published studies in the last decade.⁴⁻²¹ Preliminary experiences have been conducted using a 4-mm tip catheter, nowadays employed especially in pediatric patients. In one of these first reports, Kimman et al,⁸ compared acute and long-term effects of RF and cryoablation in a prospective, randomized trial enrolling 102 patients with AVNRT. Procedural success using a 4-mm-tip catheter was identical between the two groups (91% and 93%, respectively) with similar fluoroscopy and procedural times. Long-term clinical success was also comparable showing 10% of recurrences in both groups. Similar results have been reported by Zrenner et al.⁹ in 200 patients randomly assigned to RF or cryoablation. Acute success rate was 97%, similar to that of RF. Nevertheless, recurrence rate was significantly higher in cryoablation patients than in the RF group (1% vs. 10%; $p < 0.03$). Subsequently, several studies have been published enrolling solely patients undergoing cryoablation, and mainly using a 6-mm-tip catheter.^{4,10-21} Globally, acute procedural success rate for AVNRT cryoablation reported in the literature ranges from 85% to 99% (Table 2), not so far from acute success described in RF series.¹⁻³ In studies using RF the incidence of recurrence was low (3% to 5%), but permanent AV-block with a PM implantation has been reported to be from 1% to 2% in experimented centers.¹⁻³ Overall, recurrence rate in studies involving cryoablation ranged from 7% to 20% (Table 2), higher than with RF catheter ablation. These

Table 1. Safe cryablation profile and clinical implications.

Advantages	Clinical implications
Reversible electrical effects of cryomapping	No virtual risk of permanent AV block Prediction of the results before cryoapplication
Adhesion to the myocardium	Catheter stability
Homogenous lesions	No arrhythmogenic effects
Less risk of thrombus formation	Less risk of embolization
Painless	Cooperation of the patient and less sedation
Connective tissue structure respected	Less risk of perforation
Precision of ablative effect	Less risk of damage to adjacent structures

inhomogeneous long-term results reported in cryoablation series could be explained by several reasons, like different cryocatheter size,^{4,16,17} patients age,²² inclusion of patients with complex anatomy,⁴ as well as different follow-up duration. Additionally, most of these studies have been planned without a control group of patients treated with RF. However, two recent non-randomized studies,^{13,18} in which a 6-mm cryocatheter was used, confirmed that acute success rate was similar between cryoablation and RF but recurrence rate was significantly higher with cryoablation.

Table 2. Comparison among studies.

Author	Year	N (pts)	Follow-up (months)	Age (years)	Tip Size (mm)	Acute Success (%)	Recurrence Rate (%)	Inadvertent AV-block (%)
Skanes AC	2000	18	4.9 ± 1.7	44 ± 14	4	94	0	0
Kimman GP*	2004	30	11.7 ± 7	52	4	93	10	7
Zrenner B*	2004	100	6.2	51 ± 18	4	97	8	17
Jensen-Urstad M	2006	75	9.2	53 ± 16	6	99	7	8
Collins KK*	2006	57	5-12	14 ± 4	4	95	8	2
Gupta D*	2007	71	2.2	52 ± 16	4 and 6	85	20	-
Khairy P	2007	185	24	49 ± 14	6	92	9	4.3
De Sisti A	2008	150	18 ± 10	39 ± 14	6	95	17	22.7
Sandilands A	2008	160	18	50 ± 19	4 and 6	93	12	6
Chanani NK	2008	154	2.5	13.7	4 and 6	95	14	-
Rivard L	2008	289	5	45.5 ± 16	4 and 6	90.7	15	5.2
Chan NY*	2009	80	§	50 ± 12	6	97.5	9	-
Bastani H	2009	312	22 ± 10	53	6	99	5.8	-

* Studies comparing cryoablation vs. radiofrequency ablation for AVNRT

§ Retrospective case-control study, period 2002-2008

Long-term predictive criteria

Some authors focused on long-term predictive criteria in AVNRT cryoablation patients. There are some evidences that a 6-mm-tip cryocatheter is superior to a 4-mm-tip in long-term results.^{4,16,17} Rivard et al,¹⁷ found that cryoablation with a 4-mm-tip catheter, when compared with 6-mm-tip, is associated with a 2.5-fold increased risk of arrhythmia recurrence during the follow-up. Sandilands et al,¹⁵ found that complete anterograde slow pathway conduction suppression is associated with long-term clinical success. However, residual persistence of slow pathway conduction has not been found as a predictor of AVNRT recurrence by other authors.^{4,14,16} Experimentally, a freezing-thawing-freezing cycle has been described to be associated with more extensive lesions.²³ Whereas some authors²¹ described in pediatric patients a long-term better effect of a “bonus” cryo-application at the effective site, others^{4,14} did not observe any significant effect in adults.

Inadvertent AV-block during cryoablation

Up to now, to our knowledge, no case of complete AV-block necessitating PM implant after cryoablation has been reported in the literature although this complication can be possible. Nevertheless, inadvertent AV-block, preceded by preliminary successful and uncomplicated cryomapping, ranges between 7% and 23%, when including also unwanted fast pathway lesion with PR prolongation (Table 2). Despite that AV-block occurrence was not uncommon, AV conduction rapidly recovered with tissue warming in all series describing this complication (Figure 3). In a study of De Sisti et al,⁴ all AV blocks occurring during cryoablation were transient, confirming the safety profile of cryoablation. After cryoablation interruption, 2nd - 3rd AV-block lasted generally few seconds, while 1st degree AV-block sometimes persisted, but AV conduction recovered after hours or some days (up to 4 days) in these patients. However, inadvertent fast pathway lesion with residual permanent 1st degree AV-block has been recently

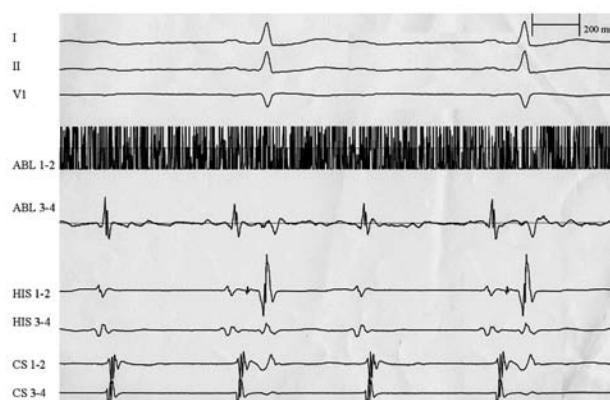

Figure 3. Example of inadvertent AV-block during cryoablation. Despite a successful and uncomplicated preliminary cryomapping (-30° C), 10 sec from the beginning of the cryoablation at -80° C, a 2/1 AV-block appeared. AV-block was transient, followed by complete AV recovery few seconds later. I, II, V1: surface ECG leads; ABL: ablation catheter; HIS: His catheter; CS: coronary sinus catheter.

described, but these patients underwent multiple ablation procedures and presented a small Kock's triangle.²⁴ Thus, adverse but still reversible effects on AV conduction may be observed during cryoablation in spite of the lack of previous deleterious effects of cryomapping. As underlined by Fischbach,²⁵ this experience demonstrates that the cryolesion created during cryoablation may expand relative to that suggested by cryomapping.

Clinical implications

It has been assumed that the cornerstone of cryotechnology is the capability to test its effect by creating a reversible lesion at a less critical temperature (-30 to -40° C) and, thereby, assessing a risk of AV-block. Cryoadherence prevents dislodgement of the catheter tip and therefore avoids unwanted energy delivery at the compact AV node

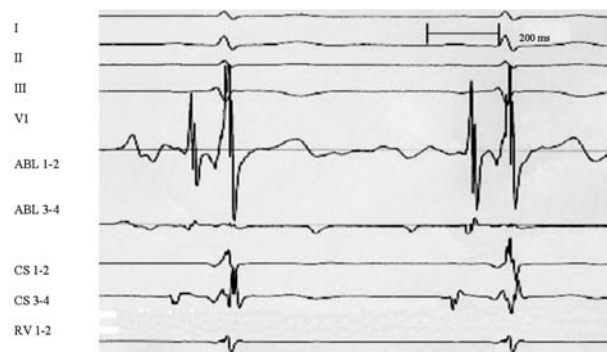


Figure 4. Note on ABL 1-2 the slow pathway potential and an atrio/ventricular amplitude ratio of about 1 recorded at the successful site before cryoapplication, slightly above the coronary sinus ostium. Procedural target, anatomic sites and markers of successful ablation are not the same between cryoablation and RF. Atrio/ventricular amplitude ratio at successful target when using cryoablation tends to be higher than that usually recommended when employing RF. I, II, III, V1: surface ECG leads; ABL: ablation catheter; CS: coronary sinus catheter; RV: right ventricle.

or His bundle. Junctional ectopy, a sensitive marker of successful RF ablation,²⁶ does not occur during cryoablation, which can facilitate monitoring during ablation. If this is the case, there will be a significant proportion of patients, especially young ones and those with particular AV node anatomy, in whom a less efficacious action may be preferred over the risk of needing a PM implantation, a disastrous event in the young population. However, inadvertent AV-block can occur despite an uncomplicated cryomapping. It has been observed in an animal model that the minimal application of cryoenergy to achieve complete nodal AV-block is of 10 sec in duration.²⁷ These data stress the need for a careful attention when ablating with cryoenergy instead of RF. Nevertheless, cryoablation's safe profile is counterbalanced by a slightly higher recurrence rate of arrhythmias during the follow-up.

Procedural target, anatomic sites, and markers of successful ablation are not the same between cryoablation and RF. Atrio/ventricular amplitude ratio at successful target when using cryoablation tends to be higher (Figure 4) than that usually recommended when employing RF. Absence of junctional rhythm during cryoablation facilitates fast pathway monitoring, whereas during RF it constitutes a common accepted marker of success.

Recurrence rate seems to be lower along the learning curve effect, and the use of 6-mm-tip catheters. Finally, a limitation for a widespread use of cryocatheters is their cost, which is higher in France than catheters commonly used in RF.

Conclusions

Current experiences indicate that cryoablation for AVNRT is effective and safe. However, its use seems to be counteracted by a slightly lower long-term efficacy when compared to radiofrequency. Further studies evaluating long-term success of cryoablation versus radiofrequency are warranted. However, for high-risk ablations, cryoenergy is very helpful and should be systematically used.

References

1. Calkins H, Yong P, Miller JM, et al. Catheter ablation of accessory pathways, atrioventricular nodal reentrant tachycardia, and the atrioventricular junction: final results of a prospective, multicenter clinical trial. The Atakr Multicenter Investigators Group. *Circulation* 1999;99:262-270.
2. Hindricks G. The Multicentre European Radiofrequency Survey (MERFS): complications of radiofrequency catheter ablation of arrhythmias. The Multicentre European Radiofrequency Survey (MERFS) investigators of the Working Group on Arrhythmias of the European Society of Cardiology. *Eur. Heart J* 1993;14:1644-1653.
3. Scheinman MM, Huang S. The 1998 NASPE prospective catheter ablation registry. *Pacing Clin Electrophysiol* 2000;23:1020-1028.
4. De Sisti A, Tonet J, Gueffaf F, et al. Effects of inadvertent atrioventricular block on clinical outcomes during cryoablation of the slow pathway in the treatment of atrioventricular nodal reentrant tachycardia. *Europace* 2008;10:1421-1427.
5. Márquez MF, Colín L, Iturralde P, et al. La ablación criotérmica percutánea directa elimina la conducción de la vía lenta intranodal sin inducir ritmos ectópicos. *Arch Cardiol Mex* 2005;75:112-117.
6. Khairy P, Chauvet P, Lehmann J, et al. Lower incidence of thrombus formation with cryoenergy versus radiofrequency catheter ablation. *Circulation* 2003 22;107:2045-2050.
7. Skanes AC, Dubuc M, Klein GJ, et al. Cryothermal ablation of the slow pathway for the elimination of atrioventricular nodal reentrant tachycardia. *Circulation* 2000;102:2856-2860.
8. Kimman GP, Theuns DAMJ, Szili-Torok T, et al. CRAVT: a prospective, randomized study comparing transvenous cryothermal and radiofrequency ablation in atrioventricular re-entrant tachycardia. *European Heart Journal* 2004; 25: 2232-2237.
9. Zrenner B, Dong J, Schreieck J, et al. Transvenous cryoablation versus radiofrequency ablation of the slow pathway for the treatment of atrioventricular nodal re-entrant tachycardia: a prospective randomized pilot study. *European Heart Journal* 2004;25:2226-2231.
10. Friedman PL, Dubuc M, Green MS, et al. Catheter cryoablation of supraventricular tachycardia: results of the multicenter prospective "frosty" trial. *Heart Rhythm* 2004;1:129-138.
11. Jensen-Urstad M, Tabrizi F, Kenneback G, et al. High success rate with cryomapping and cryoablation of atrioventricular nodal reentry tachycardia. *Pacing Clin Electrophysiol* 2006;29:487-489.
12. Collins KK, Dubin AM, Chiesa NA, et al. Cryoablation versus radiofrequency ablation for treatment of pediatric atrioventricular reentrant tachycardia: initial experience with 4-mm cryocatheter. *Heart Rhythm* 2006;3:564-570.
13. Gupta D, Al-Lamee RK, Earley MJ, et al. Cryoablation compared with radiofrequency ablation for atrioventricular nodal re-entrant tachycardia: analysis of factors contributing to acute and follow-up outcome. *Europace* 2006;8:1022-1026.
14. Khairy P, Novak PG, Guerra PG, et al. Cryothermal slow pathway modification for atrioventricular nodal reentrant tachycardia. *Europace* 2007;9:909-914.
15. Sandilands A, Boreham P, Pitts-Crick J, et al. Impact of cryoablation catheter size on success rates in the treatment of atrioventricular nodal re-entry tachycardia in 160 patients with long-term follow-up. *Europace* 2008 Jun;10:683-686.
16. Chanani NK, Chiesa NA, Dubin AM, et al. Cryoablation for atrioventricular nodal reentrant tachycardia in young patients: predictors of recurrence. *Pacing Clin Electrophysiol* 2008;31:1152-1159.
17. Rivard L, Dubuc M, Guerra PG, et al. Cryoablation outcomes for AV nodal reentrant tachycardia comparing 4-mm versus 6-mm electrode-tip catheters. *Heart Rhythm* 2008;5:230-234.
18. Chan NY, Mok NS, Lau CL, et al. Treatment of atrioventricular nodal re-entrant tachycardia by cryoablation with a 6 mm-tip catheter vs. radiofrequency ablation. *Europace* 2009;11:1065-1070.

19. Bastani H, Schwieler J, Insulander P, et al. Acute and long-term outcome of cryoablation therapy of typical atrioventricular nodal reentrant tachycardia. *Europace* 2009;11:1077-1082.
20. Papez AL, Al-Ahdab M, Dick M 2nd, et al. Transcatheter cryotherapy for the treatment of supraventricular tachyarrhythmias in children: a single center experience. *J Interv Card Electrophysiol* 2006;15:191-196.
21. Drago F, Silvetti MS, De Santis A, et al. Lengthier cryoablation and a bonus cryoapplication is associated with improved efficacy for cryothermal catheter ablation of supraventricular tachycardias in children. *J Interv Card Electrophysiol* 2006; 16:191-198.
22. Estner HL, Ndreppa G, Dong J, et al. Acute and long-term results of slow pathway ablation in patients with atrioventricular nodal reentrant tachycardia-an analysis of the predictive factors for arrhythmia recurrence. *Pacing Clin Electrophysiol* 2005;28: 102-110.
23. Baust JG, Gage AA. The molecular basis of cryosurgery. *BJU International* 2005;95:1187-1191.
24. De Sisti A, Tonet J, Benkaci A, et al. A case of inappropriate sinus tachycardia after AVNRT cryoablation successfully treated by ivabradine. *Europace* 2010;12:1029-1031.
25. Fischbach PS, Saarel EV, Dick M. Transient atrioventricular conduction block with cryoablation following normal cryomapping. *Heart Rhythm* 2004;1:554-557.
26. Jentzer JH, Goyal R, Williamson BD, et al. Analysis of junctional ectopy during radiofrequency ablation of the slow pathway in patients with atrioventricular nodal reentrant tachycardia. *Circulation* 1994;90:2820-2826.
27. Wadhwa MK, Rahme MM, Dobak J, et al. Transcatheter cryoablation of ventricular myocardium in dogs. *J. Interv Card Electrophysiol* 2000;4:537-545.