



Multi-disciplinary approach for rehabilitation of a partially edentulous patient: Case presentation

Manejo multidisciplinario para la rehabilitación de un paciente parcialmente desdentado: Presentación de un caso

Carolina Sánchez Zúñiga* Carolina Higashida Guerrero,[§] Humberto J Ballado Nava,^{||} Adriana Peniche Becerra[¶]

ABSTRACT

Multidisciplinary treatment for oral rehabilitation of a partially edentulous patient with atrophic process is paramount to emit correct diagnosis and to determine the most convenient treatment plan which might restore appropriate masticatory function and adequate aesthetics. The clinical case here presented is that of a partially edentulous 51 year old male. The periodontics, prosthetics, and orthodontic departments jointly concurred in emitting a total rehabilitation diagnosis. As part of the treatment, it was decided to orthodontically extrude upper right central and lateral incisors in order to achieve enhanced bone levels. Five months into the treatment, four implants were put into place; in a simultaneous fashion, elevation of the maxillary sinus floor was undertaken. This process was performed with the Caldwell Luc technique, with the use of an electrical hand-piece device. During the same surgical procedure, another implant was placed in the area of the left upper first molar. Elevation of the sinus floor was conducted following Summers technique. Six months after placing the implants, implants were uncovered and healing abutments were put into place. Three months later, a prosthetic rehabilitation was initiated by placing an implant-supported prosthesis on the right side of the upper jaw, a single zircon crown on the implant in the first upper left molar, and a bilateral, partially removable prosthesis on the lower jaw. Achieved results, with respect to function and aesthetics, were deemed satisfactory by the patient.

RESUMEN

El manejo multidisciplinario para la rehabilitación bucal de un paciente parcialmente desdentado con un proceso atrófico, es de suma importancia para lograr un diagnóstico correcto y así poder determinar el tratamiento más adecuado, devolviendo la función masticatoria y estética. El caso clínico que se presenta es de un paciente masculino de 51 años de edad parcialmente desdentado, el cual fue diagnosticado en conjunto con los departamentos de periodoncia, ortodoncia y prótesis para su rehabilitación bucal. Dentro del tratamiento se decidió realizar la extrusión forzada lenta, ortodómicamente asistida, de los órganos dentarios (o.d.) central y lateral superior derecho para mejorar el proceso óseo y posteriormente hacer la colocación de cuatro implantes endóseos, realizando simultáneamente la elevación de piso de seno maxilar, utilizando la técnica de Caldwell Luc con piezoeléctrico. En el mismo acto quirúrgico se realizó la colocación de otro implante en la zona del primer molar superior izquierdo y se realizó elevación del piso de seno con la técnica de Summers. Seis meses posterior a la colocación de implantes se realizó el descubrimiento de los mismos y se colocaron tornillos de cicatrización. Tres meses después, se inició con la rehabilitación protésica, colocando una prótesis fija implanto soportada de zirconia en la zona del maxilar superior derecho, una corona individual de zirconia en el implante del maxilar superior izquierdo y una prótesis parcial removible bilateral inferior. Los resultados que se obtuvieron fueron satisfactorios para el paciente tanto en función como en estética.

Key words: Maxillary Sinus Floor Elevation, piezoelectric, periimplant tissue, slow force extrusion, zircon.

Palabras clave: Elevación del piso del seno maxilar, piezoeléctrico, tejido periimplantar, extrusión forzada, zirconia.

INTRODUCTION

After loss of teeth in the upper and lower jaw, alterations might take place. These are: horizontal and vertical resorption of the alveolar bone, decrease in bone quality as well as decrease in amount of soft tissues. These factors might be detrimental to prosthetic rehabilitation based on dental implants. Different regeneration techniques have been used to restore bone volumes and rebuild lost tissues.

* Resident, Implantology and Periodontics Specialty.

§ Professor, Implantology and Periodontics Specialty, Implantology Degree.

|| Professor, Implantology and Periodontics Specialty.

¶ Resident, Orthodontics Specialty.

Graduate School, National School of Dentistry, National University of Mexico (UNAM).

This article can be read in its full version in the following page:
<http://www.medigraphic.com/facultadodontologiaunam>

Forced extrusion is an orthodontic treatment approach, aimed at elongating the tooth's clinical crown. When using moderate forces, it is possible that the insertion apparatus, as a whole, extrudes along with the tooth,¹ in such a way as to favoring tissue regeneration, thus decreasing intra-osseous defects and diminishing depth in the periodontal pocket, and in turn guiding connective tissue towards a more coronary position. Extrusion of a single tooth is specifically used for correction of bone defects created by periodontal problems, dental fractures, and to level or align gingival margins.¹⁻³ To perform this movement, anchorage or orthodontic mini-implants can be used; this will allow movement of the teeth in three spatial planes. They are very effective when combined with other orthodontic systems (straight wire, expansion devices, etc.) as well as in cases when the number of teeth present is insufficient to perform conventional anchorage. This might be due to hypodontia or as a consequence of periodontal disease. FDA considers these implants less invasive, they present few usage limitations, they are easy to place and remove and they allow immediate loads without requiring previous bone integration.⁴

Tatum (1970) introduced the technique of maxillary sinus elevation for implant placement. He modified this technique in 1974, based on the Caldwell Luc technique. The procedure was later modified by Boyne and James (1980) and Wood and Moore (1998). In 1996, the Consensus Conference, sponsored by the Osseo-Integration Academy, determined that bone graft in the sinus can be considered a highly predictable and effective treatment. In Tatum's technique, access to the maxillary sinus is achieved through a bone window, performed with a ball-like rotating device and located in the lateral wall. The membrane lining the sinus is carefully dislodged. When placing implants with elevation of the maxillary floor, two strategies can be followed. Favoring one over the other will depend on amount and quality of residual bone to allow primary stability of the implant.^{5,19} Firstly, when bone process is considerably atrophic (< 4mm height) it is recommended to perform a bone graft to elevate the sinus, and place the implants after 6 to 10 months. The disadvantage here lies in the fact of prolonging treatment.⁶ Secondly, elevation of sinus floor and implant placement can be performed simultaneously. This technique offers the advantage of decreasing the number of surgical procedures and thus reducing treatment time and cost. Nevertheless, > 5 mm residual bone height is required for the placed implant to have primary stability.^{6,7} Generally, a diversity of bone materials are used; among these we can mention autologous grafts, iliac

crest, chin, mandibular ramus upper skull fragment (calvarium). These can be bone substitutes, used either by themselves or in combination with autologous bone, and sometimes with the use of growth factors which could enhance angiogenesis, healing, as well as stability of the bone implant.^{6,8,9}

Presently, the use of an ultrasonic device introduced by Dr. Tomaso Vercellotti (electrical or surgical hand-piece) offers a very conservative technique to cut bone without damaging neighboring soft tissues (vessels, nerves, etc.) with the use of 25-30 kHz frequency. Therefore, it offers the following advantages: it reduces the risk of perforating maxillary sinus membrane, improves visibility since it decreases bleeding and it decreases surgical trauma.⁹⁻¹¹

Summers, in 1994,¹² introduced an implant placement technique whereby implants were put into place simultaneously with the elevation of the maxillary sinus either with osteotomes or through alveoli. This technique is considered less invasive when compared to the lateral window technique. Summers suggests to perform the technique with the immediate insertion of the implant in cases when the remaining bone measures over 6 mm in height. Nevertheless some other scientific studies inform of the possibility to perform this procedure in bone processes measuring less than 5 mm height when combined with bone grafts.^{13,14}

During the process of placing implants, treatment of soft tissues during the second surgical phase is a key factor to achieve esthetic results, as well as to achieve long term maintenance. Adell, Lekholm and Branemark¹⁴ originally described a technique for uncovering implants after the integration phase. This is also known as second phase surgery. The aim of this type of surgery is to expose the implant in the oral cavity and create favorable soft tissue anatomy and contour around the implant to thus achieve healthy gingival architecture. In this technique, implants are located through palpation and probing, an incision is performed over all implants, preferably on keratinized tissue. The upper section (lid) of the implants is exposed, and with the help of «tissue punch» tissue perforator, tissue remnants found around the implants are removed. After this, the lid is withdrawn and healing components (materials) are put into place. Hertel et al.¹⁵ studied several second phase techniques and divided them into incision or reconstructive. Within the reconstructive technique, they propose a method which consists on performing a wide incision in the middle portion of keratinized tissue over the implants so as to gain visualization. Then, healing components are placed without removing keratinized tissue, which

in fact is just pushed into vestibular and lingual, or palatine direction. After this, suturing is conducted from side to side. With this procedure, second intention healing is promoted in some cases, so as to preserve and gain keratinized tissue. Palacci and Nowzai¹⁶ mention a similar technique where a crest incision is performed without extension. It only encompasses the diameter of the lid of the implant, and thus allows for the positioning in the mouth of tissues surrounding the implant. The authors mention that the tissue-punch technique is recommended in cases when no connective tissue and keratinized mucosa are required around the devices, in cases when there is an excess of tissue around the implant, or when implants and fixtures are placed in one single phase.

Raetzke¹⁷ Introduced the «bag or envelope» technique of connective tissue graft to cover an exposed root. This technique consists on performing a small groove-like incision around the defect; the incision is deepened along the tooth, creating a «bag» so as to later place connective tissue within it. This technique is considered minimally invasive, it offers excellent vascularization, and this type of graft achieves height and volume of keratinized tissue, improving thus the esthetics of the restoration. Askary¹⁸ informs that this «bag or envelope» technique can be used to increase soft tissue thickness in implant-supported restorations, especially in areas where esthetics are important. There are two ways of applying these connective grafts: the first consists on only applying connective tissue, in the other there is connective tissue along with epithelium ring (composite graft). Palacci and Nowzari¹⁶ suggest to use this «envelope» technique to modify the quality of tissue surrounding the implants and thus thickening it in cases where fenestrations might be present, or when soft tissue is thin and transparent, or in zones when esthetics are important.

Different ceramic materials are used nowadays for the prosthetic rehabilitation of implants. One of these materials is zirconia. Zirconia was discovered by Heinrich Klaproth in 1789, but it was not until 1969 when it was again described by Helmer Driskell. In his article he describes it as a fit material to be used in biomedical fields. In 1975, Ron Garvic called it «ceramic steel» due to its outstanding mechanical properties. Tetragonal zirconia, partially stabilized with Yttrium (Y-TZP) is, nowadays, the most resistant and stable ceramic material in the market. It has the property of resisting compression at a 2,000 Mpa magnitude, and presents 900 to 1,200 Mpa flexure (bending) resistance. It is recommended to use zirconia in fixed prosthesis (up to 14 teeth), inlays and onlays, structures for implants, fixtures, Maryland type bridges and

one piece cantilevers. Zirconia is bio-compatible with tissue, it also allows for emergence of proper profile, translucency, and its texture enables proper cleansing of the prosthesis. It is therefore here concluded that ceramic materials should be preferred to metallic materials, especially in those patients who demand high levels of esthetic results.^{35,36,38}

CLINICAL CASE

A 51 year old male arrived at the Periodontics and Implantology clinic seeking oral rehabilitation with fixed prosthesis. The orthodontics, periodontics and prosthesis departments were consulted to achieve proper treatment (*Figure 1*). Clinical history was taken as well as study models, X-Rays, and bone mapping of the edentulous zone. The patient did not report any relevant pathological persona data; he was a generally healthy, non-smoker subject. When performing oral diagnosis, Kennedy type I class was found in upper and lower edentulous areas, as well as chronic periodontitis located at tooth number 11, with a 5 mm probing depth. Teeth number 43 and 44 presented caries. Radiographic examination revealed canal treatment in teeth number 12, 11, 23, 25, 35 and 44. C-h division residual ridge according to Misch and Judy classification (1985)¹⁹ and a SA-3 maxillary sinus in both sides, according to the sub-antrum classification provided by these same authors (1987) (*Figure 2*).

TREATMENT

Operative dentistry was performed on affected teeth. Periodontal phase 1 and debridement with a flap on tooth 11. Once periodontal stabilization was achieved, reconstruction and placement of provisional restorations on teeth 11 and 12 were undertaken.

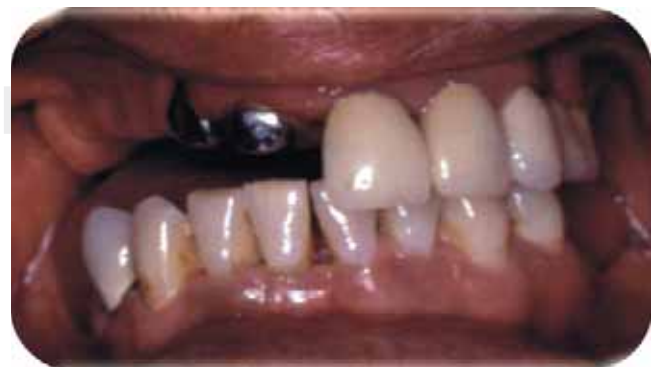

Figure 1. Initial picture.

To this effect, O.S.A.S (Orthodontic Skeletal Anchorage System) orthodontic mini-implants were used to achieved slow, forced extrusion. Implants were placed in vestibular position at the level of tooth number 43. Rubber bands were placed connecting mini-implants with the provisional restorations. Treatment continued by applying 3.5 ounce force (99.22 g) with 1/4 Φ rubber bands, every day during three months. These rubber bands were later replaced by 3/16 Φ rubber bands.

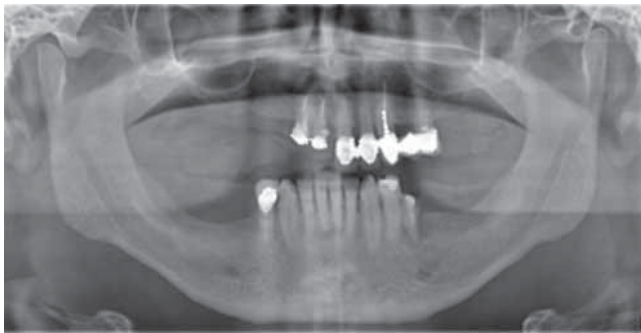

Figure 2. Initial x-ray.

These bands daily exert a 4.5 ounce force (127.57 g). Slow, forced extrusion was conducted for a 5 month span (*Figure 3*). Once the vertical bone defect present in tooth number 11 was corrected, mini-implants were removed and the restoration was stabilized for one month.

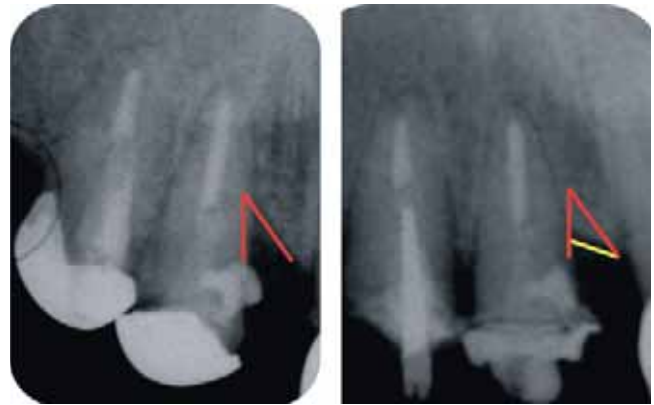

Figure 3. Forced extrusion results. **A)** before forced extrusion. **B)** after forced extrusion. The highlighted line indicates decrease of vertical bone defect.

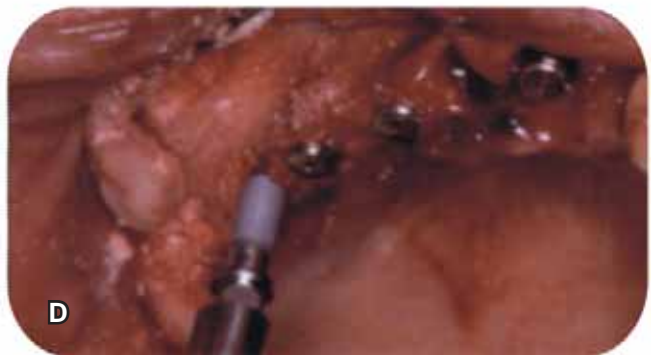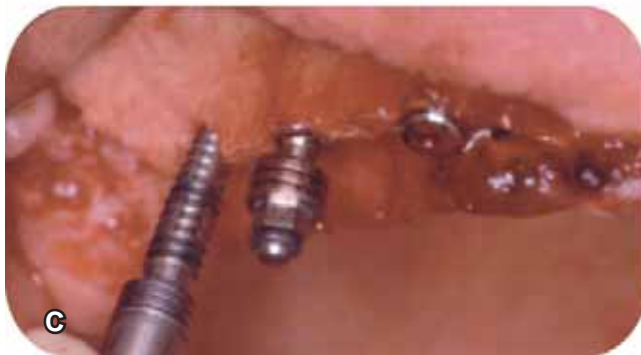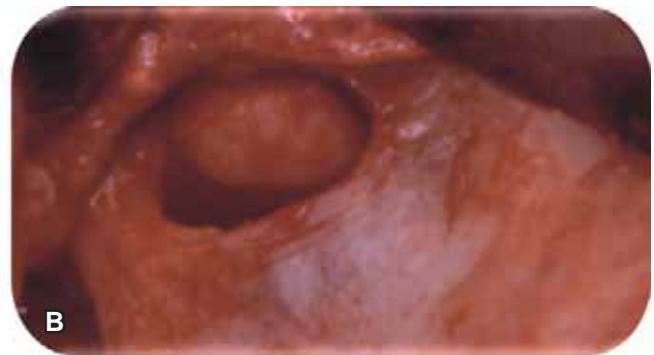


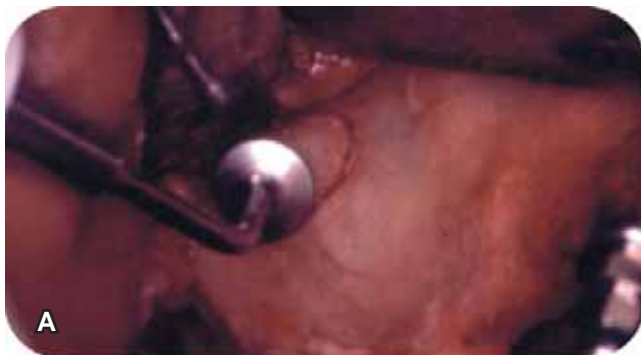Figure 4. Surgical procedure. **A)** A lateral window was established with an electrical hand-piece. **B)** Rotation of bone window and dissected membrane. **C)** Preparation of surgical bed in combination with bone expansion. **D)** implants in place.

Under infiltration local anesthesia (2% lidocaine and 1:100,000 UI epinephrine) a-traumatic extraction of teeth number 11 and 12 was performed. A muco-periosteal flap was raised, and an osteotomy was performed with the help of a surgical guide. SLA IMTEC 3.75 x 13 mm implant placement burr use protocol was observed for implant placement in area of teeth 11 and 13. At a later point, the sinus was located and the osteotome for right maxillary sinus approach was undertaken. To this effect ultrasonic device (electrical handpiece Osada Electric®) was used. Once the window definition was established, it was medially rotated. Sinus membrane was dissected with electrical hand-piece points as well as curettes (Sinus Standar, ACE®). Bone process was regulated. With the help of the surgical guide, the burr work was continued. This procedure was combined with bone expansion performed with engine-driven expanders (BTI® Expanders) to prepare the surgical bed in the area of teeth 15 and 16. Once implants were placed, and adequate primary stability achieved, a mixture of de-mineralized cortical bone (Osseo, IMTEC®) absorbable hydroxylapatite (HA) (OsteoGen® Impladent) and plasma rich in growth factors (PRGF) were placed into the sinus. The lateral window was covered with a collagen membrane (Biosorb®) secured with titanium tacks (Titac®) (Figure 4). On the left side, a maxillary sinus elevation was performed following Summers technique. A muco-periosteal flap was raised. Preparation of surgical bed was undertaken. To this effect use was made of a marking burr, which perforated up to 1 mm of the sinus floor. X-ray verification was employed. Engine-driven expanders were introduced, and the sinus floor was fractured with a number 3 osteotome (Biomet®). De-mineralized cortical bone, absorbable HA, and PRGF were applied. Finally, the implant was put into place (Figure 5). Both sides were sutured with 3-0 silk.

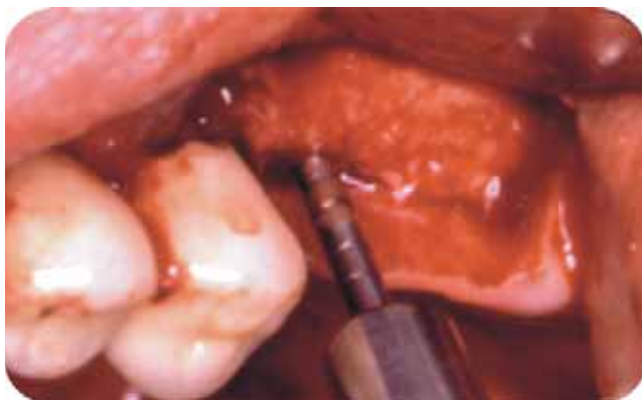

Figure 5. Elevation of sinus with osteotomes.

After the operation, the patient was prescribed with amoxicillin and clavulanic acid 500/125 mg, every 8 hours for 10 days, ibuprofen 400 mg every 6 hours for 5 days, loratadine 10 mg one daily for 3 days, 0.12 chlorhexidine mouthwash every 12 hours for 2 weeks, oximetazoline 50 mg/d nasal drops for 3 days. A provisional bilateral removable device was fitted to enhance esthetics. All sutures were removed 10 days after the operation. The patient was subject to radiographic and clinical follow-up at 4, 5 and 6 months. During the interval, conventional extractions of teeth number 35 and 44 were performed (Figure 6).

Six months after placement, implants were uncovered to place healing screws. Implant placed in tooth 26 area was uncovered with «punch» technique. With the help of a surgical guide and a probe, a small incision was performed on the lid of implants 16, 15, 13 and 11. The lid was removed to place healing screws, in such a manner as to displace tissue towards vestibular and palatine direction. Once the healing screws were in place, in 13 and 15 area, a connective tissue graft harvested from the palate was placed following the envelope technique. Suturing was performed with polylactic and polyglycolic acid (vicryl) 4-0. The patient received prescription of ibuprofen, 400 mg every 6-8 hours. Sutures were removed 10 days after procedure. A waiting period of 3 months was observed to initiate prosthetic rehabilitation (Figure 7).

PROSTHETIC REHABILITATION

Impressions were taken with personalized open spoon, with impression posts placed in corresponding implants. Splints were achieved with duralay acrylic, using heavy and light body vinyl-polysiloxane (Virtual, Ivoclar). A new waxing procedure was undertaken to determine position and size of teeth. Based on it, a

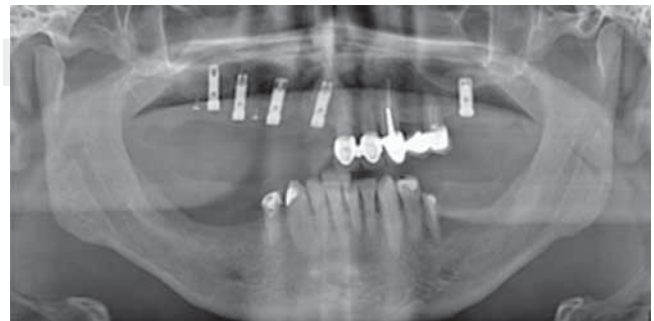

Figure 6. Panoramic x-ray with implants in place.

simulation (mock up) polyurethane prosthesis was manufactured. With the help of this device, the passive fit of the prosthesis was assessed, as well as tooth shape and occlusion. The antagonist was the skeleton of the lower removable prosthesis with wax rods. Once the prosthesis was corrected in the polyurethane, it was sent to be finished with ZirconZahn® system. The fixed prosthesis was screwed into place in the right upper jaw, the individual crown was cemented in number

26, and the metal-acrylic bilateral removable partial prosthesis was placed in the lower jaw.

DISCUSSION

Orthodontic movements can contribute to increasing soft and hard tissue dimensions located around a periodontically compromised tooth. Strict control must be exercised in cases where predisposition to

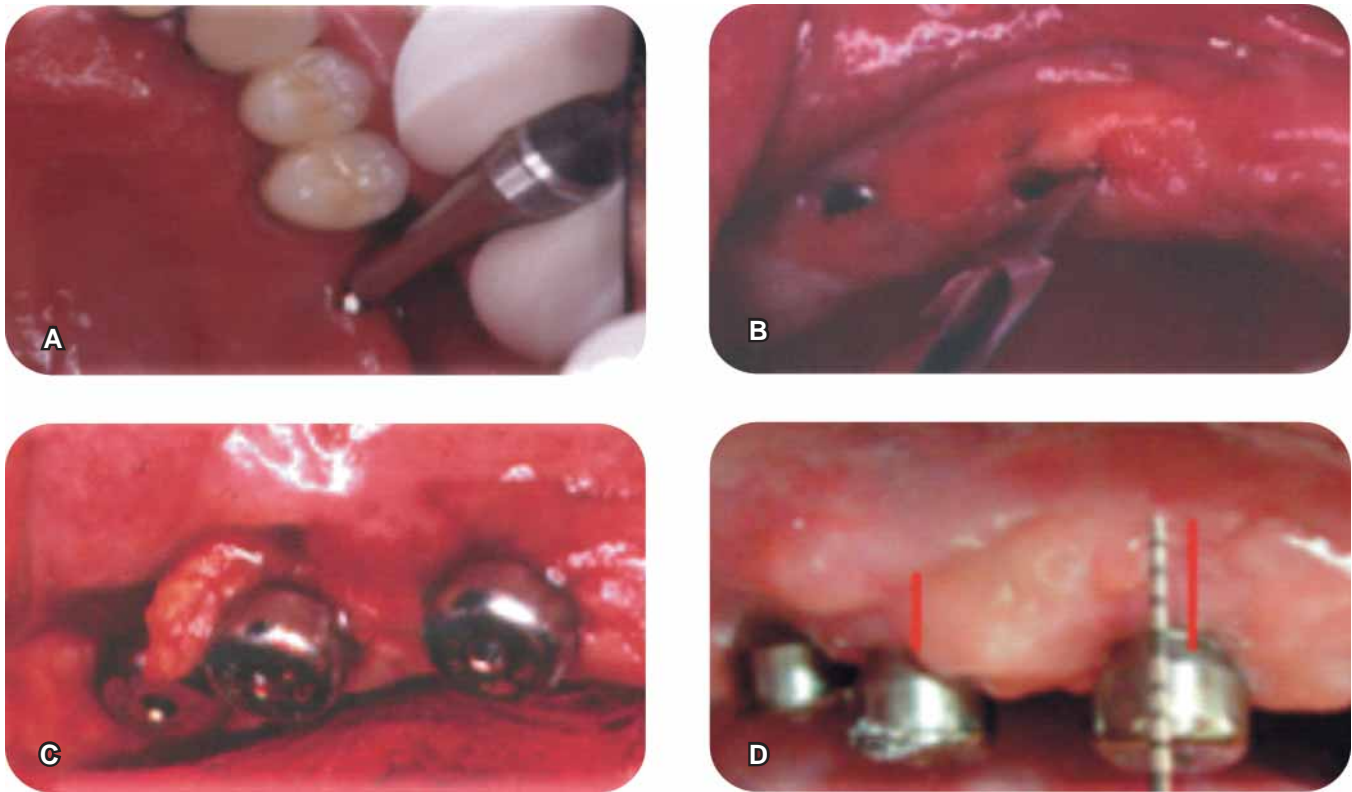


Figure 7. Uncovering of implants. **A)** Punch technique. **B)** Incision over implant lid. **C)** Connective tissue graft with envelope technique. **D)** Three months after connective tissue graft.

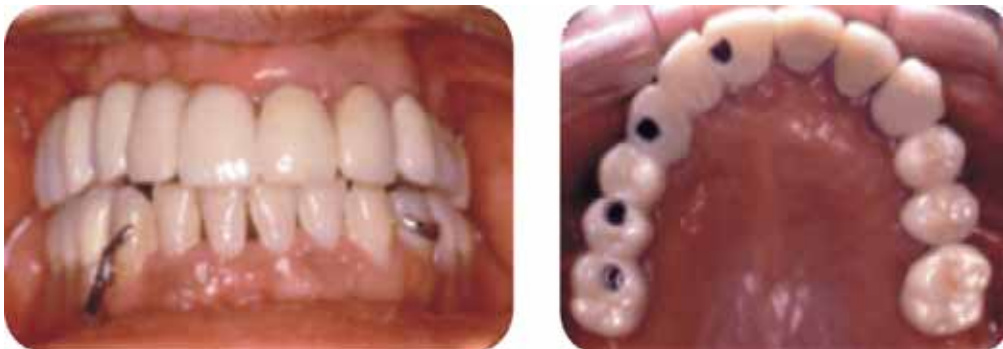

Figure 8. Final result pictures.

periodontal disease is suspected, since chronic inflammation of connective tissue can increase bone loss.³ Slow, forced extrusion is a non surgical treatment which facilitates tissue remodeling. Bone volume increase is related to the forces (tension) applied to periodontal tissue during orthodontic treatment, which induces new bone apposition due to the osteoblastic activity in the periodontal insertion system. There are clinical reports where bone development guided by slow, forced extrusion has been presented. When adhering to this technique, complex surgical procedures for bone regeneration can be avoided.^{3,20} In the present case, a force of 97-127 g was exerted for five months. With this procedure, 2 mm were decreased in probing depth; tooth number 11 vertical defect was also diminished, and bone crest height was preserved thus avoiding further resorption. Suggested speed to achieve this movement is 1 mm per month. A stabilization period must be incorporated, so as to allow newly-formed tissue to acquire needed mineralization characteristics.²¹ Smidt et al.²² mention a 2 mm gain with a 6 week forced extrusion procedure, using mini-implants as anchorage. Salam & Salama²³ mention that this technique requires 4-6 forced extrusion weeks, followed by 6 weeks for stabilization before removing the tooth and placing the implant. Mini-implant anchorage is an excellent alternative to achieve dental movements such as: mass retraction, molar migration towards mesial or distal direction, extrusion or intrusion, as well as correction of occlusal plane. Nevertheless, when following this procedure, certain indications must be observed: they must be placed in a safe area which will not damage anatomical structures, in an easily accessed location, preferably cortical bone, to establish primary stability; they must be placed over attached gingival tissue to avoid irritation and excessive movement and finally, they must be located in a place deemed favorable from the bio-mechanical point of view.⁴ In the present case, mini-implants did not lose stability and did not present infection, nevertheless they did cause chronic irritation in the mucosal lining, favoring thus fibrosis in the adjacent tissue which had to be surgically removed.

Pjetursson et al.,⁵ in a systematic review, mention that placement of bone-integrated implants in combination with sinus elevation is a predictable method presenting high survival rates (98.3% after three years) as well as low incidence of surgical complications. They used rough surfaced implants and covered the lateral window with a collagen membrane. In the present case, SLA surface implants were used (Sand Blasted, Large Grit Acid-Etched). These implants were found to be adequately integrated after six months of

being placed. Massimo et al.²⁴ reported a 95.98% survival rate in implants placed in the sinus using bone substitutes as grafting material. He mentions a survival rate in implant placement in one or two stages of 92.17% and 92.93 % respectively.

Steven et al.²⁵ conducted a study in 100 patients. This study reports certain anatomical conditions and surgical findings which could warrant the modification of the Tatum technique, as well as certain surgical complications. The main surgical complication mentioned by this author is a 14-56% rate for membrane perforation, when using rotating instruments. Vercellotti et al.¹¹ compare use of carbide and diamond burs with electrical hand-piece, they reach the conclusion that diamond burs, being less invasive, seem to enhance bone remodeling and healing in osteotomy and osteoplasty procedures. Nevertheless, there is no significant difference when using one or the other technique, since these same authors mention that membrane perforation generally takes place when it is dissected. It is important to mention that, at the moment of performing an osteotomy, proper refrigeration must be observed to avoid heating the tissues. In the present case, we used electrical hand-piece to exert better control during the osteotomy procedure, thus avoiding damage to the maxillary sinus membrane.

In the area of tooth number 26, the ridge measured 5mm in thickness and 8 mm in height. It was decided to place a 4.7 x 11mm implant, following Summers technique, to elevate 3 mm the floor of the maxillary sinus. This procedure was combined with bone expansion. The crest thickness was increased, and the bone characteristics at the site were modified. Summers technique is considered minimally invasive, since it rarely compromises blood supply to the area.^{12,13,26}

There is controversy with respect to the proper presence and thickness of keratinized tissue located around the implants. Adell et al.²⁷ acknowledges the fact that the role of soft tissues before implant placement is essential to preserve implant bone integration, avoid external forces and decrease infection risks. Warren et al.²⁸ informed that, in cases when dental plaque accumulates around the implant in areas lacking keratinized gingival tissue, gingival recession could occur as well as bone integration loss. Osteoblasts adhere to the rough surface of implants, in a similar fashion, there could be plaque accumulation which might elicit inflammatory response, and therefore, bone resorption around the implant. Abrahamson et al.²⁹ mention that sufficient tissue around the implant is required for the proper insertion of connective tissue. Appropriate biological thickness is as well required in order to avoid bone resorption. Lindhe³⁰

mentions the fact that mucosa found around the implant requires a minimum 2 mm thickness. Hertel et al.¹⁵ consider the minimum fact that, when keratinized gingival tissue width is equal or less than 1 mm, it is convenient to place a connective tissue graft in the area. In a study conducted by Kim et al.³¹ on assessment of tissue response in the presence of keratinized gums, with a 13 month follow-up, they conclude there are no statistically significant differences in the dental plaque index, inflammation and depth of pocket. Nevertheless, in the case of implants placed with deficient keratinized gums they found greater probability of gingival recession and loss of bone crest. The presence of keratinized gingival tissue helps implant maintenance and esthetics. Wennström et al.^{32,33} conducted a 5-10 years follow-up study with implants which possessed less than 2 mm keratinized gingival tissue. In this study he concludes that the width of keratinized gingival tissue, or the mobility found in soft tissues are not essential to the preservation of tissue surrounding the implant. Likewise, lining mucosa counts with the same ability as the masticatory mucosa to protect implant bone integrity, even after having accommodated the prosthesis. We beg to mention the fact that keratinized tissue is more resistant to physical, thermal and chemical trauma.

Implant located in zone 26 presented > 3 mm keratinized gingival tissue, therefore, the tissue-punch technique was used. Crest-incision technique was conducted in implants placed in zones 11, 13, 15, and 16, which counted with sufficient amount of keratinized gingival tissue. Implants placed in zones 15 and 13 required a connective tissue graft to increase keratinized gingival. This was due to the fact that those implants were surrounded by lining mucosa. Three months after placing the connective tissue graft, a keratinized tissue 1 mm increase was observed.

The use of zirconia (ZirkonZahn) enhanced esthetics as well as patient's plaque control.

The use of extremely hard materials for prosthetic rehabilitations is subject of controversy in cases where there is uncontrolled bruxism, or in antagonistic teeth of the same material, since, when directly transmitting forces to the bone there is a risk of eliciting bone resorption. In the present case, the lower jaw was rehabilitated with an acrylic-metal removable prosthesis. This decreased risks of this bone loss to a great extent.

The occlusal scheme used in this case was to leave occlusion to the first molar in both sides, so as not to leave unsupported distal extensions (cantilever). Other authors state that in the upper jaw cantilever can reach up to 8 mm.³⁴⁻³⁹

CONCLUSIONS

Multi-disciplinary treatment is important for the all-encompassing oral rehabilitation of patients. Several alternatives must be offered, and advantages and disadvantages insofar as results, treatment time and cost must be discussed. In the present case, with slow, forced extrusion treatment, simultaneous elevation of maxillary sinus floor with implant placement, and placement of fixed prosthesis supported by implants, masticatory function was restored and aesthetic results were achieved. Follow-up and maintenance phases are essential to sustain long term success in treatment.

REFERENCES

1. Seibert J, Lindhe J. *Esthetics in periodontal therapy*. In: Lindhe J, Karring T, Lang NP (eds). *Clinical Periodontology and Implant Dentistry*. 3a ed. Ed. Panamericana; 2001: 655-687.
2. Sanders, NL. Evidence-based care in orthodontics and periodontics: A review of the literature. *JADA* 1999; 130.
3. Vanarsdall R. Orthodontics and periodontal therapy. *Periodontology* 2000; 9 (1995): 132-149.
4. Lee JS, Kim JK, Par YC, Vanarsdall RL Jr. "Applications of Orthodontic Mini-implants". Ed. Quintessence Books; 2007: 1-11.
5. Pjetursson BE, Tan WC, Zwahlen M, Lang NP. A systematic review of the success of sinus floor elevation and survival of implants inserted in combination with sinus floor elevation. Part I: Lateral approach. *J Clin Periodontol* 2008; 35 (Suppl 8): 216-240.
6. Balshi T, Wolfinger G. Management of the posterior maxilla in the compromised patient: historical, current, a future perspectives. *Periodontology* 2000; 33: 67-81.
7. Van den Bergh, Bruggenkate, Tuinzing. Anatomical aspects of sinus floor elevations. *Clin Oral Implants Res* 2000; 11: 256-265.
8. Lundgren S et al. Sinus membrane elevation and simultaneous insertion of dental implants: a new surgical technique in maxillary sinus floor augmentation. *Periodontology* 2000 2008; 47: 193-205.
9. Schlee M, Steigmann M et al. Piezosurgery: basics and possibilities. *Implant Dent* 2006; 15: 334-340.
10. Wallace SS, Mazor Z et al. Schneiderian membrane perforation rate during sinus elevation using piezosurgery: Clinical results of 100 consecutive cases. *Int J Periodontics Restorative Dent* 2007; 27: 413-419.
11. Vercellotti T et al. Osseous response following resective therapy with piezosurgery. *Int J Periodontics Restorative Dent* 2005; 25: 543-549.
12. Summers RB. The osteotome technique: Part 3. Less invasive methods of elevating the sinus floor. *Compend Contin Educ Dent* 1994; 15: 698-708.
13. Nedhir R et al. Placement of tapered implants using an osteotome sinus floor elevation technique without bone grafting; 1-year results. *Int J Oral Maxillofac Implants* 2009; 24: 727-733.
14. Adell R, Lekholm U, Branemark PI. *Surgical Procedures*. In: Branemark PI, Zarb GA, Albrektsson, T. *Tissue-integrated prostheses. Osseointegration in Clinical Dentistry*. Chicago Quintessence, 1985.
15. Hertel RC, Blijdorp PA, Kalk W, Baker DL. Stage 2. Surgical techniques in endosseous implantation. *Int J Oral Maxillofac Implants* 1994; 9: 273-278.

16. Palacci P, Nowzari H. Soft tissue enhancement around dental implants. *Periodontology* 2000; 2008; 47: 113-132.
17. Raetzke PB. Covering localized an area of root exposure employing the "envelope" technique. *J Periodontol* 1985; 56 (7): 397-402.
18. Abd El Salam El Askary. "Soft tissue management". In: Abd El Salam El Askary. "Reconstructive aesthetic implant surgery". 2003, Ed. Blackwell Munksgaard.
19. Misch CE. *Contemporary implant dentistry*. Cap. 10. 3a ed. Ed Mosby; 2008: 178-199.
20. Erkut S et al. Forced eruption and implant treatment in posterior maxilla: A clinical report. *J Prosthet Dent* 2007; 70-4.
21. Rodríguez TM et al. "Fundamento estéticos para la rehabilitación de implantes oseointegrados". Ed. Artes Médicas Latinoamericana. 1ª. ed. 2006: 161.
22. Smidt A et al. Forced eruption of solitary nonrestorable tooth using mini-implants as anchorage: rationale and technique. *Int J Prosthodont* 2009; 22: 441-446.
23. Salama H, Salama M. The role of orthodontic extrusive remodeling in the enhancement of soft and hard tissue profiles prior to implant placement: a systematic approach to the management of extraction site defects. *Int J Periodont Rest Dent* 1993; 13: 313-333.
24. Del Fabbro M et al. Systematic review of survival rates for implants placed in the grafted maxillary sinus. *Int Periodontics Restorative Dent* 2004; 24: 565-577.
25. Zijderveld SA, Van den Berg JPA et al. Anatomical and surgical findings and complications in 100 consecutive maxillary sinus floor elevation procedures. *J Oral Maxillofac Surg* 2008; 66: 1426-1438.
26. Taeheon K. Sinus elevation using a staged osteotome technique for site development prior to implant placement in sites with less than 5mm of native bone: a case report. *Int J Periodontics Restorative Dent* 2008; 28: 73-81.
27. Adell R, Lekholm U, Rockler B, Branemark PI. A 15-year study of osseointegrated implants in the treatment of the edentulous jaw. *International Journal of Oral Surgery* 1981; 10: 387-416.
28. Warrar K, Buser D, Lang NP, Karring T. Plaque induced peri-implantitis in the presence or absence of keratinized mucosa. *Clin Oral Implants Res* 1995; 6: 131-138.
29. Abrahamsson I, Berglundh T, Wennström J, Lindhe J. The peri-implanhard and soft tissues at different implant systems. A comparative study in the dog. *Clin Oral Implants Res* 1996; 7(3): 212-9.
30. Berglundh T, Lindhe J. Dimension of the periimplant mucosa. Biological width revisited. *J Clin Periodontol* 1996; 23: 971-973.
31. Bum-Soo K, Young-Kyun K et al. Evaluation of peri-implant tissue response according to the presence of keratinized mucosa. *Oral Surg Oral Med Oral Pathol Oral Radiol Endod* 2009; 107: e24-e28.
32. Bengazi F, Wennström JL, Lekholm U. Recession of the soft tissue margin at oral implants. A 2-year longitudinal prospective study. *Clin Oral Implants Res* 1996; 7: 303-310.
33. Wennström JL, Bengazi F, Lekholm U. The influence of the masticatory mucosa on the peri-implant soft tissue condition. *Clin Oral Implants Res* 1994; 5: 1-8.
34. Becker et al. Implant retained fixed prosthesis: where and when. *J Prosthet Dent* 2000; 84: 432.
35. Eraslan O et al. Effects of design and material on stress distribution in fixed partial dentures a finite element analysis. *J Oral Rehabil* 2005; 32 (4): 273-278.
36. Romeed SA et al. Biomechanics of fixed partial dentures in shortened dental arch therapy. *J Prosthodont* 2004; 13 (2): 90-100.
37. Romeed SA et al. The mechanical behavior of fixed partial dentures in shortened dental arch therapy: a 2-D finite element analysis. *Eur J Prosthodont Restor Dent* 2004; 12 (1): 21-7.
38. Shillingburg y cols. *Fundamentos esenciales prótesis fija*. Quintessence España; 2000.
39. Tylman DS. *Theory and practice of crown a fixed partial prosthodontics (bridge)*. 6th. edition. C. V. Mosby, 1970. USA.

Mailing address:

Carolina Sánchez Zúñiga

E-mail: carozu_27@yahoo.com.mx