



Renal outcome in patients with complex anorectal malformations

Evolución renal en pacientes con malformaciones anorrectales complejas

Beatriz Fernández-Bautista,^{1*} María Fanjul,¹ Laura Burgos,¹ Esther Molina.¹

Abstract

Introduction: Anorectal malformations (ARMs) are one of the most frequent congenital malformations in pediatric surgery. Its estimated incidence ranges between 1 in 2000 and 1 in 5000 live newborns approximately. The aim of the work is to present the associated urinary anomalies and functional renal outcomes in patients with worse prognosis anorectal malformations treated in our department

Material and methods: A retrospective review of the patients operated at our center with complex anorectal malformations was performed, including urological abnormalities and long-term renal follow-up. Collected data included the type of urinary abnormality, classified as high or low, renal function (glomerular filtration rate and blood creatinine level), the presence of chronic kidney failure (CKD), the need for surgery to correct the urinary abnormality, the need for kidney transplantation and complications and long-term results.

Results: A total of 55 patients were included, 32 girls and 23 boys. Mean age at the time of corrective surgery for the anorectal malformation was 9 months (SD 2.18). The mean follow-up of the patients was 13 years (SD 7.01). Sixty-nine per cent of the patients presented some urological anomaly, being more frequent in the cloacal group. Renal structural abnormalities were found in 22 (40%) of 55 patients. They were identified in 11 (47%) cloacal patients, being the most frequent renal dysplasia (n=7; 32%), followed by position abnormalities in 3. Regarding the lower urinary tract anomalies, it was described in 32 (58%) patients. In the cloacal group, the incidence was 65%, being the most frequent vesicoureteral reflux (n = 14, 60%) as well as in the group of patients with a fistula to the prostatic urethra and in the group with exstrophies of the cloaca (n = 3, 42%). Regarding the rest of the lower urinary tract anomalies, the general incidence of anatomic bladder anomalies (bladder diverticulum, patent urachus) was 15%. As a pathology related to the upper urinary tract: primary obstructive megaureter 5%, ureterocele 1% and posterior urethral valves 1%.

Conclusions: Patients with complex anorectal malformations have a significant risk for renal impairment. Adequate screening, high level of suspicion, treatment and long term follow up of any associated urinary anomaly in patients with complex anorectal malformations is essential to preserve renal function and prevent CKD. Care by a multidisciplinary team and adequate transition to adulthood is essential to optimize the medical management of patients and long-term outcomes.

Keywords:

Anorectal malformation, urological anomalies, chronic kidney disease

Corresponding author:

*Beatriz Fernández Bautista. Calle O`Donnell, 48. Madrid. España
Email: bea.bfb89@gmail.com

Citation: Fernández-Bautista B., Fanjul M., Burgos L., Molina E. *Renal outcome in patients with complex anorectal malformations. Rev Mex Urol. 2022;82(3):pp 1-8*

¹Hospital Universitario Gregorio Marañón, Madrid, España.

Received: October 10, 2021
Accepted: February 11, 2022



Resumen

Introducción: Las malformaciones anorrectales son una de las malformaciones congénitas más frecuentes en cirugía pediátrica. Su incidencia estimada oscila entre 1 en 2000 y 1 en 5000 recién nacidos vivos aproximadamente. El objetivo del trabajo es presentar las anomalías urinarias asociadas y los resultados renales funcionales en pacientes con malformaciones anorrectales de peor pronóstico atendidos en nuestro servicio.

Material y métodos: Se realizó una revisión retrospectiva de los pacientes intervenidos en nuestro centro con malformaciones anorrectales complejas, incluyendo alteraciones urológicas y seguimiento renal a largo plazo. Los datos recogidos incluían el tipo de anomalía urinaria, clasificada como alta o baja, la función renal (tasa de filtración glomerular y nivel de creatinina en sangre), la presencia de insuficiencia renal crónica (ERC), la necesidad de cirugía para corregir la anomalía urinaria, la necesidad de trasplante renal y complicaciones y resultados a largo plazo.

Resultados: Se incluyeron un total de 55 pacientes, 32 niñas y 23 niños. La edad media en el momento de la cirugía fue de 9 meses (DE 2,18). El seguimiento medio de los pacientes fue de 13 años (DE 7,01). El 69% de los pacientes presentó alguna anomalía urológica, siendo más frecuente en el grupo cloacal. Se encontraron anomalías estructurales renales en 22 (40%) de 55 pacientes. Se identificaron en 11 (47%) pacientes cloacales, siendo la displasia renal la más frecuente (n=7; 32%), seguida de las anomalías de posición en 3. En cuanto a las anomalías del tracto urinario inferior, se describió en 32 (58%) pacientes. En el grupo cloacal la incidencia fue del 65%, siendo el reflujo vesicoureteral el más frecuente (n = 14, 60%) así como en el grupo de pacientes con fístula a la uretra prostática y en el grupo con extrofias de la cloaca (n = 3, 42%). Respecto al resto de anomalías del tracto urinario inferior, la incidencia general de anomalías anatómicas vesicales (divertículo vesical, uraco permeable) fue del 15%. Como patología relacionada con el tracto urinario superior: megauréter obstructivo primario 5%, ureterocele 1% y válvulas de uretra posterior 1%.

Conclusiones: Los pacientes con malformaciones anorrectales complejas tienen un riesgo importante de insuficiencia renal. El cribado adecuado, alto nivel de sospecha, tratamiento y seguimiento a largo plazo de cualquier anomalía urinaria asociada en pacientes con malformaciones anorrectales complejas es fundamental para preservar la función renal y prevenir la ERC. La atención por un equipo multidisciplinario y la transición adecuada a la edad adulta son fundamentales para optimizar el manejo médico de los pacientes y los resultados a largo plazo.

Palabras clave:

Malformación anorrectal, anomalías urológicas, enfermedad renal crónica

Introduction

Anorectal malformations (ARMs) are one of the most frequent congenital malformations in pediatric surgery. Its estimated incidence ranges between 1 in 2000 and 1 in 5000 live newborns approximately.⁽¹⁾

It has been described that between 49 and 93% of ARMs associate some type of congenital malformation.⁽²⁾ Overall, urinary tract abnormalities are the most frequent with an incidence from 28% to 50% depending on the series,⁽³⁾ including solitary kidney, ectopic and fused kidneys, renal dysplasia, hydronephrosis and vesicoureteral reflux.⁽⁴⁾ The risk of an associated urinary abnormality is higher in worse prognosis anorectal malformations.⁽⁵⁾ The actual incidence of end-stage renal failure in patients with ARM is unknown.⁽⁶⁾ This pathology represents an important factor in the contribution to morbidity and mortality in these patients.⁽⁷⁾

The aim of the work is to present the associated urinary anomalies and functional renal outcomes in patients with worse prognosis anorectal malformations treated in our department.

Material and methods

A retrospective review of the patients operated at our center with complex anorectal malformations was performed, including urological abnormalities and long-term renal follow-up.

All the patients studied had complex anorectal malformations. The following ARMs are included as complex types: **a.** Girls with cloaca, **b.** Boys with recto-prostatic fistula, **c.** Cloacal exstrophy, **d.** Patients with other complex combined malformations (“H” fis-

tula, genital duplication, bladder exstrophy + anorectal malformation with rectal fistula to prostatic urethra).

All patients were screened for urological malformations by ultrasound at presentation, and imaging and renal function tests (MRI, voiding cystography, nuclear renography, urodynamic studies and renal blood profile) were performed during follow-up according to their clinical course.

Collected data included the type of urinary abnormality, classified as high or low, renal function (glomerular filtration rate and blood creatinine level), the presence of chronic kidney failure (CKD), the need for surgery to correct the urinary abnormality, the need for kidney transplantation and complications and long-term results.

As for urological abnormalities, the presence of renal dysplasia, agenesis, ectopy, duplication, stenosis of the pyeloureteral junction or lower urinary tract abnormalities (bladder structural or functional alterations, vesicoureteral reflux, obstructive megaureter, posterior urethral valves or ureterocele) were recorded.

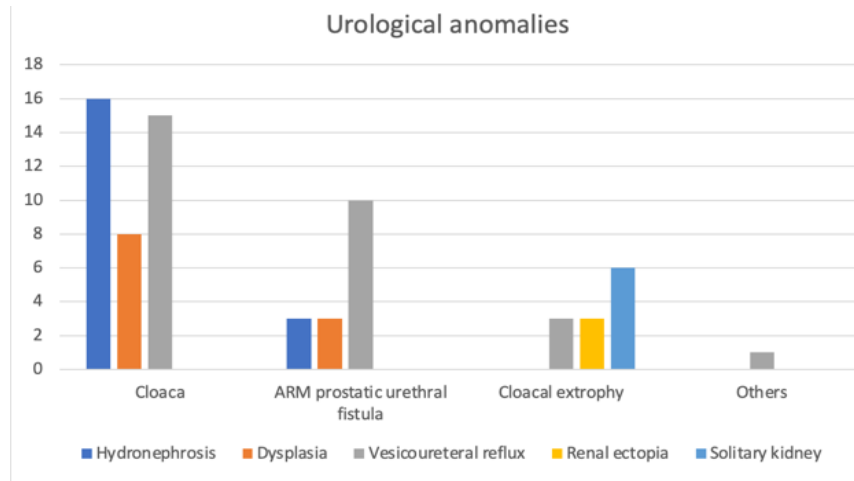
For the statistical study, the SPSS 27 system was used to examine differences between groups.

Results

A total of 55 patients were included, 32 girls and 23 boys. Mean age at the time of corrective surgery for the anorectal malformation was 9 months (SD 2.18). The mean follow-up of the patients was 13 years (SD 7.01).

Sixty-nine per cent of the patients presented some urological anomaly, being more frequent in the cloacal group (Figure 1).

Figure 1. Description of the most frequent urological anomalies in the different groups



Renal structural abnormalities were found in 22 (40%) of 55 patients. They were identified in 11 (47%) cloacal patients, being the most frequent renal dysplasia (n=7; 32%), followed by position abnormalities in 3 (2 horseshoe kidneys, 1 crossed renal ectopia), a duplicated excretory system in 3 and renal agenesis in 2. In the group of patients with rectal fistula to prostatic urethra there was one horseshoe kidney. In patients with cloacal exstrophy there were three pelvic kidneys and one of them horseshoe.

Regarding the lower urinary tract anomalies, it was described in 32 (58%) patients. In the cloacal group, the incidence was 65%, being the most frequent vesicoureteral reflux (n = 14, 60%) as well as in the group of patients with a fistula to the prostatic urethra and in the group with exstrophies of the cloaca (n=3, 42%).

Regarding the rest of the lower urinary tract anomalies, the general incidence of anatomic bladder anomalies (bladder diverticulum, patent urachus) was 15%. As a pathology related to the upper urinary tract: primary obstructive megaureter 5%, ureterocele 1% and posterior urethral valves 1%.

Some of the main characteristics by groups are reflected in Figure 2.

Figure 2. Summary results by groups

Groups	Estructural urological anomalies	Lower urinary tract anomalies	Urological intervention	Chronic kidney disease
Cloaca (n=23)	11 (47%)	15 (65%)	16 (69%)	6 (26%)
Recto- prostatic fistula (n=22)	7 (31%)	12 (54%)	12 (54%)	3 (13%)
Cloacal exstrophy (n=7)	4 (57%)	3 (42%)	4 (57%)	2 (28%)
Complex combined malformations (n=3)	0	2 (66%)	2 (66%)	0

As for patients who met criteria for VACTERL syndrome, we found 43% (n=10) of cloacae, 13% (n=3) of patients with fistula to the prostatic urethra, and 42% (n=3) of patients with cloacal exstrophy.

There were 18 patients (33%) with neurogenic bladder, of which 83% received some type of urological surgical intervention (5 endoscopic treatments for vesicoureteral reflux, 3 ureteral reimplantations, 4 enterocystoplasties, 5 continent catheterization mechanisms and 1 cervicourethral disconnection). Thanks to these procedures, intermittent catheterization, and the treatment of some of these patients with anticholinergics, the patients are now continent.

Of all patients, 61% required some type of urological surgery, being more frequent in the cloacal group. The most frequent urological surgery was endoscopic antireflux treatment, and 5 patients finally underwent ureteral reimplantation.

A total of 7 (12%) nephrectomies were performed. In the cloacal group there were 6 (27%) and in the group with fistulas to the prostatic urethra one (4%). Of the total of nephrectomized patients, 3 (43%) patients developed CKD.

Fifteen patients (27%) had a solitary kidney, either anatomically or functionally, six of which developed chronic kidney disease.

It was found that unlike nephrectomized patients, patients with renal agenesis did not develop chronic kidney disease

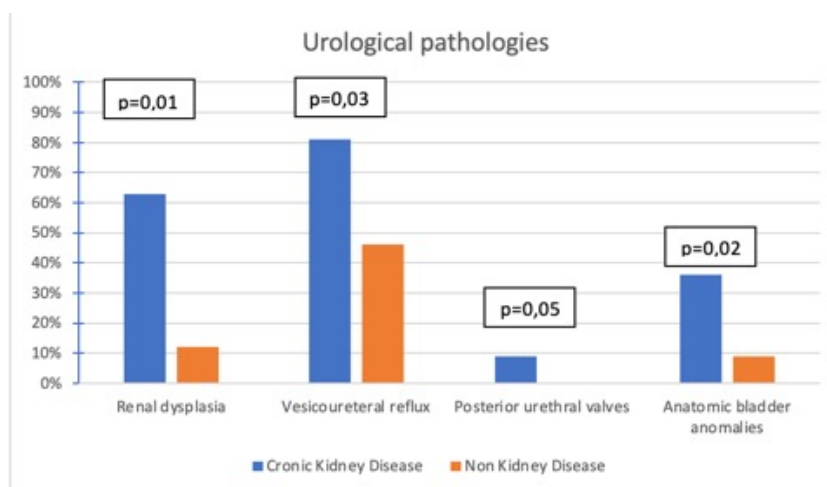
Of all patients, 21% had chronic kidney disease, considering glomerular filtration rate and serum creatinine values. Of the patients with chronic kidney disease, most had a G2 stage and only one patient (who had cloacal exstrophy) had a G5 stage and required kidney transplantation.

Of the patients who developed chronic kidney disease (predominantly in the cloacal group), the majority had vesicoureteral reflux followed by renal dysplasia.

Among the patients with neurogenic bladder, 47% developed chronic kidney disease, requiring a kidney transplant.

Statistically significant differences were found in relation to vesicoureteral reflux, 81% patients with chronic kidney disease presented it, compared to 46% of patients without ($p=0.03$) (Figure 3).

Figure 3. Urological pathologies associated with chronic kidney disease



It was shown that 63% of the patients with CKD had renal dysplasia ($n = 7$, $p = 0.001$) compared to 36% of those without renal function impairment.

Likewise, of these 7 patients with CKD and renal dysplasia, 6 of them had a neurogenic bladder.

In addition, no significant differences were found regarding the presence of spinal or lumbo-sacral abnormalities and the presence of any urological structural abnormality or the development of chronic kidney disease.

The relationship between congenital kidney damage and the presence of neurogenic bladder was analyzed. As results, it was found that 58% ($n=7$) of the patients with dysplasia presented neurogenic bladder. Of the patients with renal dysplasia, 16% ($n=1$) presented neurogenic bladder, as well as 40% of the patients with renal agenesis ($n=6$).

Discussion

Worse prognosis anorectal malformations are a type of complex anorectal malformation with a presentation of variable characteristics in terms of anatomy and a wide spectrum of severity.⁽⁸⁾ The diagnosis of these malformations is made based on a meticulous physical examination of the newborn.

Associated anomalies are very common in these patients and include, among others, urological, and vertebral / medullary, being more frequent in the cloacal group and cloacal extrophies.⁽⁹⁾

Overall, urinary tract abnormalities are the most frequent with an incidence from 28% to 50% depending on the series.⁽³⁾ This wide range is due to the fact that genital anomalies

as cryptorchidism are included in some studies. We did not include it in our analysis. Our high rate of associated urological anomalies found is due to the selection of patients, which excluded those anorectal malformations with better prognosis (perineal, vestibular and recto-bulbar fistula).

This pathology represents an important factor in the contribution to morbidity and mortality in these patients.⁽⁷⁾ The impairment of renal function can sometimes be preventable with an early diagnosis, an adequate treatment and a long-term follow up. Most of the urological abnormalities associated with complex ARMs can be detected with a neonatal ultrasound. Duci *et al.*⁽¹⁰⁾ evaluated the efficacy of the early detection and found that the screening program can diagnose 88% of urinary disorders. Goossens *et al.*⁽⁵⁾ in their evaluation of urological pathology screening methods in patients with ARM, concluded that an ultrasound of the urinary tract should be performed in all patients. All this information could help to select the cases that require closer work-up to optimize long-term follow-up. Furthermore, Duci also evaluated the efficacy of clinical follow-up, and their study suggests that monitoring can find 12% of the total.⁽¹⁰⁾ This emphasizes the need for appropriate long-term follow-up in these patients.

Renal function depends on a variety of factors, including bladder status, intrinsic abnormalities, and other associated abnormalities.^(4,11) There is not much information on kidney function results in patients with anorectal malformations and studies in this regard are scarce. The actual incidence of end-stage renal failure in patients with ARM is unknown.⁽⁶⁾ In our series, 21% of the patients with complex anorectal malformations had chronic kidney

disease, the most frequent cause being urinary tract infections secondary to vesicoureteral reflux. It is worth mentioning that of the patients with vesicoureteral reflux who developed chronic kidney disease, 89% had a neurogenic bladder.

These patients will require attention beyond the pediatric age and they will benefit from adequate participation in transition plans to adult care.⁽¹²⁾ It is crucial that the transition begins at an early age with regular and well-structured follow-up to reduce long-term morbidity. Urologic goals during the transition from childhood to adulthood continue to include preservation of kidney function and optimization of lower urinary tract function. Transition is intended to maximize quality of life and independence by ensuring appropriate uninterrupted care. Cooperation with a selected multidisciplinary team of pediatric and adult physicians and surgeons is required to prepare patients and families for an effective transition.⁽¹³⁾

In summary, neonatal evaluation of the upper and lower urinary tract, accompanied by prompt detection of abnormal anatomy and function of the urinary system, is essential in every patient diagnosed with a complex ARM to minimize the impact of any urological condition on their renal function and overall health. An adequate screening, with early recognition of existing urological abnormalities, is crucial to allow optimal and appropriate medical and surgical treatment, continued follow-up during childhood and a controlled transition to adulthood, reducing the morbidity of these patients. A late or failed diagnosis can have adverse consequences for the patient.

Conclusions

Patients with complex anorectal malformations have a significant risk for renal impairment. Adequate screening, high level of suspicion, treatment and long term follow up of any associated urinary anomaly in patients with complex anorectal malformations is essential to preserve renal function and prevent CKD. Care by a multidisciplinary team and adequate transition to adulthood is essential to optimize the medical management of patients and long-term outcomes.

Financing

No sponsorship was received to write this article.

Conflict of interest

The authors declare no conflicts of interest.

References

1. Nah SA, Ong CCP, Lakshmi NK, Yap T-L, Jacobsen AS, Low Y. Anomalies associated with anorectal malformations according to the Krickenbeck anatomic classification. *J Pediatr Surg.* 2012 Dec;47(12):2273–8. doi: <https://doi.org/10.1016/j.jpedsurg.2012.09.017>
2. Stoll C, Dott B, Alembik Y, Roth M-P. Associated anomalies in cases with anorectal anomalies. *Am J Med Genet A.* 2018 Dec;176(12):2646–60. doi: <https://doi.org/10.1002/ajmg.a.40530>
3. Islam MN, Hasina K, Reza MS, Hasanuzzaman SM, Akter T, Talukder SA. Urinary tract anomalies in patients with anorectal

- malformation. *Mymensingh Med J.* 2015 Apr;24(2):352–5.
4. **Caldwell BT, Wilcox DT.** Long-term urological outcomes in cloacal anomalies. *Semin Pediatr Surg.* 2016 Apr;25(2):108–11. doi: <https://doi.org/10.1053/j.sempedsurg.2015.11.010>
 5. **Goossens WJH, de Blaauw I, Wijnen MH, de Gier RPE, Kortmann B, Feitz WFJ.** Urological anomalies in anorectal malformations in The Netherlands: effects of screening all patients on long-term outcome. *Pediatr Surg Int.* 2011;27(10):1091–7. doi: <https://doi.org/10.1007/s00383-011-2959-4>
 6. **Ganesan I, Rajah S.** Urological anomalies and chronic kidney disease in children with anorectal malformations. *Pediatr Nephrol.* 2012 Jul;27(7):1125–30. doi: <https://doi.org/10.1007/s00467-012-2128-6>
 7. **Clapuyt P, Claus D, Otte JB, Wese F.** [Anomalies of the urogenital system associated with anorectal malformations. Apropos of 99 cases]. *Acta Urol Belg.* 1989;57(2):675–80.
 8. **Wood RJ, Levitt MA.** Anorectal Malformations. *Clin Colon Rectal Surg.* 2018 Mar;31(2):61–70. doi: <https://doi.org/10.1055/s-0037-1609020>
 9. **Stoll C, Alembik Y, Dott B, Roth MP.** Associated malformations in patients with anorectal anomalies. *Eur J Med Genet.* 2007 Aug;50(4):281–90. doi: <https://doi.org/10.1016/j.ejmg.2007.04.002>
 10. **Duci M, Midrio P, Castagnetti M, Gamba P, Faggin R, Fascetti-Leon F.** Urinary Tract Anomalies in Patients With Anorectal Malformations: The Role of Screening and Clinical Follow-Up. *Urology.* 2020 Sep;143:216–20. doi: <https://doi.org/10.1016/j.urology.2020.05.052>
 11. **Warne SA, Wilcox DT, Ledermann SE, Ransley PG.** Renal Outcome in Patients With Cloaca. *J Urol.* 2002 Jun;167(6):2548–51. doi: [https://doi.org/10.1016/S0022-5347\(05\)65034-3](https://doi.org/10.1016/S0022-5347(05)65034-3)
 12. **Cairo SB, Gasior A, Rollins MD, Rothstein DH,** Delivery of Surgical Care Committee of the American Academy of Pediatrics Section on Surgery. Challenges in Transition of Care for Patients With Anorectal Malformations: A Systematic Review and Recommendations for Comprehensive Care. *Dis Colon Rectum.* 2018 Mar;61(3):390–9. doi: <https://doi.org/10.1097/dcr.0000000000001033>
 13. **Giuliani S, Grano C, Aminoff D, Schwarzer N, Van De Vorle M, Cretolle C, et al.** Transition of care in patients with anorectal malformations: Consensus by the ARM-net consortium. *J Pediatr Surg.* 2017 Nov;52(11):1866–72. doi: <https://doi.org/10.1016/j.jpedsurg.2017.06.008>