

Early T-wave inversion in anterior leads predict patency of the anterior descending artery in ST-segment elevation myocardial infarction

La onda T invertida temprana en derivaciones anteriores predice permeabilidad de la arteria descendente anterior en infarto agudo de miocardio con elevación del segmento ST

Ernesto Alexis Barrera-Oranday,* Juan Manuel Cortés de la Torre,*
Juan Manuel Rodríguez Castillo,* Alexandra Arias-Mendoza*

Key words:

ST-segment elevation myocardial infarction, auto-reperfusion, T-wave inversion.

Palabras clave:

Infarto agudo de miocardio con elevación del ST, autorreperusión, onda T invertida.

ABSTRACT

Introduction: T-wave inversion has always been considered as a natural progression sign of the non-perfused myocardial infarction, however it is also seen after early successful reperfusion via fibrinolysis or primary angioplasty; its role in predicting auto-reperfusion has not been established. **Objective:** Assess the patency of the infarct-related artery (IRA) in patients presenting with early (< 3 hours of symptoms onset) T-wave inversion (TWI) in leads with ST-segment elevation (STE) myocardial infarction (STEMI). **Methods:** We retrospectively analyzed 432 patients admitted at the emergency department of the National Cardiology Institute in Mexico City with a diagnosis of STEMI who arrived within three hours of symptoms onset and underwent primary percutaneous coronary intervention (p-PCI) from October 2005 to November 2015. Clinical data, electrocardiogram (ECG) and angiographic data were reviewed. The subjects were divided in two groups: those with TWI and those with positive T waves (PTW). **Results:** 386 (89.3%) patients presented with PTW and 46 (10.6%) with TWI. The presence of early TWI in anterior leads predicted patency of the anterior descending artery (LAD) (18 [69.2%] vs 41 [24%]; $p < 0.001$) but not in other arteries. **Conclusions:** The presence of early TWI in anterior leads with STE is associated with patency of the LAD. This relationship was not found in other infarct-related arteries.

RESUMEN

Introducción: La onda T invertida siempre se ha considerado como progresión natural de un infarto de miocardio no reperfundido, sin embargo, también se puede observar posterior a fibrinólisis o angioplastia primaria exitosas, su rol en predecir autorreperusión no ha sido establecido. **Objetivo:** Valorar la permeabilidad de la arteria culpable del infarto (ACI) en pacientes que se presentan con onda T invertida (OTI) temprana (menos de tres horas de inicio de síntomas) en derivaciones con elevación del segmento ST (IAMCEST). **Métodos:** Se analizaron 432 pacientes de forma retrospectiva que fueron admitidos al Servicio de Urgencias del Instituto Nacional de Cardiología en la Ciudad de México con diagnóstico de IAMCEST dentro de las primeras tres horas de inicio de los síntomas y que fueron llevados a angioplastia primaria de octubre de 2005 a noviembre de 2015. Se revisaron datos clínicos, electrocardiogramas y angiografías coronarias. Los sujetos fueron divididos en dos grupos: aquéllos con OTI y aquéllos con onda T positiva (OTP). **Resultados:** Se presentaron 386 (89.3%) pacientes con OTP y 46 (10.6%) con OTI. La presencia de OTI temprana en derivaciones anteriores predijo permeabilidad de la descendente anterior (DA) (18 [69.2%] vs 41 [24%]; $p < 0.001$) pero no en las otras arterias. **Conclusión:** La presencia de OTI tempranas en derivaciones anteriores con elevación del segmento ST se asocia a permeabilidad de la DA. Este hallazgo no fue encontrado en otras arterias culpables de infarto.

* Coronary Unit,
National Institute of
Cardiology, Mexico city,
Mexico.

Received:
15/03/2018
Accepted:
10/07/2018

INTRODUCTION

The main objective in the treatment of ST segment elevation (STE) myocardial infarction (STEMI) is the prompt restoration of coronary flow and microvasculature.¹ The presence of T-wave inversion (TWI) in leads with ST-segment elevation (STE) is classically considered as the natural progression of non-perfused STEMI.² The presence of TWI after reperfusion therapy has been considered as a sign of successful therapy.^{1,3-5} The presence of early TWI (before the reperfusion strategy) has not been well established. Previous studies have reported that the presence of an early TWI in leads with STE before primary percutaneous coronary intervention (pPCI) is associated with a patent infarct-related artery (IRA).^{6,7} We analyzed the prevalence of early TWI in leads with STE in a group of patients admitted with a diagnosis of STEMI who arrived within three hours of symptoms onset and underwent pPCI.

METHODS

Study population

We did a retrospective cohort study, with 622 consecutive patients admitted at the emergency department of the National Cardiology Institute in Mexico City with a diagnosis of STEMI who

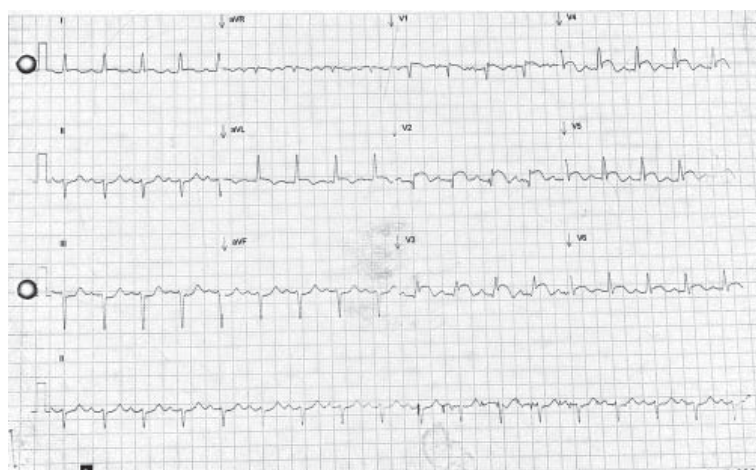

Figure 1: Electrocardiogram showing ST-segment elevation in anterior leads with T-wave inversion.

arrived within three hours of symptoms onset and underwent primary percutaneous coronary intervention (p-PCI) from October 2005 to November 2015. We excluded 190 patients (161 for having an incomplete file, 28 for having left or right bundle branch block and one for being in a idioventricular rhythm).

Electrocardiographic analysis

As described elsewhere^{6,7} patients were divided into two groups: those with TWI (≥ 0.5 mm below the isoelectric line) in two or more adjacent leads with STE (*Figure 1*) and those with positive T waves (PTW) in two or more adjacent leads with STE (*Figure 2*). If a patient had a biphasic T wave it was considered negative if the terminal portion was ≥ 0.5 mm below the isoelectric line.

Angiographic analysis

Patients were taken to the catheterization laboratory as fast as possible (all of them had a time of onset of symptoms-angiogram of less than 12 hours), and were divided in two groups: non patent IRA, with a TIMI flow grade 0-1; and patent IRA with a TIMI flow 2-3. This analysis was made by blinded expert in interventional cardiology.

Statistical analysis

Categorical variables were compared using χ^2 and continuous variables with Wilcoxon rank sum test. Sensibility, Specificity, positive predictive value and negative predictive value were obtained using a 2×2 table including true positives, true negatives, false positives and false negatives. The software used was SPSS version 15.0 (SPSS, Inc, Chicago, Illinois) a $p \leq 0.05$ was considered statistically significant.

RESULTS

432 consecutive patients who presented with STEMI and underwent pPCI were included in the study. Baseline characteristics of the two groups are presented in *Table 1*. 386 (89.3%) patients presented with PTW and 46 (10.6%) with TWI.

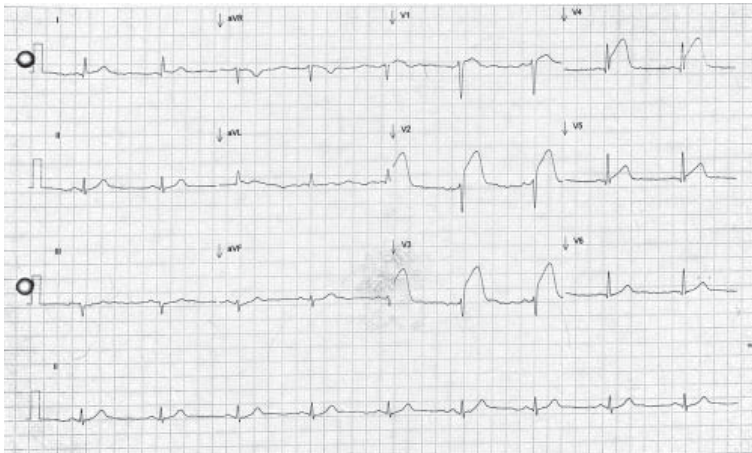


Figure 2: Electrocardiogram showing ST-segment elevation in anterior leads with positive T-wave.

Baseline characteristics including gender, age, dyslipidemia, hypertension, diabetes mellitus, previous PCI, previous use of aspirin and statin, stable angina and death were comparable between the groups. There were more current smokers in the PTW group than in the TWI group (19.6% vs 37.3% $p = 0.017$), there were more patients with previous CABG (8.7% vs 1.8% $p = 0.005$) and more patients with diminished creatinine clearance, defined as a creatinine clearance less than 60 mL/min using the MDRD formula (32.6% vs 17.9% $p = 0.017$) in the TWI group than in the PTW. We found more patent IRA in the TWI group than in the PTW group (32.6% vs 17.9% $p = 0.017$). The most frequent IRA was the left anterior descending (LAD) accounting for 198 (45.8%)

Table 1: Baseline characteristics.

Characteristics	T-wave inversion (n = 46)	Positive T-wave (n = 386)	p-value
Age \pm SD (years)	61.5 \pm 11.8	58.2 \pm 11.7	0.078
Males n (%)	38 (82.6)	343 (88.9)	0.226
Smokers n (%)	9 (19.6)	144 (37.3)	0.017
Dyslipidemia n (%)	22 (47.8)	149 (38.6)	0.227
Hypertension n (%)	24 (52.2)	202 (52.3)	0.984
Diabetes mellitus n (%)	17 (37.0)	102 (26.4)	0.131
Previous infarction n (%)	16 (34.8)	88 (22.8)	0.072
Previous PCI n (%)	10 (21.7)	55 (14.2)	0.179
Previous CABG n (%)	4 (8.7)	7 (1.8)	0.005
Previous use of aspirin n (%)	17 (37.0)	98 (25.4)	0.093
Previous use of statin n (%)	12 (26.1)	78 (20.2)	0.353
Previous stable angina n (%)	11 (23.9)	59 (15.3)	0.133
Creatinine clearance < 60 mL/min n (%)	15 (32.6)	69 (17.9)	0.017
Killip-Kimball			0.863
I	38 (82.6)	318 (83.0)	
II	6 (13.0)	56 (14.6)	
III	1 (2.2)	4 (1.0)	
IV	1 (2.2)	5 (1.3)	
TIMI risk			0.133
0-4	35 (76.1)	327 (84.7)	
≥ 5	11 (23.9)	59 (15.3)	
TIMI flow			0.006
0	21 (45.7)	255 (66.8)	
1	4 (8.7)	42 (11.0)	
2	15 (32.6)	56 (14.7)	
3	6 (13.0)	29 (7.6)	
Death	4 (8.7)	17 (4.4)	0.260

patients in the overall sample and 26 (56.5%) in patients with TWI (Table 2).

The presence of early TWI in anterior leads were associated with patency of the anterior descending artery (LAD) (18 [69.2%] vs 41 [24%]; $p < 0.001$) but not in other arteries (Table 3). Thus, the sensitivity of TWI to predict spontaneous reperfusion in anterior STEMI was 30.5%, specificity was 94.2%, positive predictive value was 69.2% and negative predictive value was 76.1%.

DISCUSSION

The current AHA and ESC guidelines recommend early reperfusion therapy (less than 12 hours from symptom onset) in patients presenting with STEMI.^{1,8} The electrocardiographic evolution of a non-treated STEMI includes apparition of Q-waves and T-wave inversion.⁹ The reason we excluded the patients who presented with more than three hours of symptom onset is that the TWI may be due to the normal progression of a non-reperfused STEMI.

In the context of reperfusion (pPCI or thrombolysis) TWI has been shown to predict a successful reperfusion.^{3-5,10} Theoretically the same phenomena could be seen in patients with spontaneous reperfusion. Alsaab and Hira showed that early TWI in patients with anterior STEMI predicted a patent IRA. Our analysis showed similar results. The presence of a patent IRA at the moment of the angiogram is correlated with less mortality, heart failure, need for intubation and less length of stay.^{11,12}

There were little differences between the two groups, there were more current smokers with a PTW than TWI. Smoking has been associated with endothelial dysfunction and coronary artery disease.¹³ Several endothelial dysfunction predictors of a non-patent IRA have been described such as elevated uric acid levels, neutrophil/lymphocyte index,¹⁴ platelet/lymphocyte,¹⁵ and low levels of endotelin-1;¹⁶ also, patients presenting with spontaneous reperfusion have less oxidative stress.¹⁷ All of this evidence may explain the difference between both groups in our study.

There were more patients with renal failure and previous CABG in the TWI group, which may be due to the fact that these patients already had TWI prior to the STEMI event because of pre-existing ischemia.

A hypothesis of why this novel electrocardiographical sign is only present in the LAD-related STEMI is because the lateral and inferior infarcts have more collateral circulation from the LAD, not the other way round when this artery is occluded; the LAD is the artery that supplies more irrigation to the left ventricular mass, which may explain more ECG changes when more ventricular mass is involved. Other possible hypothesis includes preconditioning because a occlusion-recanalization phenomena.

Limitations

The limitations in our study are its retrospective, one-center design; the vast majority of the patients didn't have a previous ECG for comparisons; we measured TIMI flow grade, however, It has been shown that the TIMI myocardial blush grade is a more sensitive predictor of outcomes. It will be important to make a prospective study with echocardiographic studies, blush grade and grade of collaterals and see the long-term prognosis of this presentation.

CONCLUSIONS

The presence of early T-wave inversion in anterior leads with ST-segment elevation is associated with patency of the left anterior descending artery. This relationship was not found in other infarct-related arteries.

Table 2: Infarct-related artery and the presence of TWI and PTW.

Infarct-related artery $p = 0.28$ for both groups	T-wave inversion (n = 46)	Positive T-wave (n = 386)
Anterior descending n (%)	26 (56.5)	172 (44.6)
Left circumflex n (%)	1 (2.2)	41 (10.6)
Right coronary n (%)	17 (37.0)	151 (39.1)
Diagonal n (%)	0 (0.0)	6 (1.6)
Obtuse marginal n (%)	0 (0.0)	9 (2.3)
Posterolateral n (%)	0 (0.0)	1 (0.3)
Posterior descending n (%)	1 (2.2)	2 (0.5)
Venous bypass n (%)	1 (2.2)	2 (0.5)
Ramus intermedius n (%)	0 (0.0)	2 (0.5)

Table 3: Infarct-related artery and patency.

Infarct-related artery	TIMI flow	TWI (n = 46)	PTW (n = 386)	p-value
LAD n (%)	0	6 (23.1)	109 (63.3)	< 0.001
	1	2 (7.7)	22 (12.7)	
	2	13 (50.0)	25 (14.5)	
	3	5 (19.2)	16 (9.3)	
Left circumflex n (%)	0	1 (100.0)	23 (56.1)	0.857
	1	0 (0.0)	6 (14.6)	
	2	0 (0.0)	8 (19.5)	
	3	0 (0.0)	4 (9.8)	
Right coronary n (%)	0	13 (76.5)	108 (73.0)	0.648
	1	2 (11.8)	10 (6.8)	
	2	2 (11.8)	21 (14.2)	
	3	0 (0.0)	9 (6.1)	
Diagonal n (%)	0	0 (0.0)	5 (83.3)	NV
	1	0 (0.0)	1 (16.7)	
	2	0 (0.0)	0 (0.0)	
	3	0 (0.0)	0 (0.0)	
Obtuse marginal n (%)	0	0 (0.0)	5 (55.6)	NV
	1	0 (0.0)	3 (33.3)	
	2	0 (0.0)	1 (11.1)	
	3	0 (0.0)	0 (0.0)	
Posterolateral n (%)	0	0 (0.0)	1 (100.0)	NV
	1	0 (0.0)	0 (0.0)	
	2	0 (0.0)	0 (0.0)	
	3	0 (0.0)	0 (0.0)	
Posterior descending n (%)	0	1 (100.0)	1 (50.0)	0.386
	1	0 (0.0)	0 (0.0)	
	2	0 (0.0)	1 (50.0)	
	3	0 (0.0)	0 (0.0)	
Venous bypass n (%)	0	0 (0.0)	2 (100.0)	0.083
	1	0 (0.0)	0 (0.0)	
	2	0 (0.0)	0 (0.0)	
	3	1 (100.0)	0 (0.0)	
Ramus intermedius n (%)	0	0 (0.0)	2 (100.0)	NV
	1	0 (0.0)	0 (0.0)	
	2	0 (0.0)	0 (0.0)	
	3	0 (0.0)	0 (0.0)	

NV = not valid.

www.medigraphic.org.mx

REFERENCES

- American College of Emergency Physicians; Society for Cardiovascular Angiography and Interventions, O'Gara PT, Kushner FG, Ascheim DD, Casey DE Jr et al. 2013 ACCF/AHA guideline for the management of ST-elevation myocardial infarction: a report of the American College of Cardiology Foundation/American Heart Association Task Force on Practice Guidelines. *J Am Coll Cardiol.* 2013; 61 (4): e78-e140.
- Nable JV, Brady W. The evolution of electrocardiographic changes in ST-segment elevation myocardial infarction. *Am J Emerg Med.* 2009; 27 (6): 734-746.
- Matetzky S, Barabash GI, Shahar A, Rabinowitz B, Rath S, Zahav YH et al. Early T wave inversion after thrombolytic therapy predicts better coronary

- perfusion: clinical and angiographic study. *J Am Coll Cardiol.* 1994; 24 (2): 378-383.
4. Corbalán R, Prieto JC, Chavez E, Nazzari C, Cumsille F, Krucoff M. Bedside markers of coronary artery patency and short-term prognosis of patients with acute myocardial infarction and thrombolysis. *Am Heart J.* 1999; 138 (3 Pt 1): 533-539.
 5. Doevendans PA, Gorgels AP, van der Zee R, Partouns J, Bär FW, Wellens HJ. Electrocardiographic diagnosis of reperfusion during thrombolytic therapy in acute myocardial infarction. *Am J Cardiol.* 1995; 75 (17): 1206-1210.
 6. Alsaab A, Hira RS, Alam M, Elayda M, Wilson JM, Birnbaum Y. Usefulness of T wave inversion in leads with ST elevation on the presenting electrocardiogram to predict spontaneous reperfusion in patients with anterior ST elevation acute myocardial infarction. *Am J Cardiol.* 2014; 113 (2): 270-274.
 7. Hira RS, Moore C, Huang HD, Wilson JM, Birnbaum Y. T wave inversions in leads with ST elevations in patients with acute anterior ST elevation myocardial infarction is associated with patency of the infarct related artery. *J Electrocardiol.* 2014; 47 (4): 472-477.
 8. Task Force on the management of ST-segment elevation acute myocardial infarction of the European Society of Cardiology (ESC), Steg PG, James SK, Atar D, Badano LP, Blömsstrom-Lundqvist C et al. ESC Guidelines for the management of acute myocardial infarction in patients presenting with ST-segment elevation. *Eur Heart J.* 2012; 33 (20): 2569-2619.
 9. Eskola MJ, Holmvang L, Nikus KC, Sclarovsky S, Tilsted HH, Huhtala H et al. The electrocardiographic window of opportunity to treat vs. the different evolving stages of ST-elevation myocardial infarction: correlation with therapeutic approach, coronary anatomy, and outcome in the DANAMI-2 trial. *Eur Heart J.* 2007; 28 (24): 2985-2991.
 10. Wehrens XH, Doevendans PA, Ophuis TJ, Wellens HJ. A comparison of electrocardiographic changes during reperfusion of acute myocardial infarction by thrombolysis or percutaneous transluminal coronary angioplasty. *Am Heart J.* 2000; 139 (3): 430-436.
 11. Stone GW, Cox D, Garcia E, Brodie BR, Morice MC, Griffin J et al. Normal flow (TIMI-3) before mechanical reperfusion therapy is an independent determinant of survival in acute myocardial infarction: analysis from the primary angioplasty in myocardial infarction trials. *Circulation.* 2001; 104 (6): 636-641.
 12. Ernst N, Zijlstra F, de Boer MJ, Dambrink JH, Gosselink AT, Henriques JP et al. The importance of patency of the infarct-related artery in treatment of patients with acute myocardial infarction. *Neth Heart J.* 2003; 11 (1): 11-14.
 13. Messner B, Bernhard D. Smoking and cardiovascular disease: mechanisms of endothelial dysfunction and early atherogenesis. *Arterioscler Thromb Vasc Biol.* 2014; 34 (3): 509-515.
 14. Sahin DY, Gür M, Elbasan Z, Yıldız A, Kaya Z, İçen YK et al. Predictors of preinterventional patency of infarct-related artery in patients with ST-segment elevation myocardial infarction: Importance of neutrophil to lymphocyte ratio and uric acid level. *Exp Clin Cardiol.* 2013; 18 (2): e77-e81.
 15. Acet H, Ertaş F, Akıl MA, Özyurtlu F, Yıldız A, Polat N et al. Novel predictors of infarct-related artery patency for ST-segment elevation myocardial infarction: Platelet-to-lymphocyte ratio, uric acid, and neutrophil-to-lymphocyte ratio. *Anatol J Cardiol.* 2015; 15 (8): 648-656.
 16. Kilickesmez KO, Bingöl G, Bulut L, Sinan UY, Abacı O, Ersanli M et al. Relationship between serum endothelin-1 level and spontaneous reperfusion in patients with acute myocardial infarction. *Coron Artery Dis.* 2015; 26 (1): 37-41.
 17. Börekçi A, Gür M, Türkoğlu C, Selek Ş, Baykan AO, Şeker T et al. Oxidative stress and spontaneous reperfusion of infarct-related artery in patients with ST-segment elevation myocardial infarction. *Clin Appl Thromb Hemost.* 2016; 22 (2): 171-177.

Correspondence to:

Ernesto Alexis Barrera Oranday
Paseo de Los Olivos Núm. 3732,
Col. Residencial del Paseo, 64920,
Monterrey, Nuevo León, México.
Telephone: (81) 83579406 / 0458110805366
E-mail: alexisbarrerao@gmail.com