

Acute myocardial infarction due to coronary embolism in atrial fibrillation: case presentation and systematic review

Infarto agudo de miocardio debido a embolia coronaria en fibrilación auricular: presentación de caso y revisión sistemática

Juan Carlos Díaz,* Danilo Weir,** William Uribe,*** Julián Aristizábal,****
Jorge Velásquez,**** Jorge Marin,**** Mauricio Duque*****

Key words:

Acute myocardial infarction, atrial fibrillation, coagulation, coronary embolism.

Palabras clave:

Infarto agudo de miocardio, fibrilación auricular, coagulación, embolia coronaria.

* Cardiology and Electrophysiology. CES Cardiología. Clínica CES, Medellín.

** Medical Student. Fundación Universitaria San Martín, Sabaneta.

*** Cardiology and Electrophysiology. CES Cardiología.

Electrophysiology chief CES Cardiología and Centros Especializados de San Vicente

Fundación, Medellín and Rionegro.

**** Cardiology and Electrophysiology, CES Cardiología.

***** Cardiology and Electrophysiology, CES Cardiología. Cardiology chief, CES Cardiología.

Received:
01/06/2016

Accepted:
04/11/2016

ABSTRACT

Atrial fibrillation is the most common sustained arrhythmia in the general population, responsible for significant morbidity and mortality due to an increased risk of systemic embolism. The anatomic and hemodynamic characteristics of the cardiovascular system direct most emboli towards the central nervous system or the peripheral circulation, being coronary embolism an uncommon event. This has led to a paucity in the available medical literature regarding the importance of atrial fibrillation as a cause of acute myocardial infarction and the treatment these patients should be offered, with most of the evidence arising from case reports and small case series. A case of acute myocardial infarction associated with coronary embolism in a patient with new onset atrial fibrillation who was successfully treated with thrombus aspiration is presented, followed by a systematic review of the topic. The objective of this review is to establish the clinical characteristics of patients with coronary embolism due to atrial fibrillation and determine the best treatment options based on the available evidence.

RESUMEN

La fibrilación auricular es la arritmia sostenida más común en la población general, responsable de una gran morbilidad y mortalidad debido a un mayor riesgo de embolia sistémica. Las características hemodinámicas y anatómicas del sistema cardiovascular conducen directamente la mayoría de los émbolos hacia el sistema nervioso central o a la circulación periférica, siendo la embolia coronaria infrecuente. Esto ha llevado a una escasez en la literatura médica sobre la importancia de la fibrilación auricular como causa de infarto agudo de miocardio y del tratamiento que debe ser ofrecido a estos pacientes, con la mayoría de las pruebas derivadas de informes de casos y series de casos pequeñas. Un caso de infarto agudo de miocardio asociado con embolia coronaria en un paciente con fibrilación auricular de nueva aparición que fue tratada exitosamente con tromboaspiración es presentado, seguido de una revisión sistemática del tema. El objetivo de esta revisión es determinar las características clínicas de los pacientes con embolia coronaria debido a fibrilación auricular y determinar las mejores opciones de tratamiento basadas en la evidencia disponible.

INTRODUCTION

Atrial fibrillation (AF) is the most common sustained arrhythmia worldwide, being the main reason for arrhythmia related hospitalization; AF is also associated with a significant increase in mortality.¹ Furthermore, it is an important cause of cerebral embolism, with five-fold increase in the risk of ischemic

stroke, being responsible for about 1 of every 5 ischemic strokes.¹⁻⁴ Management is based on controlling underlying diseases which can trigger or perpetuate the arrhythmia and defining if the patient is suitable for a rhythm vs rate control strategy; whichever the strategy chosen evaluation and treatment of embolic risk is warranted.^{1,2} Most emboli are directed towards the cerebral circula-

tion, with less than 11% of embolic events directed towards systemic circulation.⁵ The incidence of acute myocardial infarction (AMI) as a consequence of AF is unknown,⁶ with scarce information available in medical literature. Nevertheless, AMI caused by coronary embolism in AF is known to be an infrequent condition (considering the number of patients with arrhythmia); a recently published study using the AVERROES, RELY, ACTIVE A & ACTIVE W database (including more than 37,000 patients with an average follow up of 2.4 years, equivalent to 91,746 patient-years) found no episodes of AMI associated to AF-related embolism.⁵ This low incidence has led to underrepresentation of this association in medical literature; risk factors, affected patient's characteristics and appropriate management are currently unknown. A case of AF-related coronary embolism is presented, followed by a systematic review of the available medical literature to summarize the best evidence available. The primary objective is to identify the general characteristics of patients who suffer an AMI by coronary embolism associated with AF. The secondary objective is to define the most appropriate treatment strategy for this group of patients.

CASE PRESENTATION

A 52-year-old man with history of arterial hypertension (CHA2DS2VASC: 1) was admitted in June 2015 for palpitations and nausea; his initial ECG in the emergency room revealing atrial fibrillation. He described previous episodes of short lasting palpitations, without previous documentation of AF (first detected AF). After initial evaluation, he referred chest pain oppression without ECG changes suggesting acute ischemia (Figure 1) but because of an elevated troponin I result (0,595 ng/mL; reference value: 0,012-0,024 ng/mL) he was diagnosed with an acute myocardial infarction without ST elevation (NSTEMI). Anticoagulant (enoxaparine 1 mg/kg each 12 hours) and anti-platelet aggregation (load of acetylsalicylic acid 300 mg and clopidogrel 300 mg both PO) were administered and the patient underwent coronary angiography. During the procedure, a fresh thrombus in the proximal portion of the anterior descending artery (ADA) with total occlusion of distal circulation was found (Figure 2), without significant atherosclerosis. Mechanical thrombectomy with aspiration of a red thrombus was performed out, restoring blood flow through the vessel with a residual occlusion at the distal portion of the ADA. Subsequent at-

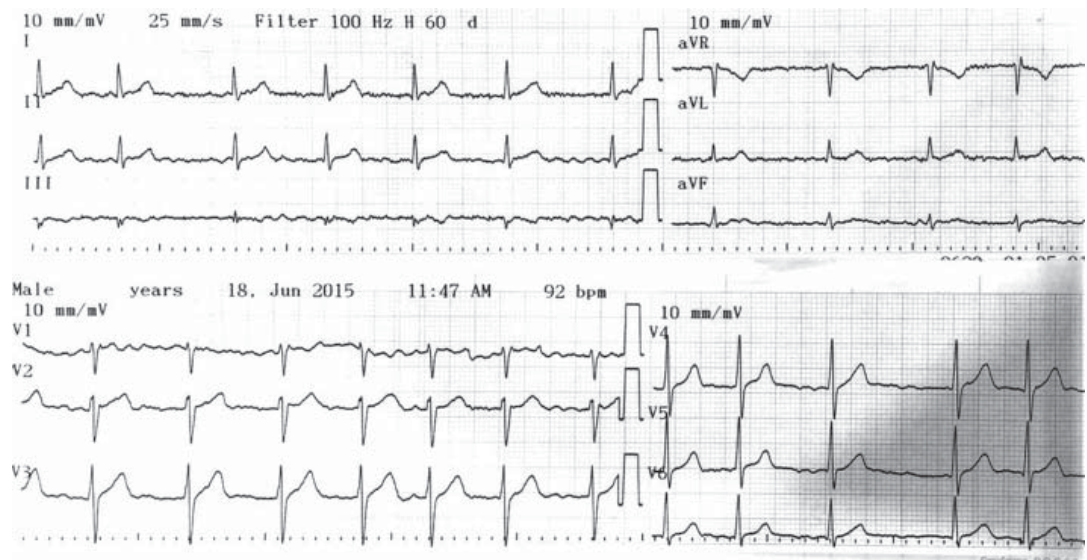


Figure 1. 12 lead ECG upon arrival at the emergency room. Atrial fibrillation (lack of a P wave, with variable RR interval) without acute ischemic changes.

tempts during the same procedure completely restored normal blood flow.

A transthoracic echocardiogram performed after coronary angiography showed a normal ejection fraction (60%) without any contractility disorders; a transesophageal echocardiogram performed the next day excluded left atrial thrombus and pharmacologic cardioversion was undertaken using an intravenous amiodarone infusion. The patient was discharged with anti-platelet therapy (acetylsalicylic acid 100 mg PO/24 h, clopidogrel 75 mg PO/24 h), oral anticoagulation with warfarin and antiarrhythmic treatment (propafenone 150 mg PO/12 h and metoprolol succinate 50 mg PO/24h). One month after the index event, pulmonary vein ablation was performed to decrease the risk of arrhythmia recurrence. After a six month follow up, no new episodes of AF have been documented during Holter monitoring, and the patient has had no angina episodes.

ATRIAL FIBRILLATION RELATED CORONARY EMBOLISM: SYSTEMATIC REVIEW

Methods: A systematic search of databases (Pubmed, EMBASE and Cochrane) was made in November 2015 using the terms «coronary embolism» OR «coronary artery embolism» OR «coronary embolization» OR «coronary throm-

boembolus» OR «coronary artery embolization» AND atrial fibrillation; the search was limited to publications written in English and/or Spanish. Additionally, a search in SciELO and LILACS was performed using the English terms and their Spanish translation («embolismo coronario» OR «embolismo de arteria coronaria» OR «tromboembolia coronaria») AND fibrilación auricular. Publications were included if coronary embolism related to AF was demonstrated by coronary angiography; publications what included patients with prosthetic valves or alternative sources of emboli (ateromatosis with suspect of ateroemboli, infective endocarditis) were excluded. Additionally, bibliographic references of the included publications were reviewed, aiming to identify studies which had not been included during the initial search. The PubMed search yielded 32 results, out of which 19 were initially excluded due to an alternative source of embolism because they were unrelated with the study question (coronary embolism associated to AF without prosthetic valves or another emboli causes); another publication was excluded because it was a letter to editor. The EMBASE search yielded 53 results in total, out of which 30 were excluded due to an alternative source of embolism; 7 were unrelated to the study question (including two posters in which there was no demonstration of coronary embolism at coronarography) and 11 were excluded because

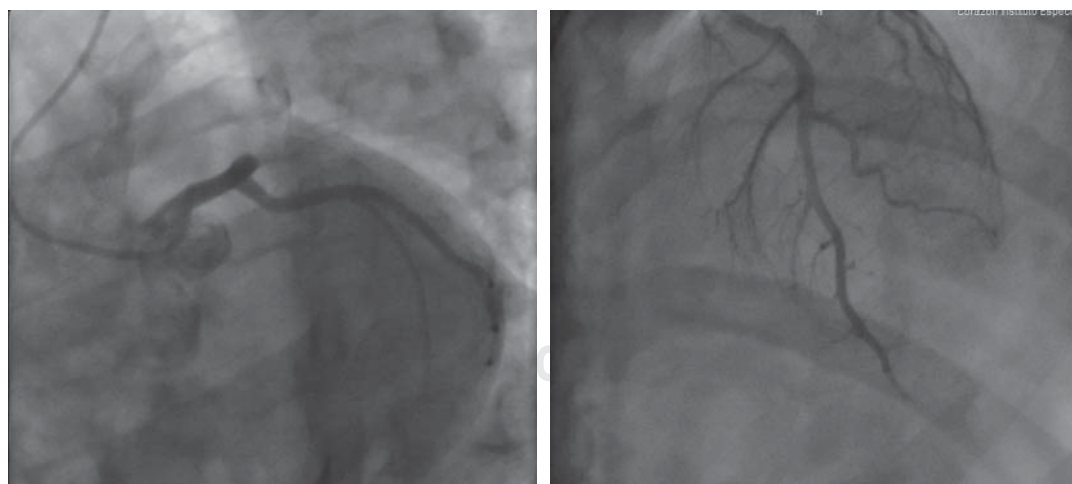


Figure 2. Coronary angiography. Left (CAU 26°, RAO19°): Occlusion of the proximal ADA proximal produced by a thrombus. Right (CAU 25°, RAO 22°): ADA reperfusion with a residual thrombus in the distal portion. CAU = Caudal, RAO = Right anterior oblique, ADA = Anterior descending artery.

of duplicate publication (10 articles identified in the previous database search and 1 with patients included in another publication). As a result, 5 publications were included from the EMBASE search. The Cochrane search yielded four results, none of which were related with the topic. The search in SciELO yielded 26 results in total (24 in English and 2 in Spanish); all were excluded because they were unrelated with the study question. The search in LILACS and Latindex did not yield any results. As a result, 17 articles were analyzed for this review (13 case reports and 4 case series) (Figure 3).

RESULTS

A total of 13 case reports of coronary embolism associated with AF were identified (each one with only one patient) (Table I); the first of these cases was reported in 1971 with the rest of them being reported over the last two decades.⁷ The mean age of patients was 63.8 ± 13.7 years, with an equal distribution of men and women. In 9 patients AF was paroxysmal, 2 patients had persistent and only 1 had permanent AF; one case report did not establish AF duration. When assessing embolism risk, most patients had a significant risk (including a patient with CHA2DS2VASC score of 7 and another patient with history of rheumatic

valvulopathy and mitral valvuloplasty), with just 3 patients with a CHA2DS3VASC score of 0 and one patient with score of 1. In 7 patients (53.8%), the acute coronary event was classified as an ST segment elevation AMI (STEMI). Most case reports agree on the use of anticoagulants and anti-platelet aggregation therapy (dual in some cases) as an initial treatment. In 53.8% of the cases, thrombus aspiration was used as the initial reperfusion strategy, achieving an excellent angiographic result;⁸⁻¹⁴ two patients had angioplasty with stent implantation due to fragmentation and distal thrombus embolism¹⁵ or inability for thrombus aspiration due to its large size.¹¹ In another 2 cases, the distal localization of the occlusion precluded any intervention (Table II).^{16,17} In one case the patient was treated unsuccessfully with thrombolytics; this patient was taken posteriorly to aortic valve surgery due to severe regurgitation without any description of whether or not coronary artery revascularization was performed during the same operatory act.¹⁸ In the case reported by Pindado et al,¹⁹ the patient was not intervened. This patient had an anomalous origin of his left coronary artery, arising from the right Valsalva sinus, with total occlusion of left coronary trunk and contained ventricular rupture; the patient presented with cardiogenic shock and finally died during the index hospitalization.¹⁹

Interestingly, two publications reported embolism after a direct current (DC) cardioversion. In one of them, the patient had been started on dabigatran 110 mg each 12 hours (a suboptimal dose according to the patient's reported characteristics) 23 days before the cardioversion.¹² In the second case, embolism occurred 4 days after DC cardioversion in a patient who was not receiving anticoagulant therapy, because of an apparently low embolic risk.¹⁸

After the acute event, most patients were treated on an outpatient basis with oral anti-coagulants, most of them without anti-platelet therapy. The agent most commonly used was warfarin; only one case reported the use of a direct oral anticoagulant.¹⁴

CASE SERIES

Four case series assessing AF-related coronary embolism were also found. In the first series,

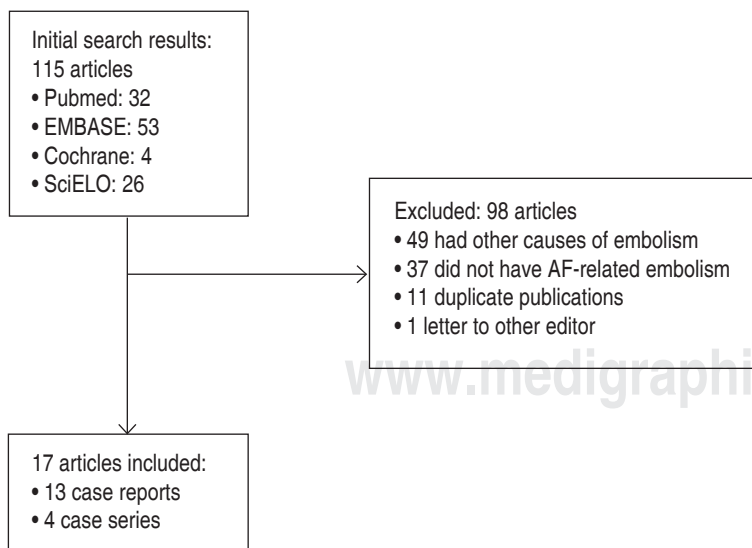


Figure 3. Study selection.

Kotooka et al described three patients (2 men; mean age 76 ± 14.9 years old) with paroxysmal AF and coronary embolism demonstrated by angiography and with a histological analysis compatible with red clots.²⁰ All three patients reported in this series had clots hosted in the coronary arteries ostia (including one patient with a clot localized in the common left trunk) which were treated with aspiration, achieving an excellent angiographic result.

Iliá et al described a series of 14 patients with AF, STEMI, one-vessel coronary artery disease and documented coronary embolism.²¹ These patients (71% female) had a mean age of 64 ± 14 years, with 64% of emboli lodged in the ADA, 29% in the right coronary artery, and only 7% in the circumflex artery. In four patients, coronary embolism was the first manifestation of paroxysmal AF. Even though the authors suggest thrombus aspiration as the preferred method for the treatment of embolic coronary occlusion, it was only performed in 36% of patients.

In a series including 33 patients reported by Hideko et al,²² acute coronary events caused by AF-related embolism had a higher mortality than other types of STEMI, a finding that had already been described in association with a higher risk of central nervous system embolism.²³ Unfortunately, individual patient characteristics are unknown (particularly the presence of comorbidities which might influence outcomes or structural heart disease), making it impossible to assume this higher mortality is due exclusively to coronary embolism. In a good percentage of these patients (67%), angioplasty was used as the primary reperfusion strategy.

Finally, Shibata et al²⁴ reported 52 confirmed coronary embolism events, 30 of which were AF related. Similar previously described, most patients (77%) had a significant risk of embolism with a CHA2DS2VASC score greater than 1; nonetheless, only 39% of patients were receiving oral anticoagulation and most of these patients had an subtherapeutic INR value. Culprit vessel was evenly distributed (35% ADA and

Table I. General characteristics of patients included in case reports.

Publication		Patient characteristics and description of the event					
Author	Date	Age	Gender	PMR	CHA2DS2VASC*	AF duration	Type of AMI
Richardson et al ⁷	1971	40	F	Mitral valvuloplasty	NA	Per	NSTEMI
Pindado et al ¹⁹	2005	82	F	DM, HTN, stroke	7	Per	STEMI
Sakai et al ⁸	2007	72	M	DM, HTN, stent ADA	4	Perm	STEMI
van der Walle et al ¹⁵	2007	64	M	Tamoxifen use	0	Par	STEMI
Garg et al ¹⁷	2007	53	F	HF, DM, HTN	3	Par	NSTEMI
Lin et al ¹⁸	2009	34	F	Severe aortic regurgitation	0	Par	STEMI
Camaro et al ¹⁶	2009	66	F	Smoking	2	NA	STEMI
Acikel et al ⁹	2011	69	F	HTN	3	Par	NSTEMI
Zasada et al ¹⁰	2013	77	M	None	1	Par	STEMI
Kim et al ¹¹	2013	58	M	None	0	Par	NSTEMI
Gagliardi et al ¹²	2014	66	M	ICC	2	Par	STEMI
Tsang et al ¹³	2014	71	F	None	2	Par	NSTEMI
Mallouppas et al ¹⁴	2015	77	M	Dyslipidemia	2	Par	NSTEMI

PMR = Past medical record, AF = Atrial fibrillation, ASA = Acetylsalicylic acid, DM = Diabetes mellitus; HTN = Hypertension, HF = Hypertension, Per = Persistent, Perm = Permanent, Par = Paroxysmal, STEMI = ST segment myocardial infarction, NSTEMI = Non ST elevation myocardial infarction, NA = Information not available, PMR = Past medical record.
* CHA2DS2VASC was calculated based on data provided.

circumflex, each one; 33% right coronary); in 28 patients clot aspiration was undertaken. Five of these patients required were further treated with stents and 4 with balloon angioplasty. Despite this, TIMI 3 flow was only achieved in 66% of cases. After a 49 month follow-up period, recurrent embolism was diagnosed in three patients with non-valvular AF (10%), a finding that should be taken into account when considering long term therapy.

Analysing this data, a total of 80 patients (28 women; 35%) were included in these series, with a similar distribution of culprit vessel (*Table III*). Embolism to the left coronary trunk seems to be an unusual finding. There is no uniform treatment between different series (and even between patients within a same series), with some patients being treated with aspiration, angioplasty or platelet inhibitors.

DISCUSSION

Global incidence (particularly in men and in the elderly) and prevalence (affecting both genders) of AF has risen during the last decades.²⁵

AF induces structural and electrophysiological changes in the atria, which coupled with a prothrombotic state complete Virchow's triad (blood stasis, abnormal blood constituents, abnormal blood vessel walls).²⁶ These changes are related with chaotic atrium depolarization (which generate progressive loss in atrial contractility), atrial dilation and remodeling; these changes are significantly greater in patients with mitral valve disease or structural heart disease. A rise in platelet activation, fibrinogen and D-dimer levels, and other molecules released by platelet granules has also been documented. AF is also associated with histologic changes (fibroblastic sub-endocardium infiltration, producing tissue constitutive changes) and increased Von Willenbrand's factor expression, changing the adhesion characteristics of the atrial wall which favors thrombosis.^{26,27} Furthermore, AF is associated with other procoagulant states such as systemic inflammation, increased growth factor release, extracellular matrix changes and nitric oxide & angiotensin II synthesis disturbances; all these changes favor thrombus formation at the interior of atrial cavities, particularly within

Table II. Medical and interventional treatment in case reports.

Author	Date	Artery involved	Intervention	Medical treatment			
				ASA	Clopidogrel	LMWH	UFH (U)
Richardson et al ⁷	1971	LMCA	None	--	--	--	40000
Pindado et al ¹⁹	2005	LMCA	None	NA	NA	NA	NA
Sakai et al ⁸	2007	RCA ostia	Aspiration	NA	NA	NA	NA
van der Walle et al ¹⁵	2007	ADA	Angioplasty, stent	160	NA	NA	NA
Garg et al ¹⁷	2007	PL	None	--	--	--	NA
Lin et al ¹⁸	2009	RCA	Thrombolysis – Surgery	NA	NA	NA	NA
Camaro et al ¹⁶	2009	RCA	None	250	600	--	5000
Acikel et al ⁹	2011	RCA	Aspiration	300	300	Enoxaparina 60 c/12h	--
Kim et al ¹¹	2013	ADA	DES	300	600	NA	NA
Zasada et al ¹⁰	2013	ADA	Aspiration	300	600	--	5000
Gagliardi et al ¹²	2014	RI	Aspiration	NA	--	--	NA
Tsang et al ¹³	2014	D2	Aspiration	NA	NA	NA	NA
Mallouppas et al ¹⁴	2015	Cx	Aspiration	NA	NA	NA	NA

ADA = Anterior descending artery, RCA = Right coronary artery, D2 = Second diagonal artery, RI = Ramus intermedius, Cx = Circumflex artery, PL = Posterolateral, -- = Not used, NA = Information not available, LMWH = Low molecular weight heparin, UFH = Unfractionated heparin, DES = Drug eluting stent.

the left atrial appendage.²⁷ These clots are composed by accumulation of red blood cells and platelets (red thrombus), as was demonstrated in the case by Sakai et al.⁸ Conversely, the presence of a white clot (platelet rich) is related to atherosclerotic disease, making histologic evaluation of the thrombus an important tool in determining its origin.

Most emboli formed during an AF episode will be directed towards the central nervous system, with coronary thromboembolism a rare occurrence due to the hemodynamic characteristics of the circulatory system. First, the lumen size of the coronary vessels and the difference in vascular resistance between the aorta and the coronary arteries favor flow along the aorta and decreases possibilities of flowing into the coronary circulation. Second, coronary arteries emerge from the aortic root artery and their ostia are partially protected by the aortic valves and Valsalva's sinus. Lastly, coronary flow occurs mainly during diastole (due to pressure differences between the aorta and ventricles) but emboli mobilize usually during systole.^{28,29}

In most of cases (around 80%) of embolic AMI, postmortem studies have found that embolus is lodged in the distal portion of coronary arteries, producing small but transmural infarctions.²⁹ In comparison with patients presenting systemic embolism or ischemic stroke, reported patients with coronary embolism seem to be younger (63 versus 73 years old) and with less risk factors for embolism; despite having cardiovascular risk factors (mainly arterial hypertension, glucose metabolism disturbances and smoking); they also have a vascular structure

and atherosclerosis markers (reactive hyperemia index and intima-media thickness) similar to healthy subjects.^{5,30}

It is possible that the incidence of AF-related coronary embolism is higher than reported. An estimated that between a 1.5-7% of acute coronary events occur in patients without coronary artery disease visible during angiography.³¹⁻³⁵ Given the results by Shibata et al, in which 2,9% of acute coronary events were related with embolism, it is possible that an important part of acute coronary events with healthy coronary arteries could be caused by resolved embolism.²⁴ In this series (the largest one evaluating coronary embolism) 73% of patients with embolism had associated AF, raising the possibility that approximately 2% of acute coronary events being caused AF-related embolism. When taking into account patients can present embolism associated with paroxysmal AF (being afterwards in sinus rhythm, making it impossible to discover an association between AF and coronary embolism), it is clear that the frequency of AF-related embolism can be even higher. On the other hand, although red thrombus are more resistant to endogenous fibrinolytic mechanisms (apparently by a lower fibrin permeability when thrombus pores are occluded by red blood cells),³⁶ it is possible that endogenous fibrinolytic mechanisms degrade the clot before coronarography, making it impossible to find evidence of coronary embolism. In his article, Shibata et al proposed criteria to standardize the diagnosis of coronary embolism (Table IV),²⁴ applying these criteria to our case, a definitive diagnosis of embolic AMI

Table III. Patient characteristics and angiographic findings in patients included in case series.

Author	Date	n	Age (y)	Fem	HTN	DM	CAD	Vessel involved				Aspiration
								LMCA	ADA	RCA	Cx	
Kotooka et al ²⁰	2004	3	76 ± 14.9	1	1	0	0	1	0	2	0	3
Ilia et al ²¹	2013	14	67 ± 14	10	11	6	14	0	9	4	1	5
Hideko et al ²²	2013	33	74 ± 9	12	NA	NA	NA	1	4	10	9	NA
Shibata et al ²⁴	2015	30	63.6 ± 12.7	5	NA	NA	NA	0	NA	NA	NA	NA

Fem = Female sex, HTN = Hypertension, DM = Diabetes mellitus, CAD = Coronary artery disease, NA = Information not available, LMCA = Left main coronary artery, ADA = Anterior descending artery, RCA = Right coronary artery, Cx = Circumflex artery.

(1 major criteria: angiographic demonstration of a clot without evidence of atherosclerosis, plus 2 minor criteria: absence of atherosclerotic injuries of more than 25% and presence of AF as an embolic risk factor).

Finally, several aspects concerning AF-related coronary embolism cannot be clarified with the available evidence. It is still to be defined if the reported higher mortality is due to embolic event per se or is rather related to a higher prevalence of comorbidities and recurrent embolism. Additionally, it is currently unknown which should be the preferred anticoagulant in these patients (either warfarin or the direct oral anticoagulants dabigatran, rivaroxaban or apixaban). Similarly, it is unclear whether or not antiplatelet therapy (either with just one drug or with dual antiplatelet therapy) is beneficial in these patients. This raises several questions:

- Is triple therapy (dual antiplatelet therapy + warfarin) associated with a net clinical benefit in these patients?
- Should antiplatelet therapy be used in combination with direct oral anticoagulants in these patients?

STUDY LIMITATIONS

This systematic review has several limitations that should be considered. First, these results cannot be extrapolated to other populations at risk for coronary embolism (including patients with prosthetic valves, aortic atheromatosis, endocarditis, and diseases associated with hypercoagulability) since the underlying mechanisms of those emboli could differ from those found in AF, which could in turn be associated with differences in treatment strategies and prognosis. It is possible that somewhere missed

Table IV. Definition of coronary embolism.

Major criteria

- Angiographic evidence of coronary artery embolism and thrombosis without atherosclerotic component
- Concomitant coronary artery embolization at multiple sites
- Concomitant systemic embolization without left ventricular thrombus attributable to acute myocardial infarction

Minor criteria

- < 25% stenosis on coronary angiography, except for the culprit lesion
- Evidence of an embolic source based on transthoracic echocardiography, transesophageal echocardiography, computed tomography, or MRI
- Presence of embolic risk factors: atrial fibrillation, cardiomyopathy, rheumatic valve disease, prosthetic heart valve, patent foramen ovale, atrial septal defect, history of cardiac surgery, infective endocarditis, or hypercoagulable state

A definite diagnosis of coronary embolism is established when:

- Presence of two or more major criteria OR
- One major criterion plus 2 or more minor criteria, OR
- Three minor criteria

A probable diagnosis is defined as one of the following:

- One major criterion PLUS 1 minor criterion
- Two minor criteria

A diagnosis of CE should not be made if there is:

- Pathological evidence of atherosclerotic thrombus
- History of coronary revascularization
- Coronary artery ectasia
- Plaque disruption or erosion detected by intravascular ultrasound or optic coherence tomography in the proximal part of the culprit lesion

Diagnostic criteria for coronary embolism proposed by Shibata et al.²⁴

during our search. This is a limitation of all systematic reviews; however, by identifying the most relevant results, a clear picture about actual evidence that surrounds the diagnosis and treatment of this condition can be obtained. By performing the search in several data bases, this possibility is decreased. Finally, the low incidence of AF-related coronary embolism is surprising; despite several hemodynamics mechanisms have been proposed to explain this, it is impossible to deny any underlying hypercoagulable state that can explain coronary embolism. None of our case reports evaluated this possibility, so no clear conclusions can be drawn about this.

CONCLUSIONS

Acute myocardial infarction due to AF-related coronary embolism is a rare event, with few cases reported in medical literature. In many patients, this is the first AF manifestation, frequently occurring in patients with low embolic risk according to existing risk stratification scales. Based on current evidence, it is possible that the use of anti-platelet aggregation, anticoagulants and thrombus aspiration could be the optimal treatment strategy in this group of patients, achieving a good rate of vessel reperfusion.

Treatment with oral anticoagulants seems necessary to avoid new events. Studies with mid and long term follow-up are required to clarify which should be the optimal treatment of these patients.

Disclosures

The authors have no disclosures.

REFERENCES

1. January CT, Wann LS, Alpert JS, Calkins H, Cigarroa JE, Cleveland JC Jr. et al. 2014 AHA/ACC/HRS guideline for the management of patients with atrial fibrillation: a report of the American College of Cardiology/American Heart Association Task Force on practice guidelines and the Heart Rhythm Society. *Circulation*. 2014; 130: e199-267.
2. European Heart Rhythm A, European Association for Cardio-Thoracic S, Camm AJ, Kirchhof P, Lip GY, Schotten U et al. Guidelines for the management of atrial fibrillation: the Task Force for the Management of Atrial Fibrillation of the European Society of Cardiology (ESC). *Europace*. 2010; 12: 1360-1420.
3. Kirchhof P, Auricchio A, Bax J, Crijns H, Camm J, Diener HC et al. Outcome parameters for trials in atrial fibrillation: executive summary. *Eur Heart J*. 2007; 28: 2803-2817.
4. Wolf PA, Dawber TR, Thomas HE, Jr., Kannel WB. Epidemiologic assessment of chronic atrial fibrillation and risk of stroke: the Framingham study. *Neurology*. 1978; 28: 973-977.
5. Bekwelem W, Connolly SJ, Halperin JL, Adabag S, Duval S, Chrolavicius S et al. Extracranial systemic embolic events in patients with nonvalvular atrial fibrillation: incidence, risk factors, and outcomes. *Circulation*. 2015; 132: 796-803.
6. Lloyd-Jones DM, Wang TJ, Leip EP, Larson MG, Levy D, Vasan RS et al. Lifetime risk for development of atrial fibrillation: the Framingham heart study. *Circulation*. 2004; 110: 1042-1046.
7. Richardson PM, Gotsman MS. Angiographic evidence of coronary embolism and resolution. *S Afr Med J*. 1971; 45: 805-809.
8. Sakai K, Inoue K, Nobuyoshi M. Aspiration thrombectomy of a massive thrombotic embolus in acute myocardial infarction caused by coronary embolism. *Int Heart J*. 2007; 48: 387-392.
9. Acikel S, Dogan M, Aksoy MM, Akdemir R. Coronary embolism causing non-ST elevation myocardial infarction in a patient with paroxysmal atrial fibrillation: treatment with thrombus aspiration catheter. *Int J Cardiol*. 2011; 149: e33-35.
10. Zasada W, Bartus S, Krolkowski T, Dudek D. Patient with atrial fibrillation and myocardial infarction due to coronary artery embolism treated with thrombus aspiration. *Kardiologia Polska*. 2013; 71: 99-101.
11. Kim HL, Seo JB, Chung WY, Zo JH, Kim MA, Kim SH. Simultaneously presented acute ischemic stroke and non-st elevation myocardial infarction in a patient with paroxysmal atrial fibrillation. *Korean Circ J*. 2013; 43: 766-769.
12. Gagliardi L, Guerbaai RA, Marliere S, Bouvaist H, Ennezat PV. Coronary embolization following electrical cardioversion in a patient treated with dabigatran. *Int J Cardiol*. 2014; 175: 571-572.
13. Tsang MY, Calvin AD, Reeder GS, Ammash NM, Hammack JE, Melduni RM. New-onset chest pain and palpitation. Coronary embolism. *Heart*. 2014; 100 (22): 1769, 1814-1815.
14. Mallouppas M, Christopoulos C, Watson W, Cader R, Cooper J. An uncommon complication of atrial fibrillation. *Oxford Medical Case Reports*. 2015; 2015: 232-234.
15. Van de Walle S, Dujardin K. A case of coronary embolism in a patient with paroxysmal atrial fibrillation receiving tamoxifen. *Int J Cardiol*. 2007; 123: 66-68.
16. Camaro C, Aengevaeren WR. Acute myocardial infarction due to coronary artery embolism in a patient with atrial fibrillation. *Neth Heart J*. 2009; 17: 297-299.
17. Garg RK, Jolly N. Acute myocardial infarction secondary to thromboembolism in a patient with atrial fibrillation. *Int J Cardiol*. 2007; 123: e18-20.
18. Lin TC, Hsieh YC, Lee WL, Lin YK, Ting CT, Wu TJ. Acute embolic myocardial infarction in a patient with

- paroxysmal atrial fibrillation receiving direct-current cardioversion. *J Chin Med Assoc.* 2009; 72: 146-149.
19. Pindado J, Marcos-Alberca P, Rey M, Rábago R, de Diego C, Ibáñez B et al. Incomplete myocardial rupture after coronary embolism of an isolated single coronary artery. *Eur J Echocardiog.* 2005; 6: 72-74.
 20. Kotooka N, Otsuka Y, Yasuda S, Morii I, Kawamura A, Miyazaki S. Three cases of acute myocardial infarction due to coronary embolism: Treatment using a thrombus aspiration device. *Jpn Heart J.* 2004; 45: 861-866.
 21. Iliá R, Weinstein JM, Wolak A, Cafri C. Coronary thrombus in ST elevation myocardial infarction and atrial fibrillation. *J Thromb Thrombolysis.* 2013; 35: 119-122.
 22. Hideko H, Dote K, Kato M, Sasaki S, Oda N et al. Clinical impact of acute coronary syndrome due to coronary thromboembolism with atrial fibrillation. *Circulation.* 2013; 128: A16112.
 23. Huang A, Shaw E, Hansen P, et al. The impact of aspiration thrombectomy on the diagnosis and outcomes of coronary embolism. *Heart Lung and Circulation.* 2011; 20: S149.
 24. Shibata T, Kawakami S, Noguchi T, Tanaka T, Asami Y, Kanaya T et al. Prevalence, Clinical Features, and Prognosis of Acute Myocardial Infarction Attributable to Coronary Artery Embolism. *Circulation.* 2015; 132: 241-250.
 25. Chugh SS, Havmoeller R, Narayanan K, Singh D, Rienstra M, Benjamin EJ et al. Worldwide Epidemiology of Atrial Fibrillation: A Global Burden of Disease 2010 Study. *Circulation.* 2014; 129: 837-847.
 26. Khoo CW, Krishnamoorthy S, Lim HS, Lip GY. Atrial fibrillation, arrhythmia burden and thrombogenesis. *Int J Cardiol.* 2012; 157: 318-323.
 27. Watson T, Shantsila E, Lip GY. Mechanisms of thrombogenesis in atrial fibrillation: Virchow's triad revisited. *Lancet.* 2009; 373: 155-166.
 28. Soliman EZ, Safford MM, Muntner P, Khodneva Y, Dawood FZ, Zakai NA et al. Atrial fibrillation and the risk of myocardial infarction. *JAMA Intern Med.* 2014; 174: 107-114.
 29. Prizel KR, Hutchins GM, Bulkley BH. Coronary artery embolism and myocardial infarction. *Ann Intern Med.* 1978; 88: 155-161.
 30. Daniel M, Ekenback C, Agewall S, Brolin EB, Caidahl K, Cederlund K et al. Risk factors and markers for acute myocardial infarction with angiographically normal coronary arteries. *Am J Cardiol.* 2015; 116: 838-844.
 31. Abid L, Bahloul A, Frikha Z, Mallek S, Abid D, Akrouf M et al. Myocardial infarction and normal coronary arteries: the experience of the cardiology department of Sfax, Tunisia. *Intern Med.* 2012; 51: 1959-1967.
 32. Collste O, Sorensson P, Frick M, Agewall S, Daniel M, Henareh L et al. Myocardial infarction with normal coronary arteries is common and associated with normal findings on cardiovascular magnetic resonance imaging: results from the Stockholm Myocardial Infarction with Normal Coronaries study. *J Int Medicine.* 2013; 273: 189-196.
 33. Larsen AI, Nilsen DW, Yu J, Mehran R, Nikolsky E, Lansky AJ et al. Long-term prognosis of patients presenting with ST-segment elevation myocardial infarction with no significant coronary artery disease (from the HORIZONS-AMI trial). *Am J Cardiol.* 2013; 111: 643-648.
 34. Stensaeth KH, Fossum E, Hoffmann P, Mangschau A, Klow NE. Clinical characteristics and role of early cardiac magnetic resonance imaging in patients with suspected ST-elevation myocardial infarction and normal coronary arteries. *Int J Cardiovasc Imaging.* 2011; 27: 355-365.
 35. Waller BF. Atherosclerotic and nonatherosclerotic coronary artery factors in acute myocardial infarction. *Cardiovasc Clin.* 1989; 20: 29-104.
 36. Varin R, Mirshahi S, Mirshahi P, Klein C, Jamshedov J, Chidiac J et al. Whole blood clots are more resistant to lysis than plasma clots--greater efficacy of rivaroxaban. *Thromb Res.* 2013; 131: e100-109.

Correspondence to:

Juan Carlos Díaz M

Cl. 34 Num. 43-66,
Centro comercial San Diego, piso 11,
Medellín, Colombia
Telephone number: (+574)4447378
E-mail: jcdiaz1234@hotmail.com