



## Non-intubated anesthesia during thoracoscopic surgery: benefits in patients with mediastinal masses

*Anestesia sin intubación en cirugía videotoroscópica: beneficios en pacientes con masas mediastínicas*

Rocío Mato-Búa, M.D.,\* David López-López, M.D.,\*  
Alejandro García-Pérez, M.D.,‡ César Bonome, PhD§

**How to cite:** Mato-Búa R, López-López D, García-Pérez A, Bonome C. Non-intubated anesthesia during thoracoscopic surgery: benefits in patients with mediastinal masses. Rev Mex Anesthesiol. 2023; 46 (1): 73-74. <https://dx.doi.org/10.35366/108626>

Sir,

For video-assisted thoracic surgery (VATS), standard anesthetic approach is increasingly questioned. Non-intubated or tubeless VATS is based on adequate loco-regional anesthetic techniques, so the patient can stay awake or under light sedation. It was associated with shorter anesthetic time, shorter hospital stays and lower postoperative complications<sup>(1)</sup>. Adverse effects of general anesthesia and positive pressure ventilation like ventilator-induced lung injury, airway trauma by lung isolation devices, residual neuromuscular block or postoperative nausea<sup>(2)</sup> can be avoided. Benefits of maintaining diaphragmatic contraction are based on a better ventilation-perfusion ratio: positive intrathoracic pressure can inflict alveolar overdistention, diverting part of the cardiac output to the non-ventilated lung and increasing intraoperative shunt<sup>(3)</sup>. As interference with anesthetic drugs is minimized, hypoxic pulmonary vasoconstriction becomes more efficient.

In this context, we would like to report a case that illustrates the benefits of tubeless anesthesia in a patient with high intraoperative risk of right ventricular dysfunction. A 14-year-old female with an anterior mediastinal tumor and multiple lung lesions underwent atypical lung resection. Computerized tomography revealed a mediastinal mass with pericardial, right atrium and ventricle infiltration, echocardiography showed extrinsic compression and impaired filling of right ventricle. She arrived to the operation room with peripheral oxygen saturation (SpO<sub>2</sub>) of 95% and a respiratory rate of 17 breaths per minute. An ultrasound-guided paravertebral block was performed in a semi-recumbent position. Ventilation was supported with high flow nasal cannula at 30 liters per minute and oxygen inspired fraction (FiO<sub>2</sub>) 0.7, initial PaO<sub>2</sub> was 292 mmHg. The procedure lasted for 16 minutes. She was sedated with propofol and remifentanyl, spontaneous breathing at 8-10 breaths per minute was maintained. At postoperative care unit, arterial blood gases showed pO<sub>2</sub> 75.5 mmHg and pCO<sub>2</sub> 34.6 mmHg (estimated FiO<sub>2</sub> 0.5 through Venturi mask). Recovery of basal SpO<sub>2</sub> was achieved in the first postoperative hour. No complications were reported, the patient's guardian gave informed consent to publication.

\* Department of Anesthesiology, Resuscitation and Pain Treatment. Complejo Hospitalario Universitario de A Coruña. A Coruña, Galicia, Spain.

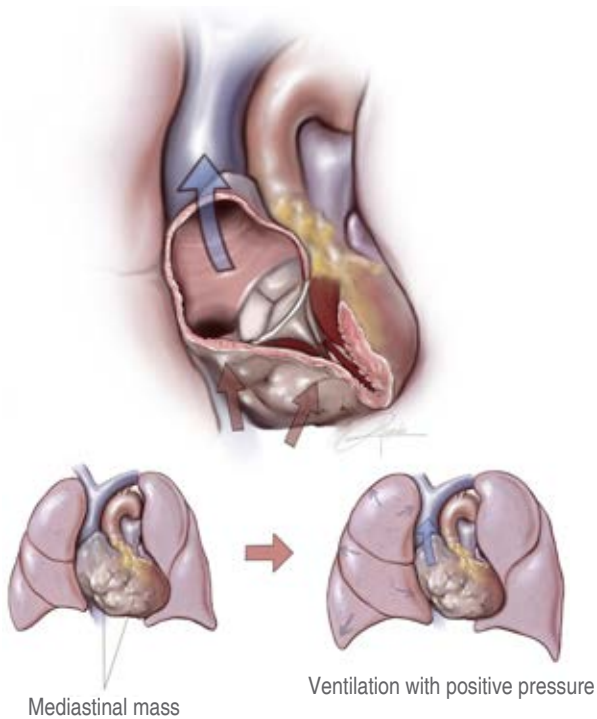
‡ Department of Thoracic Surgery and Lung Transplantation. Complejo Hospitalario Universitario de A Coruña, A Coruña, Galicia, Spain.

§ Department of Anesthesiology, Resuscitation and Pain Treatment. San Rafael Hospital. A Coruña, Galicia, Spain.

*Correspondence:*

**Rocío Mato-Búa, M.D.**

**E-mail:** [rocio.mato.bua@gmail.com](mailto:rocio.mato.bua@gmail.com);  
[rocio.mato.bua@sergas.es](mailto:rocio.mato.bua@sergas.es)



**Figure 1:** Illustration of the hemodynamic derangements generated by the initiation of mechanical ventilation on a patient with an anterior mediastinal mass (in this picture, a sarcoma originated in the right ventricle is represented).

This is an example of the benefits of tubeless VATS in patients with high risk of hemodynamic complications. On the one hand, positive pressure, hypoxia and hypercapnia generate an acute increase in pulmonary vascular resistance and right ventricle afterload, leading to right ventricular dysfunction and uncoupling with the pulmonary artery<sup>(4)</sup>. On the other hand, positive pressure could increase vascular obstruction, further impairing the filling of a right ventricle with previous diastolic dysfunction (*Figure 1*).

However, several limitations must be considered. The Surgical Team should be experienced, as spontaneously ventilation usually entails higher technical difficulty. Any contraindication for regional anesthesia, high risk of regurgitation or expected difficult airway management should preclude this approach. Adequate respiratory monitoring is mandatory and devices such as high-flow oxygen therapy could become a useful option, since both oxygenation and ventilation -airway «wash-out» effect- are supported<sup>(5)</sup>.

To sum up, experience is still scarce with tubeless VATS and it is unknown whether it provides long-term benefits compared to traditional approach<sup>(2)</sup>. However, it should be considered in some high-risk patients, as those with impaired right heart function. Further evidence is required to clarify the effectiveness and safety of this approach.

## REFERENCES

1. Wen Y, Liang H, Qiu G, Liu Z, Liu J, Ying W, et al. Non-intubated spontaneous ventilation in video-assisted thoracoscopic surgery: a meta-analysis. *Eur J Cardiothorac Surg.* 2020;57:428-437.
2. Deng HY, Zhu ZJ, Wang YC, Wang WP, Ni PZ, Chen LQ. Non-intubated video-assisted thoracoscopic surgery under loco-regional anaesthesia for thoracic surgery: a meta-analysis. *Interact Cardiovasc Thorac Surg.* 2016;23:31-40.
3. Gonzalez-Rivas D, Bonome C, Fieira E, Aymerich H, Fernandez R, Delgado M et al. Non-intubated video-assisted thoracoscopic lung resections: the future of thoracic surgery? *Eur J Cardiothorac Surg.* 2016;49:721-731.
4. Gelzinis T, Assaad S, Perrino A. Right ventricular function during and after thoracic surgery. *Curr Opin Anaesthesiol.* 2020;33: 27-36.
5. Wittenstein J, Ball L, Pelosi P, Gama de Abreu M. High-flow nasal cannula oxygen therapy in patients undergoing thoracic surgery: current evidence and practice. *Curr Opin Anesthesiol.* 2019;32:44-49.