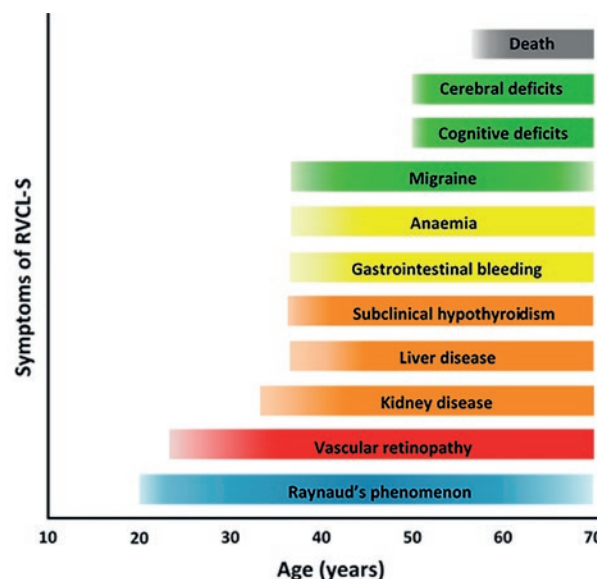


Dear Editor,

Recently, Monroy-Jaramillo et al.¹ described a new family with a disorder now known as retinal vasculopathy with cerebral leukoencephalopathy and systemic manifestations (RVCL-S)². RVCL-S is a monogenetic small vessel disease caused by C-terminal frameshift mutations in *TREX1*³. The auteurs confirm phenotypic variability in RVCL-S but inaccurately claim a large number of pre-manifest mutation carriers². In general, RVCL-S is often underdiagnosed as not all necessary diagnostic tests are performed. In a large study with 78 patients from 11 unrelated families, neuroimaging reveals white matter lesions with or without nodular enhancement (97%), rim-enhancing mass lesions (84%), and calcifications (52%). Clinical brain symptomatology was found in 90%, including focal neurological deficits (68%), migraine (59%), cognitive impairment (56%), psychiatric disturbances (42%), and seizures (17%). Systemic features included liver disease (78%), anemia (74%), nephropathy (61%), hypertension (60%), Raynaud's phenomenon (40%), and gastrointestinal bleeding (27%)² (Fig. 1). Therefore, we advise follow-up with diagnostic laboratory, ophthalmological, and neuro-radiological screening of RVCL-S mutation carriers but strongly object against biopsies because these have no added value. We would like to stress that disease status can be reliably made based on genetic testing and clinical and radiological findings alone. We would strongly argue against withholding a diagnosis to (potential) mutation carriers, especially as this is relevant for their brain, eyes, and

systemic condition and, if followed up regularly, may prevent unnecessary invasive tests and allows for timely ophthalmological treatment to prevent blindness at a young age.

Figure 1. Clinical course of retinal vasculopathy with cerebral leukoencephalopathy and systemic manifestations (RVCL-S). Symptoms of RVCL-S^{2,4} derived from cross-sectional investigation of RVCL-S patients (aged 18-65 years). Vascular retinopathy and Raynaud's phenomenon are the earliest symptoms presenting from age 20 onward. Kidney disease becomes manifest from around the age of 35 years, followed by liver disease, anemia, and, in some mutation carriers, migraine and subclinical hypothyroidism, all from age 40. Cerebral and cognitive deficits usually started mildly around age 50, associated with increasing volume of white matter hyperintensities and intracerebral mass lesions, and becoming severe and ultimately lethal around the age of 60-65 years.



REFERENCES

1. Monroy-Jaramillo N, Cerón A, León E, et al. Phenotypic variability in a Mexican mestizo family with retinal vasculopathy with cerebral leukodystrophy and *TREX1* mutation p.V235Gfs*6. *Rev Invest Clin.* 2018;70:68-75.
2. Stam AH, Kothari PH, Shaikh A, et al. Retinal vasculopathy with cerebral leukoencephalopathy and systemic manifestations. *Brain.* 2016;139:2909-22.
3. Richards A, van den Maagdenberg AM, Jen JC, et al. C-terminal truncations in human 3'-5' DNA exonuclease *TREX1* cause autosomal dominant retinal vasculopathy with cerebral leukodystrophy. *Nat Genet.* 2007;39:1068-70.
4. Pelzer N, Hoogeveen ES, Haan J, et al. Systemic features of retinal vasculopathy with cerebral leukoencephalopathy and systemic manifestations: a monogenetic small vessel disease. *J Intern Med.* 2018; [Epub ahead of print].

I. DE BOER^{1*}, A.M.J.M. VAN DEN MAAGDENBERG^{1,2}, AND G.M. TERWINDT¹

Departments of ¹Neurology and ²Human Genetics, Leiden University Medical Center, Leiden, Netherlands

Corresponding author:

*Gisela M. Terwindt

Department of Neurology

Leiden University Medical Center

Albinusdreef, 2

PO Box 9600, 2300 RC Leiden, the Netherlands

E-mail: g.m.terwindt@lumc.nl

Received for publication: 01-02-2019

Approved for publication: 12-02-2019

DOI: 10.24875/RIC.19002979
