

Pseudo-Meigs' syndrome due to high-grade serous ovarian carcinoma

Vitorino Modesto-dos Santos,*;✉ Marcos Correa-Trindade,[§] Mayza Lemes-Duarte,*
Victor Manabu-Yano,* Marcus Vinícius Ferreira-Dutra,* Francisca Germanya Morais Borges-Viana*

*Internal Medicine of Armed Forces Hospital, Brasília-DF, Brazil; [§]Catholic University of Brasília-DF, Brazil;

[§]Oncology of Armed Forces Hospital, Brasília-DF, Brazil.

Work received: 07-XI-2016; accepted: 16-XII-2016

ABSTRACT. Serous ovarian carcinoma is among the main causes of cancer-related death, and the levels of pretreatment CA 125 can be associated with survival in the high grade tumors. A postmenopausal woman with ovarian cancer and elevated levels of CA 125, presented with hydrothorax and massive ascites, which are features of pseudo-Meigs' syndrome. Data of immunohistochemistry study were consistent with high grade serous carcinoma. Diagnostic challenges of the syndrome and the mechanisms of effusions are also commented.

Key words: CA 125, cavity effusions, ovarian cancer, pseudo-Meigs' syndrome.

RESUMEN. El carcinoma seroso del ovario está entre las causas principales de muerte relacionada con el cáncer, y los niveles de CA 125 del pretratamiento se pueden asociar con supervivencia en los tumores de alto grado. Una mujer posmenopáusica con cáncer de ovario y niveles elevados de CA 125, presentó hidrotórax y ascitis masiva, que son características del síndrome de pseudo-Meigs. Los datos del estudio de inmunohistoquímica fueron consistentes con el carcinoma seroso de alto grado. También se comentan los retos diagnósticos del síndrome y los mecanismos de las efusiones.

Palabras clave: CA 125, efusiones de las cavidades, cáncer de ovario, síndrome de Pseudo-Meigs.

INTRODUCTION

In 1937, Meigs JV and Cass JW described seven patients with the typical triad of Meigs' syndrome (MS) - a benign ovarian fibroma with ascites and hydrothorax.¹⁻⁶ Worthy of note, pleural effusions and ascites should resolve after the tumor removal.¹⁻⁶ Differential diagnosis of MS includes pseudo-MS and pseudo-pseudo MS.^{2,3,6} Pseudo-MS is characterized by pleural effusions and ascites associated with other benign or malignant pelvic tumors;^{2,6} whereas in pseudo-pseudo MS the cavitory effusions with high levels of CA 125 are related to systemic lupus erythematosus.³ Elevated levels of CA 125 are reported in cases of MS, pseudo-MS and pseudo-pseudo MS;^{2,3} however, this tumor marker is indicative of malignant ovarian cancer.^{7,8} Serous ovarian cancer is a main cause of cancer-related death in USA,⁷ and the pretreatment levels of CA 125 are related to survival in high grade serous ovarian cancer (HGSOC).⁸ A case of pseudo-MS associated with HGSOC is herein described; and

the role of CA 125 levels and mechanisms of ascites and pleural effusions are commented.

CASE REPORT

A 64-year-old Brazilian woman was admitted on January 24th 2016 because of abdominal distension causing progressive breathlessness with two months of duration. She had noticed changes in her bowel function, with alternate constipation and diarrhea. Before admission, a chest radiography showed bilateral pleural effusion; and abdominal computed tomography revealed an extensive hypogastric mass with central areas of necrosis and involving adjacent small and large intestinal bowels. In addition, there was massive ascites, and infra diaphragmatic bilateral lymph node enlargement (figure 1). On admission, she claimed abdominal pain and presented with tachycardia and dyspnea. Physical examination revealed BMI: 29 kg/m², normal heart function, pleural effusion and ascites, absence of visceromegaly

and of lymph node changes, or peripheral edema. Diagnostic thoracentesis and paracentesis were done with suspicion of Meigs' syndrome. Pleural fluid was a transudate and malignant cells were not observed in pleural specimens, whereas ascites was clearly carcinomatous. Routine tests showed: hemoglobin 13.7 g/L, hematocrit 42.1%, leukocytes $5.18 \times 10^9/L$, platelets $476 \times 10^9/L$, urea 12.7 mg/dL, creatinine 0.6 mg/dL, AST 55.4 U/mL, ALT 37.5 U/

mL, ESR 61/1sth, C-reactive protein 5 mg/dL; the rest of biochemistry was normal. Worthy of note was the elevated level of CA 125: 6,973.0 U/mL (reference: < 35 U/mL). Pulmonary computed tomography angiography ruled out lung thromboembolism, and showed bilateral pleural effusion. PET-CT scan detected hypermetabolic foci indicative of neoplastic involvement in the hypogastric mass, in abdominal and thoracic lymph nodes, and in the first left rib; in addition to smooth and nodular inspissation in some peritoneal and pleural locations. Exploratory laparotomy revealed a large hypogastric tumor (9.9 cm x 9.7 cm x 7.4 cm) without plans of cleavage, and omental caking that indicated peritoneal carcinomatosis. Histopathology findings from samples obtained of the peritoneum as well as of the tumor were consistent with the diagnosis of HGSOC (figure 2). Immunohistochemistry: cytokeratins 40, 48, 50 and 50.6 kDa (AE1/AE3) positive; estrogen receptor (SP1) positive; PAX8, transcription factor of the family of gene-paired box [PAX] (MRQ50) positive; and product of oncogene Wilms Tumor 1 [WT-1] (6F-H2) positive. Additionally, the CDX2, intestinal transcription factor (EPR2764Y) and TTF-1, thyroid and lung transcription factor (clone 8G7G3/1) were all negative. The possibility of surgical approach was discarded. Therefore, patient was referred to outpatient Oncology care, and underwent chemotherapy with paclitaxel and carboplatin. It is worth noting that the patient's general condition as well as ascites and hydrothorax had progressively improved on the course of chemotherapy. Therefore, the patient did not undergo further thoracentesis since her hospital discharge. Currently, approximately 10 months after beginning of specialized follow-up, no recurrence of ascites or significant pleural effusion was revealed by routine radiographic control (figure 3).

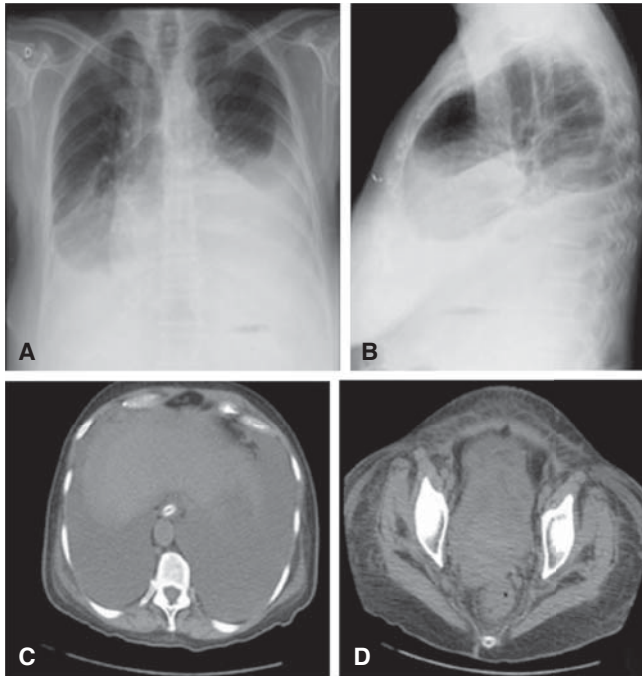


Figure 1. **A** and **B**: Chest radiograph showing accentuated bilateral pleural effusion; and abdominal CT revealing massive ascites (**C**); and voluminous hypogastric mass with areas of necrosis, bilaterally involving adjacent organs and local lymph nodes (**D**).

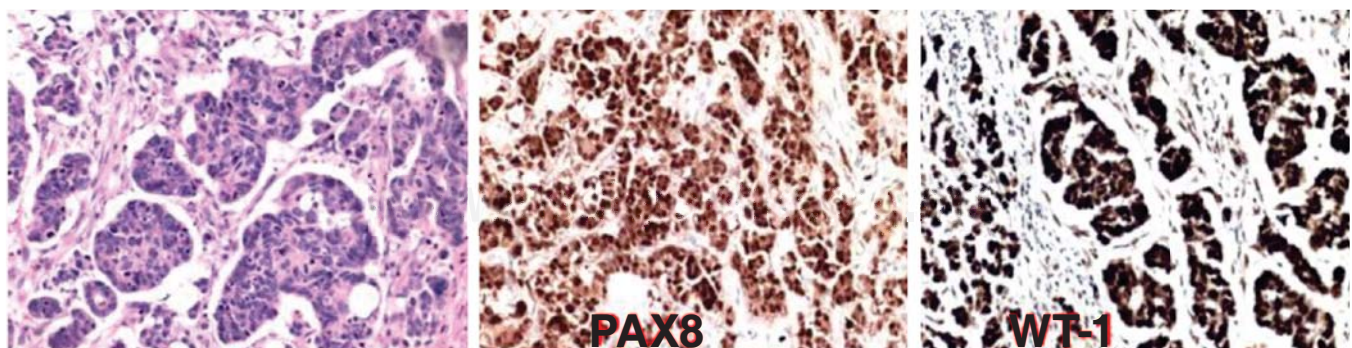


Figure 2. Immunohistochemistry evaluation strongly consistent with diagnosis of high-grade ovarian serous carcinoma, revealing the expressions of PAX8 and WT-1; the cytokeratins 40, 48, 50 and 50.6 kDa (AE1/AE3) and the estrogen receptor (SP1) were also found positive.

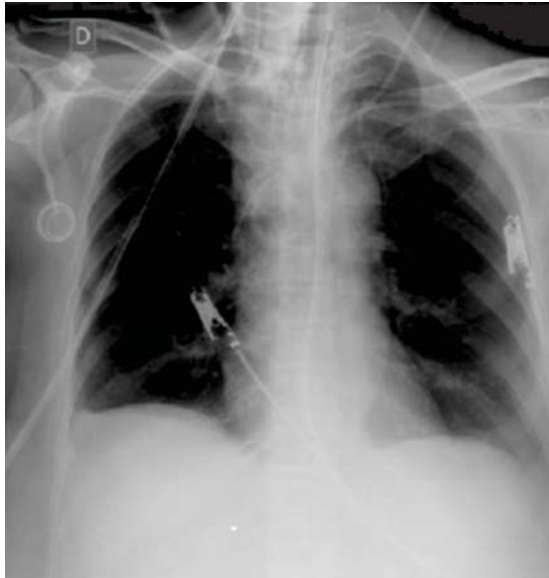

Figure 3. Recent chest radiograph of control showing absence of pleural effusion, and the implanted port for chemotherapy (at the anterior chest region and below the right clavicle).

DISCUSSION

Initially, the patient of the present case study had the diagnostic hypothesis of MS, but the diagnosis of pseudo-MS was confirmed with base on histopathology findings.¹⁻⁶ The classical triad of MS specifically refers to a benign ovarian tumor associated with hydrothorax and ascites.¹⁻⁶ Moreover, these cavity effusions should resolve after tumor removal;¹⁻⁶ phenomenon not found in people with carcinomatous ascites.⁹ Although the ovarian tumors represent the fifth cause of death by cancer in women, they are the most lethal gynecologic malignancies in the US.¹⁰ The morphological and phenotypic patterns of this tumor include HGSOE and low-grade serous cancer, endometrioid, clear cell and mucinous carcinoma.¹⁰ Furthermore, the HGSOE may be genetically classified in the following molecular groups: immunoreactive, proliferative, differentiated, and mesenchymal.¹⁰ Useful protein markers are PAX8 and WT1.¹⁰ The main ovarian tumors related to MS are fibroma, thecoma, Brenner's tumor, granulosa cell tumor, and teratoma.⁴⁻⁶ Pseudo-MS is associated with other benign or malignant pelvic tumors, and pseudo pseudo-MS is due to systemic lupus erythematosus.^{2,3,6} The mechanisms of the elevated levels of CA 125 in patients with active systemic lupus are related to serositis, inflammatory phenomena involving proinflammatory cytokines, and the expression of this tumor marker by cells of the omentum and

mesovarium.⁹ Histopathology data of biopsy samples showed peritoneal carcinomatosis in our patient. A major concern in the present case was the possibility of pseudo-MS due to metastases of digestive tract cancers with high levels of CA 125, as reported in two women with colon cancer (1,150.0 U/L)⁹ and omental caking by pancreatic cancer (465.0 U/L).⁹ Concerns about the origin of the pelvic mass were ruled out by immunohistochemistry confirmatory findings of pseudo-MS secondary to a HGSOE. Cytokeratins 40, 48, 50 and 50.6 kDa (AE1/AE3) and estrogen receptor (SP1) positive, and the expression of PAX8, and of WT-1 were consistent with ovarian etiology.¹⁰ Pretreatment levels of CA 125 higher than 500 U/ml in patients with HGSOE of FIGO stage III were found in association with enhanced survival rate.⁵ The woman herein reported presented with exceeding high blood level of CA 125 (6,973.0 U/mL); the presence of ascites and omental caking discarded possibilities of surgical approach. The antigen CA-125 is a glycoprotein that origins in the epithelium of fallopian tubes, endometrium, mesothelium of the pleura, peritoneum, and pericardium.^{6,7} High levels of this protein marker may be found in menstruation period, pregnancy, endometriosis, peritonitis, or liver cirrhosis.⁷ Finally, etiopathogeny of cavitory effusions both of MS and of pseudo-MS merit comments. The mechanisms of ascites and pleural effusion in Meigs' syndrome are controversial.⁶⁻⁸ Hypotheses include passage of ascites through diaphragmatic foramens or lymphatics, and increased capillary permeability by VEGF or inflammatory cytokines.⁶⁻⁸ Whereas pleural transudates may be due to local changes in hydrostatic or oncotic pressures; exudative effusions often occur in MS, and are found in the vast majority of the pseudo-MS cases.⁶⁻⁸ Worthy of note, novel HGSOE cell models can reliably generate tumors and ascites,¹⁰ findings that may contribute to better understanding about these syndromes.

CONCLUSION

Ovarian cancers are among the major causes of death from malignant genital tract tumors, and the association with hydrothorax and ascites constitutes pseudo-Meigs' syndrome. High levels of CA 125 do not discriminate benign from malignant abdominal conditions. Finding of PAX8 and WT1 increases the specificity and sensitivity of the ovarian cancer diagnosis. Classical MS is a benign condition that regresses after tumor removal, but the outcome of the pseudo-MS depends on the benign or malignant nature of the causes. Diagnostic criteria of both MS and pseudo-MS include the disappearance of effusions after the removal of the tumors. The option

for surgery was discarded in the present case, but successful chemotherapy yielded similar result as an invasive extraction of the tumor bulk.

REFERENCES

1. Meigs JV, Cass JW. *Fibroma of the ovary with ascites and hydrothorax: with a report of seven cases*. Am J Obstet Gynecol 1937;33:249-267.
2. Liao Q, Hu S. *Meigs' syndrome and pseudo-Meigs' syndrome: report of four cases and literature reviews*. J Cancer Ther 2015;6(4):293-298.
3. Kyo K, Maema A, Shirakawa M, Nakamura T, Koda K, Yokoyama H. *Pseudo-Meigs' syndrome secondary to metachronous ovarian metastases from transverse colon cancer*. World J Gastroenterol 2016;22(18):4604-4609. doi: 10.3748/wjg.v22.i18.4604.
4. McVorrán S, Song J, Pochineni V, Abrudescu-Opran A. *Systemic lupus erythematosus presenting with massive ascites: A case of pseudo-pseudo Meigs syndrome*. Case Rep Rheumatol 2016;2016:8701763. doi: 10.1155/2016/8701763.
5. Morales-Vásquez F, Pedernera E, Reynaga-Obregón J, et al. *High levels of pretreatment CA125 are associated to improved survival in high grade serous ovarian carcinoma*. J Ovarian Res 2016;9(1):41. doi: 10.1186/s13048-016-0247-6.
6. Okuda K, Noguchi S, Narumoto O, et al. *A case of Meigs' syndrome with preceding pericardial effusion in advance of pleural effusion*. BMC Pulm Med 2016;16(1):71. doi: 10.1186/s12890-016-0241-1.
7. Park JW, Bae JW. *Postmenopausal Meigs' syndrome in elevated CA-125: a case report*. J Menopausal Med 2015;21(1):56-59. doi: 10.6118/jmm.2015.21.1.56.
8. Sánchez-Torres DA, Díaz-Murillo R, Kazlauskas S, de Santiago J, Zapardiel I. *Síndrome de Meigs por fibroma ovárico bilateral parecido al cáncer de ovario*. Ginecol Obstet Mex 2016;84(2):122-125.
9. Santos VM, Garcia CJFS, Lopes JWP, Marques Jr VCFM, Santos LAM. *A 74-year-old woman with peritoneal carcinomatosis: diagnosis challenges*. Brasília Med 2013;50(2):156-161.
10. Mitra AK, Davis DA, Tomar S, et al. *In vivo tumor growth of high-grade serous ovarian cancer cell lines*. Gynecol Oncol 2015;138(2):372-377. doi: 10.1016/j.ygyno.2015.05.040.

✉ Corresponding author:

Prof. Vitorino Modesto-dos Santos, PhD.
Armed Forces Hospital. Estrada do Contorno do
Bosque s/n, Cruzeiro Novo. 70658-900,
Brasília-DF, Brazil.
Telephone: #5561 3966 2103
Fax: #5561 3233 1599
E-mail: vitorinomodesto@gmail.com

Conflicts of interest to declare: None.