



Infective endocarditis following transcatheter aortic valve replacement with SAPIEN 3 prosthetic valve

Endocarditis infecciosa temprana posterior a reemplazo valvular aórtico transcatóter con válvula protésica SAPIEN 3

José Pablo Sonqui-Soto,* Marco Antonio Hernández-Mercado,† Jesús Antonio Reyes-Corona§ José León Victoria-Campos,¶ Norma Eloisa Morales-Bernal||

Keywords:

EI-TAVR,
Streptococcus mitis,
transesophageal
echocardiogram,
SAPIEN 3 prosthetic
valve.

Palabras clave:

EI-RVAT,
Streptococcus mitis,
ecocardiograma
transesofágico, válvula
protésica SAPIEN 3.

* Resident Doctor
the Cardiology and
Cardiovascular
Surgery Service.

† Specialist in
Cardiology and Internal
Medicine. Investigator
and Clinical Advisor.
Head of the Cardiology
and Cardiovascular
Surgery Service.

§ Interventional
Cardiologist,
Investigator and
Clinical Advisor
in Interventional
Cardiology.

¶ Interventional
Cardiologist, Professor
of the High Speciality
in Interventional
Cardiology.

|| Master of Higher
Education. Researcher
and Methodological
Advisor. Data
Manager ConsulMed.
Mexico City.

ABSTRACT

Infective endocarditis in native valves or in surgically replaced valves has been widely reported in the literature; however, it is still in a continuous process of investigation regarding infective endocarditis in transcatheter bioprosthetic valves. We present the case of a 66-year-old female patient with the diagnosis of early infective endocarditis (IE) of percutaneous prosthetic aortic valve SAPIEN 3 who had a favorable clinical evolution and outcome with conservative treatment with antibiotics despite that in-hospital mortality incidence due to IE-TAVR, represents > 40%. The report of new cases with their different characteristics, various treatments and results obtained, is considered of great importance to support the diagnosis and medical care for future patients.

RESUMEN

La endocarditis infecciosa en válvulas nativas o en válvulas reemplazadas quirúrgicamente ha sido ampliamente descrita en la literatura; sin embargo, respecto a la endocarditis infecciosa en válvulas bioprotésicas transcatóter, aún se encuentra en un proceso continuo de investigación. Presentamos el caso de una paciente de 66 años con diagnóstico de endocarditis infecciosa temprana de válvula protésica aórtica percutánea SAPIEN 3, quien tuvo una evolución clínica y desenlace favorable con tratamiento médico conservador basado en antibióticos, a pesar de que la incidencia de mortalidad intrahospitalaria a causa de EI-TAVR, representa más de 40%. Reportar nuevos casos clínicos con sus diferentes características, sus tratamientos y resultados obtenidos, se considera de suma importancia para apoyar a un mejor diagnóstico y tratamiento médico en futuros pacientes.

INTRODUCTION

Infective endocarditis in native valves or in surgically replaced valves has been widely reported in the literature; however, it is still in a continuous process of investigation regarding infective endocarditis in transcatheter bioprosthetic valves since these have relatively little time to be approved for international use. The echocardiogram is currently the main diagnostic tool for endocarditis; however, identifying endocarditis in biological prosthetic valves is complicated—even in expert hands—due to the characteristics that it has, such

as metal struts, which prevent adequate visualization of its leaflets.¹

CASE PRESENTATION

We present the case of a 66-year-old female patient with a diagnosis of early infective endocarditis (IE) of percutaneous prosthetic aortic valve SAPIEN 3, who began with an ischemic cerebral vascular event, corroborated by studies of cabinet and laboratory. Her medical history of relevance included six months with the diagnosis of diabetes mellitus, arterial hypertension that was diagnosed a

How to cite: Sonqui-Soto JP, Hernández-Mercado MA, Reyes-Corona JA, Victoria-Campos JL, Morales-Bernal NE. Infective endocarditis following transcatheter aortic valve replacement with SAPIEN 3 prosthetic valve. *Cardiovasc Metab Sci.* 2022; 33 (2): 78-81. <https://dx.doi.org/10.35366/105823>

Toluca Medical Center,
ISSEMYM, Lic.
Arturo Montiel Rojas.
Mexico State. Mexico.

Received: 25/11/2021

Accepted: 24/03/2022

year before, frailty and partial dependency as a geriatric syndrome, also with the diagnosis of chronic systolic heart failure with mildly reduced ejection fraction (44%) and severe aortic valve stenosis. Her echocardiogram reported AVA (aortic valve area) 1 cm^2 , a peak velocity of 4.39 m/s and a mean gradient of 65 mmHg . The patient was attended by replacement with a biological aortic prosthetic SAPIEN type transcatheter, with no incidents during the procedure.

Her condition began nine months later, with clinical data of neurological deficit characterized by hemiparesis and sensitive loss of the left part of the body, together with dyslalia and dysarthria, with loss of sphincter control, so she decided to visit medical emergencies for an evaluation. During the admission, the patient presented the same neurological alterations, and physical examination identifies a mid-systolic expulsive of grade II in aortic focus without irradiation to neck vessels, hemodynamically stable, no breathing difficulty and fever of $39 \text{ }^\circ\text{C}$. Within the diagnostic protocol performed on the patient—blood cultures and echocardiogram—magnetic resonance imaging (MRI) revealed hyperintensity zone in T2 Flair (*Figure 1*) and four positive blood cultures with *Streptococcus mitis* (predominant microorganism in endocarditis after transcatheter aortic valve replacement (TAVR) isolation).^{2,3}

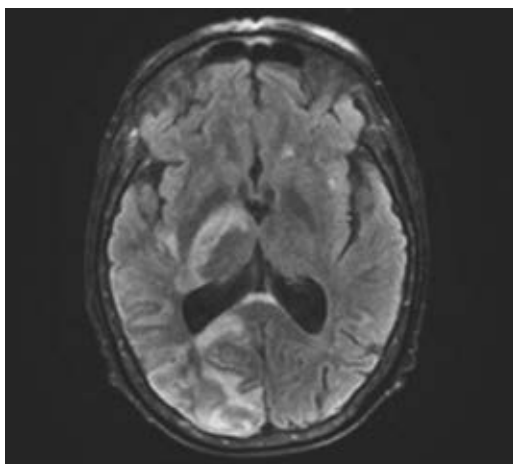


Figure 1: Zone of hyperintensity in T2 Flair, magnetic resonance.

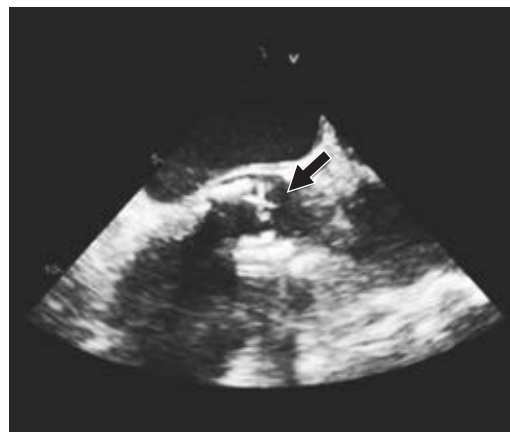

Figure 2: View of the prosthetic aortic valve in transesophageal echocardiography.

The transesophageal echocardiogram in mode 2D and 3D showed three little masses suggestive of vegetations in the aortic prosthetic valve. In the image (*Figure 2*), a small and mobile mass is observed (black arrow) about $2 \times 2 \text{ mm}$ on the ventricular side of the prosthetic aortic valve, at the level of prosthetic discs that are not commonly seen clearly, due to interposition of the valve stent/struts.¹

The third and fourth images of the 3D transesophageal echocardiogram seen at 130 degrees (*Figure 3*) show other pedunculated and mobile masses on the arterial side of the aortic prosthetic, suggestive of vegetations (black arrow) of 3×2 and $5 \times 3 \text{ mm}$ (area 0.2 cm^2).

Before the procedure, the protocol for the eradication of septic foci was followed (dental evaluation, negative nasal and otic cultures) without identifying sites of active infection. During three weeks, antibiotic treatment—vancomycin and ceftriaxone—was given, coursing a favorable clinic evolution, with no fever, negative blood cultures at the ten days of treatment, without new episodes or data of neurologic or cardiac fail. It was decided that the patient left the hospital to continue with the same intravenous treatment for three weeks, with a follow-up of external consultation.

DISCUSSION

The incidence of infective endocarditis after TAVR continues to be low, with ranges of 0.5 to

3% within the first year^{4,5} and up to 5.8% at five years of follow-up,⁶ being more frequent the in-hospital post-TAVR infective endocarditis, with 0.3%.² However, in-hospital mortality due to IE-TAVR represents a high incidence of > 40%²⁻⁴ developing as main complications fever, heart failure and systemic embolism⁴ and, as reported in the present case, *Streptococcus mitis* as one of the main causative microorganisms.⁷

The mobility, size, number of masses and adherence —specifically to the prosthesis leaflets— are characteristics that may imply a high risk of detachment and development of septic embolism as a complication. These characteristics are frequently described in the Edwards SAPIEN valve.¹

In-hospital mortality and all-cause mortality from IE-TAVR occurred in 46% of patients in the analyzes of the partner studies. Although the rates of endocarditis after TAVR remain low, the infectious consequences are catastrophic, with high numbers in mortality after diagnosis.³ Despite the fact that the mortality rate of infective endocarditis in TAVR is high (> 40%),^{2,4} this case did not have a fatal end, with the established conservative measures, having a favorable clinical evolution different from that described in the literature where it is reported that mortality is higher with medical treatment versus surgical treatment.^{8,9}

The use of third-generation cephalosporin associated with a glycopeptide showed excellent results. *Streptococcus mitis* has demonstrated in vitro susceptibility to this combination, and by allowing shorter treatment regimens, bacterial resistance and adverse effects such as nephrotoxicity are reduced.⁷

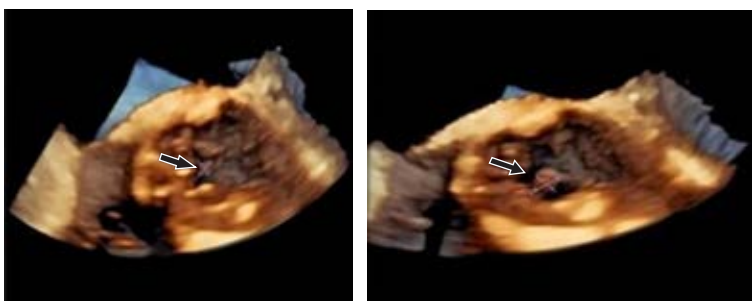


Figure 3: View showing a suggestive image of vegetation in 3D transesophageal echocardiogram.

Although various risk factors associated with prosthetic valve endocarditis such as cirrhosis, pulmonary disease or chronic kidney disease have been described.⁴ The range of factors that influence early and/or late complications of TAVR are still to be studied, especially of the infectious type (such as the isolation of different germs and their effective treatment), the previous techniques, during the intervention and/or post-surgery care. For this reason, the exploration and reporting of cases with their different characteristics, various treatments and results obtained, is considered of great importance to support the diagnosis and medical care for future patients.

CONCLUSIONS

In the short time since one of the best treatments for valve replacement has been implemented, the factors that influence early or late complications of TAVR have yet to be described; mainly, of the infectious type such as the isolation of different germs, previous techniques and their treatment during the intervention or post-surgery care.

REFERENCES

1. Miranda WR, Connolly HM, Baddour LM et al. Infective endocarditis following transcatheter aortic valve replacement: Diagnostic yield of echocardiography and associated echo-Doppler findings. *Int J Cardiol.* 2018; 271: 392-395.
2. Yeo I, Kim LK, Park SO et al. In-hospital infective endocarditis following transcatheter aortic valve replacement: a cross-sectional study of the national inpatient sample database in the USA. *J Hosp Infect.* 2018; 100 (4): 444-450. Available in: <https://doi.org/10.1016/j.jhin.2018.05.014>
3. Summers MR, Leon MB, Smith CR et al. Prosthetic valve endocarditis after TAVR and SAVR: insights from the PARTNER trials. *Circulation.* 2019; 140 (24): 1984-1994. Available in: <https://doi.org/10.1161/CIRCULATIONAHA.119.041399>
4. Regueiro A, Linke A, Latib A et al. Association between transcatheter aortic valve replacement and subsequent infective endocarditis and in-hospital death. *JAMA.* 2016; 316 (10): 1083-1092.
5. Amat IJ, Messika D, Eltchaninoff H et al. Infective endocarditis following transcatheter aortic valve implantation? results from a large multicenter registry. *Circulation.* 2015; 131 (18): 1566-1574.
6. Butt JH, Ihlemann N, De Backer O et al. Long-term risk of infective endocarditis after transcatheter aortic valve replacement. *J Am Coll Cardiol.* 2019; 73 (13): 1646-1655.

7. Yim J, Smith JR, Singh NB et al. Evaluation of daptomycin combinations with cephalosporins or gentamicin against *Streptococcus mitis* group strains in an in vitro model of simulated endocardial vegetations (SEVs). *J Antimicrob Chemother.* 2017; 72 (8): 2290-2296.
8. García D, Olmos C, Vivas D et al. Endocarditis infecciosa. *Medicine.* 2017; 12 (40): 2380-2395.
9. Sohail MR, Martin KR, Wilson WR et al. Medical versus surgical management of *Staphylococcus aureus* prosthetic valve endocarditis. *Am J Med.* 2006; 119 (2): 147-1454.

Funding/support: No financial support was received for this study.

Declaration of interests: The authors declare no conflict of interest.

Correspondence:

Norma Eloisa Morales-Bernal

E-mail: elisumb@hotmail.com