



# Triplane left atrial strain

## Strain de aurícula izquierda triplanar

Jorge Eduardo Hernández-Del Río,\* Sergio Herrera-Méndez,‡ María Cepeda-Rocha,§  
Tomás Miranda-Aquino,\* Michel Machuca-Hernández¶

### Keywords:

Left atrial, strain deformation, triplane.

### Palabras clave:

Aurícula izquierda, deformación de strain, triplanar.

### ABSTRACT

Left atrial strain, assessed by two-dimensional echocardiography with speckle tracking, has emerged as an important part of the evaluation of the atrial function in different pathologies. The objective was to compare the percentage of myocardial deformation of the left atrium evaluated by monoplane, biplane and triplane measurement. The study was a Cross-sectional, prospective, observational, analytical and single-center, atrial deformation was examined using the syngo® Velocity Vector Imaging technology software. It was predetermined to use the apical 4, 2 and 3-chamber views to calculate myocardial deformation. Patients older than 18 without cardiovascular risk factors, without previous chronic, infectious, or congenital diseases were included. A total of 126 healthy patients were collected, of which 71 (56%) were male, the mean age of the population was 38 years ( $\pm 16$ ). Intraobserver and interobserver variability were adequate. The different values of the left atrium were compared. For the reservoir strain, only a significant difference was found between the apical 3-chamber and apical 2-chamber values reported; in pump strain, there were no significant differences in values obtained; for the conduit strain, again the apical 3-chamber view was the lowest, finding a significant difference with the apical 4c, apical 2c and biplane views. The concordance of the reservoir strain of each apical view was independently related to the biplane and triplane views, finding that both apical 2c and 4c views had a good concordance with both biplane and triplane views. However, the apical 3c view had a lower concordance. The same was found for pump strain and conduit strain, being Apical 2c and 4c views superior. **Conclusion:** The 3-chamber view has different left atrial strain values than the other apical views, and the concordance of all other values of left atrium examination are similar; hence it is not further significant to perform a biplane or triplane examination. Based on the information obtained, the 3-chamber view should not be used, and a monoplane evaluation can be used, either the 4-chamber or 2-chamber views with similar concordance among them.

### RESUMEN

El strain de aurícula izquierda evaluado mediante ecocardiografía bidimensional con speckle tracking se ha convertido en una importante parte de la evaluación de la función auricular en diferentes patologías. El objetivo fue comparar el porcentaje de deformación miocárdica de la aurícula izquierda evaluado mediante medición monoplane, biplane y triplane. El estudio fue transversal, prospectivo, observacional, analítico y unicéntrico, la deformación auricular fue evaluada utilizando la deformación de la aurícula izquierda, se obtuvo utilizando el software syngo® Velocity Vector Imaging technology. Se determinó utilizar la vista apical 4, 2 y 3 cámaras para poder calcular la deformación miocárdica. Pacientes mayores de 18 sin factores de riesgo cardiovascular sin enfermedades previas crónicas, infecciosas o congénitas fueron incluidos. Se recabaron en total 126 pacientes sanos, de los cuales 71 (56%) eran del género masculino, la media de edad de la población fue de 38 años ( $\pm 16$ ). La variabilidad intraobservador e interobservador fue adecuada. Se compararon los diferentes valores de la aurícula izquierda, en el strain reservorio, sólo se encontró diferencia significativa entre los valores de apical 3 cámaras y el apical 2 cámaras; en el strain bomba no hubo diferencias significativas en los valores; en el strain conducto nuevamente la vista apical 3c fue la menor, encontrando diferencia significativa con el apical 4c, apical 2c y biplane. Se relacionó la concordancia del strain reservorio de cada vista apical de manera independiente con biplane y triplane, documentando que tanto la vista apical 2c y la apical 4c tenían buena concordancia con ambas vistas, sin embargo, la vista apical 3c tenía una menor concordancia. Lo mismo se encontró en el strain bomba y el strain conducto. Siendo superiores las vistas apicales 2c y 4c. **Conclusión:** La vista de tres cámaras tiene resultados diferentes a las demás vistas y la concordancia de todos los demás valores de la aurícula izquierda es similar, por lo que no le da más valor tomarlo en biplane o triplane. Con base en la información obtenida no se debe utilizar la vista de tres cámaras y se puede utilizar una evaluación monoplane, ya sea 4 o 2 cámaras con concordancia similar.

\* Cardiologist and Echocardiographer, Master in transesophageal echocardiography.  
‡ General Medicine.  
§ Cardiologist and Echocardiographer.  
¶ Cardiologist.

Hospital Civil de Guadalajara, Universidad de Guadalajara.

Received: 28/04/2021  
Accepted: 13/01/2022

**How to cite:** Hernández-Del Río JE, Herrera-Méndez S, Cepeda-Rocha M, Miranda-Aquino T, Machuca-Hernández M. Triplane left atrial strain. Cardiovasc Metab Sci. 2022; 33 (1): 8-16. <https://dx.doi.org/10.35366/104032>

## INTRODUCTION

Left atrial strain, assessed by two-dimensional echocardiography with speckle tracking, has emerged as an important part of the evaluation of diastolic function and for the estimation of left ventricular (LV) filling pressures, as well as in the prediction of adverse events, such as heart failure, atrial fibrillation (AF), and acute myocardial infarction (AMI).

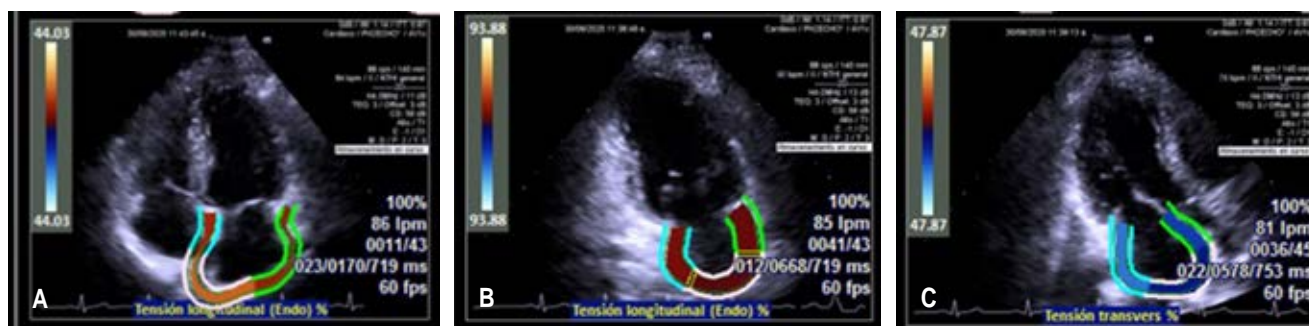The left atrium (LA) contributes to cardiac hemodynamics, modulating LV filling through the interaction of reservoir function, conduit phase, and contractile force. The reservoir function corresponds to the isovolumic contraction of the LV, its ejection and isovolumic relaxation; this depends on the systolic function of the LV, the size of the atrium and its compliance. The conduit function corresponds to the early ventricular filling phase and is modulated by atrial compliance and LV relaxation. Contractile function depends on pulmonary venous return (atrial preload), end-diastolic ventricular pressure (atrial afterload), and atrial contractile reserve.

The deformation of the atrium is a non-volumetric atrial function parameter. It evaluates its function as a muscle pump, making the deformation of atrial tissue a crucial component. Reservoir, conduit, and pump functions can be measured through longitudinal atrial strain. A low strain value orientates us towards a non-compliant, fibrous atrium, with a reduction in its contractile capacity. However, in the latest guidelines published by the American

Society of Echocardiography and the European Association of Cardiovascular Imaging for diastolic function evaluation and the quantification of atrial strain function, Strain assessment was not included. The need for methodology standardization, the acquisition of more experience by the operators, more reproducible studies, and specific software for atrial strain, with more predetermined values in healthy people, are the proposed rationales.

**Background.** Strain, also called deformation, is interpreted as the degree of deformation of the myocardial fiber during the cardiac cycle, with negative values when it contracts and positive when the myocardium relaxes.<sup>1</sup> There are three techniques to calculate strain: Tissue Doppler evaluation (angle-dependent); the second is by «speckle tracking» or point tracking, being the most widely used today since it is not modified by the angle of interrogation; and the most recent is the «velocity vector imaging» (VVI) technique, which is also angle independent, but has the advantages of faster point tracking, processing, and tracking in a single frame.<sup>2</sup> The points to be followed on the endocardial border must be set, and the software automatically tracks these marks during the cardiac cycle.

Left atrial strain (*Figure 1*) is acquired in the apical 4-chamber, 2-chamber, and 3-chamber views. The endocardial border is traced, excluding the entrance of the pulmonary veins. Currently, it has been described that it can only be acquired in a 4-chamber view, but there is also a biplane mode analysis by adding



**Figure 1:** Representation of the tracing of the atrial border for obtaining left atrial strain in the three apical planes: **A)** 4 chambers, **B)** 2 chambers, **C)** 3 chambers.

a 2-chamber view assessment.<sup>3</sup> The great advantage of using the longitudinal strain of the left atrium is that the three phases of the atrial cycle are perfectly represented, and depending on the part of the electrocardiographic trace that is taken as reference, the order of representation of these phases will change.<sup>2</sup> All waves will be positive when the QRS is used as the reference point. The first corresponds to the reservoir phase, it is the largest, so it has been taken as a synonym for the global strain of the left atrium. Then, the one that follows corresponds to the conduit phase and the last one to the pump phase. Quantitatively the value of the conduit phase is the subtraction of the reservoir phase and the pump phase values (*Figure 2*). When the P wave is taken as the reference point, the first wave is negative, corresponding to the pump phase or atrial contraction, followed by the reservoir phase and finally the conduit phase. Previously, it has been shown that similar values are obtained when taking any of the two reference points.<sup>4</sup> The technique is highly reproducible for both novices and experts, with a concordance greater than 88% among them.<sup>5</sup>

Left atrial strain is correlated to diastolic function, decreasing linearly as diastolic dysfunction progresses.<sup>1,6</sup> One relevant point is that unlike the other phases of the atrial cycle, the pump phase increases in grade 1, and later in grades 2 and 3, it decreases along with the other phases.<sup>6</sup> Reduced strain values have been associated with higher filling pressures, being inversely related to the E/e' wave ratio.<sup>7-9</sup> It has also been associated with increased left atrial stiffness and fibrosis as left atrial strain is depressed in these conditions.<sup>10</sup> In addition, it has been related to an increased wedge pressure and BNP values.<sup>11</sup> Another point in favor is that deformation values of the atrium begin to change even before the volume of the left atrium begins to increase.<sup>12</sup> It correlates better than left atrial volume and E/e' to categorize diastolic dysfunction.<sup>6</sup> It can even reclassify, especially those patients who have an undetermined diastolic function.<sup>13</sup>

Normal values have been widely discussed with some variability among studies for the reservoir phase values ranging from 28 to 60%,<sup>14</sup> this due to the great heterogeneity

in the echocardiogram equipment/software used,<sup>15</sup> the electrocardiographic reference point, and the view used for the assessment. In a recent meta-analysis that included 40 studies, it was reported that for the reservoir phase, the normal value was 39%, for the conduit phase 23% and 17% for the pump phase.<sup>16</sup> Singh et al. reported that a cut-off point below 35% could be taken as a reference point for a patient with diastolic dysfunction, and even a cut-off point lower than 19% for grade 3 diastolic dysfunction.<sup>6</sup>

A non-standardized aspect and the main purpose of this study is which views should be included to perform the atrial deformation analysis: if only 4-chamber view, if 2 and 4-chambers or 2, 3 and 4-chambers views. In the previously mentioned review and meta-analysis,<sup>14</sup> 19 studies evaluated atrial strain only in the 4-chamber view, 17 in the 2 and 4-chamber views, and only four studies in the 2, 3, and 4-chamber views, without finding significant differences in LA longitudinal strain values. In the EACVI NORRE study,<sup>17</sup> the 2 and 4-chamber views were included. The standardization document on the atrial strain, published in 2018 by the EACVI/ASE group,<sup>18</sup> recommended measuring deformation only with a 4-chamber view, taking as a valid option also to include the 2-chamber view in the analysis. Regarding the apical 3-chamber view, it can be difficult to define correctly between the ascending aorta and the anteroseptal atrial wall, a situation that can affect the measurement and strain values.<sup>19</sup>

In patients with ischemic heart disease, it has been observed that atrial strain decreases in relation to the progression of diastolic dysfunction.<sup>11,20</sup> A correlation with diastolic function has been recognized, increased mortality, reinfarction and rehospitalizations,<sup>10,12</sup> and in turn, an improvement in strain values has been observed with cardiac rehabilitation.<sup>14,21,22</sup>

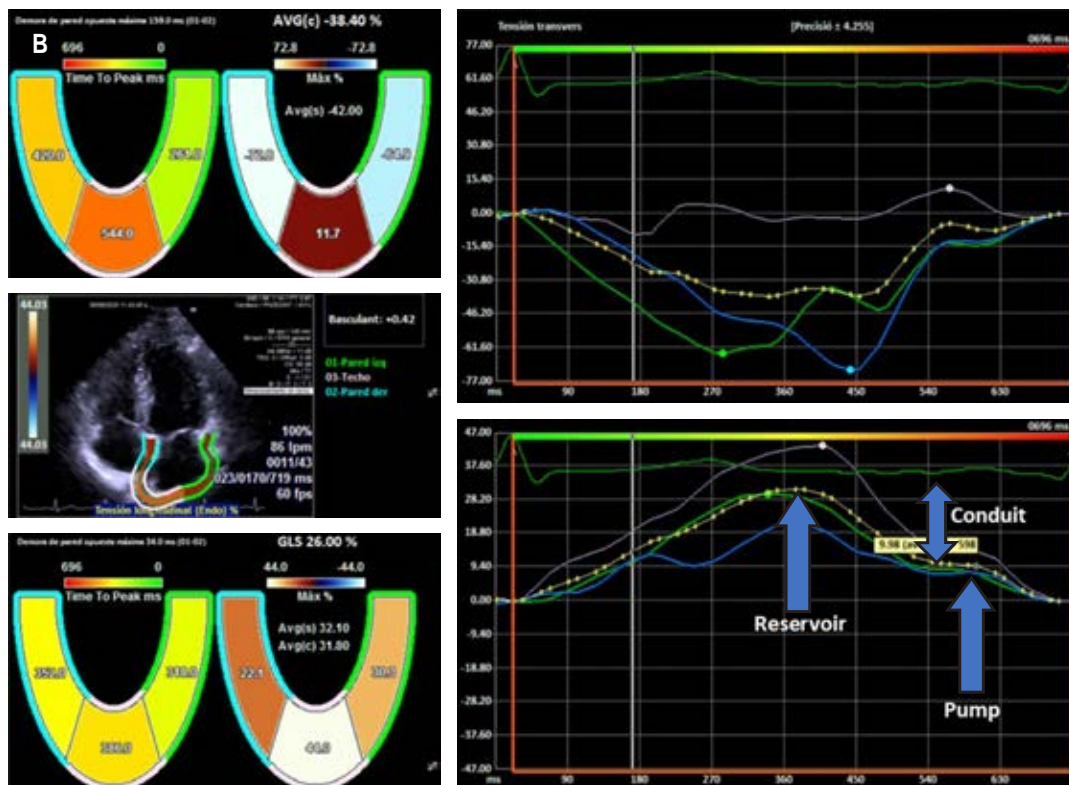
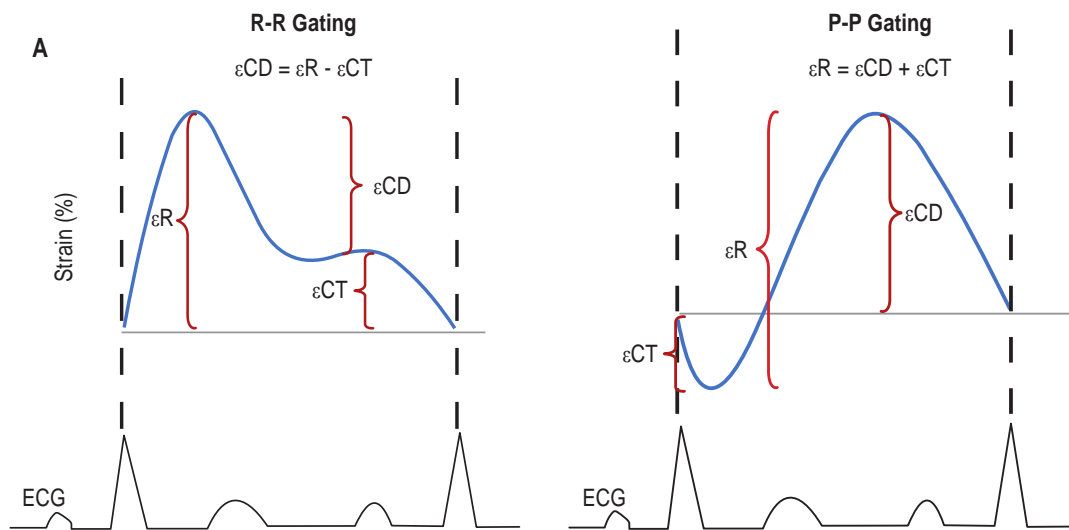
Another pathology in which left atrial deformation has been widely described is its association with atrial fibrillation. Decreased values predict the onset of this arrhythmia.<sup>23-25</sup> After atrial fibrillation ablation, the presence of a decreased strain predicts the recurrence of atrial fibrillation.<sup>26</sup> The identification of

altered strain is also associated with the risk of presenting systemic embolism in patients with atrial fibrillation.<sup>5,10,27</sup>

In mitral valve disease, a linear relationship has been widely reported as mitral regurgitation increases with decreased left atrial strain. Moreover, it has been associated

with survival.<sup>12,25,28,29</sup> It also predicts the development of atrial fibrillation in patients with mitral stenosis.<sup>30</sup>

The utility of left atrial strain in arterial hypertension,<sup>25,31</sup> chronic kidney disease,<sup>32</sup> autoimmune diseases such as lupus<sup>33</sup> and rheumatoid arthritis<sup>34</sup> has also been evaluated.



**Figure 2:**

**A)** Schematic representation of the electrocardiogram reference points (R-R, P-P) and the measurements of the different phases of atrial function measured by left atrial strain ER: reservoir strain, ECT pump strain, ECD conduit strain.  
**B)** Measurement of left atrial strain in Siemens Acuson equipment SC 2000.



**Justification.** Myocardial deformation has recently been used to assess left atrial function. The advantage of being angle-independent makes it less susceptible to errors.<sup>6</sup>

This technique has been studied in multiple cardiovascular diseases,<sup>16,35</sup> especially in atrial fibrillation, where it predicts which patients will present this arrhythmia in the near future<sup>2</sup> and who is at risk of developing thrombus. It has been observed that hypertensive patients show decreased myocardial deformation values,<sup>31</sup> and among patients with valvular heart disease, a decreased myocardial deformation is related to increased morbidity and mortality of cardiovascular cause.<sup>16,25,27,28</sup> The strain has also been related to cardiovascular events in ischemic heart disease.<sup>7,30</sup>

Myocardial deformation is closely related to diastolic function. Singh et al.<sup>6</sup> showed that the left atrial deformation decreased linearly with the degree of diastolic dysfunction, similarly in the reservoir, conduit, and pump phases. In turn, the authors identified that the best cut-off point to differentiate normal diastolic function from diastolic dysfunction was 35%.<sup>6</sup>

The importance of this study involves the relevance of determining the variability that exists between the monoplane, biplane and triplane measurement of the left atrial deformation (strain) in order to determine the appropriate method for its analysis, since this technique of evaluation is recent and specifically in atrial deformation, there is not enough evidence, especially in Latin America. The reason why it is important to establish the best analysis method.

In this study, the continuous variables were measured with the Kolmorov Smirnov test and compared with the ANOVA test, determining the agreement between values and later, the agreement was compared independently in each view of the left atrium.

**General objective.** To compare the percentage of myocardial deformation of the left atrium evaluated by monoplane, biplane and triplane measurements.

## MATERIAL AND METHODS

Cross-sectional, prospective, observational, analytical, single-center study. All patients older

than 18 who attended the Hospital Civil de Guadalajara «Fray Antonio Alcalde» cardiology department without cardiovascular risk factors, without previous chronic, infectious, or congenital diseases were included.

Demographic variables of patients were age and gender. Echocardiographic variables related to the left atrium were reservoir, conduit and pump strain, end-diastolic volume, end-systolic volume, ejection fraction and stroke volume.

The echocardiogram equipment used was a Siemens ACUSON SC2000 prime with a 2.5 MHz sectorial 4v1c probe. The ejection fraction of the left atrium was determined using the biplanar method in the traditional apical 4 and 2-chamber views (Simpson method). The tele-diastolic and tele-systolic volume of the left atrium was calculated at the end of systole and at the end of ventricular diastole, respectively, by tracing the entire atrial border starting at the medial side of the mitral annulus and ending at the lateral mitral annulus in the 4-chamber view and for the 2-chamber in the lower region of the mitral annulus and ending in the anterior mitral annulus, using the biplanar Simpson method.

Atrial deformation was examined using the syngo® Velocity Vector Imaging technology software. It was predetermined to use the apical 4, 2 and 3-chamber views to calculate myocardial deformation. The left atrial endocardium was traced at end-systole, following the endocardial borders trace during the cardiac cycle. The R-R interval of the electrocardiogram was used as the reference point for the deformation calculation. A maximum global longitudinal strain value was obtained, represented by the value of the longitudinal strain of the reservoir phase (rALS), and in addition, two other values were obtained: the conduit (cALS) and pump strain (pALS). The rALS is represented by the maximum value of the reservoir phase, the pALS at the highest point of the pump phase and the cALS by the difference between rALS and pALS.

Upon admission to the cardiology department, informed consent was given of the procedures to be performed if required. Every patient admitted to the cardiology cabinet service undergoes an echocardiogram in accordance with the recommendations of the European Society of Cardiac Imaging and the American Society of Echocardiography

guidelines. The ethical statutes of the Declaration of Helsinki were followed.

*Inclusion criteria*

1. Healthy patients older than 18 years of age.
2. Transthoracic echocardiogram performed in the Cardiology department of the Hospital Civil de Guadalajara Fray Antonio Alcalde
3. Good acoustic window.
4. Electrocardiographic trace at the time of echocardiographic images capture.
5. Have a complete clinical record that allows the acquirement of demographic variables.
6. Heart rate less than 100 beats per minute
7. Echocardiographic images acquired at 40-70 frames per second to calculate the left atrium myocardial deformation.

*Exclusion criteria*

1. Patients who have not had an echocardiogram.
2. Poor acoustic window.
3. Do not have an electrocardiographic trace at the time of echocardiogram examination.
4. Presence of any cardiovascular risk factor
5. Previous chronic, congenital, or infectious disease
6. Previous cardiovascular disease
7. Atrial fibrillation or any supraventricular arrhythmia present at the study time.
8. Heart rate greater than 100 beats per minute.
9. Less than 40 or greater than 70 frames per second at the image acquisition

time to calculate the left atrium myocardial deformation.

10. Incomplete medical record.

11. Refusal to sign the informed consent.

Specific objectives

1. To assess the left atrium deformation in the 4-chamber, 2-chamber, and 3-chamber views.
2. To compare the percentage value of strain of the LA according to the number of planes used to collect them.

**Statistical analysis**

Continuous variables are described with mean and standard deviation, according to the normality of the variables were measured with the Kolmogorov Smirnov test. Continuous variables were compared with the ANOVA test. Concordance between the values of the left atrium variables was determined using the intraclass correlation coefficient. The concordance in each view of the left atrium was then independently compared with the intraclass correlation coefficient. Statistical significance is described with a  $p < 0.05$ . Statistical analysis was performed using the medical 15.0 software.

**RESULTS**

A total of 126 healthy patients were included, of which 71 (56%) were male. The mean age of our population studied was 38 years ( $\pm 16$ ).

**Table 1: Comparison of results of left atrial values.**

Value	4c	2c	3c	Biplane	Triplane	p
Reservoir	52.3 $\pm$ 19	53.4 $\pm$ 16*	47.1 $\pm$ 17*	52.9 $\pm$ 13	50.9 $\pm$ 12	0.01
Pump	20.2 $\pm$ 10	20.3 $\pm$ 9	20.2 $\pm$ 10	20.2 $\pm$ 7	20.2 $\pm$ 7	NS
Conduit strain	32.5 $\pm$ 14*	32.9 $\pm$ 14*	26.8 $\pm$ 13*	32.7 $\pm$ 11*	30.7 $\pm$ 10	< 0.001
End-diastolic volume	13.5 $\pm$ 11	14.2 $\pm$ 11	12.5 $\pm$ 11	13.8 $\pm$ 9	13.4 $\pm$ 9	NS
End-systolic volume	46.9 $\pm$ 16*	51.9 $\pm$ 21*	41.2 $\pm$ 18*	49.1 $\pm$ 17*	46.5 $\pm$ 15	< 0.001
Ejection fraction	75.3 $\pm$ 13	72.9 $\pm$ 14	75.3 $\pm$ 13	74.2 $\pm$ 11	73.7 $\pm$ 11	NS
Stroke volume	35.7 $\pm$ 13*	37.5 $\pm$ 16*	29.2 $\pm$ 12*	36.7 $\pm$ 13*	34.2 $\pm$ 11	< 0.001

\* significant statistical difference between the left atrial values,  $p < 0.05$

Intra-observer variability was 0.92 for reservoir strain, 0.89 for pump strain, and 0.91 for the conduit strain. The inter-observer variability by the kappa method was 0.93.

The different values of the left atrium were compared (Table 1). For the reservoir strain, only a significant difference was found between the apical 3-chamber and apical 2-chamber values reported; in pump strain, there were no significant differences in values obtained; for the conduit strain, again the apical 3-chamber view was the lowest, finding a significant difference with the apical 4c, apical 2c and biplane views. No significant differences were found in the end-diastolic volumes; however, in the end-systolic volume, it was lower for the 3c apical view. Similar values for ejection fraction were documented among all three views. The stroke volume was lower in the apical 3c view.

When comparing the concordance between the apical 2c, 3c, 4c, biplane and triplane views, it was found that all three parameters of the left atrial strain had a very good concordance (Table 2). The Reservoir strain was 0.83 (Table 3), 0.81 for pump strain (Table 4), and 0.85 for conduit strain (Table 5).

The concordance of the reservoir strain of each apical view was independently related

to the biplane and triplane views (Table 3), finding that both apical 2c and 4c views had a good concordance with both biplane and triplane views; however, apical 3c view had a lower concordance. The same was found for pump strain (Table 4) and conduit strain (Table 5), being Apical 2c and 4c views superior (Tables 4 y 5).

## DISCUSSION

The intra-observer variability was adequate. We achieved a very good concordance between the left atrium values in all views. The values of left atrial deformation found in our population of healthy subjects are comparable to the values reported in the literature.<sup>17</sup> In our study, deformation values of the three phases of atrial function were compared, finding lower values for the 3-chamber apical view in both reservoir and conduit strain, without differences in pump strain. Atrial volumes showed similar behavior, finding lower values for the 3-chamber view, although this difference was only significant in the end-systolic volume but insignificant for the end-diastolic volume. The ejection fraction did not have a significant difference between the three views, unlike the stroke volume, which did present a behavior similar to the deformation and end-systolic volume with lower values.

These results are consistent with the previously described difficulty of delimitation in the 3-chamber view between the ascending aorta and the anteroseptal wall of the atrium, making it difficult to assess both deformation and atrial volumes.<sup>19</sup>

When matching the concordance of the reservoir, conduit or pump strain of each apical view independently with biplane and triplane

**Table 2: Concordance between the left atrium values among all views.**

Value	k	IC95%
Reservoir strain	0.83	0.78-0.87
Pump strain	0.81	0.75-0.85
Conduit strain	0.85	0.81-0.89

**Table 3: Concordance of reservoir strain in each view of the left atrium.**

Value	2c	3c	4c	Biplane	Triplane
2c		0.46 (0.2-0.6)	0.37 (0.1-0.5)	0.86 (0.8-0.9)	0.81 (0.7-0.9)
3c	0.46 (0.2-0.6)		0.25 (0.1-0.5)	0.42 (0.2-0.6)	0.79 (0.7-0.9)
4c	0.37 (0.1-0.5)	0.25 (0.1-0.5)		0.87 (0.8-0.9)	0.76 (0.6-0.8)
Biplane	0.86 (0.8-0.9)	0.42 (0.2-0.6)	0.87 (0.8-0.9)		0.93 (0.9-1.0)
Triplane	0.81 (0.7-0.9)	0.79 (0.7-0.9)	0.76 (0.6-0.8)	0.93 (0.9-1.0)	

**Table 4: Concordance of pump strain in each view of the left atrium.**

Value	2c	3c	4c	Biplane	Triplane
2c		0.37 (0.1-0.6)	0.19 (0.1-0.4)	0.80 (0.7-0.9)	0.74 (0.6-0.8)
3c	0.37 (0.1-0.6)		0.35 (0.1-0.5)	0.43 (0.2-0.6)	0.79 (0.7-0.9)
4c	0.25 (0.1-0.4)	0.35 (0.1-0.5)		0.85 (0.8-0.9)	0.76 (0.7-0.8)
Biplane	0.80 (0.7-0.9)	0.43 (0.2-0.6)	0.85 (0.8-0.9)		0.93 (0.9-1.0)
Triplane	0.74 (0.6-0.8)	0.79 (0.7-0.9)	0.76 (0.7-0.8)	0.93 (0.9-1.0)	

**Table 5: Concordance of conduit strain in each view of the left atrium.**

Value	2c	3c	4c	Biplane	Triplane
2c		0.51 (0.3-0.7)	0.41 (0.2-0.6)	0.87 (0.8-0.9)	0.83 (0.8-0.9)
3c	0.51 (0.3-0.7)		0.37 (0.1-0.6)	0.52 (0.3-0.7)	0.81 (0.7-0.9)
4c	0.41 (0.2-0.6)	0.37 (0.1-0.6)		0.87 (0.8-0.9)	0.80 (0.7-0.9)
Biplane	0.87 (0.8-0.9)	0.52 (0.3-0.7)	0.87 (0.8-0.9)		0.95 (0.9-1.0)
Triplane	0.83 (0.8-0.9)	0.81 (0.7-0.9)	0.80 (0.7-0.9)	0.95 (0.9-1.0)	

assessments, something similar to that found with strain and atrial volumes was observed, that is, lower values of concordance with the 3-chamber view, as opposed to the 4-chamber and 2-chamber views that match both views appropriately.

### CONCLUSIONS

The 3-chamber view has different left atrial strain values than the other apical views, and the concordance of all other values of left atrium examination are similar. Hence it is not further significant to perform a biplane or triplane examination. Based on the information obtained, the 3-chamber view should not be used, and a monoplane evaluation can be used, either the 4-chamber or 2-chamber views with similar concordance among them.

### REFERENCES

1. Thomas L, Marwick TH, Popescu BA, Donal E, Badano LP. Left atrial structure and function, and left ventricular diastolic dysfunction. *J Am Coll Cardiol.* 2019; 73 (15): 1961-1977.
2. Gan GCH, Ferkh A, Boyd A, Thomas L. Left atrial function: evaluation by strain analysis. *Cardiovasc Diagn Ther.* 2018; 8 (1): 29-46.
3. Kowallick JT. Left atrial physiology and pathophysiology: Role of deformation imaging. *World J Cardiol.* 2015; 7 (6): 299.
4. Buggy J, Hoit BD. Left atrial strain: measurement and clinical application. *Curr Opin Cardiol.* 2018; 33 (5): 479-485.
5. Rausch K, Shiino K, Putrino A, Lam AK-Y, Scalia GM, Chan J. Reproducibility of global left atrial strain and strain rate between novice and expert using multi-vendor analysis software. *Int J Cardiovasc Imaging.* 2019; 35 (3): 419-426.
6. Singh A, Addetia K, Maffessanti F, Mor-Avi V, Lang RM. LA strain for categorization of LV diastolic dysfunction. *JACC Cardiovasc Imaging.* 2017; 10 (7): 735-743.
7. Hoit BD. Assessment of left atrial function by echocardiography: novel insights. *Curr Cardiol Rep.* 2018; 20 (10): 96.
8. Morris DA, Belyavskiy E, Aravind-Kumar R, Kropf M, Frydas A, Braunauer K et al. Potential usefulness and clinical relevance of adding left atrial strain to left atrial volume index in the detection of left ventricular diastolic dysfunction. *JACC Cardiovasc Imaging.* 2018; 11 (10): 1405-1415.
9. Santos ABS, Roca GQ, Claggett B, Sweitzer NK, Shah SJ, Anand IS et al. Prognostic relevance of left atrial dysfunction in heart failure with preserved ejection fraction. *Circ Heart Fail.* 2016; 9 (4): e002763.
10. Cameli M, Mandoli GE, Loiacono F, Dini FL, Henein M, Mondillo S. Left atrial strain: a new parameter for assessment of left ventricular filling pressure. *Heart Fail Rev.* 2016; 21 (1): 65-76.
11. Degirmenci H, Bakirci EM, Demirtas L, Duman H, Hamur H, Ceyhun G et al. Relationship of left atrial global peak systolic strain with left ventricular diastolic



- dysfunction and brain natriuretic peptide level in patients presenting with non-ST elevation myocardial infarction. *Med Sci Monit Int Med J Exp Clin Res*. 2014; 20: 2013-2019.
12. Vieira MJ, Teixeira R, Goncalves L, Gersh BJ. Left atrial mechanics: echocardiographic assessment and clinical implications. *J Am Soc Echocardiogr*. 2014; 27 (5): 463-478.
  13. Telles F, Nanayakkara S, Evans S, Patel HC, Mariani JA, Vizi D et al. Impaired left atrial strain predicts abnormal exercise haemodynamics in heart failure with preserved ejection fraction. *Eur J Heart Fail*. 2019; 21 (4): 495-505.
  14. Pathan F, D'Elia N, Nolan MT, Marwick TH, Negishi K. Normal ranges of left atrial strain by speckle-tracking echocardiography: a systematic review and meta-analysis. *J Am Soc Echocardiogr*. 2017; 30 (1): 59-70.e8.
  15. Wang Y, Li Z, Fei H, Yu Y, Ren S, Lin Q et al. Left atrial strain reproducibility using vendor-dependent and vendor-independent software. *Cardiovasc Ultrasound*. 2019; 17 (1): 9.
  16. Zhang L, Taub CC. Clip, slip, and grip: impact on left atrial strain. *Circulation: Cardiovascular Imaging*. 2018; 11: e007491.
  17. Sugimoto T, Dulgheru R, Bernard A, Ilardi F, Contu L, Addetia K et al. Echocardiographic reference ranges for normal left ventricular 2D strain: results from the EACVI NORRE study. *Eur Heart J Cardiovasc Imaging*. 2017; 18 (8): 833-840.
  18. Badano L, Kolas T, Muraru D, Abraham T, Aurigemma G, Edvardsen T et al. Standardization of left atrial, right ventricular, and right atrial deformation imaging using two-dimensional speckle tracking echocardiography: a consensus document of the EACVI/ASE/Industry Task Force to standardize deformation imaging. *Eur Heart J Cardiovasc Imaging*. 2018; 19 (6): 591-600.
  19. Matías P. Strain de la aurícula izquierda por speckle tracking: descripción de protocolo para su medición paso a paso; *Rev Urug Cardiol*. 2019; 34: 72-79.
  20. Fernandes RM, Le Bihan D, Vilela AA et al. Association between left atrial strain and left ventricular diastolic function in patients with acute coronary syndrome. *J Echocardiogr*. 2019; 17: 138-146.
  21. Deniz Acar R, Bulut M, Ergun S, Yesin M, Alici G, Akcakoyun M. Effect of cardiac rehabilitation on left atrial functions in patients with acute myocardial infarction. *Ann Phys Rehabil Med*. 2014; 57 (2): 105-113.
  22. Salerno M. Multi-modality imaging of diastolic function. *J Nucl Cardiol*. 2010; 17 (2): 316-327.
  23. Lima JAC, Ambale-Venkatesh B. Left atrial strain to address the cryptogenic puzzle. *JACC Cardiovasc Imaging*. 2018; 11 (11): 1566-1568.
  24. Cho J. Left ventricular diastolic function: the link between CHA2DS2-VASc score and ischemic stroke in patients with atrial fibrillation. *J Cardiovasc Imaging*. 2018; 26 (3): 144-146.
  25. Cameli M, Incampo E, Mondillo S. Left atrial deformation: useful index for early detection of cardiac damage in chronic mitral regurgitation. *Int J Cardiol Heart Vasc*. 2017; 17: 17-22.
  26. Sugimoto T, Robinet S, Dulgheru R, Bernard A, Ilardi F, Contu L et al. Echocardiographic reference ranges for normal left atrial function parameters: results from the EACVI NORRE study. *Eur Heart J Cardiovasc Imaging*. 2018; 19 (6): 630-638.
  27. Sahebjam M, Montazeri V, Zoroufian A, Hosseinsabet A, Lotfi-Tokaldany M, Jalali A. The correlation between conventional echocardiography and two-dimensional speckle strain imaging for evaluating left atrial function in patients with moderate to severe mitral stenosis. *Echocardiogr Mt Kisco N*. 2018; 35 (10): 1550-1556.
  28. Ring L, Abu-Omar Y, Kaye N, Rana BS, Watson W, Dutka DP et al. Left atrial function is associated with earlier need for cardiac surgery in moderate to severe mitral regurgitation: usefulness in targeting for early surgery. *J Am Soc Echocardiogr*. 2018; 31 (9): 983-991.
  29. Vieira MJ, Teixeira R, Goncalves L, Gersh BJ. Left atrial mechanics: echocardiographic assessment and clinical implications. *J Am Soc Echocardiogr*. 2014; 27 (5): 463-478.
  30. 2013 ESC guidelines on the management of stable coronary artery disease. The Task Force on the management of stable coronary artery disease of the European Society of Cardiology. *Rev Esp Cardiol Engl Ed*. 2014; 67 (2): 135.
  31. Hennawy B, El Kilany W, Galal H, Mamdouh A. Role of speckle tracking echocardiography in detecting early left atrial dysfunction in hypertensive patients. *Egypt Heart J*. 2018; 70 (3): 217-23.
  32. Li C, Zhang J, Fan R, Li W, Liu Y, Liu D et al. Left atrial strain associated with alterations in cardiac diastolic function in patients with end-stage renal disease. *Int J Cardiovasc Imaging*. 2019; 35 (10): 1803-1810.
  33. Pérez-Topete SE, Miranda-Aquino T, Hernández-del Río JE, Cerpa-Cruz S, Gutiérrez-Ureña SR, Martínez-Bonilla G et al. Deformación miocárdica de la aurícula izquierda en pacientes con lupus eritematoso sistémico. *Reumatol Clínica*. 2021; 17 (2): 74-78.
  34. Venkateshvaran A, Sarajlic P, Lund LH, Fridén C, Nordgren B, Opava CH et al. Impaired left atrial dynamics and its improvement by guided physical activity reveal left atrial strain as a novel early indicator of reversible cardiac dysfunction in rheumatoid arthritis. *Eur J Prev Cardiol*. 2018; 25 (10): 1106-1108.
  35. Malagoli A, Rossi L, Bursi F, Zanni A, Sticozzi C, Piepoli MF et al. Left atrial function predicts cardiovascular events in patients with chronic heart failure with reduced ejection fraction. *J Am Soc Echocardiogr*. 2019; 32 (2): 248-256.
- Funding or support:** No financial support was received for this study.
- Conflict of interest:** The authors declare no conflict of interest.
- Correspondence:**  
**Jorge Eduardo Hernández-Del Río**  
**E-mail:** drjorgehdez@hotmail.com