

Cerebral ischemia: some secondary alterations and animal models

María Estela López-Hernández, Hugo Solís

Isquemia cerebral: algunas alteraciones secundarias y modelos animales

RESUMEN

El ataque isquémico cerebral es una de las principales causas de morbilidad y mortalidad en los países industrializados, y genera una enorme carga económica en las familias de los enfermos y en la sociedad. El propósito de esta comunicación es revisar los diferentes modelos animales utilizados para estudiar algunas de las lesiones encefálicas causadas por la isquemia cerebral, y hacer énfasis en la importancia que tiene toda esta información que contribuye a entender los mecanismos de lesión neuronal. Algunos de estos procesos involucrados en el daño neuronal aún no están bien entendidos en la actualidad son motivo de detalladas investigaciones con el objetivo de obtener conocimiento más específico. De esta manera se tendrá una mejor herramienta para prevenir y predecir el valor y el efecto terapéutico de las estrategias utilizadas para el tratamiento en el ser humano.

Palabras clave: flujo sanguíneo cerebral, modelos animales, ataque isquémico, infarto.

ABSTRACT

Stroke is a leading cause of morbidity and mortality in industrialized countries. It imposes an enormous economic burden on the families of patients and on society. The purpose of this review is to give an overview about diverse animal models used to study some brain injury by cerebral ischemia with the aim to stress that this information has contributed to understand the mechanism of the neuronal lesion. Some of these injury

processes are not yet completely understood and are now the subject of a more detailed investigation in order to obtain more specific knowledge to prevent and to predict the value and effect of therapeutic approaches in human subjects.

Key words: cerebral blood flow, animal models, stroke, ischemic penumbra.

The metabolism of the brain depends exclusively on oxygen and glucose¹⁻⁵. Commonly the cerebral blood flow (CBF) is carefully auto-regulated so that the normal human brain receives approximately 55 mL/100 g/min (this is approximately 100 mL/100 g/min in rats). This ensures continuous delivery of oxygen and glucose to energize the brain so that it can maintain cell membrane potentials, synthesize, pack and release neurotransmitters, and support cellular architecture^{6,7}. Ischemia is defined as a state of insufficient blood flow¹. Interruption of CBF results in loss of consciousness within the first 10 seconds and cessation of spontaneous and evoked electrical activity within the next 10 seconds⁸. In ischemia CBF falls and, at approximately 30 to 35 mL/100 g/min, there is an increase in the extracellular ion concentration (H⁺). When CBF falls to around 20 mL/100 g/min, intracellular migration of water from extracellular fluid leads to swelling of astrocytes, evoked potentials

Recibido: 18 noviembre 2004. Aceptado: 31 enero 2005.

Laboratorio de Neurofisiología. Departamento de Anatomía. Facultad de Medicina UNAM. Correspondencia: María Estela López-Hernández. Laboratorio de Neurofisiología. Facultad de Medicina UNAM. Av. Universidad 3000, Edif. B 4°. Col. Copilco Universidad 04510 México, D.F. 04510. E-mail: adresses:estelalopez@correo.unam.mx

cannot be elicited and the electroencephalogram (EEG) recording becomes isoelectric. Failure of electrical activity is probably associated with the cessation of orderly synthesis and the release of neurotransmitters. Electrical silence, however, is not synonymous with loss of viability. If a net increase in cerebral water content occurs, this constitutes cytotoxic edema, initially distributed in ischemic areas of gray matter. This may reduce regional blood flow by raising local tissue pressure or by distorting blood vessels and increasing resistance to flow. All flows below 15 mL/100 g/min, ionic fluxes increase, extracellular potassium (K⁺) rises extracellular calcium (Ca²⁺) falls, and the cell membrane depolarizes^{1,6,7,9,10}. Complete arrest of the cerebral circulation leads within seconds to cessation of neuronal electrical activity and within a few minutes to deterioration of the energy state and ion homeostasis¹¹. Increases in intracellular Ca²⁺ is a pivotal event in cellular dysfunction during hypoxia. Cellular dysfunction occurs when anaerobic sources of energy fail to maintain energy production at the level required by the various metabolic processes. Irreversible cellular damage occurs when the depletion of energy affects the reactions responsible for maintaining cellular integrity. Such is the inevitable sequence of events when the blood flow to the brain is arrested^{2,3,6,7,9} (figure 1).

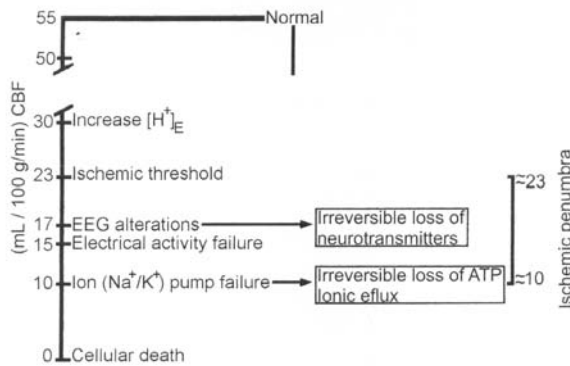


Figure 1. Cerebral Blood Flow (CBF) diagram that depicts the critical levels in which the ischemic penumbra occurs.

Some evidence indicates that in immediate failure of basic functions such as synaptic transmission, ion pumping and energy metabolism in the ischemic brain is critically dependent on residual blood flow, and that these functions fail at certain critical flow thresholds. The condition of the ischemic brain with flow between the two thresholds –the upper threshold of electrical failure and the lower threshold of energy failure and ion pump failure– can be described by electrical silence with normal or only slightly elevated extracellular K⁺

concentration. The residual perfusion supplies sufficient oxygen to maintain a close to normal tissue concentration of adenosin triphosphate (ATP). Since the concentrations of phosphocreatine and lactate are greatly reduced and increased, respectively, and since the concentrations of adenosin diphosphate (ADP) and adenosin monophosphate (AMP) are moderately increased, some degree of energy failure exists. It appears, further, that the development of infarction is critically correlated to residual perfusion, and there is a lethal threshold of residual blood flow below which tissue infarction develops after a certain time¹¹. Results obtained in hypoxia suggest that such moderate energy imbalance does not lead to neuronal damage. In focal ischemia the tissue in this condition forms a ring around the more densely ischemic center, in which energy failure and ion pump failure have developed. In analogy to the half-shaded zone around the center of a complete solar eclipse this part of the ischemic brain has been termed as the «penumbra». This term is descriptive only, and may equally well be applied in global ischemia. Although rather labile in the epileptic rat brain, the state of the «penumbra» seems stable for hours in focal ischemia and its identification may be valuable in experimental and even clinical conditions^{5,9,11,13}. Brain ischemia can result from a wide range of disturbances including cardiovascular and respiratory disorders, brain trauma¹⁴, and any condition leading to prolonged arterial hypotension or intracranial hypertension. Even in the absence of disease, cerebral ischemia remains a potential hazard of general anaesthesia^{7,9}.

Classification of cerebral ischemia:

The magnitude of ischemic cerebral damage relates the duration to the severity of ischemia. One way to classify this alteration is: *Primary brain ischemia*, that occurs because of regional cerebral ischemia (embolic or focal stroke) or global hypoxia/ischemia (resuscitation from cardiac arrest, near drowning, carbon monoxide poisoning or massive hemorrhage). *Secondary brain ischemia*, occurs in tandem with the brain injury caused by trauma, tumor or infection or with vasospasm following subarachnoid hemorrhage and is often the mayor cause of morbidity and mortality in these conditions^{7,9}. The pattern of ischemic cerebral damage depends on whether ischemic is global or focal complete or incomplete. The ischemic insults and animal models are traditionally divided into two types: global and focal (table 1). *Global ischaemia* may be incomplete –for example, in oligoemic hypoxia arising during induced or posttraumatic arterial hypotension,

Global				Focal	
Complete		Incomplete		Incomplete	
Permanent	Transient	Permanent	Transient	Permanent	Transient
Circulatory arrest** Hanging** Drowning** Brachiocephalic arterial ligation*	4-vessel occlusion* Circulatory arrest with resuscitation** Cardiac failure** Near-drowning** Massive haemorrhage** Cervical compression**	Subarachnoid hemorrhage with infarction**	Arterial** hypotension** Carbon monoxide poisoning**	MCA occlusion* Internal carotid arterial ligation* Intracarotid perfusion with wax or polyvinyl acetate* Single clip** Multiple clips** Electrocautery** Hemispherical stroke (thrombotic or embolic occlusion)**	Trauma** Tumor** Inflammatory disease** Infection** Vasospasm following subarachnoid hemorrhage** Single clip** Multiple clips** Fogarty* catheter** Atheroma** Embolism** Embolism with microspheres* Autologous blood clot** Stroke with spontaneous recanalization or thrombolytic therapy** Transient ischemic attack**

Table 1. Classification of ischemia and animal models^{5,7,9,11,5,20,28,35}.

or in carbon monoxide poisoning (an instance of anaemic hypoxia)- or *complete* after cardiac arrest (stagnant anoxia). Incomplete global ischemia implies maintenance of some flow, and ischemic damage is typically distributed along the boundary zones of flow between the main cerebral arteries. Complete global anoxia induces damage predominantly in the most recently evolved areas of the brain-neocortex, basal ganglia, hippocampus and cerebellum. While complete functional recovery cannot be expected after more than 7 minutes of normothermic global anoxia some neurons survive 1 hour of circulatory arrest^{6,9,15}. As a general rule, under normothermic conditions, 10 min. of global ischemia are lethal in man^{5,9}. Focal ischemia that follows transient or permanent flow reduction in the territory of a cerebral artery is invariably *incomplete*, and arises when blood flow in a supplying artery is reduced or stopped by atheroma, embolism, inflammatory disease or trauma (oligaemic hypoxia). The amount of damage depends on the state of the systemic or collateral circulation, and will be increased by seizure activity, hypoxaemia and systemic hypotension. Focal ischemia may also develop during episodes of raised intracranial pressure after severe head injury and it is characterized by the formation of an ischemic penumbra^{5,7,9,11,15}. If the ischemia is incomplete the outcome is more difficult to predict and is largely dependent on residual perfusion and oxygen availability. It is in large measure the outcome of incomplete cerebral ischemia, which is of particular interest in cerebral vascular disease^{5,7,9,11,15}.

Animal Models

Ischemic stroke is one of the major causes of long-term neurological disability. This condition can be reproduced in rodents and larger animals using well-

established procedures, many of which were originally developed in rats^{16,18}. The use of animal model systems forms a fundamental part of neuroscience research efforts to improve the prevention, diagnosis, understanding and treatment of neurological conditions. Without such models it would be impossible to investigate such topics as the underlying mechanisms of neuronal cell damage and death or to screen compounds for possible anticonvulsant properties¹⁹⁻²². Many of the experimental approaches have been provoked by the results of investigations that used dissociated cell culture, neuronal cell lines or hippocampal slices to study hypoxia or hypoxia/aglycemia *in vitro*, but these «test tube» lacks many features relevant to cerebral ischemia *in vivo*. *In vivo* methods that have been adopted for modeling stroke have been subject to much criticism, but consistency can be achieved, particularly in rat models, with minimal variation from laboratory to laboratory. Rodent models can be used to mimic changes in regional CBF and cerebral metabolism in a way that simulates what we have learned from human stroke by means of positron emission tomography and magnetic resonance spectroscopy. Similarity in the appearance, topography and temporal evolution of the radiologic and histopathologic injury lends further credence to the appropriateness of rodent models and suggests that agents which prevent brain injury in rats are worth testing in humans^{5,7}.

Although stroke has been studied in many species (gerbil, cats, rabbits, dogs, baboons) rats and mice are the most widely investigated^{20,23}. Rats are the most commonly used species for the modeling of neurological disease. In addition to providing an indispensable tool for basic research, rat models of human disorders allow us to investigate therapeutic strategies as a prerequisite to their testing in patients^{5,18,20}. Mice are specially useful because of the availability of unique strains that can be generically engineered to over or under express targeted gene^{5,24,27}.

Several well established models are available to study ischemia. In relation to the etiology or mechanism of ischemia two major approaches are available for disruption of the circulation of healthy blood to the brain: *extravascular* arterial compression by extrinsic ligation, and manipulation of the *intravascular* hemodynamics by embolism or hypotension. Extravascular occlusions occur in humans during surgical treatment; in experimental animals extravascular compression produces acute ischemia in the vascular distribution distal to the clip or ligation. Small spring clips may be applied under direct visual

control so that the precise site of vascular occlusion is known. Furthermore, clips may be removed after known time intervals and therefore may be used in modeling temporary or transient ischemia. However, intracranial arterial occlusion requires craniectomy, and the direct disruption of the autonomic nerve supply to the vascular bed seems unavoidable and may introduce physiological and biochemical artifacts. Intravascular methods spare the arterial nerve supply, do not require craniectomy, and while usually irreversible, may be used for pathophysiological studies spanning acute and chronic phases. Nonetheless, the site of vascular occlusion is controlled only by the size and physical characteristics of the embolic substance used. Embolic material must pass through a **rete mirabile** in all laboratory species other than dogs and primates in order to occlude intracranial vessels^{5,28}. *In vivo* global models are created by cardiac arrests with resuscitation^{29,34} and by transiently occluding both common carotid arteries (CCA) in association with either hypotension or prior bilateral vertebral artery occlusion. In the so called four vessel occlusion model, flow in both CCA and vertebral arteries are blocked for a specified time period³⁵⁻³⁷. Three vessel occlusion model may be performed by ligation of one middle cerebral artery (MCA) and both CCA in succession or by occlusion of the basilar artery with a miniature clip followed by bilateral CCA^{27,38}. In the two vessel occlusion model, which is also referred as severe forebrain ischemia, only the CCA are temporarily occluded³⁹⁻⁴¹, sometimes along with mild hypotension⁴². In all of these models injury develops selectively in cells most vulnerable to ischemic damage such as in the CA1 sector in hippocampus, medium sized neurons in the striatum, and Purkinje cells in cerebellum. The variations differ relation to time and type of ischemia⁴¹ in CBF, neuronal excitability, in number, and in qualitative changes in the neurons of hippocampus differ. Experimental focal ischemia is most commonly studied during permanent or transient occlusion of the MCA^{43,44}. Proximal MCA occlusion can be induced by an intraluminal suture (so-called, filament model)⁴⁵⁻⁴⁷ or with a vascular clip and it causes injury to cortex and deep structures (striatum). Distal MCA occlusion (the so-called Brint model) is usually produced by placing a vascular clip on a pial vessel or by cautery⁴⁸. The occlusion typically spares striatum and primarily involves the neocortex. Pannecrosis develops in the territory supplied by the respective artery with glial and endothelial cell death. If recirculation is established early (2 hours or less) the outcome is better (transient MCA occlusion)⁴⁹. In some ways, the reperfused brain

imitates restoration of blood flow after spontaneous lysis of a thrombo-embolic clot in humans, even though reperfusion after clot lysis is certainly more complex than an on/off phenomenon as modeled by placement and retraction of an intravascular filament^{5,28,45,47}. *In vitro* models allow to study the effects of cerebral ischemia in post mitotic neurons and the so-called oxygen glucose deprivation (OGD) is the model commonly used. Primary cultures of post mitotic neurons from different regions of the brain (such as cortex, striatum, septum, hippocampus, etc) can be established from rat or mouse embryos (day 16 to 18). After several days *in vitro* (1st to 14th day) these post mitotic cells can be exposed to a combined deprivation of oxygen and glucose. Depending on the length and severity of the insult, cell death develops and can be quantified on a morphological, biochemical or molecular basis^{50,51}. Other possibilities to study ischemic damage *in vitro* include the studies of brain slices, particularly the hippocampal slice⁵²⁻⁵⁵. Usually, the bathing solution is changed from a mixture of oxygen/carbon dioxide to nitrogen/carbon dioxide in the absence (hence ischemia) or presence (hence anoxia) of glucose. Generally, 5-7 min of ischemia can lead to profound cell loss in the CA1 region. Shorter insults lead to a more slowly evolving damage, requiring approximately 12 h to be manifested. This type of cell death, resembles in many ways, the delayed neuronal death seen *in vivo*⁵.

Secondary alterations by cerebral ischemia

The typical histological picture following global ischemic insults is described by delayed neuronal death sparing glial cells (sometimes even associated with astrogliosis)⁵. Factors responsible for cell death in brain ischemia are believed to involve aberrations in cellular metabolic pathways, specifically calcium, arachidonic acid, oxygen metabolism and acid-base regulation¹⁵. Global ischemia is followed by selective ischemic necrosis of neurons (SINN). SINN is profound for certain populations of neurons, such as the hippocampus CA1 pyramidal cells, cortical neurons in layers 3, 5, and 6, cerebellar Purkinje cells, and the small and medium sized striatal neurons³⁶. MCA occlusion produces a relative reduction of regional CBF, which has to be maintained for at least 1 to 2 hours followed by a period of reperfusion (temporary focal ischemia) or for 3 to 6 hours or longer (permanent focal ischemia)⁷. If ischemia is prolonged, the ischemic brain is rendered inordinately acidotic or hyperthermic and the failure of adequate reperfusion injury is more likely to result in

infarction, defined as a volume of brain tissue in which there is pannecrosis, i.e. the death of neurons, glia and endothelial cells⁵⁶⁻⁶⁰. The process of SINN differs from infarction not only because it results from a very brief (5-15 min) but severe global ischemic insult as opposed to a more prolonged, regional and less severe ischemic insult, but also because it requires a prolonged interval of reperfusion (1-7 days) for the full maturation of injury to occur, particularly for cells in the hippocampus. The final common pathway appears to be mediated by an Icthal intracellular Ca²⁺ current. It might be conjectured that ischemic brain injury is a continuum with SINN at one extreme, with slow degeneration of individual strokesensitive neurons in particular regions, and liquefying pannecrosis at the other extreme. An explanation for the conundrum of SINN would help rationalize attempts to develop an effective pharmacotherapy for acute stroke^{7,36,38,57,59,60}. Transient forebrain ischemia results in an initial energy failure, followed by a homogeneous restoration of blood flow which results in recovery of energy charge, electrophysiologic function, and membrane and neurotransmitter function, but subsequently leads to the death of certain cells in a delayed fashion⁷. After longer times of ischemia, reperfusion is incomplete due to microvascular occlusion which was termed as the no-reflow phenomenon some thirty years ago⁶¹. Following significant ischemic insults, progressive brain hypoperfusion ensues, beginning 15 –120 min after reperfusion. Hypoperfusion results from elated cerebral vascular resistance, as has been shown to occur at the precapillary and capillary level^{15,45-47,62,63}. Following ischemia, endothelin may be produced by damaged endothelial cells, causing powerful vasoconstriction, and this may be mediated, in part, by an endothelium derived platelet activating factor (PAF), which can also be derived from platelets^{7,61}. Furthermore, although increased blood viscosity may contribute to impaired microvascular perfusion, clotting does not appear contributory and heparin has no beneficial effect^{15,61,64}. Ischemic insults lead to a heterogeneous distribution of injury¹⁵. Selective vulnerability to cerebral hypoxia exists not only between different cellular elements in the brain, neurons being most sensitive and microglia and blood vessel cells least sensitive, but also between different neurons⁹. Neurons are more susceptible than glial cells, and die over hours to days after the insult⁵. Selective vulnerability most likely results primarily from differences at the cellular level. Secondary vascular compromise probably occurs during the reperfusion period, presumably from cellular changes associated with ischemia and reperfusion¹⁵. In gerbils subjected to

5 mil of forebrain ischemia CA 1 neurons disintegrate after a delay of 2-3 days (delayed neuronal death)^{65,66}. Similarly, in rats submitted to forebrain ischemia of 10-30 min, neuronal death appears after delayed of 1-3 days^{36,67-70}.

Regional idiosyncrasies of postischemic CBF and metabolism are two factors that might explain the greater sensitivity of certain neurons to ischemic damage and also the progressive nature of neuronal damage in some brain regions³⁷.

Cellular damage during reperfusion following either global or focal ischemia may be influenced by substances that accumulate during the early reperfusion period. During reperfusion, free radical production and nitric oxide (NO) generation are especially pronounced and contribute to reperfusion injury^{5,7,62,63,71,72}. The production of oxy radicals and the products of lipid peroxidation suggests a role for lipid peroxidation inhibitors as a therapy for reducing brain injury following ischemia. Lipid peroxidation products are increased following transient ischemia but remain unchanged in regions of the brain exposed to permanent focal occlusion suggesting that lipid peroxidation inhibitors are more efficacious following transient rather than permanent ischemia^{7,63}.

The hippocampus exhibits the highest sensitivity of ischemia throughout the central nervous system, and within the hippocampus the hilus and the CA1 sector are much more sensitive than the CA3 sector or the dentate gyrus⁶⁶. Delayed neuronal death in hippocampus has also been observed in patients who survived cardiac arrest for more than 24 h^{73,74}. Several molecular factors have been proposed to contribute to hippocampal injury⁷⁵, such as glutamate mediated excitation⁷⁶⁻⁸⁰, calcium toxicity^{81,82} down-regulation of adenosin receptors⁸³, inhibition of protein synthesis^{84,85}, or disturbances of polyamine metabolism⁸⁶. However, hemodynamic mechanisms cannot be excluded^{87,88}, and it has not been established which of these factors is the limiting pathophysiological event and how they relate to the duration of ischemia. In fact, selective injury of the different sectors of hippocampus is usually documented after relatively short periods of cerebral ischemia or with an interval (7 days) of reperfusion^{41,67,89-93}, whereas other neuronal populations are only involved when ischemia is prolonged or complicated by hyperglycemia^{3,70,93}. Because oxygen free radicals and NO promote apoptotic cell death⁹⁴⁻⁹⁶, transient ischemia models have become especially useful to investigate cell death *in vivo*^{97,98} which may particularly apply for models of mild ischemia⁹⁹⁻¹⁰². In these models apoptosis is prominent after 30 min MCA occlusion

followed by longer reperfusion times (several days)^{102,103}. The pattern of cell death is reminiscent of global ischemia in that it is both selective for neurons and delayed. Mild ischemia models may be similar to transient ischemic attacks in man. In fact, changes in T1/T2 weighted magnetic resonance imaging 7 days after 15min MCA occlusion in rats resemble those 7 to 10 days after transient ischemic attacks TIAs in patients with known cardiogenic embolism. However, selective neuronal death has not yet been convincingly documented following TIAs in humans⁵.

CONCLUSIONS

Global and focal cerebral ischemia represents diseases that are common in the human population. Animal models have contributed to our understanding about the diverse factors of neuronal cell damage and death for cerebral ischemia in the human. We have come to infer that not only the type and duration of ischemia is the event of major significance, but also that once reperfused, reoxygenation causes further injury. Free radical generation and other biochemical compounds following reperfusion liberate different metabolic processes and contribute on diverse ways to cell membrane injury that we can see on dissimilar manners like electrophysiological failure. These observations have led to rational theoretic approaches for the prevention, diagnosis and treatment of cerebral ischemic brain injury.

REFERENCES

- Hansen AJ. Effect of anoxia on Ion distribution in the brain. *Physiol Rev* 1985; 65(1):101-48.
- Kass IS, Abramowicz AE, Cottrell JE. Brain metabolism during ischemia and anoxia. *J Neurosurg Anest* 1989; 1(3):264-66.
- Gutierrez G. "Cellular energy metabolism during hypoxia. *Crit Care Med* 1991; 19 (5):619-26.
- López-Hernández E, Solís H. Generalidades sobre el metabolismo cerebral relacionadas con la isquemia-anoxia. *Rev Mex Enf Cardiol* 1995;3(4):93-7.
- Endres M, Dimagli U. Ischemia and Stroke. *Adv Exp Med Biol* 2002; 513:455-73.
- Navarro RCE. Metabolismo cerebral en isquemia. En: Velez AH, Rojas MW, Borrero RJY, Restrepo MJ. Eds. *Fundamentos de medicina. Neurología*. Corporación para Investigaciones Biológicas. Medellín, Colombia 1991.
- Buchan A. Advances in cerebral ischemia: experimental Approaches. *Neurol Clinics* 1992; 10(1):49-61.
- Raichle ME. The pathophysiology of brain ischemia. *Ann Neurol* 1983;13:2-10.
- Dearden NM. Ischaemic brain. *Lancet* 1985; 3:255-59.
- Martínez RHR. Fisiopatología de la isquemia cerebral. En: Barinagarrementeria F. (Ed). *Enfermedad vascular cerebral*. Instituto Syntex. México 1991.
- Astrup I, Siesjö BK, Symon L. Thresholds in cerebral ischemia. The ischemic penumbra. *Stroke* 1981;12(6):723-25.
- Fisher M. The ischemic penumbra: identification, evolution and treatment concepts. *Cerebrovasc Dis* 2004; 17 Suppl 1: 1-6.
- Lovblad KO, Koussy ME, Oswald H, Baird AE, Schroth G. Magnetic resonance imaging of the ischaemic penumbra. *Swiss Med Wkly* 2003;133:551-59.
- Bramlett HM, Dietrich WD. Pathophysiology of cerebral ischemia and brain trauma: similarities and differences. *J Cereb Blood Flow Metab* 2004; 24(2): 133-50.
- Kaplan J, Dimlich RVW, Biros MH, Hedges J. Mechanisms of ischemic cerebral injury. *Resuscit* 1987;15:149-69.
- Alonso de Lecinana M, Diez-Tejedor E, Carceller F, Roda JM. Cerebral ischemia: from animal 13 studies to clinical practice. Should the methods be reviewed? *Cerebrovasc Dis* 2001; 11 Suppl:20-30.
- Fuxe K, Bjelke B, Andbjør B, Gram H, Rimondini R. Endothelin-1 induced lesions of the frontoparietal cortex of the rat. A possible model of focal cortical ischemia. *Neurorep* 1997; 8:2623-9.
- Cenci MA, Whishaw IQ, Schallert T. Animal models of neurological deficits: how relevant is the rat? *Nature* 2002; 3:574-9.
- Lythgoe MF, Sibson NR, Harris NG. Neuroimaging of animal models of brain disease. *Br Med Bull* 2003;65:235-57.
- Roda JM, Carceller F, Pascual JM, Herguido MJ, González-Llanos F. Modelos animales experimentales en isquemia cerebral. *Neurología* 1998;13(9):427-30.
- Traystman RJ. Animal models of focal and global cerebral ischemia. *ILARJ* 2003;44(2):85-95.
- Leker RR, Constantini S. Experimental models in focal cerebral ischemia: are we there yet? *Acta Neurochir Suppl* 2002;83:55-9.
- Ginsberg MD, Busto R. Rodent models of cerebral ischemia. *Stroke* 1989;20(12):1627-42.
- Fassler R, Martin K, Forsberg E, Litzenburger T, Iglesias A. Knockout mice: how to make them and why. The immunological approach. *Int Arch Allergy Immunol* 1995;106(4):323-34.
- Majzoub JA, Muglia LJ. Molecular medicine knockout mice. *N Engl J Med* 1996; 334(14):904-07.
- Rubin EM, Barsh GS. Perspectives series: molecular medicine in genetically engineered animals. *J Clin Invest* 1996;97(2):275-80.
- Yonekura I, Kawahara N, Nakatomi H, Furuya J, Kirino T. A Model of global cerebral ischemia in C57 BL/6 mice. *J Cereb Blood Flow Metab* 2004; 24(2):151-8.
- Molinari GF, and Laurent JP. A Classification of experimental models of brain ischemia. *Stroke* 1976; 7(1):14-7.
- Pluta R, Lossinsky AS, Mossakowski MJ, Faso L, Wisniewski HM. Reassessment of a new model of complete cerebral ischemia in rats. *Acta Neuropathol* 1991;83:1-11.
- Gisvold SE, Safar P, Hendrickx HHL, Rao G, Moossy J. Thiopental treatment after global brain ischemia in pigtailed monkeys. *Anesthesiol* 1984;60:88-96.
- Cervantes M, Ruelas R, Sánchez R, Alvarez-Resendiz G. Brain injury following cardiorespiratory arrest in cats. Effects of alphaxalone-alphadolone. *Bol Estud Méd Biol Mex* 1989;37:17-27.
- Cervantes AJM. *Análisis comparativo de la actividad eléctrica de diversas estructuras cerebrales en gatos sometidos a isquemia-anoxia cerebral global aguda. Efecto de la nimodipina. Tesis de Doctorado (Área Farmacología). Facultad de Medicina, UNAM 1993.*
- Contreras GA. *Análisis electrográfico del efecto de la naloxona sobre varias estructuras cerebrales en gatos sometidos a isquemia-anoxia cerebral global aguda. Tesis de Doctorado en Ciencias Fisiológicas. UACPyP del CCH. Centro de Neurobiología. UNAM 1998.*
- González VMD. *Análisis del efecto protector de la progesterona contra el daño provocado por isquemia-anoxia cerebral global aguda en el gato. Tesis de doctorado en ciencias fisiológicas.*

- UACPyP del CCH. Centro de Neurobiología. UNAM 2000.
35. Pulsinelli WA, Brierley JB. A new model of bilateral hemispheric ischemia in the unanesthetized rat. *Stroke* 1979; 10(3):267-72.
 36. Pulsinelli WA, Brierley JB, Plum F. Temporal profile of neuronal damage in a model of transient fore brain ischemia. *Ann Neurol* 1982;11(5):491-8.
 37. Pulsinelli WA, Levy DE, Duffy TE. Regional cerebral blood flow and glucose metabolism following transient forebrain ischemia. *Ann Neurol* 1982;11(5):499-509.
 38. Chen ST, Hsu CY, Hogan EL, Maricq H, Balentine JD. A model of focal ischemic stroke in the rat: reproducible extensive cortical infarction. *Stroke* 1986;17(4):738-43.
 39. Eklöf B, Siesjö BK. The effect of bilateral carotid artery ligation upon the blood flow and the energy state of the rat brain. *Acta Physiol Scand* 1972; 86: 155-65.
 40. Eklöf B, Siesjö BK. The effect of bilateral carotid artery ligation upon acid-base parameters and substrate levels in the rat brain. *Acta Physiol Scand* 1972;86:528-38.
 41. López-Hernández E. *Alteraciones en la inhibición recurrente y en la cito arquitectura del hipocampo en un modelo de isquemia-hipoxia*. Tesis de maestría en ciencias fisiológicas. UACPyP del CCH. Centro de Neurobiología. UNAM 1997.
 42. Smith ML, Bendek G, Dahlgren N, Rosen I, Wieloch T. Models for studying long term recovery following forebrain ischemia in the rat. 2. A 2-vessel occlusion model. *Acta Neurol Scand* 1984;69:385-401.
 43. Tamura A, Graham DI, McCulloch J, Teasdale GM. Focal cerebral ischemia in the rat: description of technique and early neuropathological consequences following middle cerebral artery occlusion. *J Cereb Blood Flow Metab* 1981;1(1):53-60.
 44. Lee EJ, Wu TS, Lee MY, Chen TY, Tsai YY. Delayed treatment with melatonin enhances electrophysiological recovery following transient focal cerebral ischemia in rats. *J Pineal Res* 2004; 36(1):33-42.
 45. Zea LE, Weinstein PR, Carlson S, Cummins R. Reversible middle cerebral artery occlusion without craniectomy in rats. *Stroke* 1989; 20(1):84-91.
 46. McColl BW, Carswell HV, McCulloch J, Horsburgh K. Extension of cerebral hypoperfusion and ischemic pathology beyond MCA territory after intraluminal filament occlusion in C57 Bl/6J mice. *Brain Res* 2004;997:14-22.
 47. Hartings JA, Rolli ML, May Lu XC, Tortella F. Delayed secondary phase of peri-infarct depolarizations after focal cerebral ischemia: relation to infarct growth and neuroprotection. *J Neurosci* 2003; 23(37):11602-10.
 48. Brint S, Jacewicz M, Kiessling M, Tanabe J, Pulsinelli W. Focal brain ischemia in the rat: methods for reproducible neocortical infarction using tandem occlusion of the distal middle cerebral and ipsilateral common carotid arteries. *J Cereb Blood Flow Metab* 1988; 8 (4):474-85.
 49. Hara H, Huang PL, Panahian N, Fishman MC, Moskowitz MA. Reduced brain edema and infarction volume in mice lacking the neuronal isoform of nitric oxide synthase after transient MCA occlusion. *J Cereb Blood Flow Metab* 1996;16(4):605-11.
 50. Dawson VL, Kizushi VM, Huang PL, Snyder SH, Dawson TM. Resistance to neurotoxicity in cortical cultures from neuronal nitric-oxide-synthase-deficient mice. *J Neurosci* 1996; 16(8):2479-87.
 51. Rothman S. Synaptic release of excitatory amino acid neurotransmitter mediates anoxic neuronal death. *J Neurosci* 1984;4(7):1884-91.
 52. Traynelis SF, Dingledine R. Potassium-Induced spontaneous electrographic seizures in the rat hippocampal slice. *J Neurophysiol* 1988;59(1):259-76.
 53. Watson PL, Weiner JL, Carlen PL. Effects of variations in hippocampal slice preparation protocol on the electrophysiological stability, epileptogenicity and graded hypoxia responses of CA1 neurons. *Brain Res* 1997;775:134-43.
 54. Tsubokawa H, Oguro K, Masuzawa T, Kawai N. Spontaneous excitatory postsynaptic currents in hippocampal CA1 pyramidal neurons of the gerbil after transient ischemia. *Neurosci Lett* 1995; 191:95-8.
 55. Khazipov K, Bregestovski Pand Ben-Ari Y. Hippocampal inhibitory interneurons are functionally disconnected from excitatory inputs by anoxia. *J Neurophysiol* 1993; 70(6):2251-9.
 56. Marcoux FW, Morawetz RB, Crowell RM, DeGirolami U, Halsey JB. Differential regional vulnerability in transient focal cerebral ischemia. *Stroke* 1982; 13(3): 339-46.
 57. Pulsinelli WA. Selective neuronal vulnerability: morphological and molecular characteristics. *Prog Brain Res* 1985;63:29-37.
 58. Torvik A, Svindland A. Is there a transitional zone between brain infarcts and the surrounding brain? A histological study. *Acta Neurol Scand* 1986;74(5):365-70.
 59. Nedergaard M. Mechanisms of brain damage in focal cerebral ischemia. *Acta Neurol Scand* 1988;77:81-101.
 60. Graham DI. Hypoxia and vascular disorders. In: Adams JH, DuChen LW (Eds.) *Greenfield's neuropathology*. Edward Arnold. Great Britain 1992.
 61. Ames III A, Wright L, Kowada M, Thurston JM, Majno G. Cerebral ischemia II. The no-reflow phenomenon. *Am J Pathol* 1968; 52(2):437-53.
 62. White BC, Grossman LI, O'Neil BJ, DeGracia DJ, Neumar RW. Global Brain Ischemia and Reperfusion. *Ann Emerg Med* 1996;27:588-94.
 63. White BC, Grossman LI, Krause GS. Brain injury by global ischemia and reperfusion: A theoretical perspective on membrane damage and repair. *Neurology* 1993;43:1656-65.
 64. Gadzinski DS, White BC, Hoehner PJ, Hoelmer T, Krome C. Canine cerebral cortical blood flow and vascular resistance post cardiac arrest. *Ann Emerg Med* 1982;11(2):58-63.
 65. Schmidt-Kastner R, Ophoff BG, Hossmann KA. Pattern of neuronal vulnerability in the cat hippocampus after one hour of global cerebral ischemia. *Acta neuropathol* 1990;79:44-55.
 66. Kirino T. Delayed neuronal death in the gerbil hippocampus following Ischemia. *Brain Res* 1982;239:57-69.
 67. Kirino T, Tamura A, Sano K. Delayed neuronal death in the rat hippocampus following transient forebrain ischemia. *Acta Neuropathol (Berl)* 1984;64:139-47.
 68. Petito CK, Pulsinelli W A. Delayed neuronal recovery and neuronal death in rat hippocampus following severe cerebral ischemia: possible relationship to abnormalities in neuronal processes. *J Cereb Blood flow Metab* 1984; 4(2):194-205.
 69. Schmidt-Kastner R, Hossman KA. Distribution of ischemic neuronal damage in the dorsal hippocampus of rat. *Acta Neuropathol* 1988;76:411-21.
 70. Smith M-L, Kalimo H, Wamer DS, Siesjö BK. Morphological lesions in the brain preceding the development of postischemic seizures. *Acta Neuropathol* 1988;76:253-64.
 71. Hallenbeck JM, Dutka AJ. Background review and current concepts of reperfusion injury. *Arch Neurol* 1990;47: 1245-54.
 72. Yulug B, Kilic Ü, Kilic E, Bahr M. Rifampicin attenuates brain damage in focal ischemia. *Brain Res* 2004;996:76-80.
 73. Fujioka M, Nishio K, Miyamoto S, Hiramatsu K-I, Sakaki T. Hippocampal damage in the human brain after cardiac arrest. *Cerebrovasc Dis* 2000; 10:2-7.
 74. Perito CK, Feldmaml E, Pulsinelli WA, Plum F. Delayed hippocampal damage in humans following cardiorespiratory arrest. *Neurology* 1987; 37:1281-86.
 75. Abe K, Aoki M, Kawagoe J, Yoshida T, Hattori A Ischemic delayed neuronal death a mitochondrial hypothesis. *Stroke*

- 1995;26(8):1478-89.
76. Jorgensen MB, Diemer NH. Selective neuron loss after cerebral ischemia in the rat: possible role of transmitter glutamate. *Acta Neurol Scand* 1982;66(5):536-46.
 77. Simon RP, Swan JH, Griffith T, Meldrum BS. Blockade of N-methyl-D-aspartate receptors may protect against ischemic damage in the brain. *Science* 1984; 226:850-2.
 78. Swan JH, Evans MC, Meldrum BS. Long-term development of selective neuronal loss and the mechanism of protection by 2-amino-7-phosphonoheptanoate in a rat model of incomplete forebrain ischaemia. *J Cereb Blood Flow Metab* 1988;8 (1):64-78.
 79. Wieloch T. Neurochemical correlates to selective neuronal vulnerability. *Prog Brain Res* 1985;63:69-85.
 80. Wieloch T, Lindvall O, Blomqvist P, Gage FH. Evidence for amelioration of ischaemic neuronal damage in the hippocampal formation by lesions of the perforant path. *Neurol Res* 1985; 7(1):24-6.
 81. Simon RP, Griffith T, Evans MC, Swan JH, Meldrum BS. Calcium overload in selectively vulnerable neurons of the hippocampus during and after ischemia: an electron microscopy study in the rat. *J Cereb Blood Flow Metab* 1984;4(3):350-61.
 82. Ghosh A, Greenberg ME. Calcium signaling in neurons: molecular mechanisms and cellular consequences. *Science* 1995;268:239-47.
 83. Lee KS, Tezlaff W, Kreutzberg GW. Rapid down regulation of hippocampal adenosine receptors following brief anoxia. *Brain Res* 1986;380(1):155-8.
 84. Bodsch W, Barbier A, Oehmichen M, Grosse Ophoff B, Hossman KA. Recovery of monkey brain after prolonged ischemia. Protein synthesis and morphological alterations. *J Cereb Blood Flow Metab* 1986;6(1):22-33.
 85. Thilmann R, Xie Y, Kleihues P, Kiessling M. Persistent inhibition of protein synthesis precedes delayed neuronal death in postischemic gerbil hippocampus. *Acta Neuropathol (Berl)* 1986; 71 (1-2): 88-93.
 86. Pasehen W, Schmidt-Kastner R, Djuricic B, Meese C, Linn F. Polyamine changes in reversible cerebral ischemia. *J Neurochem* 1987;49(1):35-37.
 87. Imdahl A, Hossman KA. Morphometric evaluation of post-ischemic capillary perfusion in selectively vulnerable areas of gerbil brain. *Acta Neuropathol (Berl)* 1986;69(3-4):267-71.
 88. Marinkovic SV, Milisavljevic MM, Vuckovic VD. Microvascular anatomy of the uncus and the parahippocampal gyrus. *Neurosurgery* 1991; 29(6):805-14.
 89. Kirino T, Sano K. Selective vulnerability in the gerbil hippocampus following transient ischemia. *Acta Neuropathol (Berl)* 1984; 62:201-8.
 90. López-Hernández E, Parra GL, Bravo J, Reyes TGJ, Solís H. Cambios en la excitabilidad neuronal y alteraciones en la densidad neuronal del hipocampo inducidos por isquemia focal. *Arch Neurocién (Mex)* 1997;2(2):3-8.
 91. Akai F, Yanagihara T. Identity of the dorsal hippocampal region most vulnerable to cerebral ischemia. *Brain Res* 1993;603:87-95.
 92. Solís H, López E, Parra L, Bravo J, Escobar A. Morphological and electrophysiological changes after cerebral ischemia in the rat hippocampus. *Exp Neurol* 1998;151(1):170-1.
 93. López-Hernández E, Parra GL, Bravo MJ, García HA, Ortíz EA. Repercusiones en el hipocampo de la isquemia cerebral focal transitoria. *Rev Mex Enf Cardiol* 1997;5(4):102-8.
 94. Naveiro J, Castillo J, Suárez P, Aldrey JM, Lema M. Tiempo para el daño cerebral por hiperglicemia en la isquemia aguda. *Rev Neurol* 1998; 26(153):790-93.
 95. Kuschinsky W, Gillardon F. Apoptosis and cerebral ischemia. *Cerebrovasc Dis* 2000;110:165-9.
 96. Ferrer I. Mecanismos de muerte neuronal en la isquemia cerebral. *Rev Neurol* 1999; 29 (6):515-21.
 97. Wurtman RJ. La neurotoxicidad en la isquemia cerebral: del laboratorio a la clínica. *Rev Neurol* 1999;29(6):524-26.
 98. Murakami K, Kondo T, Chan PH. Reperfusion following focal cerebral ischemia alters distribution of neuronal cells with DNA fragmentation in mice. *Brain Res* 1997;751:160-4.
 99. Leist M, Volbracht C, Kühnle S, Fava E, Ferrando-May E. Caspase-mediated apoptosis in neuronal excitotoxicity triggered by nitric oxide. *Mol Med* 1997;3(11):750-64.
 100. Bonfoco E, Krainc D, Ankarcona M, Nicoretta P, Lipton SA. Apoptosis and necrosis: two distinct events induced, respectively by mild and intense insults with N-methyl-D-aspartate or nitric oxide/superoxide in cortical cell cultures. *Proc Natl Acad Sci USA* 1995;92(16):7162-6.
 101. Du C, Hu R, Csernansky CA, Hsu CY, Choi D W. Very delayed infarction after mild focal cerebral ischemia: a role for apoptosis? *J Cereb Blood Flow Metab* 1996; 16 (2): 195-201.
 102. Endres M, Namura S; Shimizu-Sasamata M, Waeber C, Zhang L. Attenuation of delayed neuronal death after mild focal ischemia in mice by inhibition of the caspase family. *J Cereb Blood Flow Metab* 1998;18 (3):238-47.
 103. Fink K, Zhu I, Namura S, Shimizu-Sasamata M, Endres M. Prolonged therapeutic window for Ischemic brain damage caused by delayed caspase activation. *J Cereb Blood Flow Metab* 1998;18(10):1071-6.