



Aplastic Anemia and Severe Myelosuppression with Boceprevir or Simeprevir-Containing Hepatitis C Virus Treatment

Alicia Senín,^{*} Teresa Broquetas,^{**} Sabela Lens,^{***} Nuria Cañete,^{**}
María-Carlota Londoño,^{***} Mariana Ferraro,^{*} Xavier Forns,^{***} Antonio Salar,^{*} Jose A. Carrión^{**}

^{*} Department of Clinical Hematology, Hospital del Mar, Barcelona, Spain.

^{**} Liver Unit, Gastroenterology Department, Hospital del Mar, IMIM (Hospital del Mar Medical Research Institute), Barcelona, Spain.

^{***} Liver Unit, Hospital Clinic, IDIBAPS, CIBERehd, Barcelona, Spain.

ABSTRACT

The addition of the new protease inhibitors (PIs) to peg-interferon (IFN) and ribavirin (RBV), approved for chronic hepatitis C, has clearly improved sustained virological response (SVR) rates although several adverse events have been reported with this regimens, including mild hematological toxicity. Moreover, severe pancytopenia and aplastic anemia during triple therapy with telaprevir has recently been described in seven patients. We report here two cases of severe agranulocytosis/aplastic anemia using boceprevir or simeprevir in interferon-based combination and 2 additional cases of severe myelosuppression in IFN-free therapy with sofosbuvir and simeprevir plus RBV. Our observations suggest that PIs could have a sort of class-effect in developing severe hematologic toxicity or, at least, an additive interaction with other potentially myelotoxic agents such as IFN or RBV that are used in the classical regimens against HCV. Unfortunately, the mechanisms behind this phenomenon are currently unknown. In conclusion, given the life-threatening character of these complications, close monitoring is mandatory in patients under PIs based therapy to promptly detect serious hematological toxicities and to carefully evaluate treatment discontinuation. Prospective studies assessing the usefulness of RBV in the era of new IFN-free combinations are needed.

Key words. Anemia. Hepatitis. Toxicity and protease.

INTRODUCTION

Protease inhibitors (PIs) have improved sustained virological response (SVR) in patients with chronic hepatitis C virus (HCV) when used in combination with peg-interferon and ribavirin (PR).¹ Hematological adverse events with PR, like interferon (IFN)-related central myelosuppression or ribavirin (RBV)-related hemolytic anemia are usually mild.² Few cases of hematological serious adverse events (SAEs) in HCV infected patients receiving antiviral treatment with PR have been reported in the literature: two cases of severe aplastic anemia related to IFN-alfa and two cases of pure red cell anemia (PRCA) associated with peg-IFN and RBV, respectively.^{3,4}

Addition of the new PIs to PR has shown a high frequency of mild hematological toxicity.^{5,6} Our group has

recently described severe pancytopenia or aplastic anemia in seven patients during triple therapy with telaprevir (TVR).⁷ Of note, these hematological complications resulted in a high mortality rate (three out of seven patients died). Interestingly, only one of these seven patients had both risk factors (low levels of platelet $< 100 \times 10^9/L$ and albumin $< 35 \text{ g/L}$) for developing adverse events, previously described in cirrhotic patients of the CUPIC cohort.⁸

We here report two cases of severe agranulocytosis/aplastic anemia using boceprevir (BOC) or simeprevir (SMV) in IFN-based combination and 2 additional cases of severe myelosuppression with IFN-free therapy with sofosbuvir and simeprevir (SMV) plus RBV (Table 1 summarises main clinical and laboratory features).

CASE STUDIES

Case 1

This patient was a 42 year-old man with HCV-related cirrhosis (genotype 1a/1b IL28CC), without esophageal varices. His baseline blood tests were normal with the exception of thrombocytopenia ($114 \times 10^9/L$). He started lead-in with PR and at week 4, BOC was added. RBV dose was decreased and erythropoietin (EPO) was started due to hemoglobin (Hb) reduction (103 g/L). At week 8, he had undetectable viral load (VL) and neutrophil count showed grade 1 neutropenia ($1800 \text{ cells}/\mu\text{L}$). At week 12, he was admitted to hospital because of fever and pancytopenia (neutrophils of $0 \text{ cells}/\mu\text{L}$, Hb of 81 g/L and platelets of $39 \times 10^9/L$). Antiviral treatment was withdrawn and antibiotics were initiated. A bone marrow aspiration showed agranulocytosis (Figure 1). He required granulocyte colony stimulating factor (G-CSF) for 5 days, EPO and platelet transfusions (Figure 2). Five days after admission, his neutrophil count recovered and, at last follow-up, the patient has a normal blood cell count.

Case 2

This patient was a 64-year-old man without comorbidities and HCV infection (genotype 1b ILB28CT) with advanced fibrosis (10.4 kilopascals) on transient elastography

Table 1. Main clinical and laboratory features at baseline and during follow-up.

	PEGIFN a2 180 mg/wk + RBV 1200 mg/day		RBV 800 mg/day + SOF 400 mg/day + SMV 150 mg/day	
	BOC 800 mg/8h	SMV 150 mg/day	Case 3	Case 4
	Case 1	Case 2	Case 3	Case 4
Age	42	64	53	58
Gender	Male	Male	Female	Male
Charlson index	3.2	5.4	4.3	6.8
Features at baseline:				
Hemoglobin (g/L)	153	167	167	109
Neutrophils (cell/ μL)	4390	3590	6740	2250
Platelets ($\times 10^9/L$)	114	133	133	89
Reticulocyte (%)	0.2	0.1	<1	<1
Bilirubin (mg/dL)	0.58	0.64	0.60	0.37
Albumin (g/L)	43	38	43	25
INR	1.18	1.03	1.40	0.93
Liver stiffness (kPa)	20.9 (F4)	10.4 (F3)	27 (F4)	14.3 (F4)
CP score (points)	5	-	6	7
MELD (points)	8	-	13	9
Features at pancytopenia:				
IPs therapy (wk)	12	12	24	12
Hematologic toxicity (wk)	12	12	4	6
Treatment interruption	YES	YES	YES	NO
Undetectable VL (wk)	8	4	4	4
Diagnostic	AG	AA	Non-Hem An	AG; Non-Hem An
BMB or BMA	YES	YES	YES	YES
Hb (g/L)	108	61	55	66
Neutrophils (cell/ μL)	0	0	2000	600
Platelets ($\times 10^9/L$)	39	9	140	161
EPO agent	Epoetin alfa	Epoetin alfa	Epoetin alfa	Darbepoetin alfa
EPO agents (wk)	2	39	6	15
G-CSF (days of therapy)	5	40	0	135
RBC (units)	0	21	8	6
Platelets (units)	2	36	0	0
Complication	Infection	Septic shock (<i>E. coli</i> -anal fissure)	-	Infection (herpes)
SVR 12/24wk	YES	NO	YES	YES
Outcome	Recovered	No response	Recovered	Death

INR: International normalized ratio. CP: Child Pugh score. MELD: score Model for End-Stage Liver Disease. Wk: week. Wk t at toxicity: weeks of treatment at toxicity development. AA: Aplastic anemia. AG: agranulocytosis. Non-Hem An: non hemolytic anemia. BMB: bone marrow biopsy. BMA: bone marrow aspiration. EPO: Erythropoietin. RBC: red blood cell units of transfusion. G-CSF: Granulocyte colony stimulating factor. Platelets (units): units of transfusion. SVR 12: sustained viral response at week 12 of treatment. SVR 24: sustained viral response at week 24 of treatment.

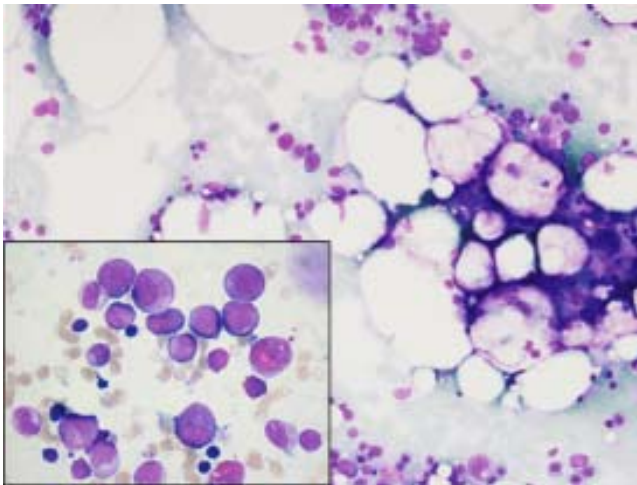


Figure 1. Bone marrow aspiration showing moderate hypocellularity and fat replacement. H&E, 200x. In the inset, promyelocytes and myelocytes consistent with early granulocytic recovery in bone marrow. H&E, 1000x.

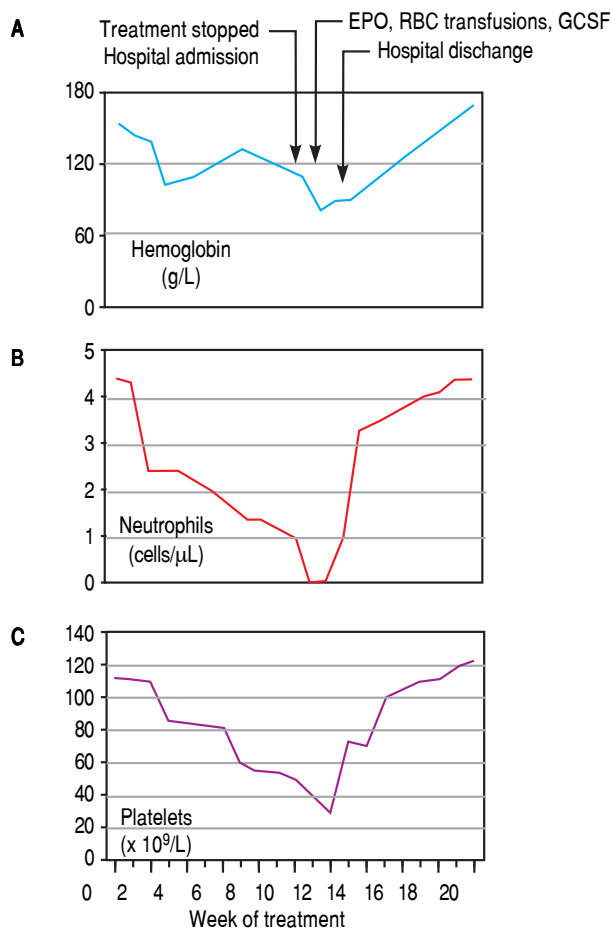


Figure 2. Hemoglobin (A), neutrophils (B) and platelets (C) profiles over a 20 weeks period from starting oral anti-hepatitis C triple therapy in case 1 with highlighted relevant clinical events. EPO: Erythropoietin. RBC: red blood cell units of transfusion. G-CSF: granulocyte colony stimulating factor.

(TE). Baseline tests were normal except for thrombocytopenia (133×10^9 /L). At week 4 after starting PR plus SMV, VL was undetectable. Hemoglobin levels dropped from 164 to 115 g/L, thus EPO alpha was started. At week 8, neutropenia appeared ($620 \text{ cells}/\mu\text{L}$) and G-CSF was given. At week 12, blood tests showed severe pancytopenia with Hb of 75 g/L, neutrophils of $0 \text{ cells}/\mu\text{L}$ and platelet count of 15×10^9 /L. HCV treatment was discontinued and red blood cells and platelet transfusions were initiated. The patient developed fever and was admitted to the hospital. Intensive fluid therapy and broad-spectrum antibiotic was started. A bone marrow aspiration showed severe hypocellularity and a bone marrow biopsy confirmed the diagnosis of aplastic anemia. An extensive work-up was initiated and other causes of acquired bone marrow failure such as myelodysplastic syndrome, leukemia, megaloblastic anemia, paroxysmal nocturnal hemoglobinuria and viral hemophagocytic syndrome were excluded. Then, it is reasonable to associate antiviral treatment as the most plausible cause of hematological toxicity in this case. Treatment with cyclosporine and prednisone was started at 21 days from admission. Though still pancytopenic, he was discharged after 49 days of hospitalization. At last follow-up, 8 months after discontinuing HCV treatment, he is still receiving immunosuppressive therapy, EPO and transfusions. Fortunately, VL remains undetectable.

Case 3

This patient was a 53-year-old woman with genotype 1a HCV-related cirrhosis with esophageal varices and cryoglobulinemia. She had previously received a first course of PR developing severe anemia. Five years later, the patient started RBV, SOF and SMV. At week 4, she achieved undetectable VL but anemia (Hb of 72 g/L) was found, requiring RBV dose reduction, red blood cell transfusion and EPO. At week 6, anemia worsened (Hb of 55 g/L) while neutrophils and platelets remained normal. Laboratory tests excluded hemolysis and vitamin deficiency. RBV and SMV were withdrawn, and daclatasvir (DCV) was added to SOF. A bone marrow examination performed 5 days later, showed incipient recovery of erythroid precursor cells in bone marrow. Three weeks later, Hb levels returned to normal. She could finish 16 weeks of treatment maintaining undetectable VL and normal blood counts.

Case 4

This patient was a 58-year-old man with genotype 1b HCV cirrhosis associated to type 2 cryoglobulinemia with lymphoplasmacytic lymphoma. The patient had received rituximab for his lymphoma twice, both times reaching remission. He received a first course of PR without show-

ing viral response. Eight years later, treatment with SMV and SOF plus RBV was started. At week 4, he achieved undetectable VL but developed grade 3 anemia. Dose of RBV was decreased and red blood cell transfusions and EPO were administered. At week 6, the patient presented with neutropenic fever (neutrophils of 600 cells/ μ L) and severe anemia (Hb of 66 g/L). Broad-spectrum antibiotics plus G-CSF were started and RBV was stopped. Bone marrow aspiration ruled out recurrence of the lymphoproliferative disorder. White cells counts recovered in a week. At week 12, anti-HCV therapy was completed and anemia fully recovered at week 15. Unfortunately, at week 23, the patient developed refractory status epilepticus secondary to an encephalitis by BK virus and died.

DISCUSSION

In the last few years, new antiviral agents have been approved for the treatment of HCV, including first and second generation PIs. Several PIs-based regimens have improved antiviral efficacy but can cause severe adverse events (AEs) including bacterial infections and clinical decompensation of liver disease.⁹ In addition, severe pancytopenia and aplastic anemia during triple therapy, including TVR, have been recently reported.⁷ This severe toxicity has shown a high risk of mortality, being imperative the close monitoring of these patients. Recently, second generation PIs (SMV) have shown a better safety profile and lower risk of developing severe anemia than TVR, a first generation PI.¹⁰

IFN, in addition to its well-known antiviral effect, exerts antiproliferative activity on many cell types, including hematopoietic cells.⁴ This property may lead to cytopenias that can interfere with the successful clinical application of IFN.

In contrast, RBV is a cytotoxic agent and its accumulation in erythrocytes produces oxidative membrane damage, leading to an accelerated extravascular hemolysis by the reticulo-endothelial system.¹¹ At a low dose, it decreases half-life of red cells with a reversible effect when the drug is discontinued, and at high doses, RBV also inhibits the release of red cells from the bone marrow.¹² However, only few cases of severe hematologic toxicity induced by IFN/RBV therapy have been reported in HCV patients after many years of use in the daily practice.^{13,14}

We here report 4 cases of severe hematological toxicity in HCV patients receiving first or second generation PIs with or without IFN, but always with RBV. Interestingly, two of these cases receiving IFN-containing combination were also under BOC or SMV, a first and a second generation PI, respectively.

Causes of hematological toxicity like drug toxicity (EPO, antibiotics, anti-inflammatory drugs, anticonvul-

sants), vitamin deficiency, autoimmune reactions, hemolysis, bone marrow infiltration or malignancy were ruled out by specific diagnostic test or absence of temporal relationship. EPO-related anemia could also be discarded since all our patients fully recovered their red cell counts while maintaining EPO administration, and in addition, to the best of our knowledge, no other cytopenias have been reported with this agent.

Of note, all patients had advanced fibrosis or cirrhosis, but none of them was decompensated and only one of the patients treated without IFN had platelets $< 100 \times 10^9/L$ and albumin < 35 g/L at the beginning of treatment.

In this study, we report 2 patients under triple therapy with PR and PIs who developed aplastic anemia or agranulocytosis, two life-threatening hematologic complications. Interestingly, one patient was receiving BOC, first generation PIs and the other one SMV, a second generation PI. Although the association with PIs cannot be totally proved, our observations suggest a sort of class-effect of PIs in the development of severe hematological toxicity. However, an alternative explanation could be an additive toxic effect of PIs to the well-known IFN/RBV hematologic toxicity or an interaction of the drug combination in susceptible patients.

It is known that genetic variants leading to inosine triphosphatase (ITPA) deficiency protect against hemolytic anemia in HCV-infected patients receiving RBV,¹⁵ but the mechanism sustaining severe anemia during PIs based therapy is still unknown. Recent reports investigating the molecular mechanisms of anemia in anti-HCV triple therapy have shown that TVR-S isomer concentration is related to the concentration of RBV in plasma.¹⁶ It is supposed that TVR can produce a boosting effect on plasma RBV and its intra-erythrocytic concentration, finally leading to a toxic effect. So that, it has been suggested a bimodal pattern: an early phase mainly due to acquired spherocytic-like hemolytic anemia and a late phase showing hyporegenerative features, most likely related to the combined effects of PR and PIs on erythropoiesis.¹⁷

In addition, we have also reported two additional patients who developed severe anemia and one of them also grade 4 neutropenia under IFN-free regimens (SMV and SOF plus RBV). Although this last patient had received rituximab for lymphoma treatment, at the time of starting HCV treatment he was in complete remission of the lymphoma and no clinical or laboratory findings due to cryoglobulinemia were evident. In addition, the coexistence of anemia and neutropenia is not consistent with the clinical picture seen in cases with delayed neutropenia induced by rituximab. To our knowledge, these are the first reported cases of severe hematologic toxicity associated to this three-agent regimen. One patient developed PRCA after 4 weeks of treatment, and the other

initiated severe bicytopenia at 6 weeks of starting therapy. RBV was held in both patients, but SMV and SOF were maintained in one, and SMV was changed to DCV in the other. Although both patients required red blood cell transfusions and EPO, anemia rapidly improved in the following weeks.

This prompt recovery of anemia after RBV withdrawal in our patients suggests that RBV probably is the main causative agent of anemia in IFN-free regimens. However, given the low incidence of PRCA due to RBV in the literature and the resolution of anemia after changing SMV for DCV in our case 4, we cannot completely rule out a possible additive toxic effect of SMV. Considering the high antiviral activity of SMV and SOF, we suggest that RBV might be avoided with these new regimens, especially in those patients with advanced liver disease and in those with mild cytopenias previous starting HCV treatment.¹⁸ However, further studies are needed to evaluate the role of RBV in these new IFN-free regimens.

These cases of severe and life-threatening adverse events have occurred in our center in a period of scarcely 2 years in which about 170 patients received treatment with PIs. This observation highlights an unexpected high incidence of hematologic toxicity, something not previously observed by our group despite decades of treatment with PR. Moreover, these hematologic complications entail large amounts of health resources, including the use of support treatment with G-CSF and EPO, transfusions, broad spectrum antibiotics, antifungals and even long-term hospitalization. In order to optimize resource use, we recommend a close cooperation between hematology and hepatology teams,¹⁹ as we previously suggested.²⁰

In conclusion, severe hematological adverse events in patients treated with PIs and RBV are more frequent than expected, an observation suggesting either a possible class effect of PIs in the development of these toxicities or an interaction to the drug combination in susceptible patients. Given the life-threatening character of these complications in some patients, we highly recommend to promptly discontinue RBV if blood cells significantly drop and to avoid it in cases with increased risk of development of hematological toxicity. In addition, close cooperation between hematologists and hepatologists is also advisable.

ABBREVIATIONS

- **BOC:** boceprevir.
- **DCV:** daclatasvir.
- **EPO:** erythropoietin.
- **G-CSF:** granulocyte colony stimulating factor.
- **Hb:** hemoglobin.
- **HCV:** chronic hepatitis C virus.

- **IFN:** peg-interferon.
- **ITPA:** inosine triphosphatase.
- **Pis:** protease inhibitors.
- **PR:** peg-interferon and ribavirin.
- **PRCA:** pure red cell anemia.
- **RBV:** ribavirin.
- **SAEs:** serious adverse events.
- **SMV:** simeprevir.
- **SVR:** sustained virological response.
- **TE:** transient elastography.
- **TVR:** telaprevir.
- **VL:** viral load.

AUTHOR CONTRIBUTIONS

ASe and TB have equally contributed as junior co-authors and ASa and JAC have equally contributed as senior co-authors. ASe, TB, ASa and JAC were involved in acquisition of data; analysis and interpretation of data; drafting the manuscript; critical revision of the manuscript for important intellectual content.

SL, NC, MCL, MF, XF were involved in acquisition of data; critical revision of the manuscript for important intellectual content.

FINANCIAL SUPPORT

ASe is a recipient of a grant from the SEHH (Sociedad Española de Hematología y Hemoterapia).

ETHICS APPROVAL

The study was reviewed and approved by the Hospital del Mar Institutional Review Board.

INFORMED CONSENT

All study participants, provided informed written consent prior to study enrollment.

CONFLICT OF INTEREST

The authors declare no conflict of interest.

REFERENCES

1. McHutchison JG, Manns MP, Muir AJ, Terrault NA, Jacobson IM, Afdhal NH, Heathcote EJ, et al. Telaprevir for previously treated chronic HCV infection. *N Engl J Med* 2010; 362: 1292-303.
2. European Association For The Study Of The Liver. EASL Clinical Practice Guidelines: Management of hepatitis C virus infection. *J Hepatol* 2013; 63: 199-236.
3. Ioannou S, Hatzis G, Vlahadami I, Voulgarelis M. Aplastic anemia associated with interferon alpha 2a in a patient with

- chronic hepatitis C virus infection: a case report. *J Med Case Rep* 2010; 4: 268.
4. Hoffmann A, Kirn E, Krueger GR, Fischer R. Bone marrow hypoplasia and fibrosis following interferon treatment. *In Vivo* 1994; 8: 605-12.
 5. Jacobson IM, McHutchison JG, Dusheiko G, Di Bisceglie AM, Reddy KR, Bzowej NH, Marcellin P, et al. Telaprevir for previously untreated chronic hepatitis C virus infection. *N Engl J Med* 2011; 364: 2405-16.
 6. Poordad F, McCone JJr, Bacon BR, Bruno S, Manns MP, Sulkowski MS, Jacobson IM, et al. Boceprevir for untreated chronic HCV genotype 1 infection. *N Engl J Med* 2011; 364: 1195-2206.
 7. Lens S, Calleja JL, Campillo A, Carrion JA, Broquetas T, Perello C, de la Revilla J, et al. Aplastic anemia and severe pancytopenia during treatment with peg-interferon, ribavirin and telaprevir for chronic hepatitis C. *World J Gastroenterol* 2015; 21: 5421-6.
 8. Hézode C, Fontaine H, Dorival C, Larrey D, Zoulim F, Canva V, de Ledinghen V, et al. Triple therapy in treatment-experienced patients with HCV-cirrhosis in a multicentre cohort of the French Early Access Programme (ANRS CO20-CUPIC) - NCT01514890. *J Hepatol* 2013; 59: 434-41.
 9. Londono MC, Perello C, Cabezas J, Canete N, Lens S, Marino Z, Gambato M, et al. The addition of a protease inhibitor increases the risk of infections in patients with hepatitis C-related cirrhosis. *J Hepatol* 2015; 62: 311-16.
 10. Ogawa E, Furusyo N, Kajiwara E, Nomura H, Kawano A, Takahashi K, Dohmen K, et al. Comparative safety study on severe anemia by simeprevir- versus telaprevir-based triple therapy for chronic hepatitis C. *J Gastroenterol Hepatol* 2015; 30: 1309-16.
 11. De Franceschi L, Fattovich G, Turrini F, Ayi K, Brugnara C, Manzato F, Noventa F, et al. Hemolytic anemia induced by ribavirin therapy in patients with chronic hepatitis C virus infection: role of membrane oxidative damage. *Hepatology* 2000; 31: 997-1004.
 12. Canonico PG, Castello MD, Spears CT, Brown JR, Jackson EA, Jenkins DE. Effects of ribavirin on red blood cells. *Toxicol Appl Pharmacol* 1984; 74: 155-62.
 13. Miura Y, Kami M, Yotsuya R, Toda N, Komatsu T. Pure red-cell aplasia associated with pegylated interferon-alpha-2b plus ribavirin. *Am J Hematol* 2008; 83: 758-9.
 14. Tanaka N, Ishida F, Tanaka E. Ribavirin-induced pure red-cell aplasia during treatment of chronic hepatitis C. *N Engl J Med* 2004; 350: 1264-5.
 15. Fellay J, Thompson AJ, Ge D, Gumbs CE, Urban TJ, Shianna KV, Little LD, et al. ITPA gene variants protect against anaemia in patients treated for chronic hepatitis C. *Nature* 2010; 464: 405-8.
 16. Cusato J, Allegra S, De Nicoló A, Boglione L, Fatiguso G, Mohamed Abdi A, Cariti G, et al. Intracellular and Plasma Trough Concentration and Pharmacogenetics of Telaprevir. *J Pharm Pharm Sci* 2015; 18: 171-6.
 17. Lupo F, Russo R, Iolascon A, Ieluzzi D, Siciliano A, Toniutto P, Matté A, et al. Protease inhibitors-based therapy induces acquired spherocytic-like anemia and ineffective erythropoiesis in chronic HCV patients. *Liver Int* 2016; 36: 49-58.
 18. Lawitz E, Sulkowski MS, Ghalib R, Lawitz E, Sulkowski MS, Ghalib R, Rodriguez-Torres M, et al. Simeprevir plus sofosbuvir, with or without ribavirin, to treat chronic infection with hepatitis C virus genotype 1 in non-responders to pegylated interferon and ribavirin and treatment-naive patients: the COSMOS randomised study. *Lancet* 2014; 384: 1756-65.
 19. Romero-Gómez M, Berenguer M, Molina E, Calleja JL. Management of anemia induced by triple therapy in patients with chronic hepatitis C: challenges, opportunities and recommendations. *J Hepatol* 2013; 59: 1323-30.
 20. Carrión JA, Gonzalez-Colominas E, García-Retortillo M, Cañete N, Cirera I, Coll S, Giménez MD, et al. A multidisciplinary support programme increases the efficiency of pegylated interferon alfa-2a and ribavirin in hepatitis C. *J Hepatol* 2013; 59: 926-33.

Correspondence and reprint request:

Alicia Senín, M.D.

Department of Clinical Hematology, Hospital del Mar, 25-29

Passeig Marítim, 08003 Barcelona, Spain.

Tel.: +34932483000. Fax: 932483343.

E-mail: 60014@parcdesalutmar.cat