

7. Burashnikov E, Pfeiffer R, Barajas-Martínez H, et al. Mutations in the cardiac L-type calcium channel associated with inherited J-wave syndromes and sudden cardiac death. *Heart Rhythm*. 2010;7:1872–82.
8. Chopra N, Knollmann BC. Genetics of sudden cardiac death syndromes. *Curr Opin Cardiol*. 2011;26:196–203.
9. Watanabe H, Nogami A, Ohkubo K, et al. Electrocardiographic characteristics and SCN5A mutations in idiopathic ventricular fibrillation associated with early repolarization. *Circ Arrhythm Electrophysiol*. 2011;4:874–81.
10. Survivors of out-of-hospital cardiac arrest with apparently normal heart. Need for definition and standardized clinical evaluation. Consensus Statement of the Joint Steering Committees of the Unexplained Cardiac Arrest Registry of Europe and of the Idiopathic Ventricular Fibrillation Registry of the United States. *Circulation*. 1997;95:265–72.

Margarita Dorantes<sup>a,\*</sup>, Roberto Marrero<sup>a</sup>,  
Annerys Méndez<sup>b</sup>, Jesús Castro<sup>a</sup> y Alfredo Vázquez<sup>a</sup>

<sup>a</sup> Servicio de Arritmias y Estimulación Cardíaca, Instituto de Cardiología y Cirugía Cardiovascular, La Habana, Cuba

<sup>b</sup> Servicio de Arritmias y Marcapasos, Hospital Hermanos Ameijeiras, La Habana, Cuba

\*Autora para correspondencia: 17 # 702, Plaza, CP 10400, Habana, Cuba. Teléfono: (537) 8386347.

Correo electrónico: dorantes@infomed.sld.cu (M. Dorantes).

<http://dx.doi.org/10.1016/j.acmx.2013.05.007>

## Aortic stenosis in the background of a subaortic membrane and tunnel-like ventricular outflow tract septal hypertrophy

### Estenosis aórtica secundaria a membrana subaórtica e hipertrofia secundaria del tracto de salida de ventrículo izquierdo tipo túnel muscular

A 42-year-old healthy woman was admitted to our institution with progressive dyspnea accompanied by angina pectoris on exertion during the last two years. Physical examination revealed the presence of a grade III/VI harsh midsystolic ejection murmur, maximal in the second right intercostal space and with radiation to the neck. On electrocardiography a sinus rhythm was demonstrated. Besides, left axis deviation, signs of left ventricular hypertrophy and none specific intraventricular conduction delay were found. A transthoracic echocardiogram was achieved. It showed moderate asymmetric septal hypertrophy with narrowing of the left ventricular outflow tract, and presence of a subaortic membrane below the aortic valve. Transesophageal echocardiography demonstrated an aortic valve with three native aortic leaflets preserved (absence of calcification or fibrosis). However, presence of a subaortic membrane

(SAM) was detected (Fig. 1). Flow acceleration in the left ventricular outflow tract (LVOT) of 4 m/s and a mean and maximum gradient of 42 mmHg and 81 mmHg respectively were demonstrated. In addition, the top part of the septum underneath the aortic valve (AV) level was hypertrophic (SH) like a tunnel, with a diastolic septum wall thickness of 22 mm causing LVOT obstruction. No cardiac catheterization was achieved because of the young age of the patient and absence of cardiovascular risk factors associated. Due to echocardiography findings and symptoms, surgical management was decided and the patient underwent cardiac surgery. Through median sternotomy standard cardiopulmonary bypass was established. We performed a longitudinal aortic arteriotomy, confirmed normal trileaflet aortic valve, resected a fibrotic and muscular subaortic membrane on a ring-like shape and performed a septal myectomy for enlargement of the LVOT. After resection and septal myectomy, we measured transaortic gradients and detected a gradient of 20 mmHg between left ventricle and ascending aorta. Intraoperative echocardiography confirmed complete surgical resection of subaortic membrane. The patient recovered uneventfully and was discharged seven days after surgery. After ten months, postoperative transthoracic echocardiography showed an 11-mm diastolic wall thickness of septum underneath the aortic valve and absence of flow acceleration with a residual gradient of 20 mmHg at the left ventricular outflow

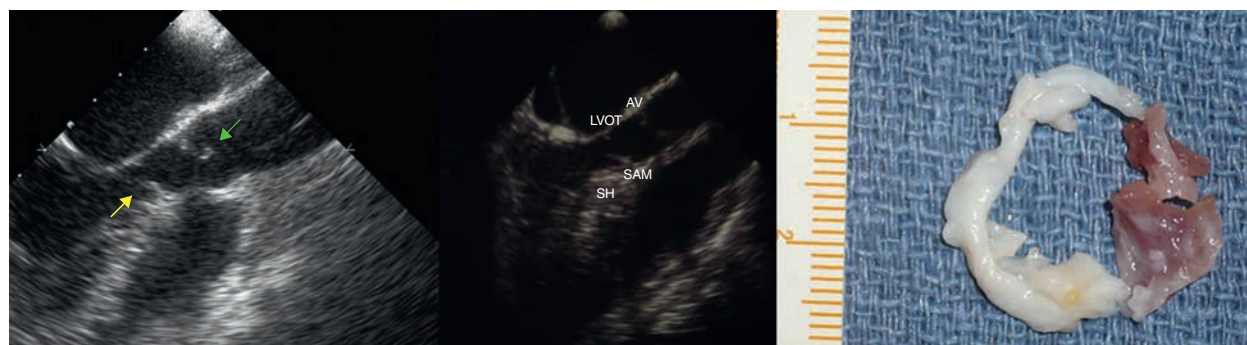


Figure 1 Subaortic membrane.

tract (LVOT). Thickness of aortic valve leaflets and no signs of stenosis or aortic valve regurgitation were confirmed.

Membrane subaortic stenosis is a congenital abnormality often discovered in young adults. Usually, patient remains asymptomatic until third or fourth decade, explaining late diagnosis. An asymmetric ventricular septal hypertrophy is usually associated and results in pressure overload secondary to subaortic membrane narrowing located on LVOT.

Clinical manifestations are largely variable, from asymptomatic cases to symptoms such as dyspnea, syncope, or angor.<sup>1,2</sup> Arrhythmias related to ventricular hypertrophy or nonspecific intraventricular conduction delays are not uncommon.<sup>3</sup> Diagnosis of congenital cardiopathies was initially based on clinical evaluation and echocardiography finding. The importance of color-coded Doppler and use of 2-dimensional echocardiography was initially described to enable diagnosis, treatment planning, spatial relationships and follow-up anatomy.<sup>4,5</sup> However, with the widespread use of new imaging techniques, diagnosis has radically improved in terms of accuracy and quality of preoperative images. In addition to transesophageal echocardiography widely used,<sup>6</sup> the magnetic resonance allows a functional diagnosis mainly related to anatomy and flow conditions.<sup>7</sup> However its use has not been generalized at present due to its low accessibility and high cost. Surgical treatment is decided according to clinical symptoms and flow acceleration or gradients through the subaortic membrane. When patients are symptomatic or maximum trans-aortic gradient is over 50 mmHg, they are derived to surgery. Recurrence is possible. It happens in complex cardiac defects, incomplete resection of subaortic membrane or deficient septal hypertrophy relief. Surgical treatment includes entire subaortic membrane resection and wide septal myectomy in order to improve residual gradients through LVOT and prevent recurrence of subaortic stenosis.<sup>8,9</sup>

We presented a case of a medium-age woman diagnosed with a subaortic membrane and a tunnel-like septal hypertrophy. We highlight the importance to discard this possibility especially in young adults with typical symptoms or signs of aortic stenosis and idiopathic left ventricular hypertrophy.

## References

1. Weymann A, Schmack B, Rosendal C, et al. Surgical management of subaortic stenosis. *Ann Thorac Cardiovasc Surg.* 2013;19:390–3.
2. Attie F, Zavaleta D, Ovseyevitz J, et al. Membranous subaortic stenosis. *Arq Bras Cardiol.* 1983;41:97–102.
3. Martín-Luengo C, Arribas-Jiménez A, Pabón-Osuna P, et al. Cardiomyopathy (X). Clinical approach to the patient with hypertrophic cardiomyopathy. *Rev Esp Cardiol.* 1996;49:457–69.
4. Vicente-Vera T, Valdés-Chavarrí M, García-Alberola A, et al. Importance of color-coded Doppler in a case of interventricular communication associated with fixed subaortic stenosis. *Arch Inst Cardiol Mex.* 1989;59:603–5.
5. Rodríguez-López AM, Huerta D, Velasco P, et al. 2-Dimensional echocardiography in fixed fibrous subaortic stenosis. Correlation with hemodynamics and M-mode echocardiography. *Arch Inst Cardiol Mex.* 1984;54:11–9.
6. Movsowitz C, Jacobs LE, Eisenberg S, et al. Discrete subaortic valvular stenosis: the clinical utility and limitations of transthoracic echocardiography. *Echocardiography.* 1993;10:485–7.
7. Bastarrika Alemañ G, Gavira Gómez JJ, Zudaire Díaz-Tejeiro B, et al. Cardiac magnetic resonance imaging of congenital heart defects in adults. *Radiología.* 2007;49:397–405.
8. Serraf A, Zoghby J, Lacour-Gayet F, et al. Surgical treatment of subaortic stenosis: a seventeen-year experience. *J Thorac Cardiovasc Surg.* 1999;117:669–78.
9. Valeske K, Huber C, Mueller M, et al. The dilemma of subaortic stenosis a single center experience of 15 years with a review of the literature. *Thorac Cardiovasc Surg.* 2011;59:293–7.

María Elena Arnáiz-García<sup>a,\*</sup>, Jose María González-Santos<sup>a</sup>,  
María José Dalmau-Sorlí<sup>a</sup>, Javier López-Rodríguez<sup>a</sup>,  
María Bueno-Codoñer<sup>a</sup>, Antonio Arribas-Jiménez<sup>b</sup>

<sup>a</sup> Cardiac Surgery Department, University Hospital of Salamanca, Salamanca, Spain

<sup>b</sup> Cardiology Department, University Hospital of Salamanca, Salamanca, Spain

\*Corresponding author.

E-mail address: elearnaiz@hotmail.com  
(M.E. Arnáiz-García).

<http://dx.doi.org/10.1016/j.acmx.2013.07.008>

## Miocardopatía arritmogénica del ventrículo derecho con afectación del ventrículo izquierdo y trombos endocavitarios: diagnóstico mediante cardiorresonancia magnética

Arrhythmogenic right ventricular cardiomyopathy with left ventricular involvement and intracavitary thrombus: Diagnosis with cardiac magnetic resonance

Sr. Editor:

La miocardopatía arritmogénica del ventrículo derecho (MAVD) es una enfermedad hereditaria autosómica

dominante que afecta con mayor frecuencia a varones y puede causar muerte súbita en sujetos jóvenes<sup>1,2</sup>. Sus manifestaciones clínicas son variables en función de la severidad y patrón de afectación del miocardio. A pesar de que el ventrículo derecho es el ventrículo clásicamente afectado en esta enfermedad, la afectación del ventrículo izquierdo está siendo cada vez más reconocida. Esto se debe en gran parte al incremento en el empleo de técnicas de imagen, como la cardiorresonancia magnética (CRM), de gran utilidad clínica para caracterizar el miocardio y diagnosticar sus enfermedades.

Se presenta el caso de un hombre de 47 años, fumador, hipertenso, sin antecedentes familiares de cardiopatía isquémica, que acudió al Servicio de Urgencias de otro hospital por palpitaciones y disnea. Como único antecedente familiar refería que un tío había fallecido de muerte súbita